

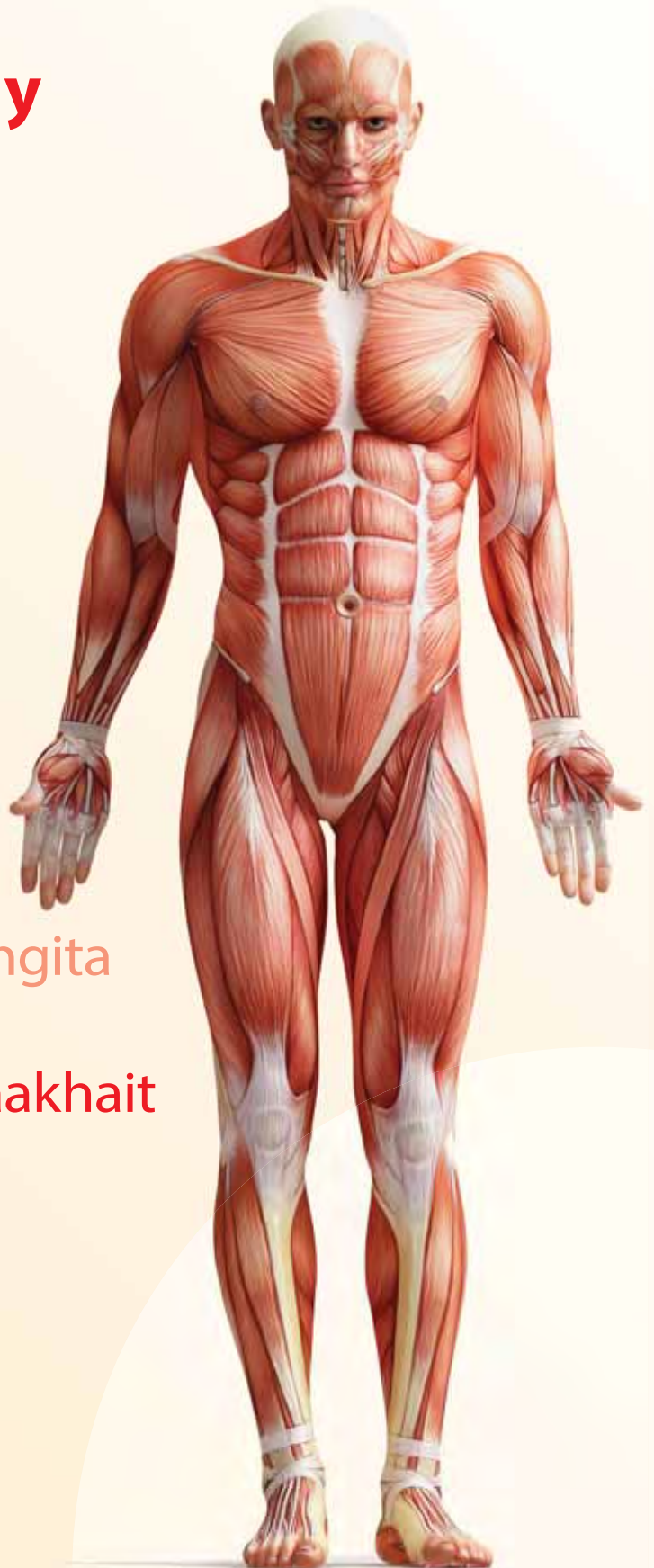# Terminology on Human Anatomy

በገጠና  
የሥነ-ጥናት  
ርዕሰ-ጽሑፍ

Timiup  
Kisukuttilimaangita  
Taiguusingit

Timimi Kituuyaakhait  
Taidjutait

Terminologie  
anatomique









# INTRODUCTION

This is the first colored illustrated human anatomy glossary in Nunavut's official languages. Under Nunavut's language legislation, Nunavummiut have a right to be served in their official language of choice. It is our hope this glossary will become a tool to help improve communications between doctors, nurses, interpreters and patients working and living in our Territory.

Human anatomy terminology is well documented in both English and French. Attempts were made to document human anatomy in Inuktitut from written sources (see Guy Bordin's *Analytical Lexicon of Human Anatomy*, 2003). However, this is the first time traditional terminology in both Inuktitut and Inuinnaqtun on human anatomy is documented directly from Inuit Elders, in consultations with medical interpreters, translators and health professionals in Nunavut.

This project was initiated to address the concerns of Inuit Elders who often struggle to understand or be understood as they often rely on interpretation for their health and medical conditions. We can't stress enough how important the use of accurate terminology in interpretation is crucial for a person's well-being and dignity.

To address these challenges, the Department of Culture and Heritage hosted four workshops in Iqaluit, Kugluktuk and Ulukhaqtuuq, NWT. Participants helped identify Inuktitut and Inuinnaqtun equivalents of approximately 400 English terms related to human anatomy. A review of the terms and associated illustrations was also conducted with smaller groups of Elders and a medical interpreter.

We would like to thank the following individuals who helped identify, review and edit the terms.

## Department of Culture and Heritage

Agnes Ayalik, Agnes Egotak, Carol Cancel, Ida Ayalik-McWilliam, Lazarie Otak, Madeleine d'Argencourt, Ranbir Hundal, Rosemarie Meyok, Sarah Nangmalik, Tocasie Burke.

## Department of Health

Abigail Ootova, Agnes Adams, Alice Kimiksana, Audrey Lemieux, Catherine Kuneluk-Taktogon, Connie Alanak, Diane Netser, Eric Anautalik, Irene Eckalook, Lizzie Nowdluk, Lori Barbour, Louisa Oqaituq, Lucy Anna Nookiguak, Mary Gabby Ikkidluak, Mary Kopak, Nora Niptanatiak-Evaglok, Rene Qulaut, Rosie Kagak, Sarah MacRury, Sandra Qamaniq, Sipporah Peterloosie, Timothy Qamaniq, Veronica Komangat.

### **Nunavut Elders**

Alice Ayalik, Arsene Ivalu, David Issigaitok, Elijah Erkloo, Elisapee Adla, Elisapee Ootovak, Jaycopie Iqalukjuaq, Joanna Qamaniq, Joanasie Kooneeloosie, Joe Ogina, Kigutikarjuk Shappa, Lillian Elias, Louisa Aitaok, Louis Angalik, Margaret Nakashook, Martha Nangmalik Enuaraq, Mariam Aglukkaq, Marianne Tattuini, Mark Taletok, Mary Kudlak, Morris Nigiyok, Nangaat Idlout, Nathan Qamaniq, Norman Attungala, Qapik Attagutsiak, Rene Oliktoak, Rhoda Karetak, Sammy Qaumagiak, Simeonie Aqpik, Simeonie Kaerner, Susie Angotealuk, Thomas Kublu, Tommy Kilaodlok, Tommy Pigalak.

### **Interpreter translators**

Jean Kusugak, Margo Kadlun-Jones, Mary Jean Katiak, Oleepika Ikkidluak.

### **Resource People**

Doris Elatiak, Emily Kudlak, Julia Ogina, Nancy Kadlun.

# ግዴታዎች

ጅምር ገዳማዎች የሚሰጡት ግዴታዎች ከሌሎች ግዴታዎች ጋር ሲያጠናክሩ ለማስታወሻው ለተጨማሪ ማረጋገጫ ለውጭ አገር የሚሰጡ ግዴታዎች ለሌሎች ግዴታዎች ሲወሰዱ ለዚህ ማረጋገጫ ላይ ማረጋገጫ ማስገባት አስፈላጊ ነው።

በግዴታዎች ላይ የተደረገው ለውጥ ለተጨማሪ ማረጋገጫ ለውጭ አገር የሚሰጡ ግዴታዎች ለሌሎች ግዴታዎች ሲወሰዱ ለዚህ ማረጋገጫ ላይ ማረጋገጫ ማስገባት አስፈላጊ ነው።

ጅምር ገዳማዎች የሚሰጡት ግዴታዎች ከሌሎች ግዴታዎች ጋር ሲያጠናክሩ ለማስታወሻው ለተጨማሪ ማረጋገጫ ለውጭ አገር የሚሰጡ ግዴታዎች ለሌሎች ግዴታዎች ሲወሰዱ ለዚህ ማረጋገጫ ላይ ማረጋገጫ ማስገባት አስፈላጊ ነው።

በግዴታዎች ላይ የተደረገው ለውጥ ለተጨማሪ ማረጋገጫ ለውጭ አገር የሚሰጡ ግዴታዎች ለሌሎች ግዴታዎች ሲወሰዱ ለዚህ ማረጋገጫ ላይ ማረጋገጫ ማስገባት አስፈላጊ ነው።

የግዴታዎች ላይ የተደረገው ለውጥ ለተጨማሪ ማረጋገጫ ለውጭ አገር የሚሰጡ ግዴታዎች ለሌሎች ግዴታዎች ሲወሰዱ ለዚህ ማረጋገጫ ላይ ማረጋገጫ ማስገባት አስፈላጊ ነው።

## ግዴታዎች

ግዴታዎች ላይ የተደረገው ለውጥ ለተጨማሪ ማረጋገጫ ለውጭ አገር የሚሰጡ ግዴታዎች ለሌሎች ግዴታዎች ሲወሰዱ ለዚህ ማረጋገጫ ላይ ማረጋገጫ ማስገባት አስፈላጊ ነው።

## ግዴታዎች

ግዴታዎች ላይ የተደረገው ለውጥ ለተጨማሪ ማረጋገጫ ለውጭ አገር የሚሰጡ ግዴታዎች ለሌሎች ግዴታዎች ሲወሰዱ ለዚህ ማረጋገጫ ላይ ማረጋገጫ ማስገባት አስፈላጊ ነው።





# HIVUATIGUN NAUNAITKUTIT

Una hivulliuuyq ivitaalik piksait timitigut tainikhat Nunavut Iltariyauhimagut Uqauhiinut titiraqhimayuq. Ukunani Nunavut uqauhiinik maligani. Nunavunmiut pilaarutiqaqtut inmik uqauhirmingnut aturumayamingnut ikayuqtautaaqtut. Piyumayugut ukua tainikhat titirait ikayuutauniaqtuq nakuuharlugit tuha-apkainiit taaktinut, munaqhinut, numiktiriyinut, aanniaqtunut nunaqaqtut Avikturviptingni.

Timitigut tainikhat titirattiaqhimayut Qablunaatut Uiviititullu. Uuktuqpaktu-ugaluit titirarlugit timip taidjutait Inuktut titirariiqhimayunit (takulugu Guy Bordin Ihiviruttiaqhimayuq Tainiit Timitigut, 2003-mi) kihiani, una hivulliuuyq pitquhiit tainiit tamangnik atuqhugik, Inuktitut Inuinnaqtullu timitigut tainikhat titiraqtauhimaliqtut ikayuqtiqaqhutik uqarvigiblugit Inirnikhaat, qauhiyarvigiblugit aanniaqtuliqiyit havaktiit numiktiriyit, aanniaqtuliqiyit ayuittiaqtunit Nunavunmi.

Una havaakhauhiq aulapkaqhimayaat kiudjutaubluni ukununga Inuit Inirnikhaat ilaani ayuqhaqpangmata kangiqhiyaamingni numiktiriyiqainnarmata aanniaru-timingnik uluriahuutigiyamingnik. Qanuq unniutiyaffingni akhuurluta ikpingnaqtuq aturiami ihuaqtunik taidjutikhanik numiktiriliraangamik ikpingnaqtuuyurlu inuup inuuhianut pidjutikhaanut.

Kiudjutigiangita haputauvaktut, Pitquhiliqiyitkut katimapkaihimmaaahimayut hitamaiqtuqhutik Iqalungni, Kugluktumi Ulukhaqtuumilu Nunattiami. Kati-maqatauyut ikayuqtut naunaiqhiblutik Inuktitut Inuinnaqtullu aadjikkuutat amigiangiqaqtut imaa 400-nguyut qablunaatut tainiit timikkut. Ihivriuqtaqhugit tainiit piksaillu katimayut ikitqiyat Inirnikhaat munaqhiqarvingni numiktiriyiit.

Quyagiyumayavut ukua ikayuqpaktut naunaiqhaiblutik, ihivriuqhiblutik ihuaqhaiblutik tainiinnik.

## Pitquhiliqiyitkunit

Sarah Nangmalik, Tocasie Burke, Ida Ayalik-McWilliam, Rosemarie Meyok, Agnes Ayalik, Agnes Egotak, Lazarie Otak, Madeleine d'Argencourt, Ranbir Hundal, Carole Cancel.

## Munaqhiliqiyitkunit

Lori Barbour, Sipporah Peterloosie, Timothy Qamaniq, Rosie Kagak, Catherine Kuneluk-Taktogon, Sarah MacRury, Sandra Qamanirq, Rene Qulaut, Mary Gabby Ikkidluak, Abigail Ootova, Lucy Anna Nookiguak, Irene Eckalook, Eric Anautalik, Diane Netser, Agnes Adams, Louisa Oqaituq, Lizzie Nowdluk, Mary Kopak, Audrey Lemieux.

## **Nunavunmi Inirnikhaat**

Elijah Erkloo, Elisapee Ootovak, Qapik Attagutsiak, Kigutikarjuk Shappa, Jaycopie Iqalukjuaq, David Issigaitok, Arsene Ivalu, Thomas Kublu, Sammy Qaumagiak, Elisapee Adla, Simeonie Aqpik, Joanasie Kooneeloosie, Martha Nangmalik Enuaraq, Marianne Tattuini, Susie Angotealuk, Louis Angalik, Rhoda Karetak, Nangaat Idlout, Mariam Aglukkaq, Alice Ayalik, Norman Attungala, Simeonie Kaernerik, Joanna Qamaniq, Nathan Qamaniq, Mark Taletok, Tommy Kilaohok, Rene Oliktoak, Morris Nigiyok, Tommy Pigalak, Mary Kudlak, Louisa Aitaok, Margaret Nakashook, Lillian Elias.

## **Numiktiriyuyut**

Jean Kusugak, Oleepika Ikkidluak, Margo Kadlun-Jones, Mary Jean Katiak.

# Body/Trunk/Limbs

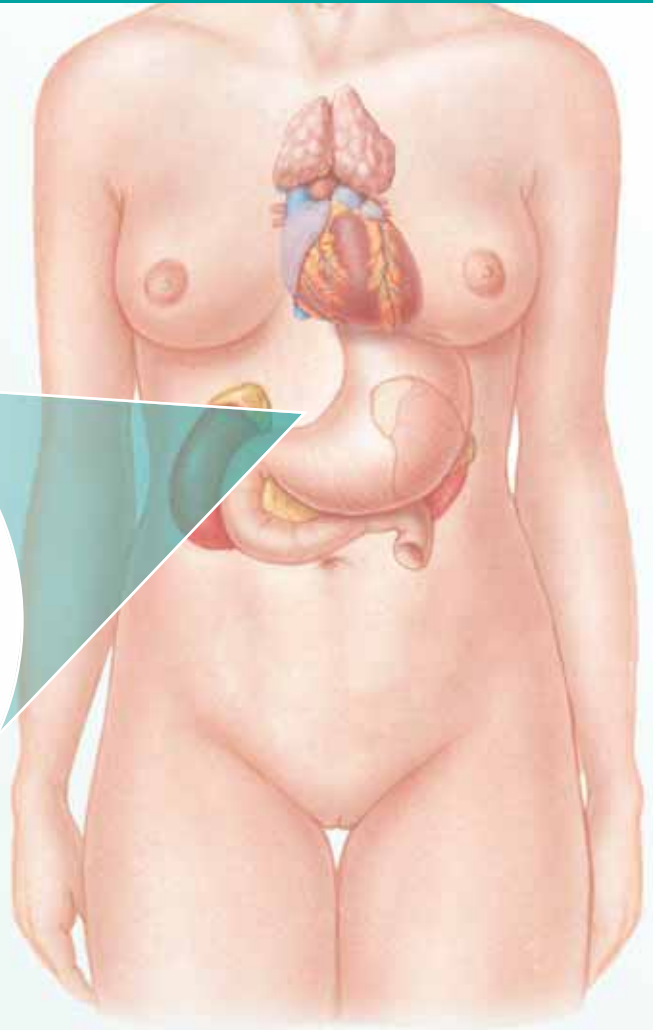
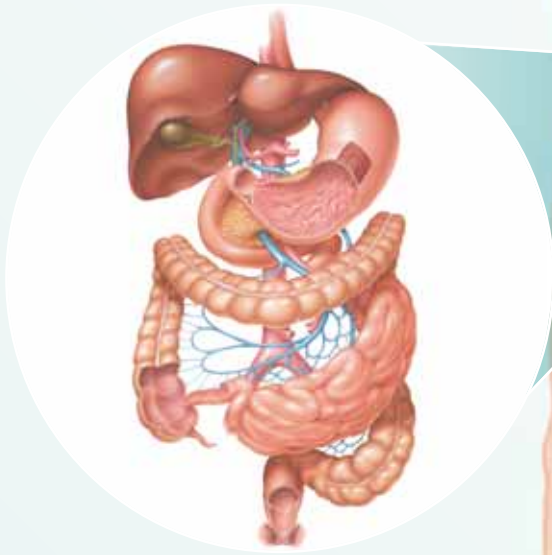ᑎᑦ / ᑭᑦᑎᑦ / ᑕᑦᑭᑦᑎᑦ

Timi/Kiati/Iqijarniit

Timi/Qatigak/Avatiit

Corps / Tronc / Membres

# Abdomen/ Belly



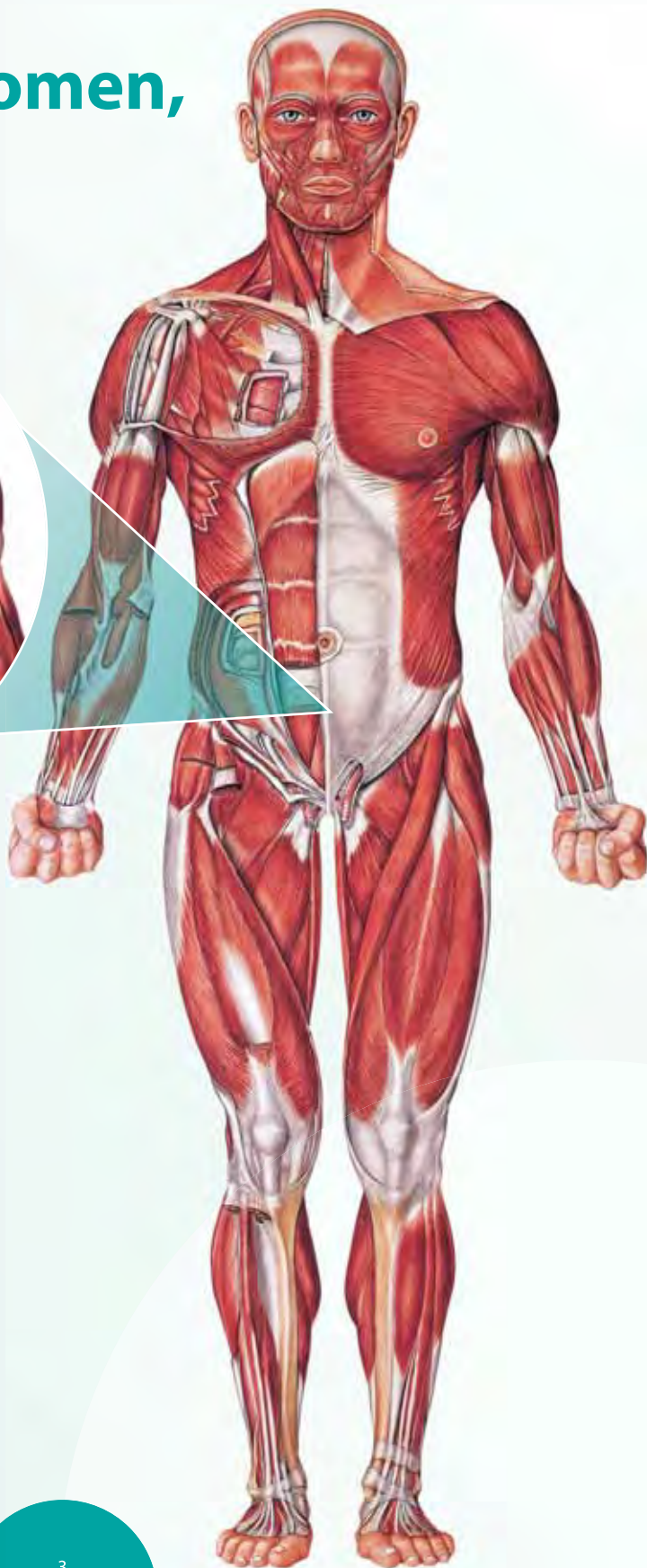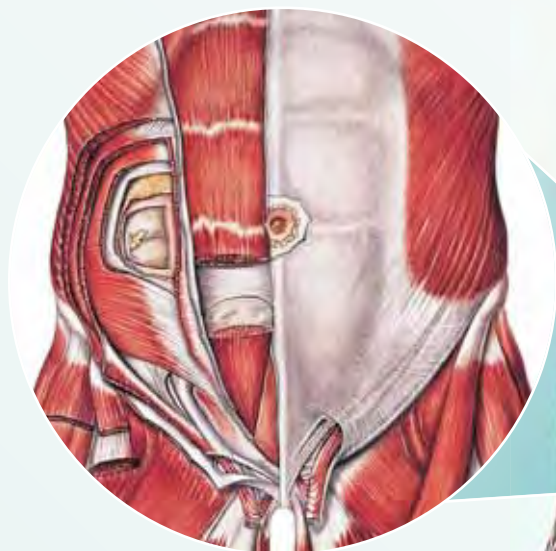᠒᠙᠖

Naaq

Naaq

Ventre, abdomen

# Lower Abdomen, Lower Belly



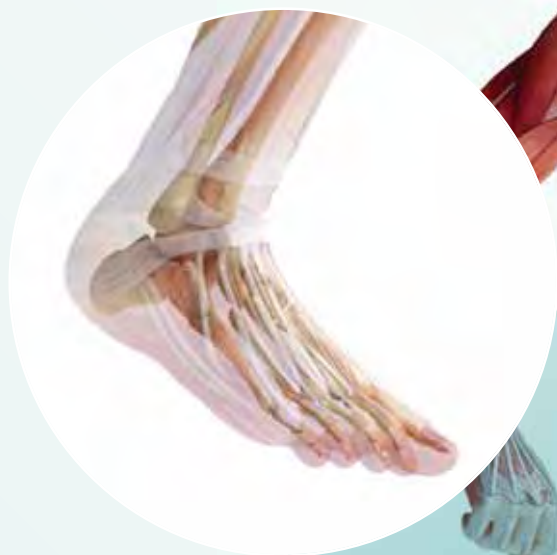ᐱᐃᐱᐃᐃᐃᐃ

Akuaq

Akuaq

Bas-ventre

# Ankle

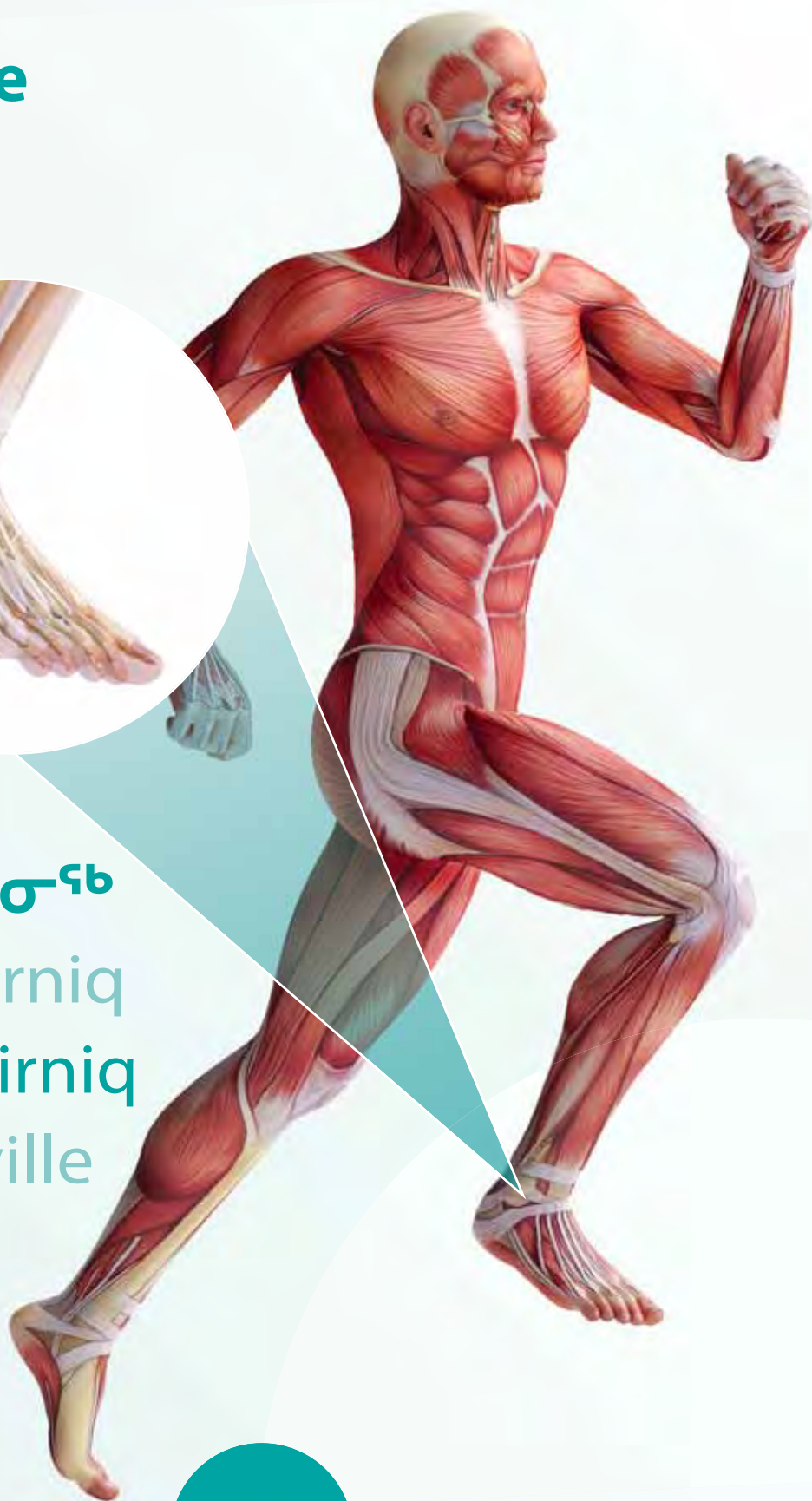

ᲠᲚᲛᲗᲚᲛᲗ

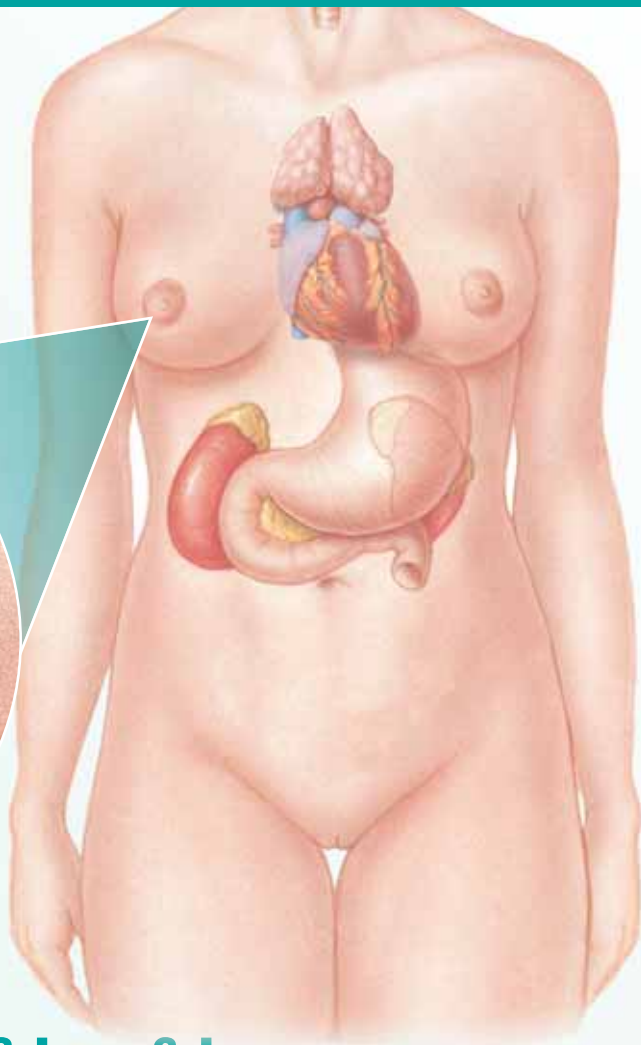
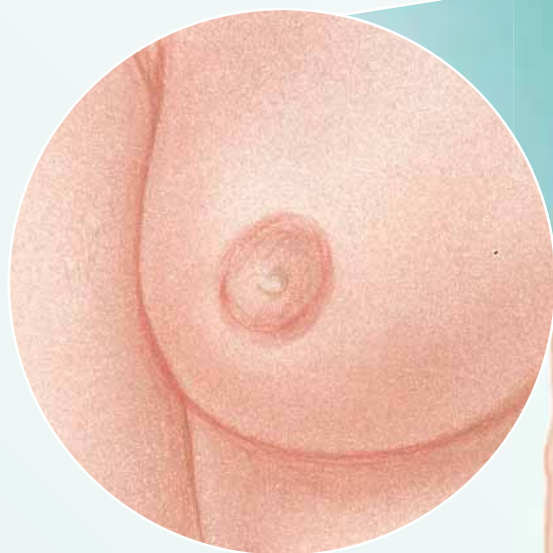Singirniq

Hingirniq

Cheville



# Areola



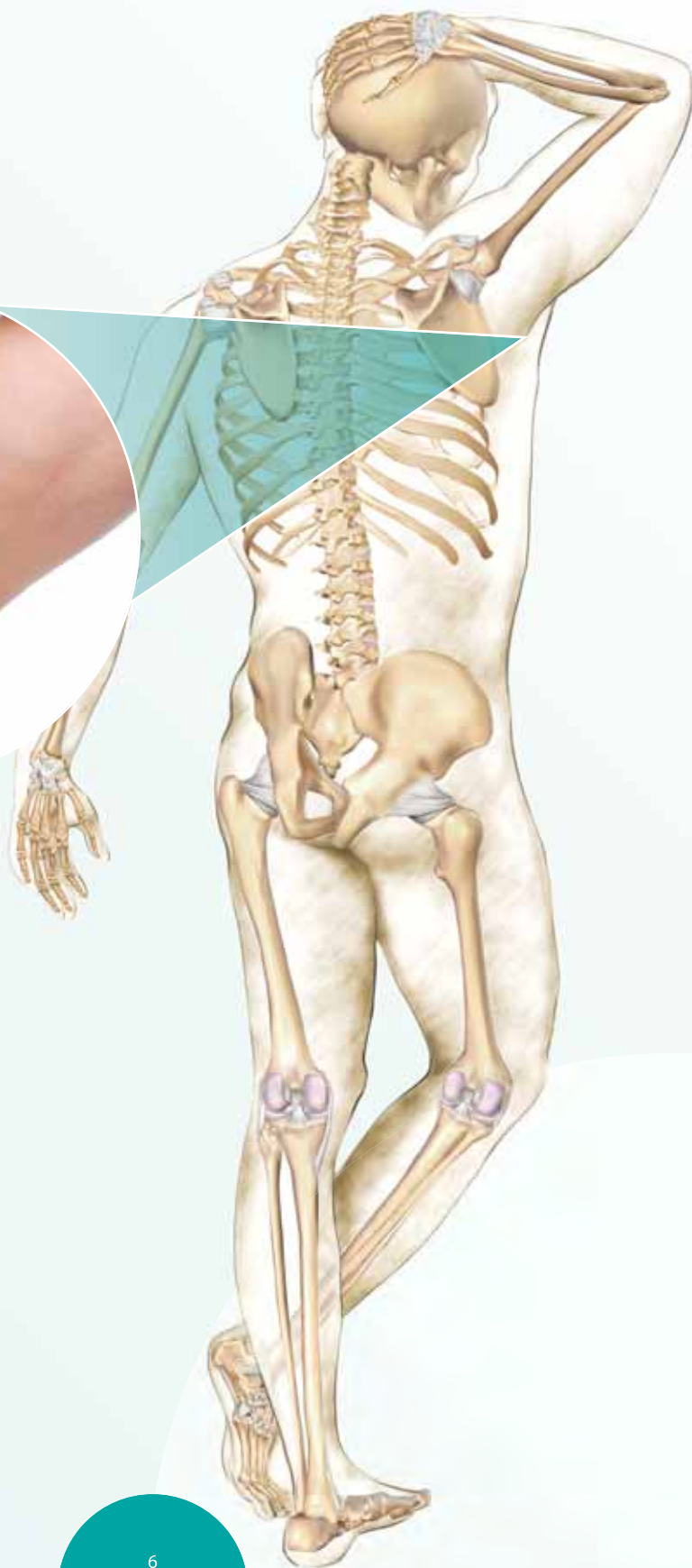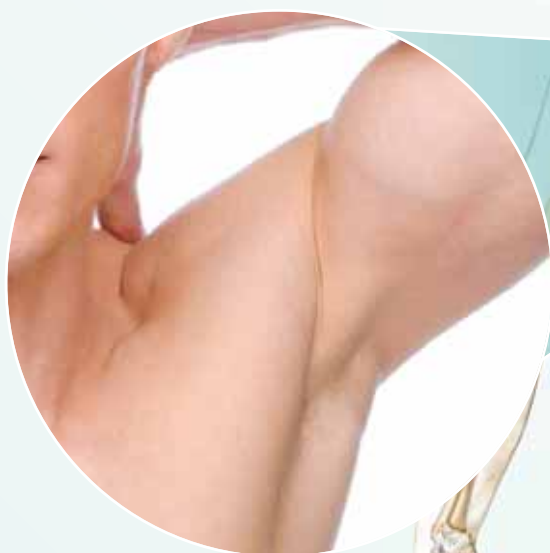ᐱᐱᐱᐱ ᐱᐱᐱᐱᐱᐱᐱᐱ

Muliup Qirnaangananinga

Muluup Avataa

Aréole

# Armpit/ Axilla



▷σ<sup>9b</sup>

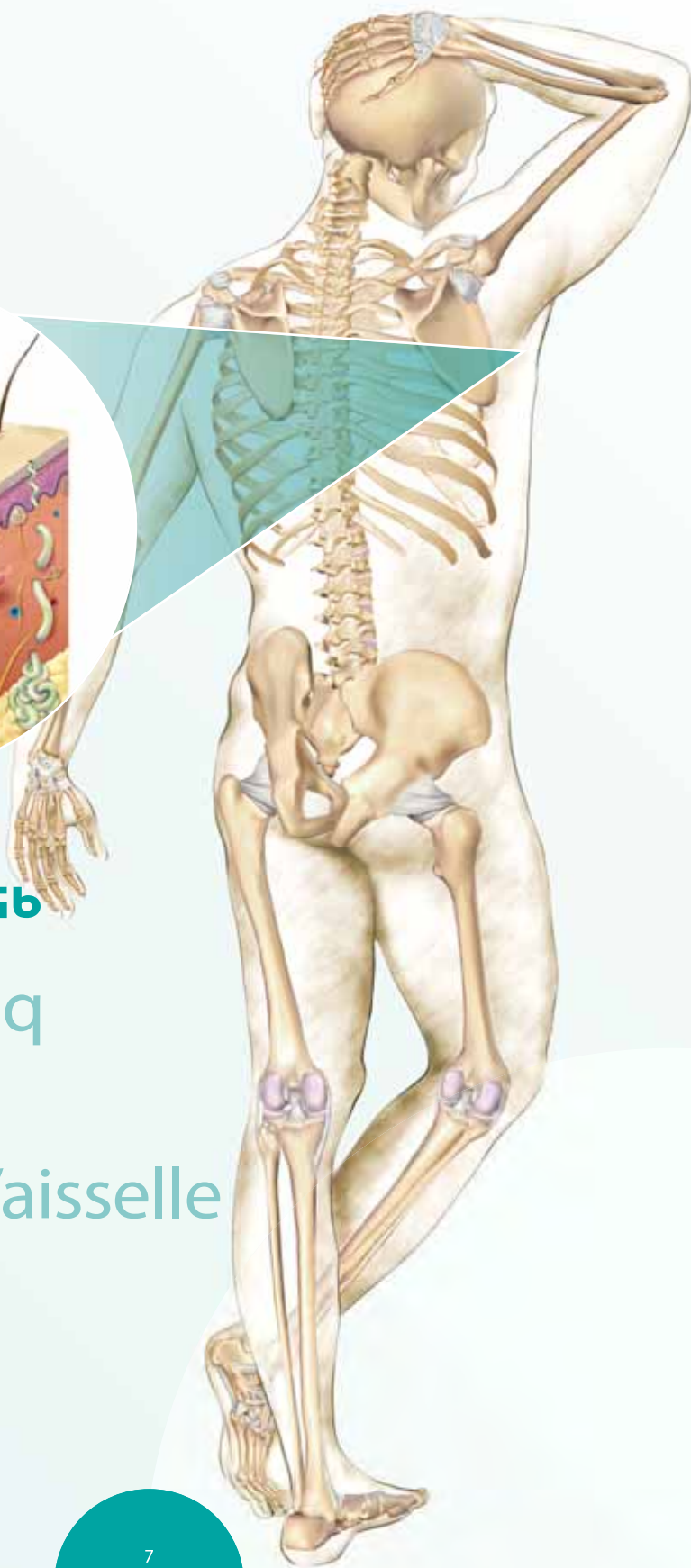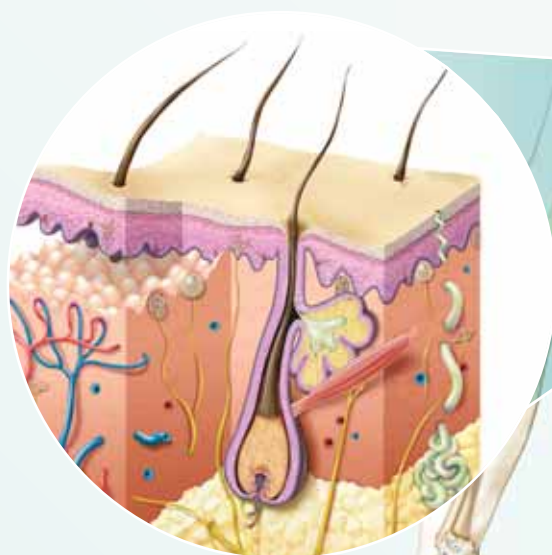
Uniq

Uniq

Aisselle



# Axillary Hair



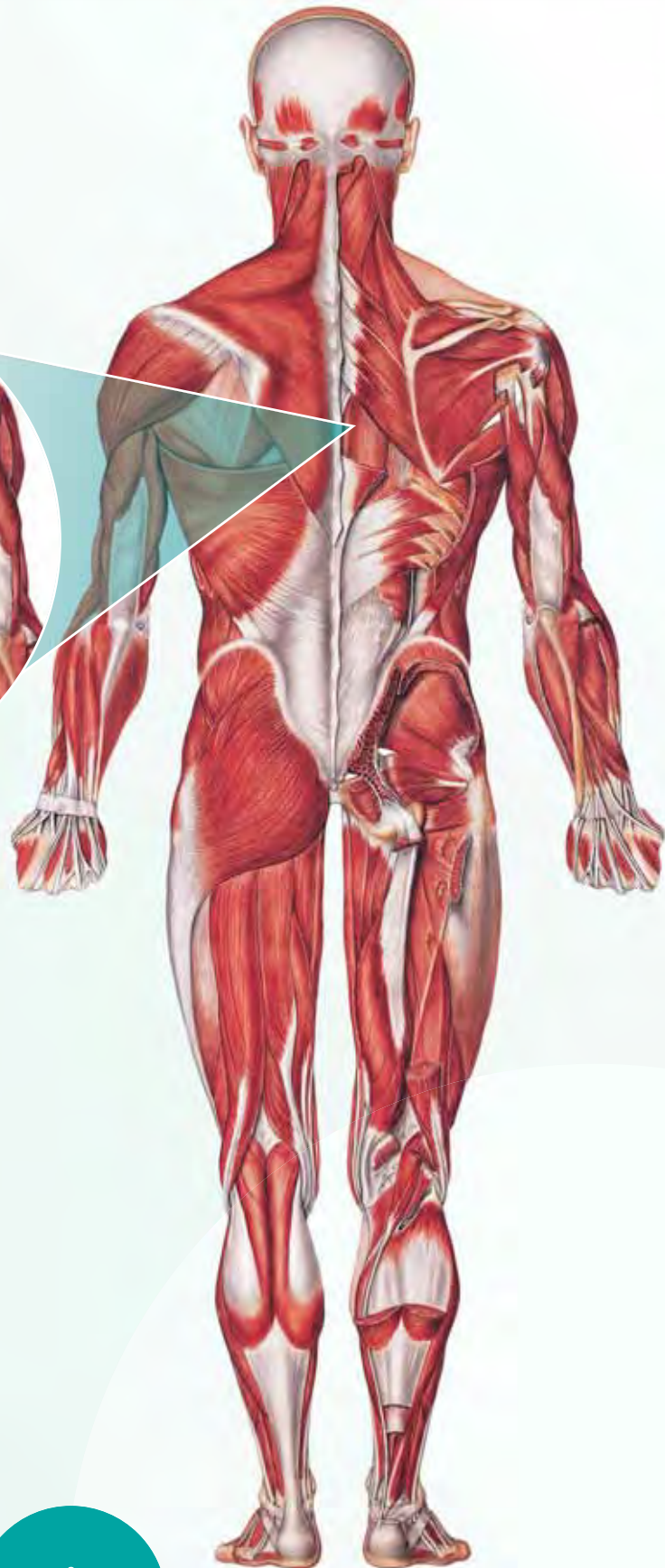
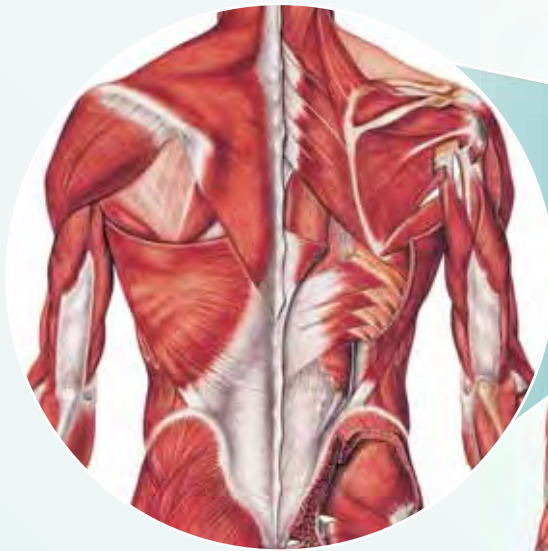▶ ԳՆՐԸԿԻՅԵ

Urngilisaq

Unirutit

Poils de l'aisselle

# Back



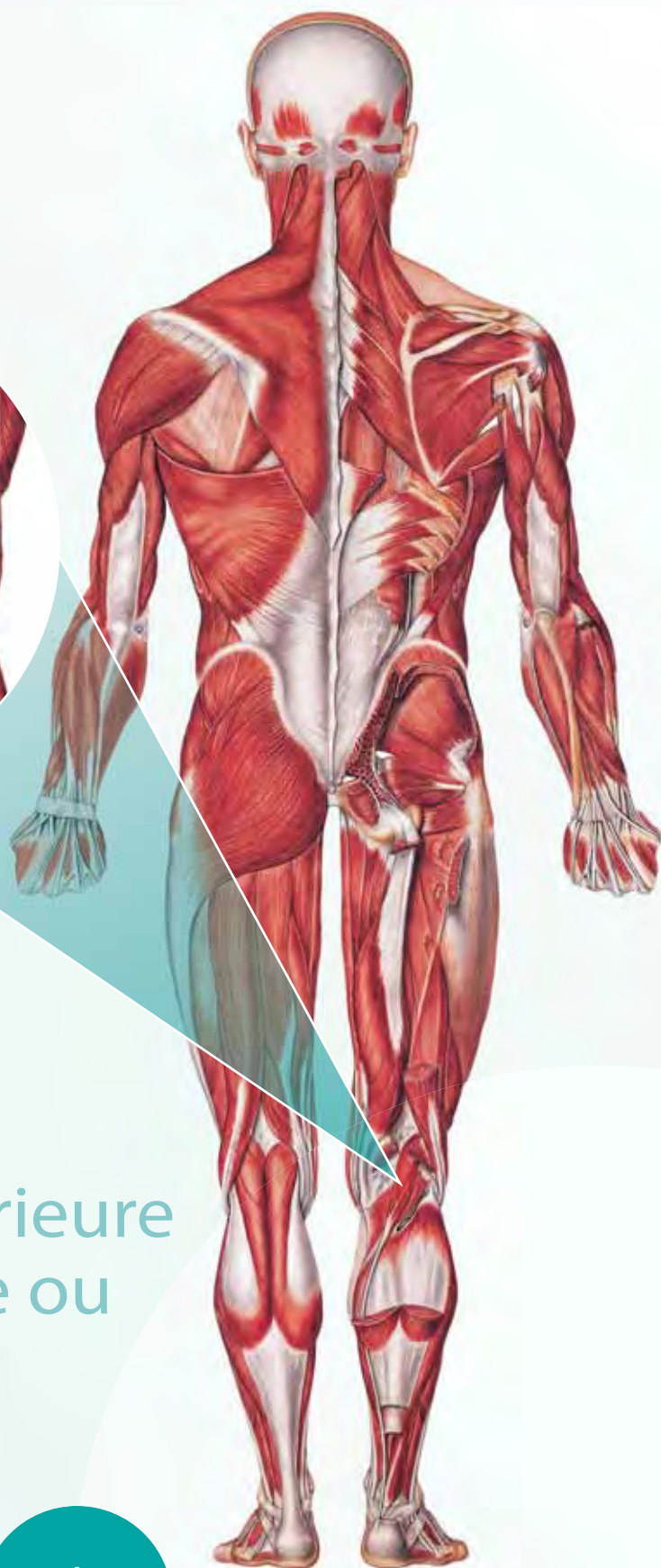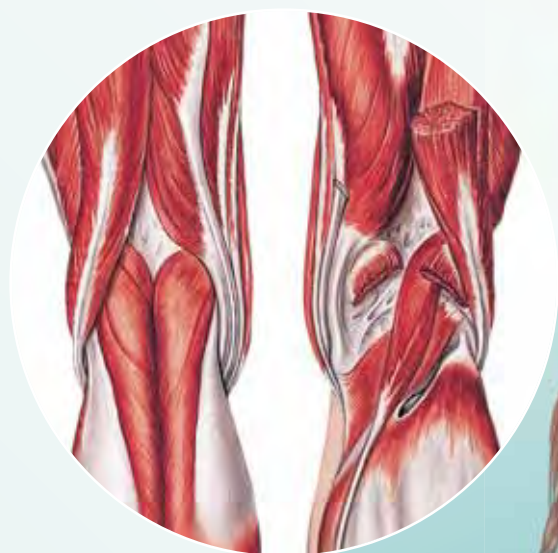
ᐅᐅ

Tunu

Quliik

Dos

# Back of the Knee



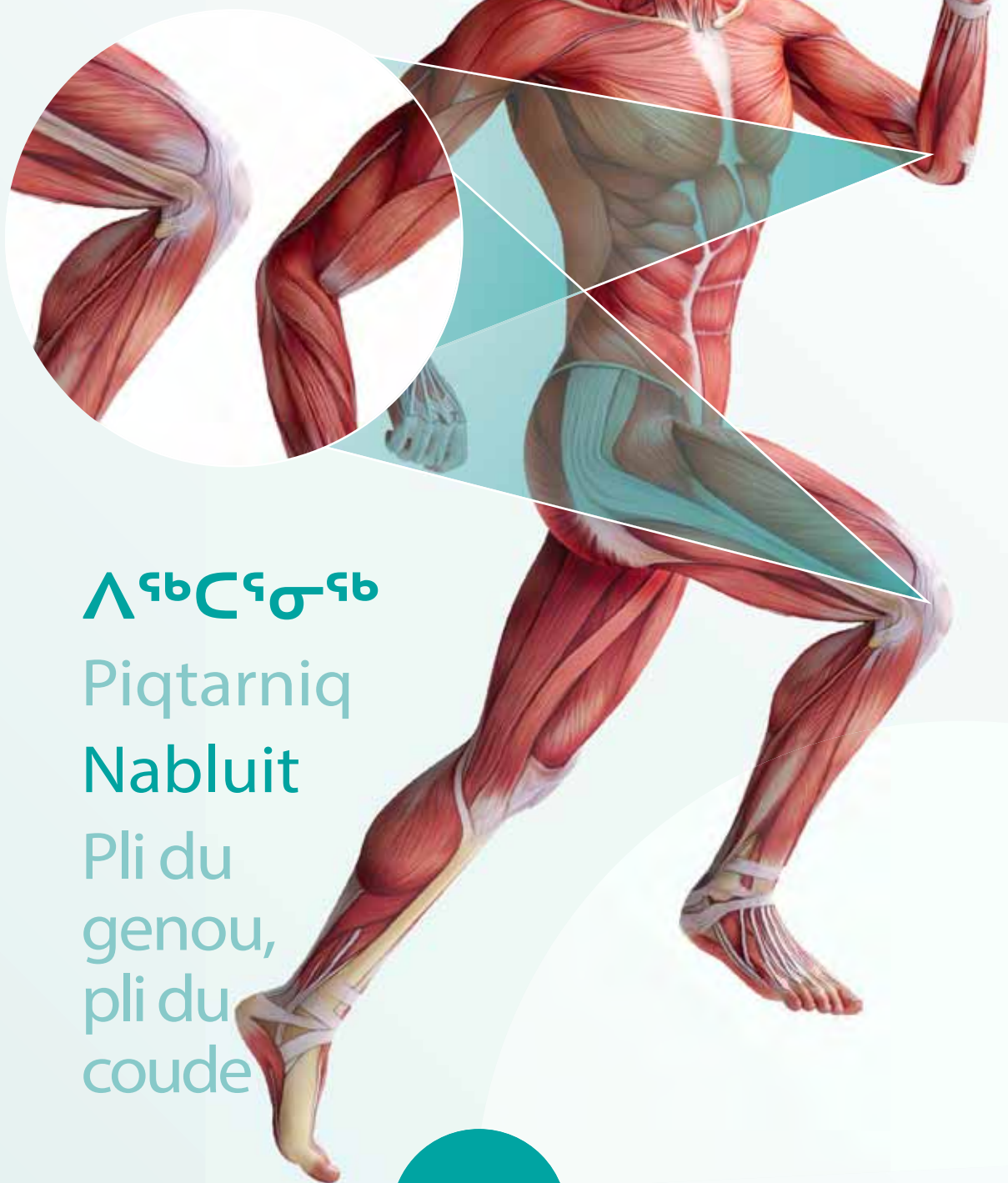ᐱᑦᑲᑦᑲᑦᑲᑦᑲᑦ

Piqtarniq

Kinguraq

Face postérieure  
de la cuisse ou  
du genou

# Bend of the Knee / Bend of the Arm



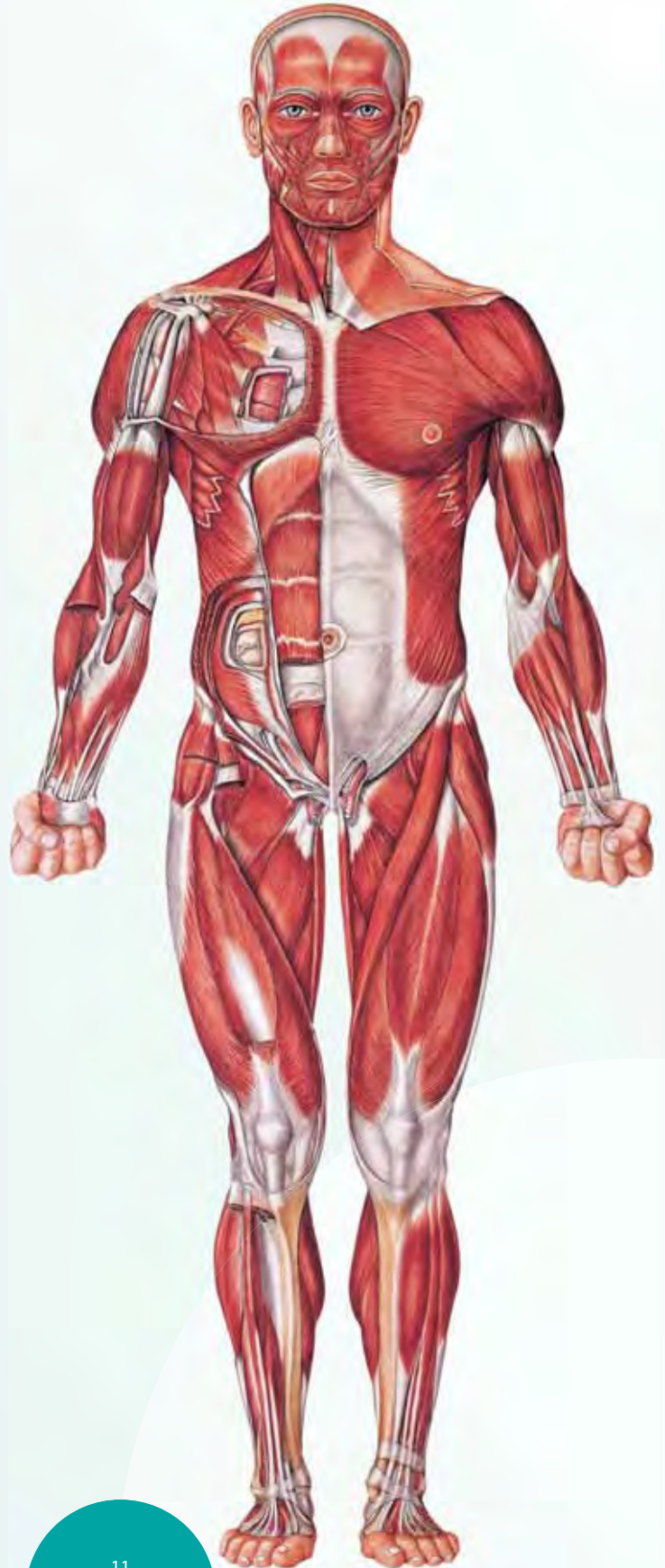Λ ςβ C ςσ ςβ

Piqtarniq

Nabluit

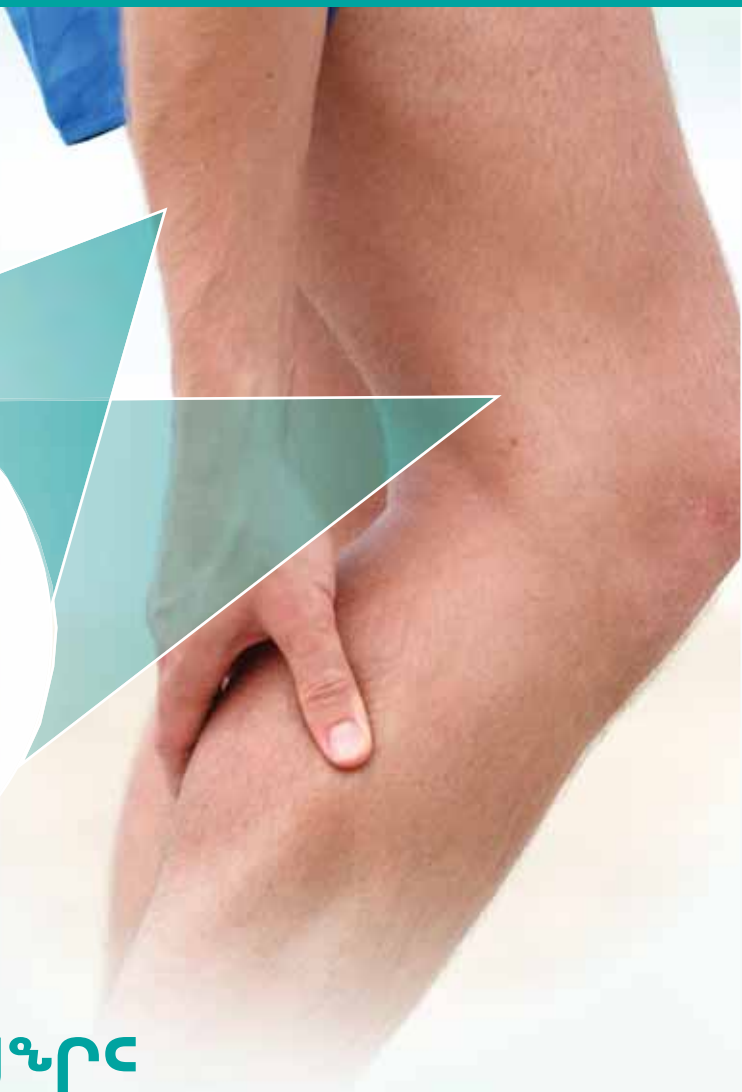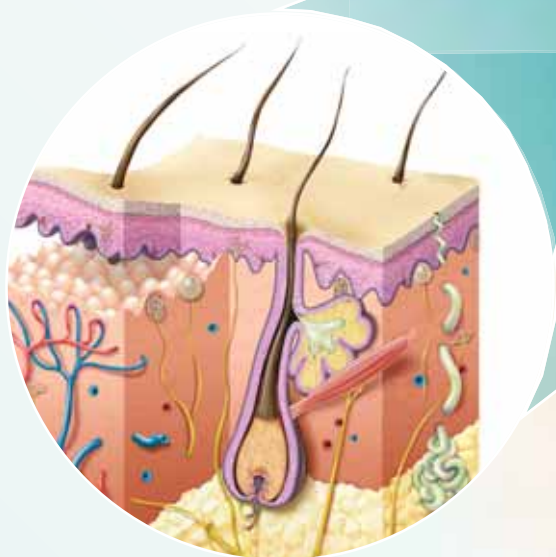
Pli du  
genou,  
pli du  
coude

# Body



nr  
Timi  
Timi  
Corps

# Body Hair



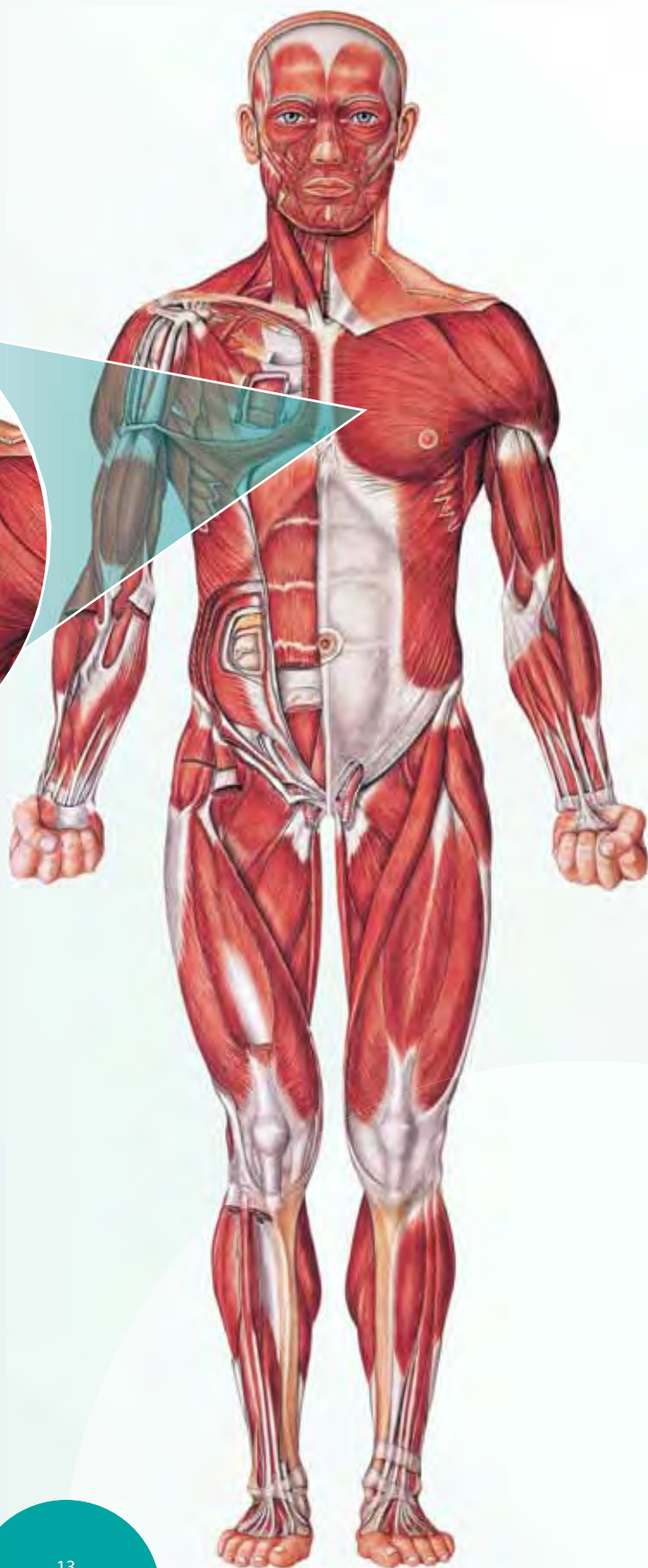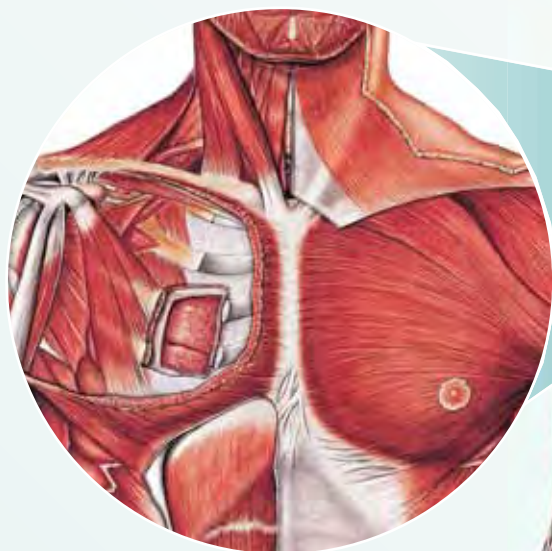
ᑲᑲᑲᑲᑲ ᑲᑲᑲᑲᑲᑲ

Timiup Miqqungit

Timip Mitquit

Poils (à l'exception  
du cuir chevelu)

# Bust



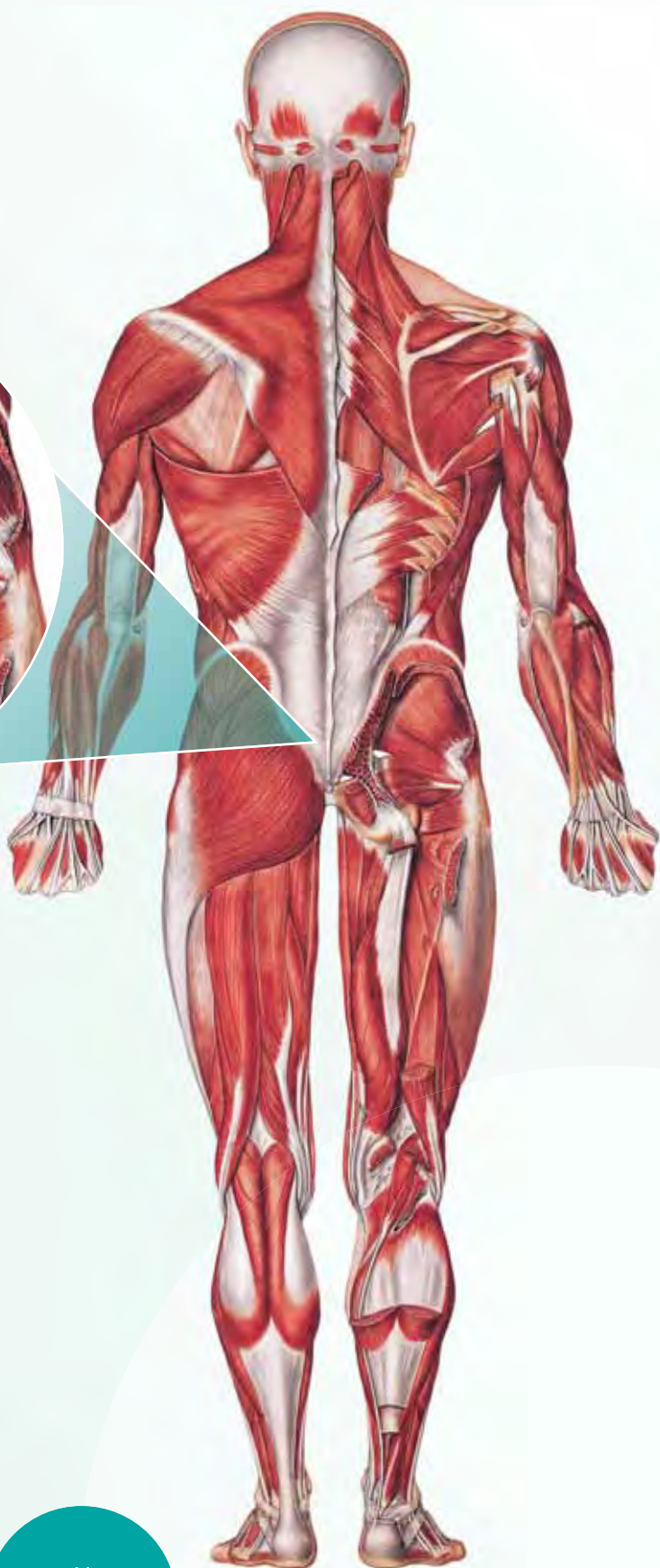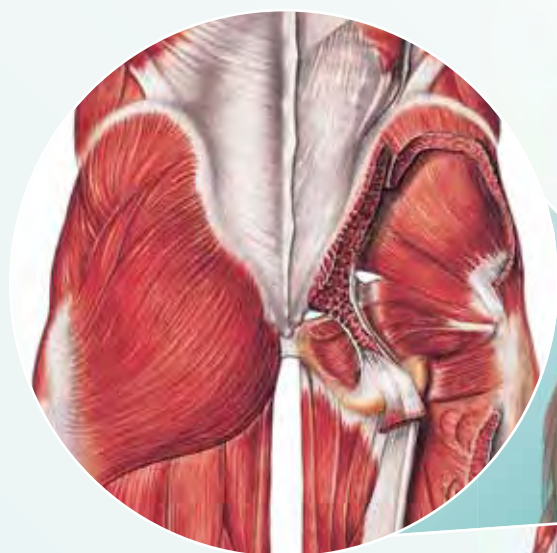
ᄁᆞᆫᆫᆞᆫ

Qatigaak

Qatigak

Buste

# Buttocks



▷◁᠋᠋᠋᠋

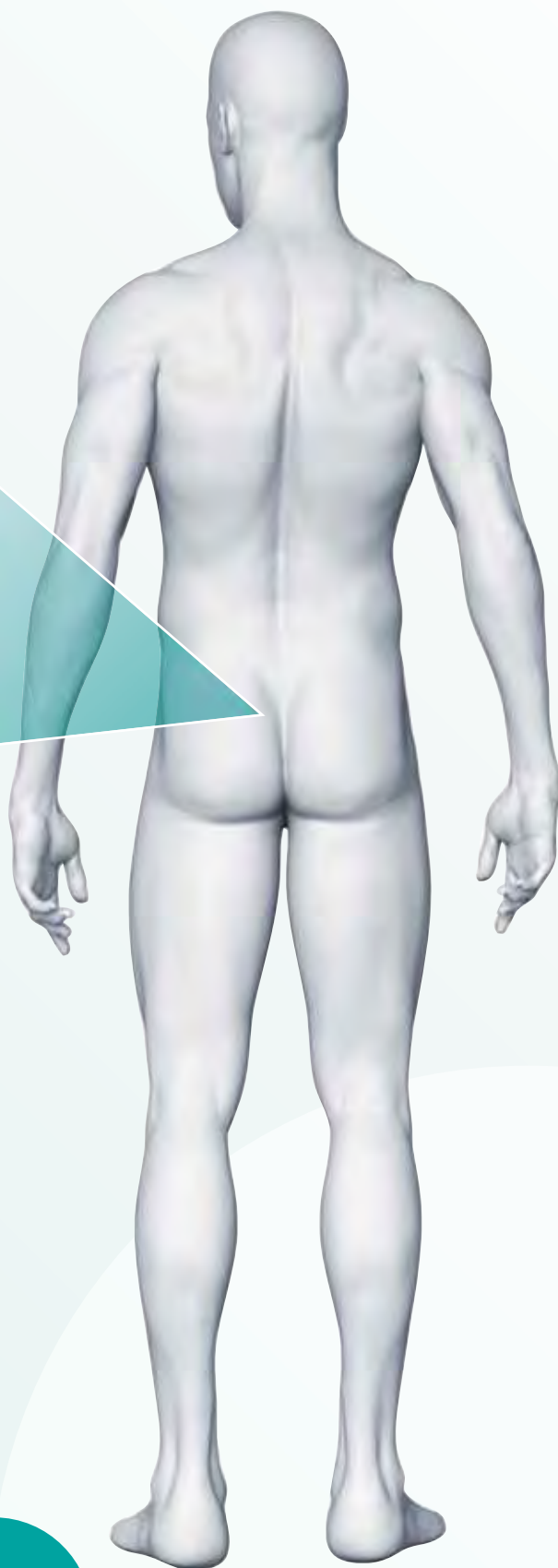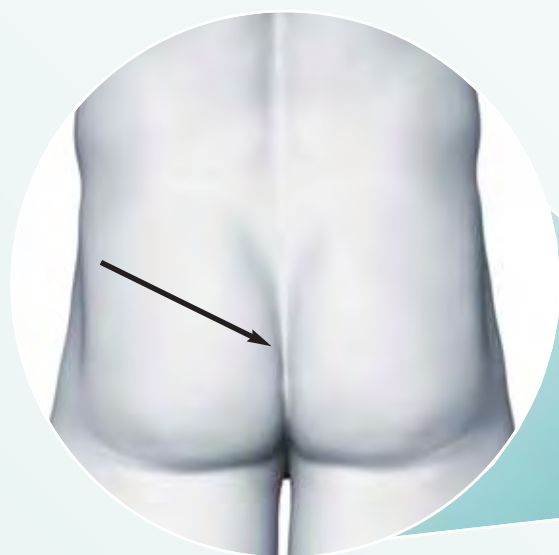Ukpatiik

Nulluk

Fesses



# Cleft of the Buttocks



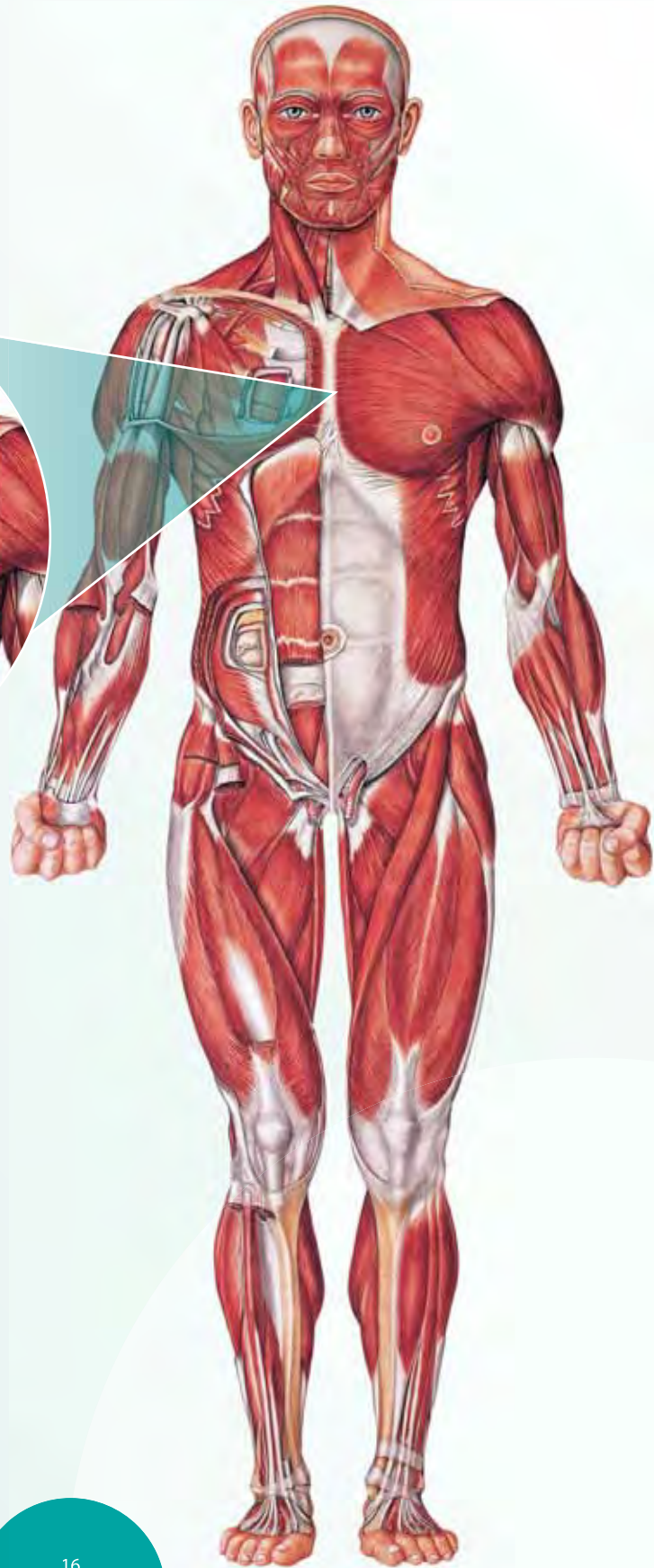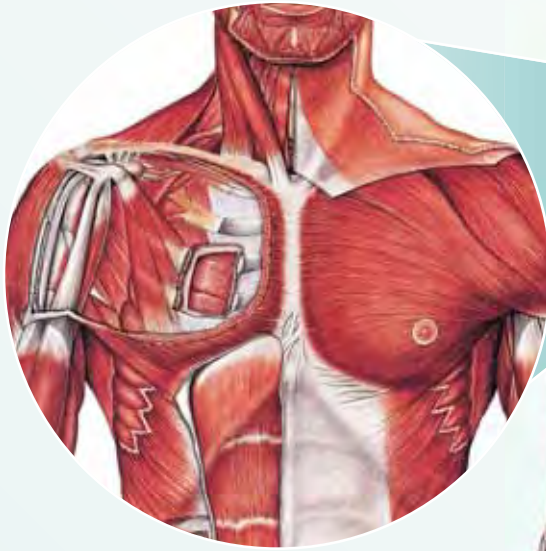
ΔΠΨΑΨ<sup>b</sup>

Itirviluk

Itirviluk

Raie des  
fesses

# Chest



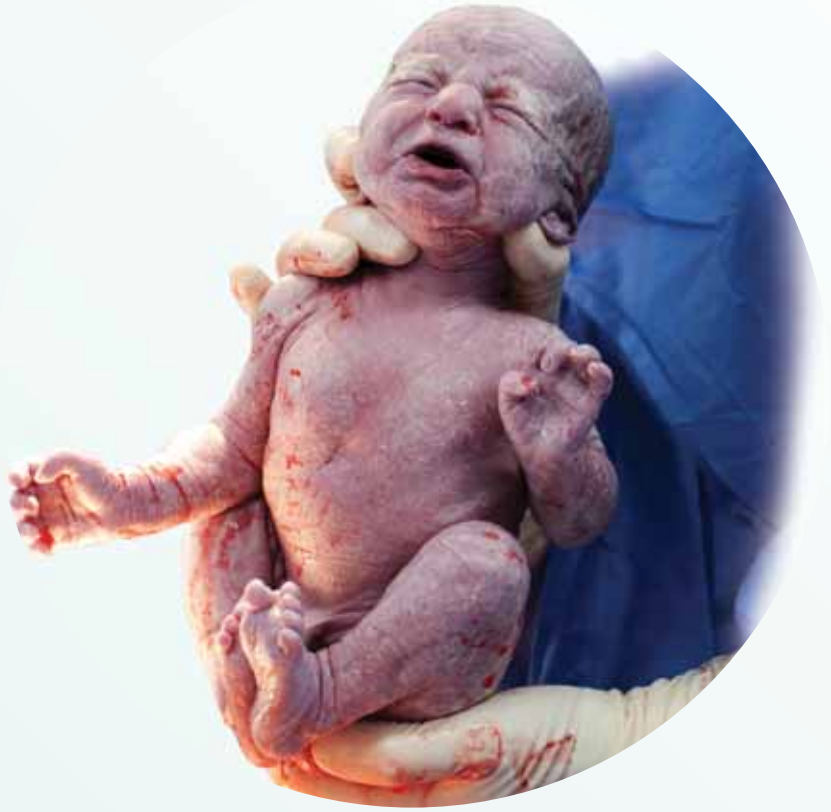ԿՆՃԵ

Sagvik

Hatqak

Poitrine

# Cyanosis



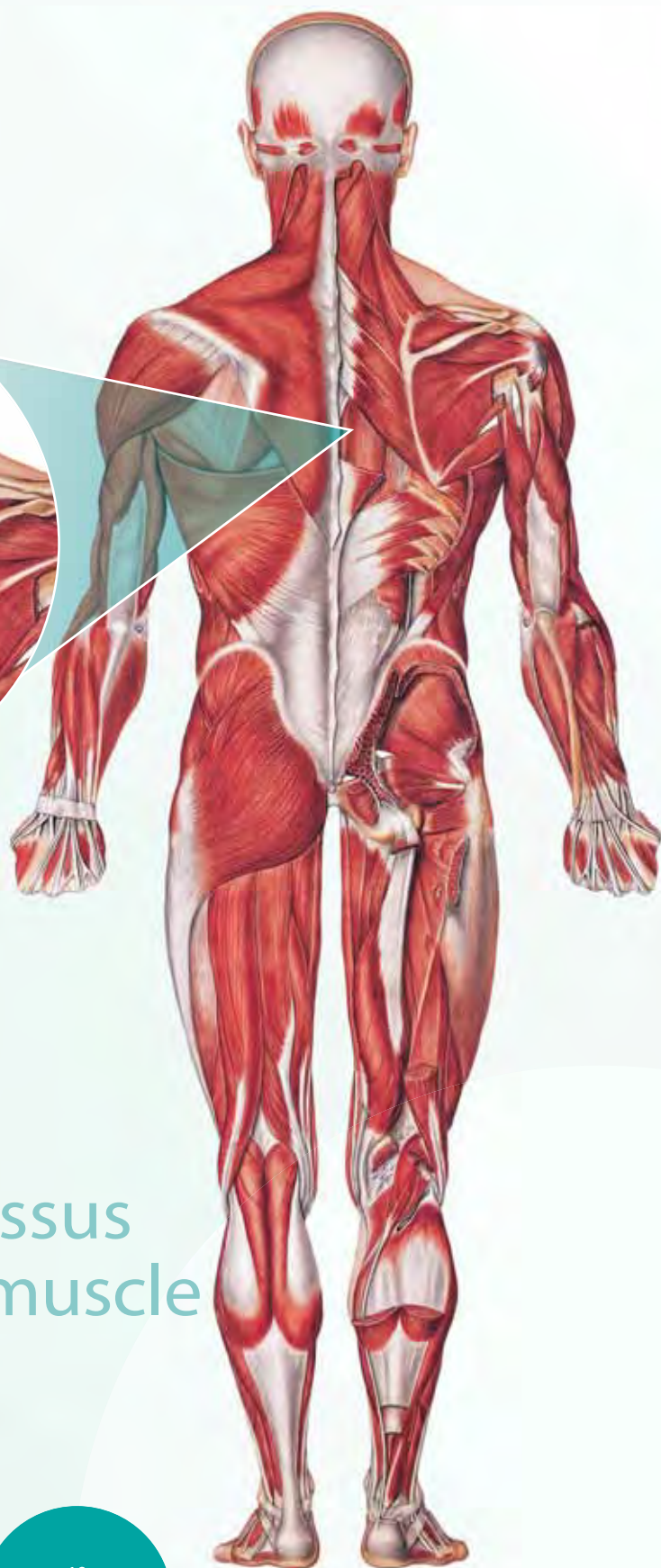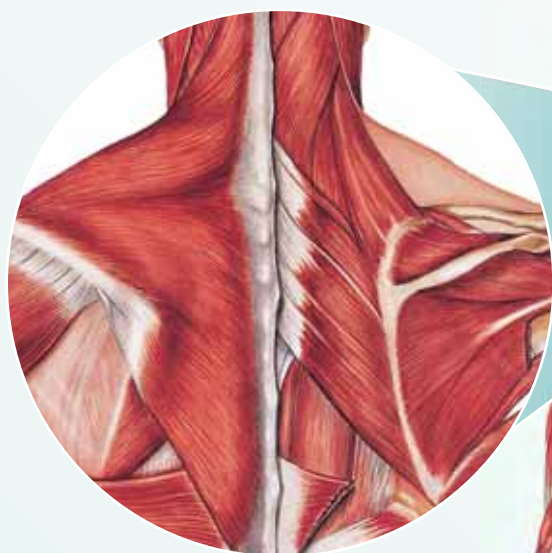
ᑕᑦᑕᑦᑕᑦᑕᑦᑕᑦ

Tunguaqtittuq

Tunguqtittuq

(qui a des) Cernes

# Dorsal Region



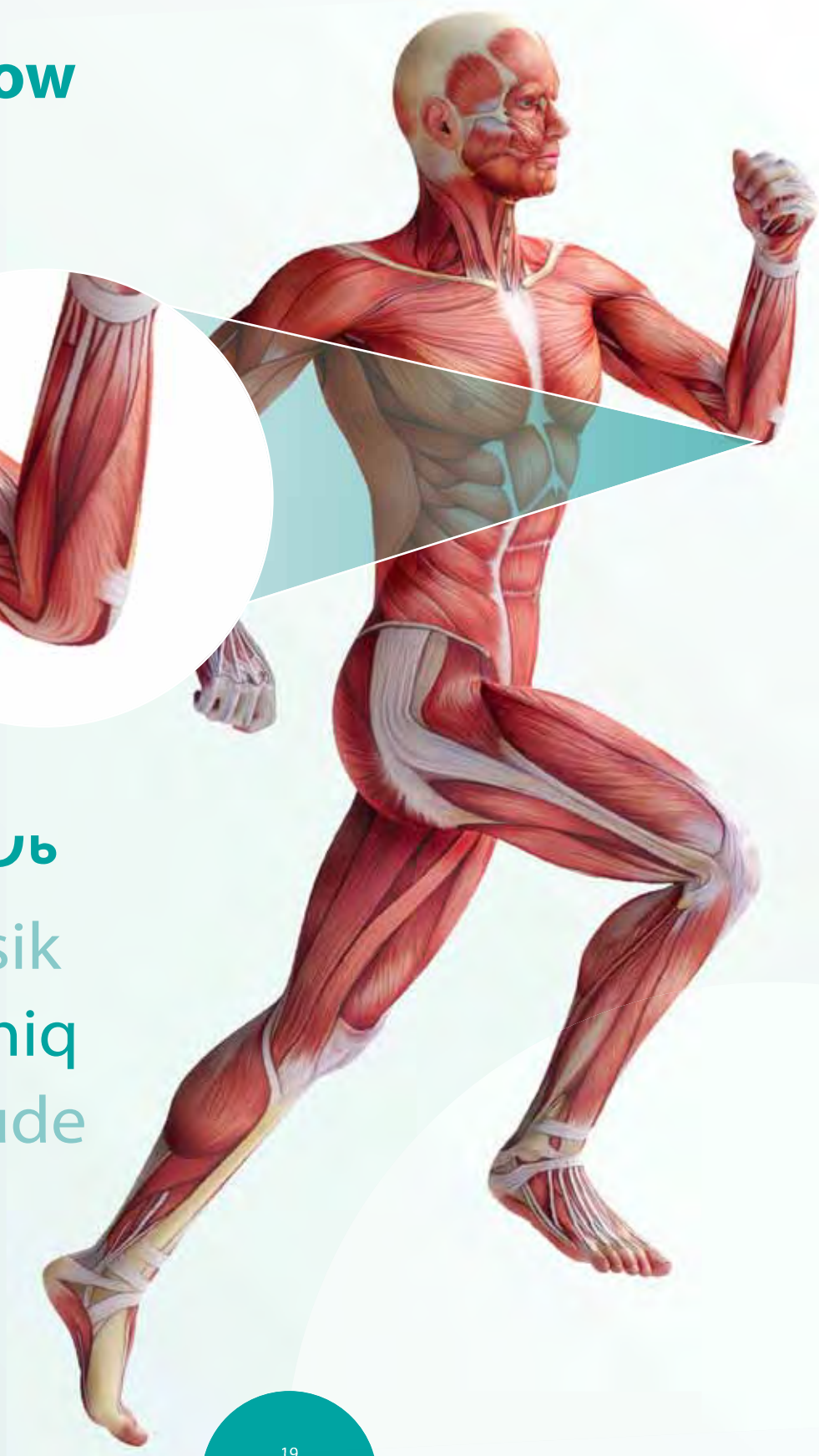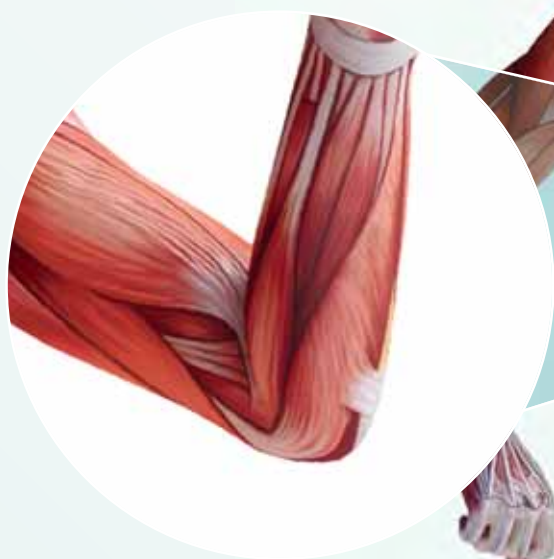قۇلىك

Quliik

Quliik

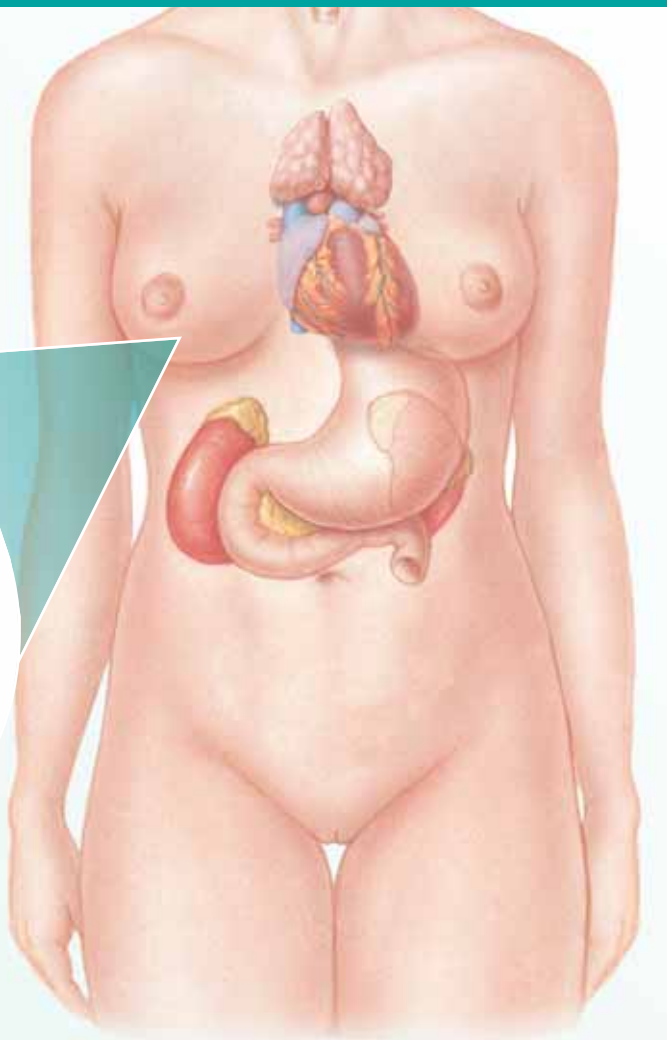
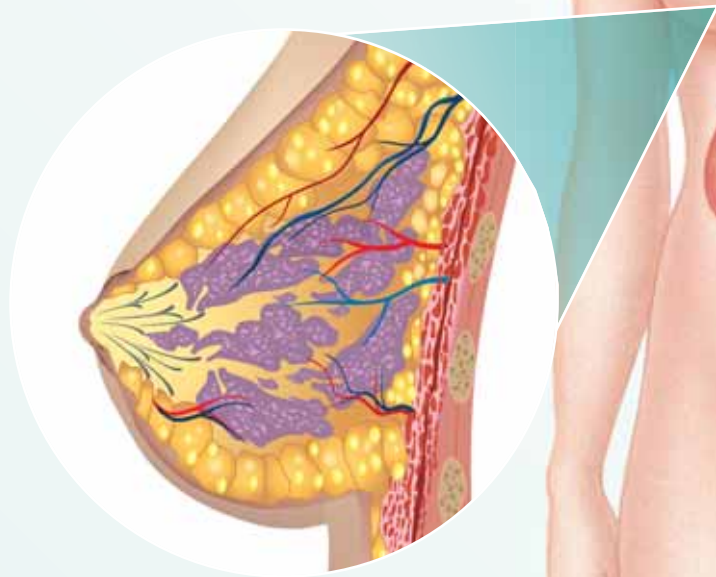
Dos (au-dessus  
des reins), muscle  
trapèze

# Elbow



ΔdP<sup>b</sup>  
Ikusik  
Ikuhiq  
Coude

# Female Breast



ΔΔΔΔΔΔ

Iviangiq

Iviangiq

Sein féminin

# Freckle



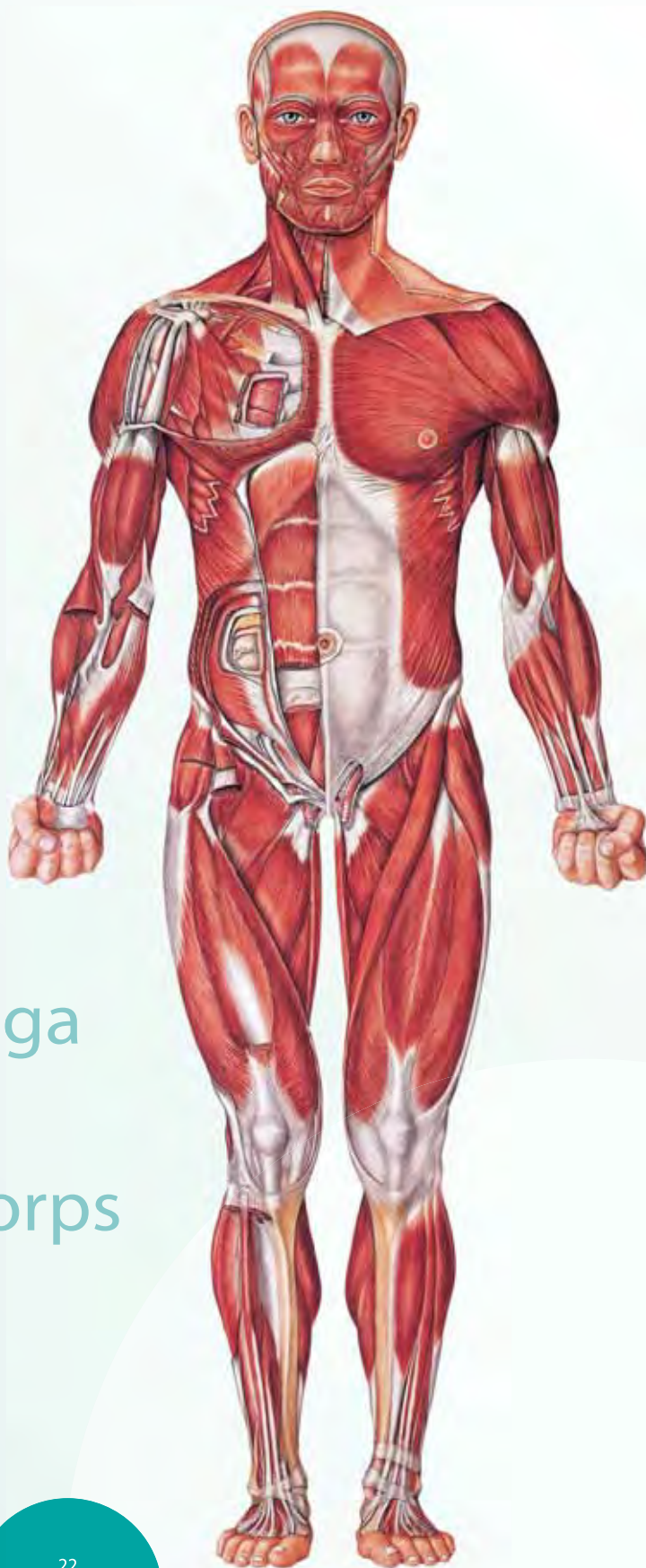ᑃᑃᑦᑲᑦ

Kukuvait

Kukuvalaaq

Grain de beauté,  
tache de son

# Front of the Body



ᐃᓂᓂ ᐱᓂᓂ

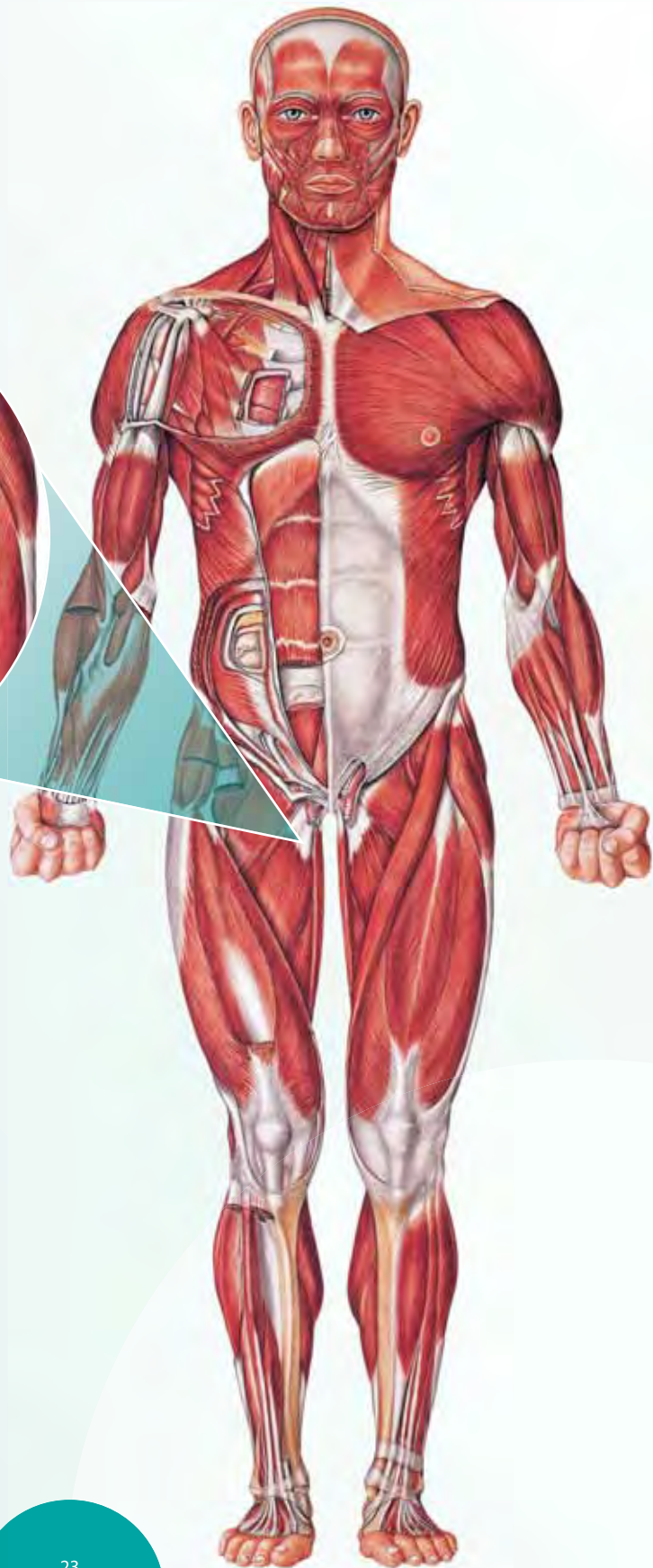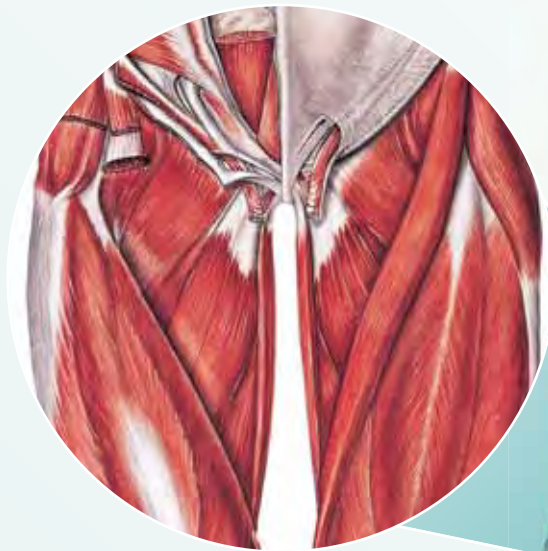
Inuup Saanga

Hatqaq

Avant du corps



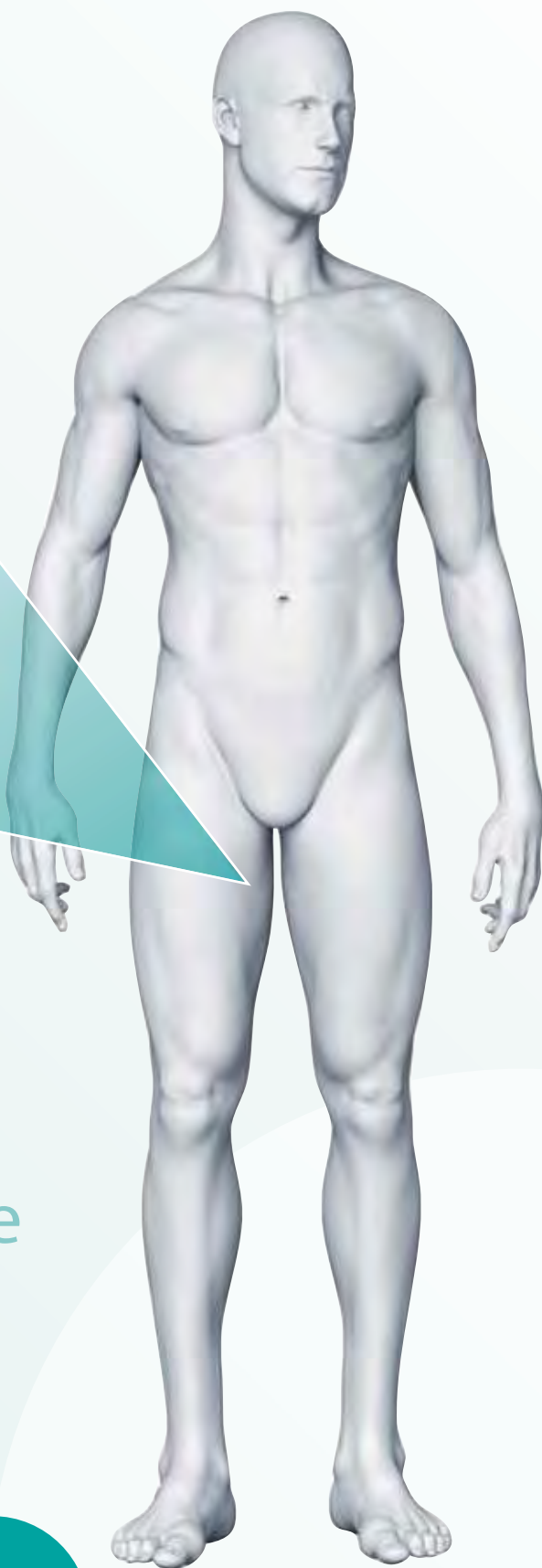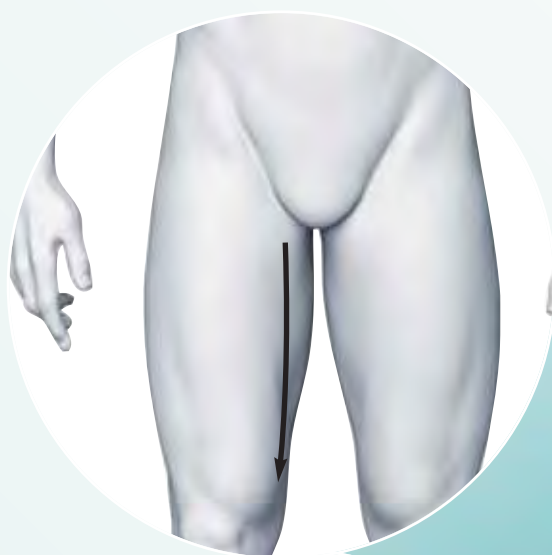# Groin



ᐱᐃᐅᐅᐅ

Akunnaak  
Imitqutak  
Aine

# Inside of the Thigh



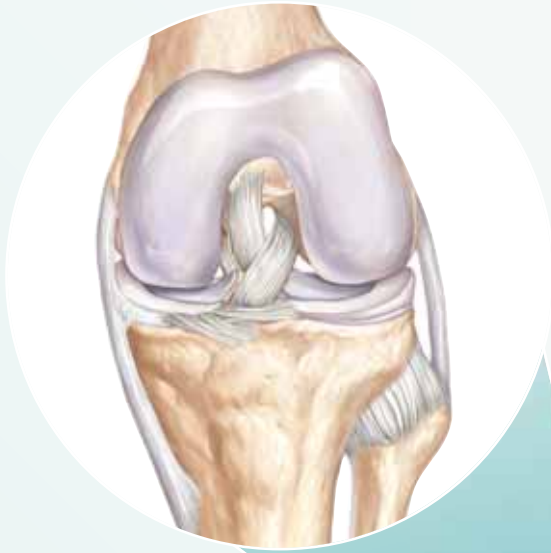Δϯϯ<sup>6</sup>

Ilutaak

Ilutak

Partie médiale  
de la cuisse

# Knee

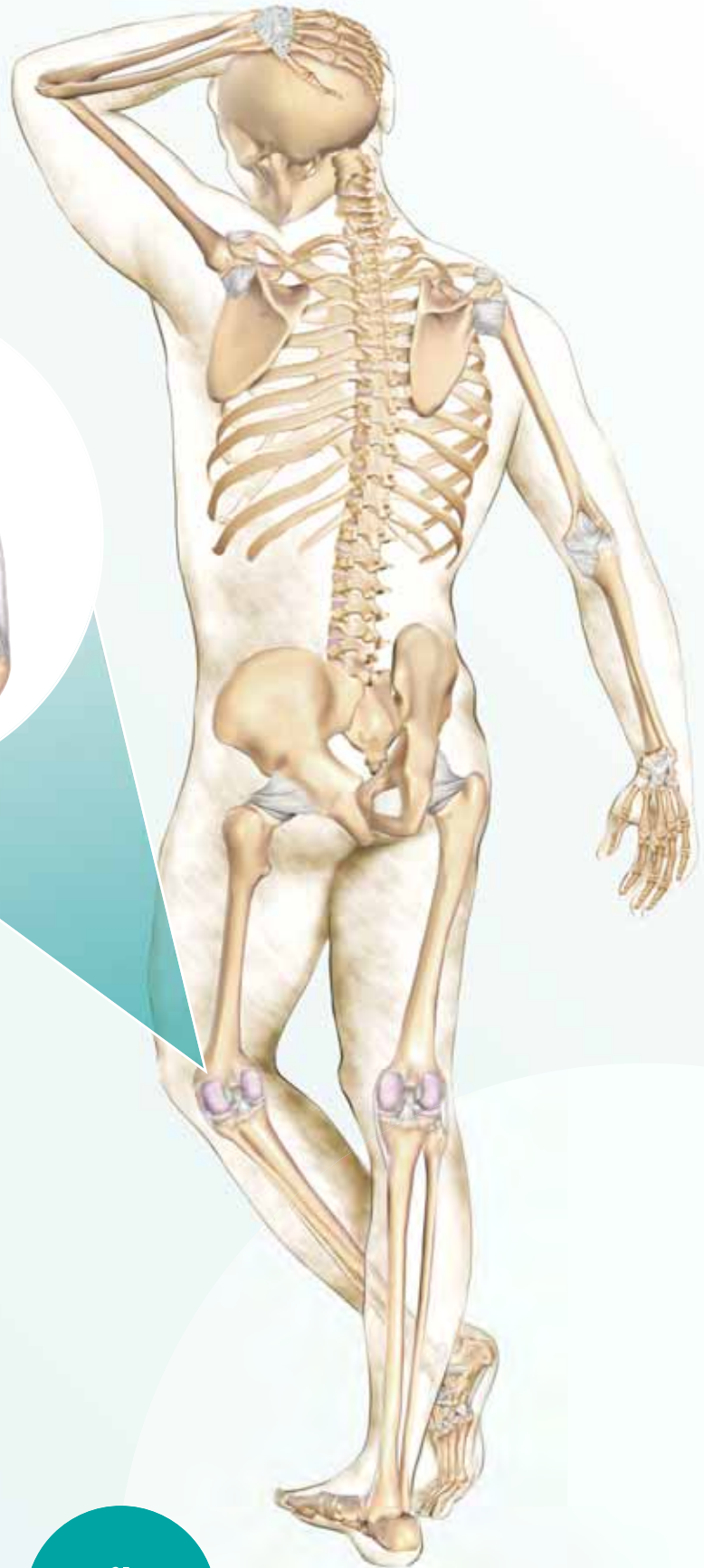

ᐱᐅᐅᐅᐅ

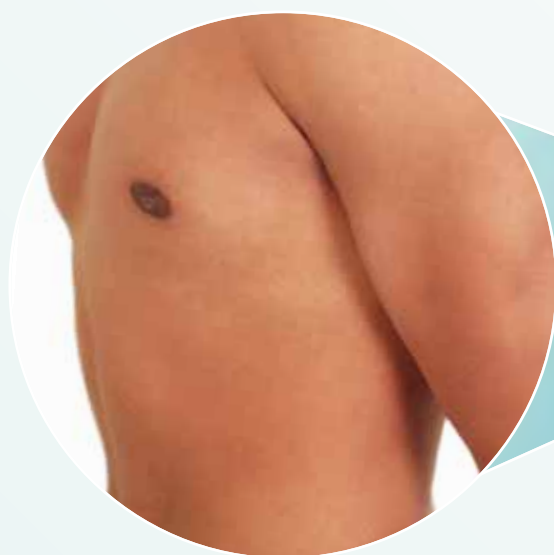Siiqquq

Hiitquq

Genou



# Lateral Side of the Chest



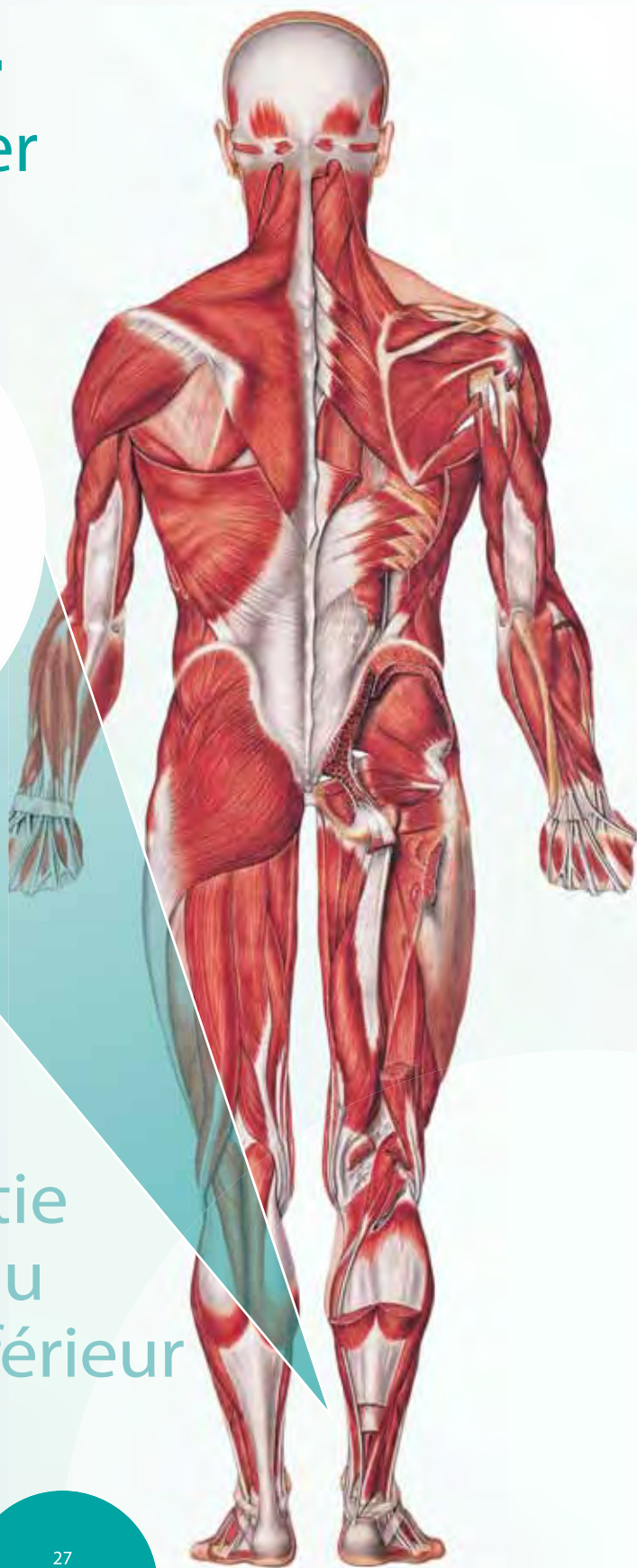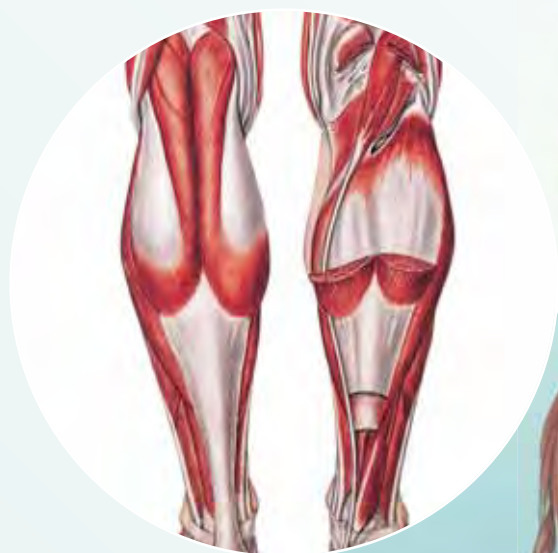ካሪናቅ

Saniraq

Haniqhuk

Partie latérale  
du buste

# Leg / Lower part of Lower Limb



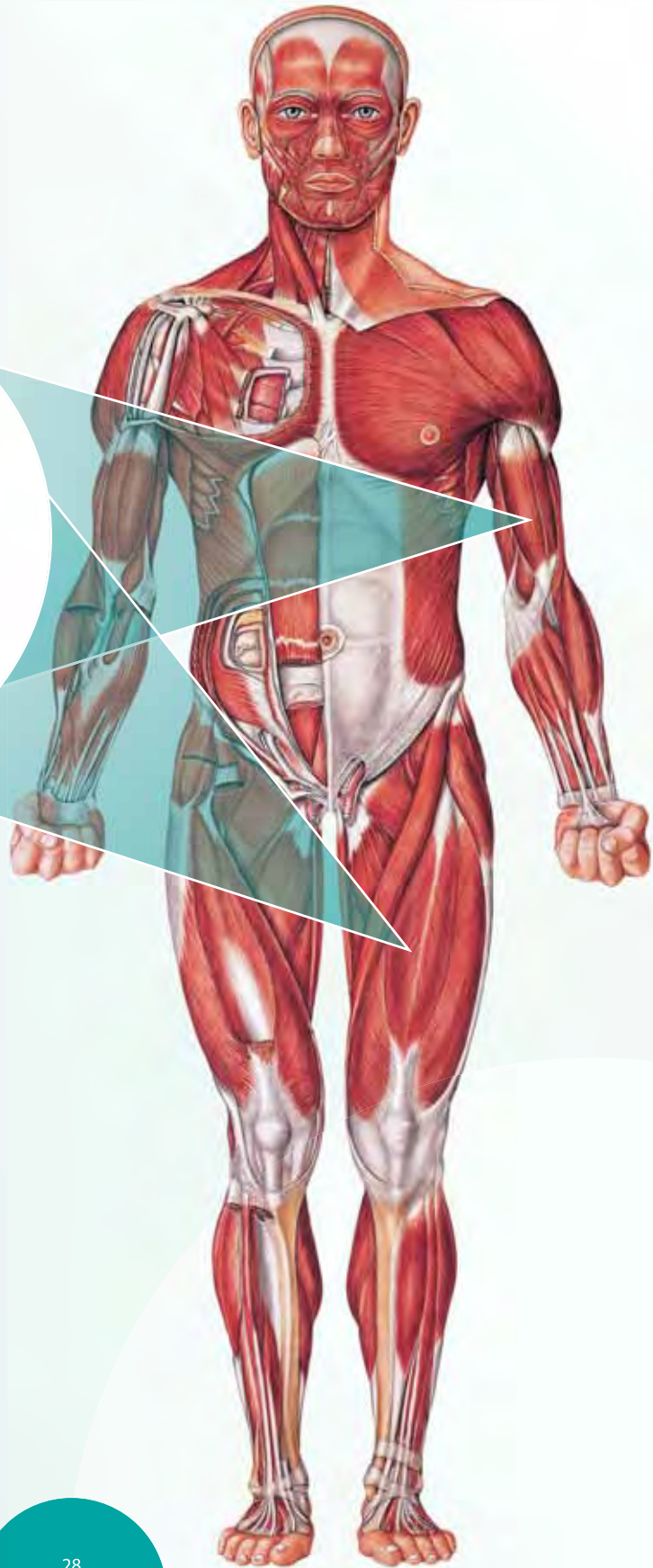
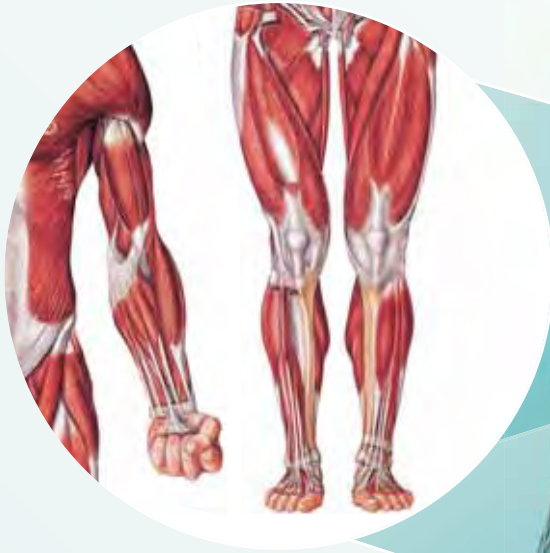ᑲᑲᑦᑲ

Kanaaq

Atiraq

Jambe, partie  
inférieure du  
membre inférieur

# Limbs



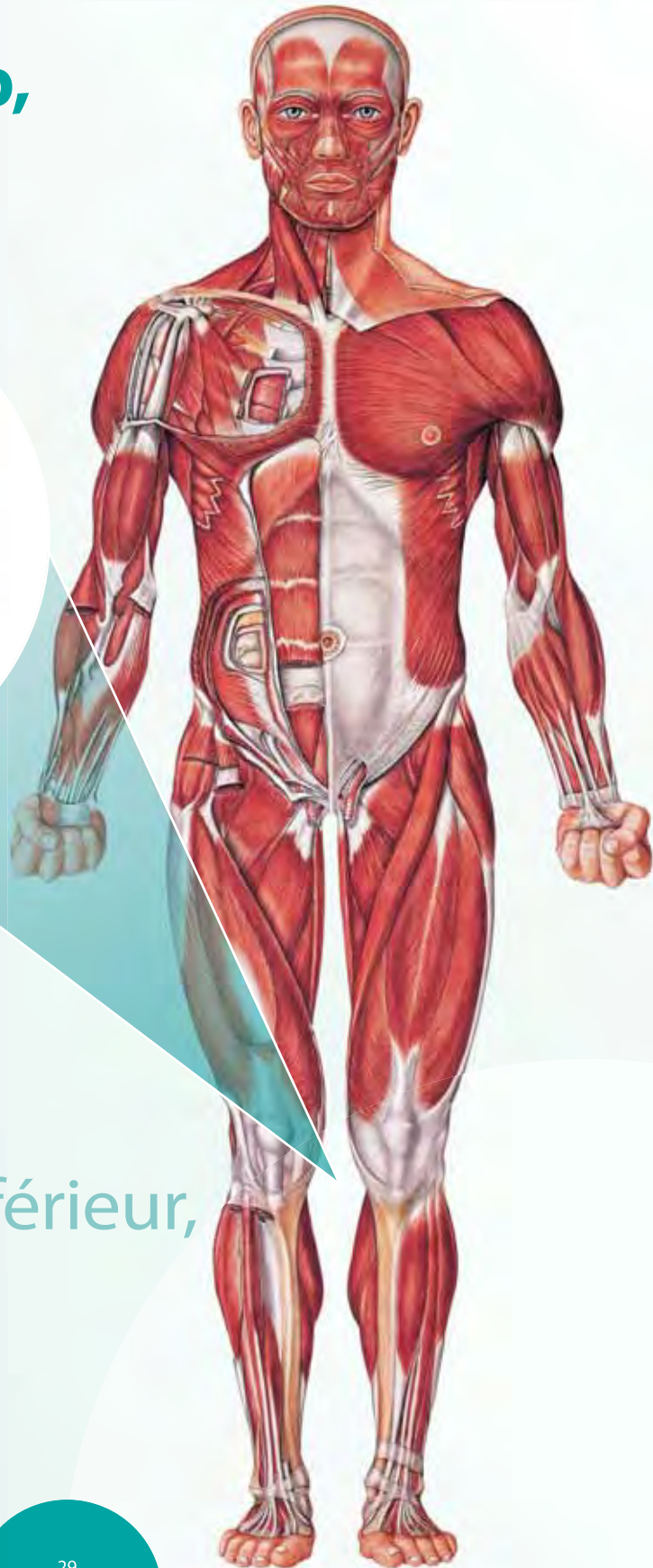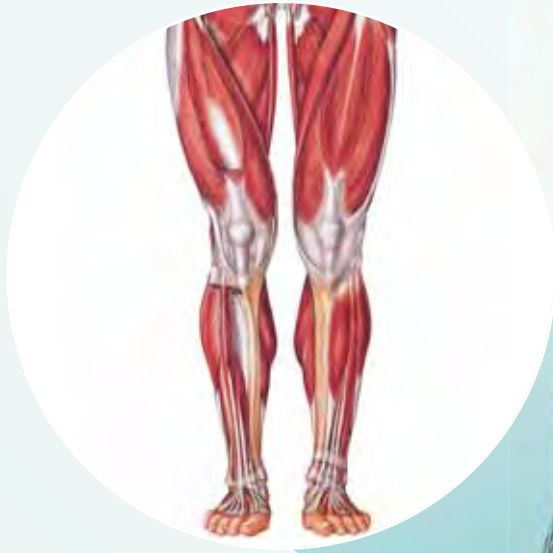ᐱᐱᐱᐱ

Avatit

Avatit

Membres

# Lower Limb, Leg



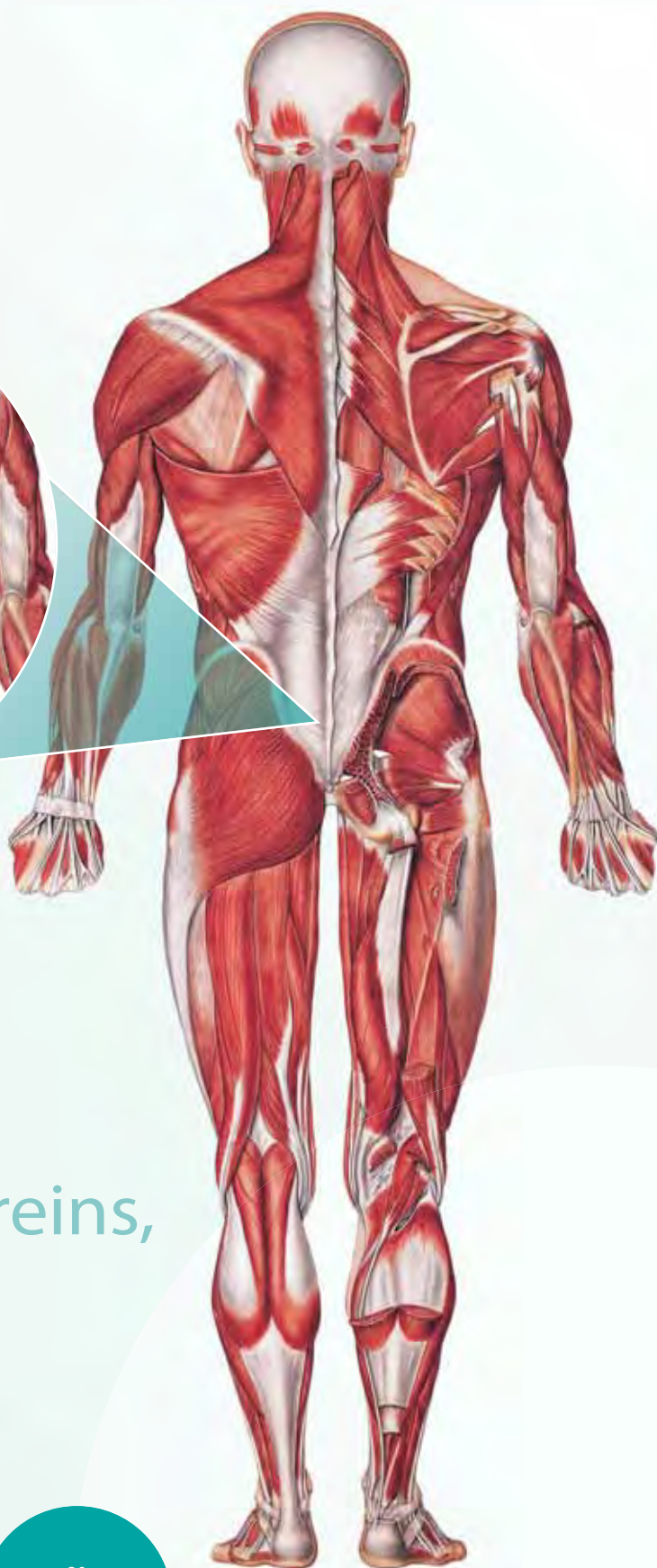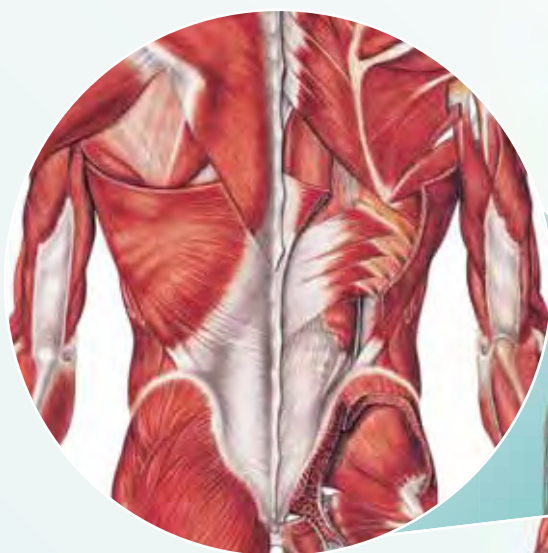♂▷

Niu

Atiraq

Membre inférieur,  
jambe

# Lower Lumbar



ᄁᄁᄁᄁ

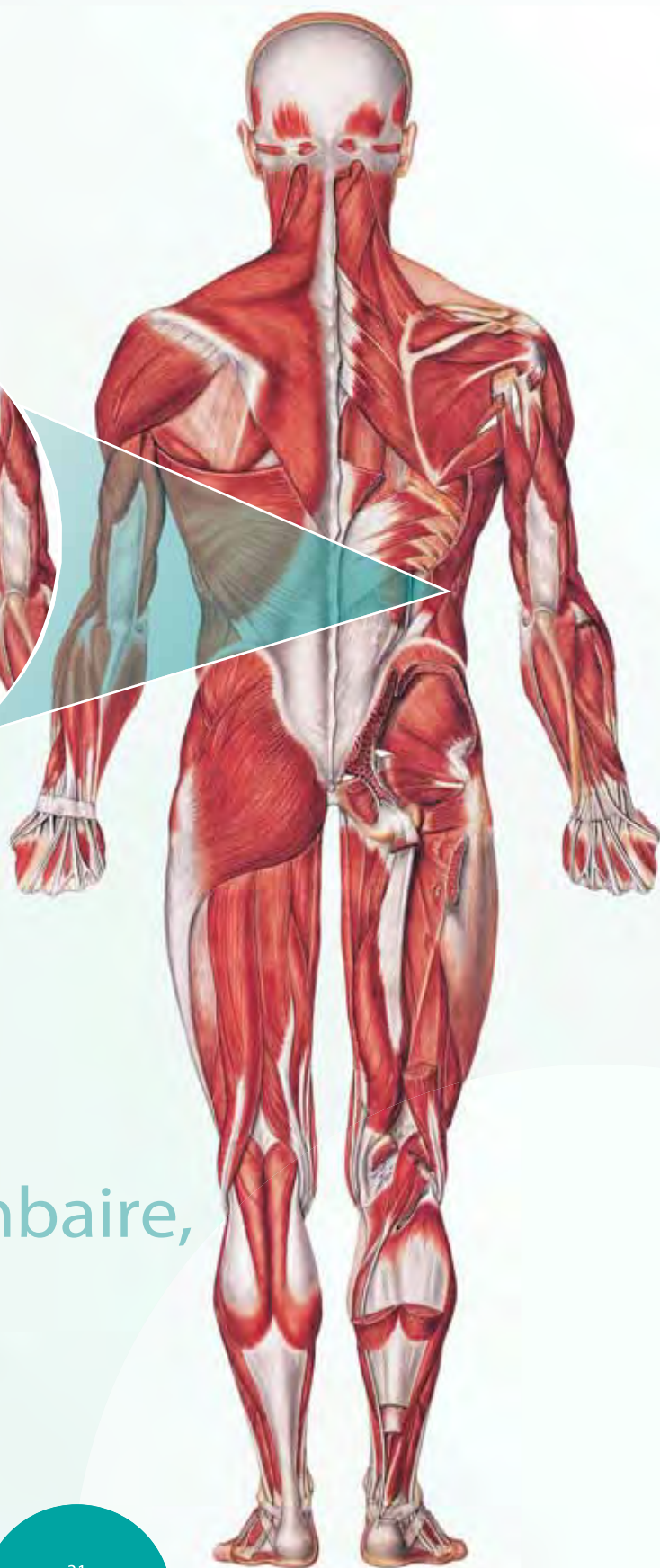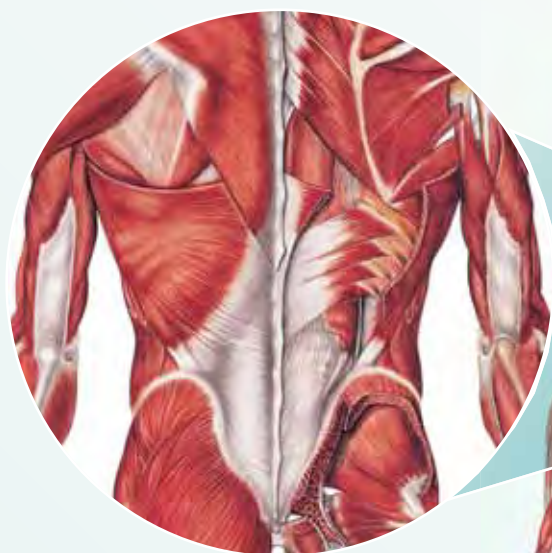Qitiq

Qitiq

Chute des reins,  
taille



# Lumbar Region



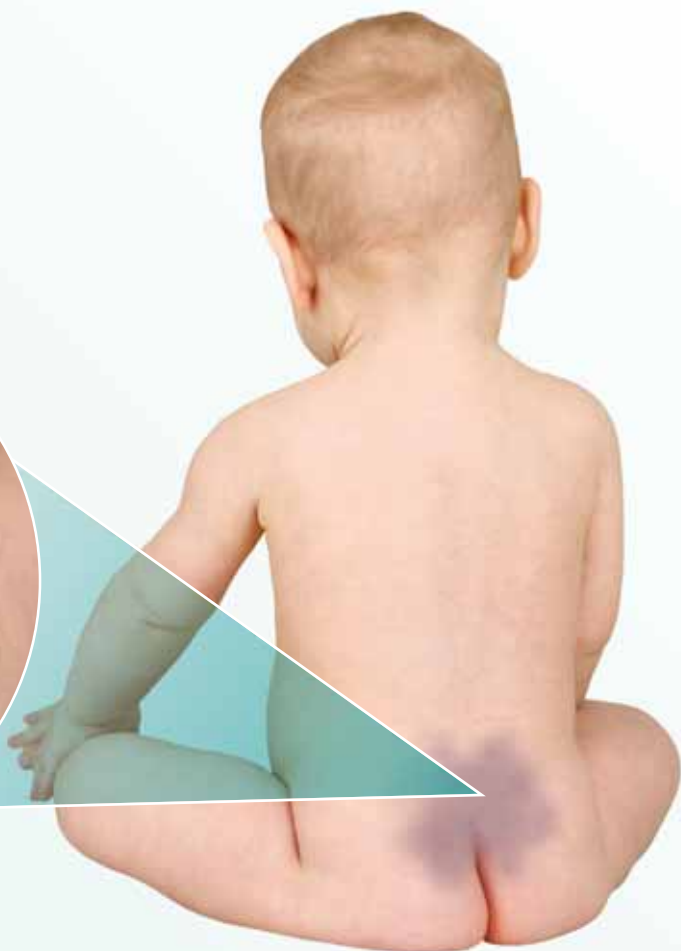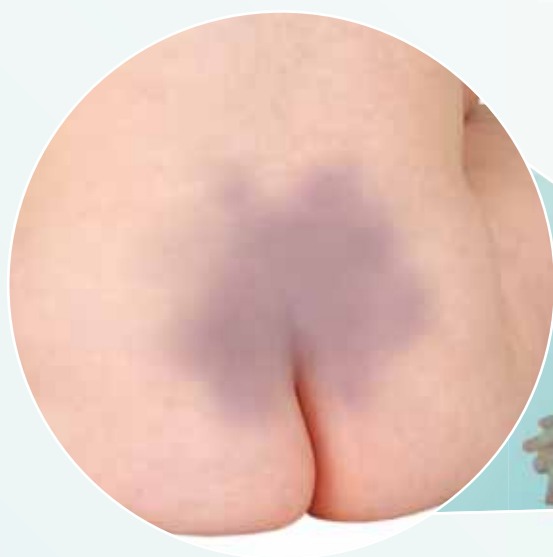ԺԿՈՏԳԵ

Kuttiniq

Kuuttiniq

Région lombaire,  
lombes

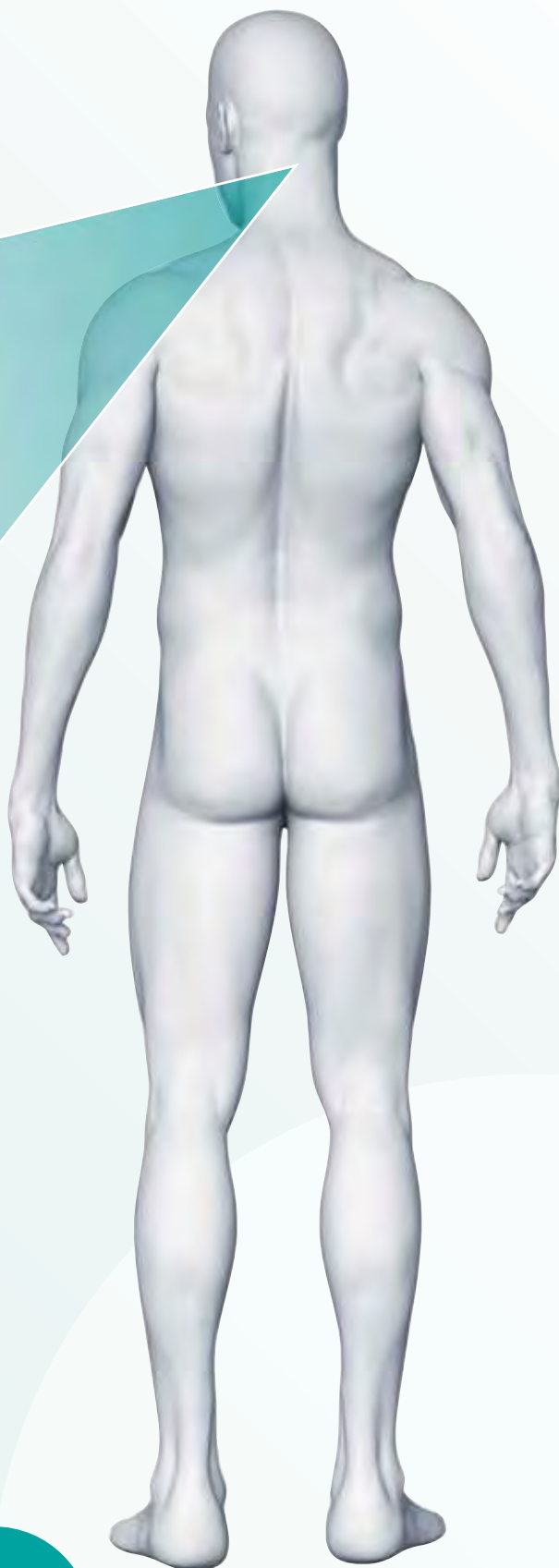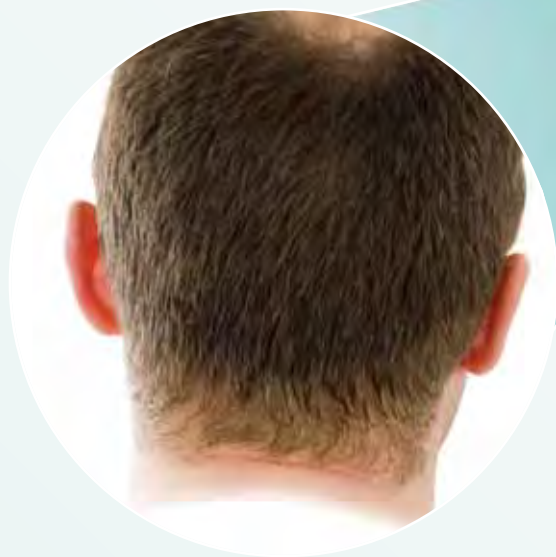# Mongolian Spot



ΔΠ⁹ΑῶΔσ  
ῚῚῚῚῚῚῚῚ

Itirviluani  
Sunnguujannguaq  
Tunguyurniq  
Tache pigmentaire

# Nape of the Neck



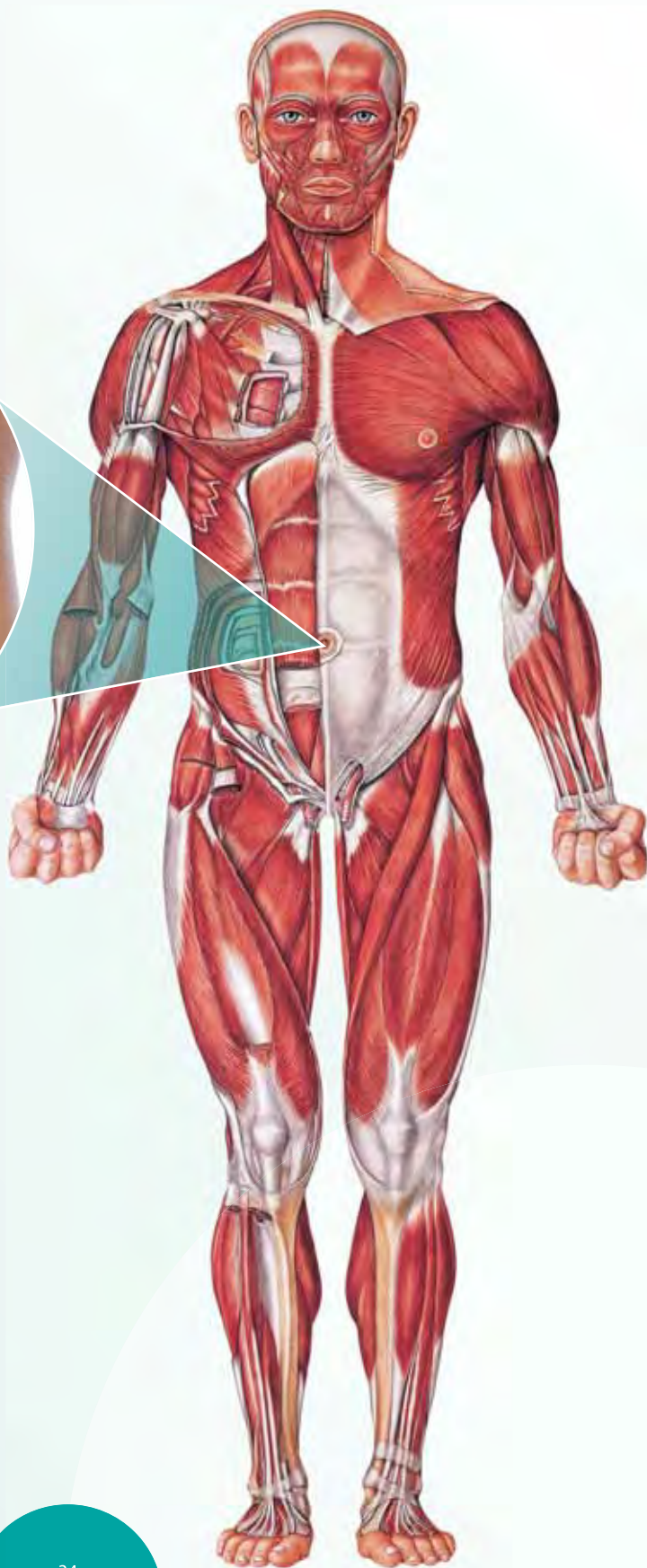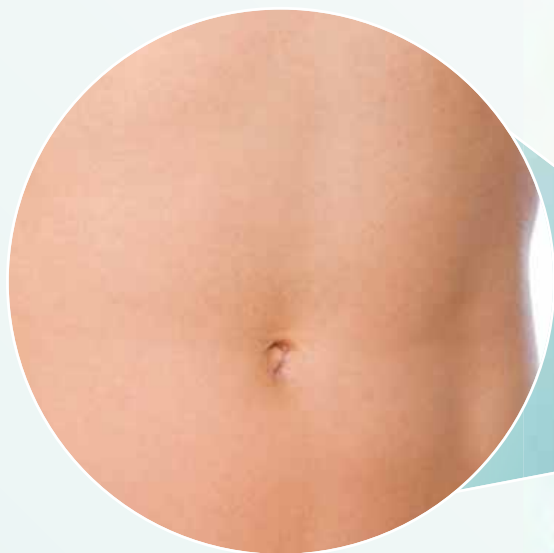نَافِيس

Tunusuk

Tunuhuk

Nuque

# Navel / Umbilicus



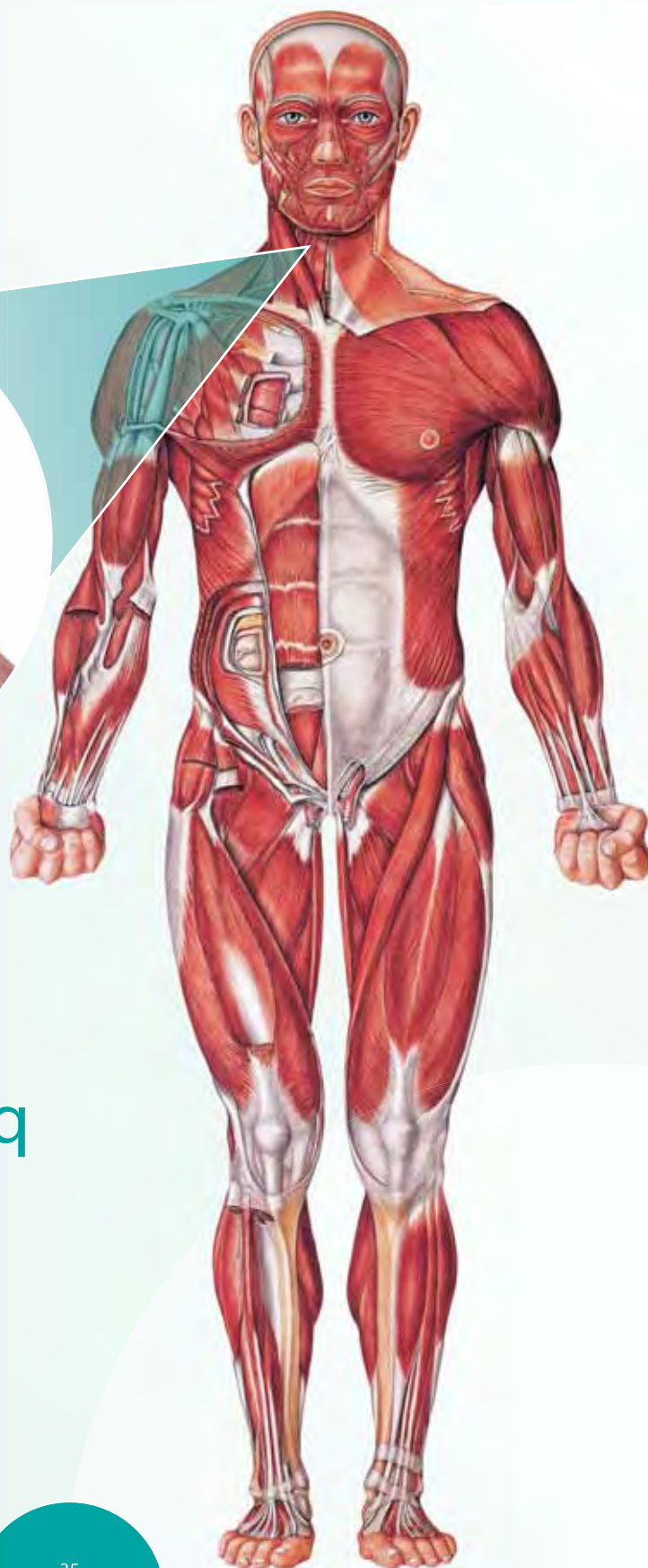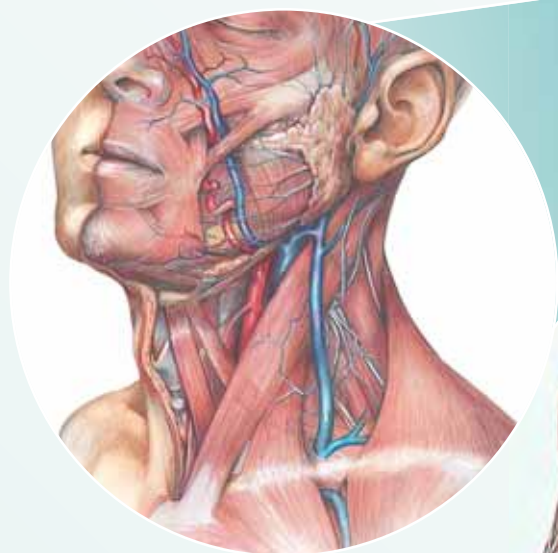
ᲒᲑᲘᲗᲑ

Qalasiq

Qalahiq

Nombril ou  
ombilic

# Neck



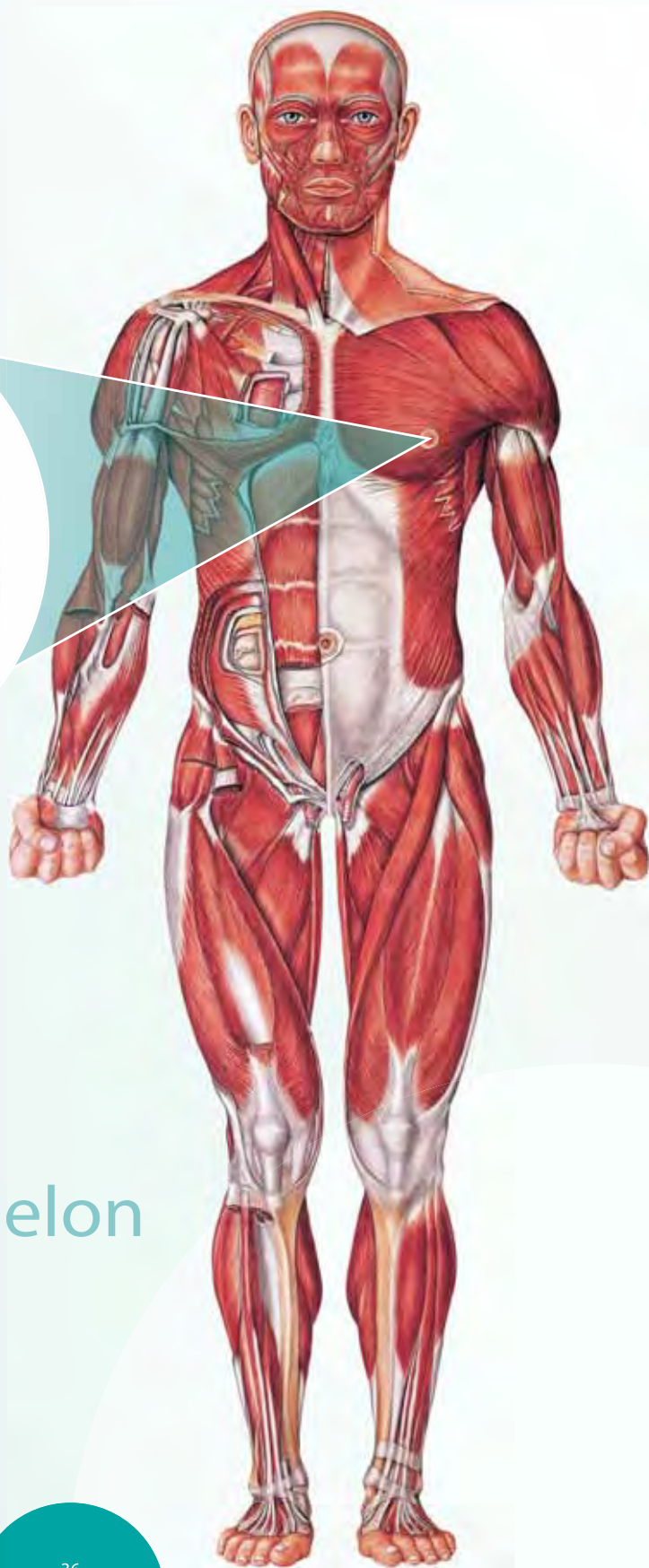
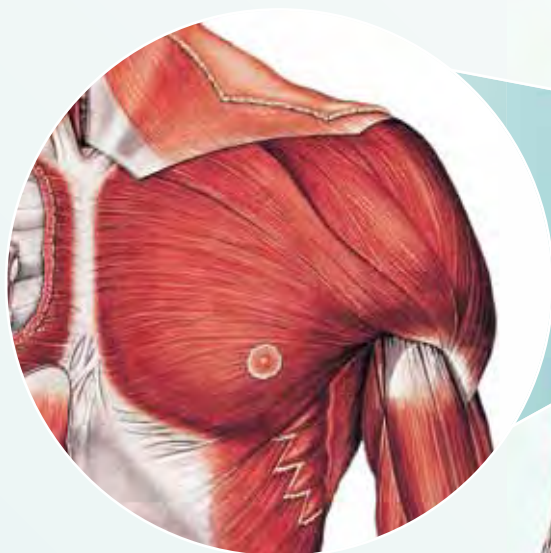
ᄒᄒᄒᄒᄒᄒᄒᄒ

Qungasiq

Qunguhiniq

Cou

# Nipple



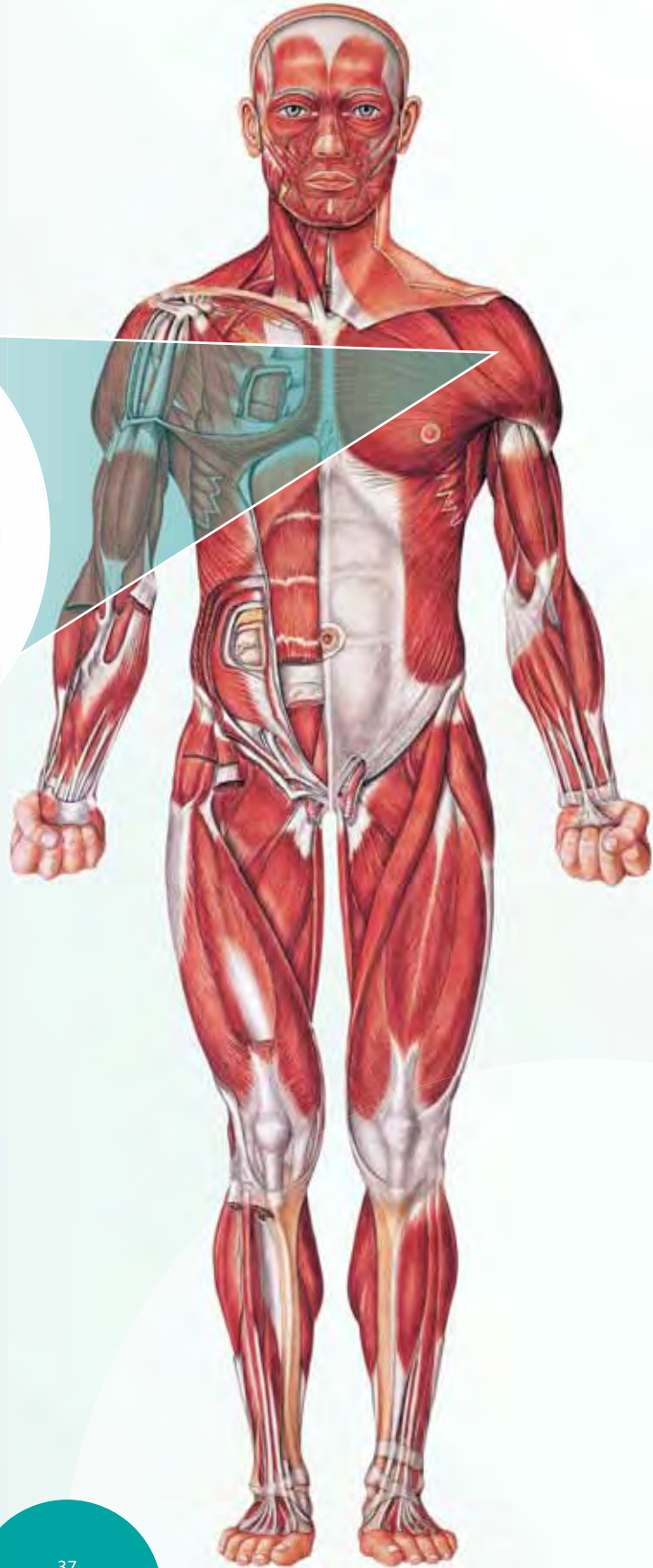
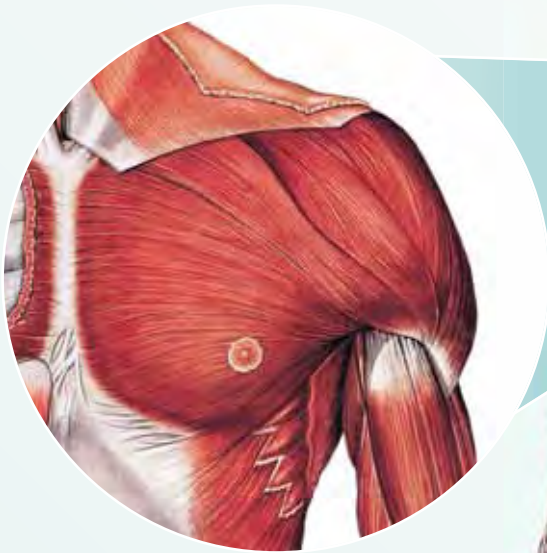
ᲒᲑ

Mulik

Muluk

Téton mamelon

# Shoulder



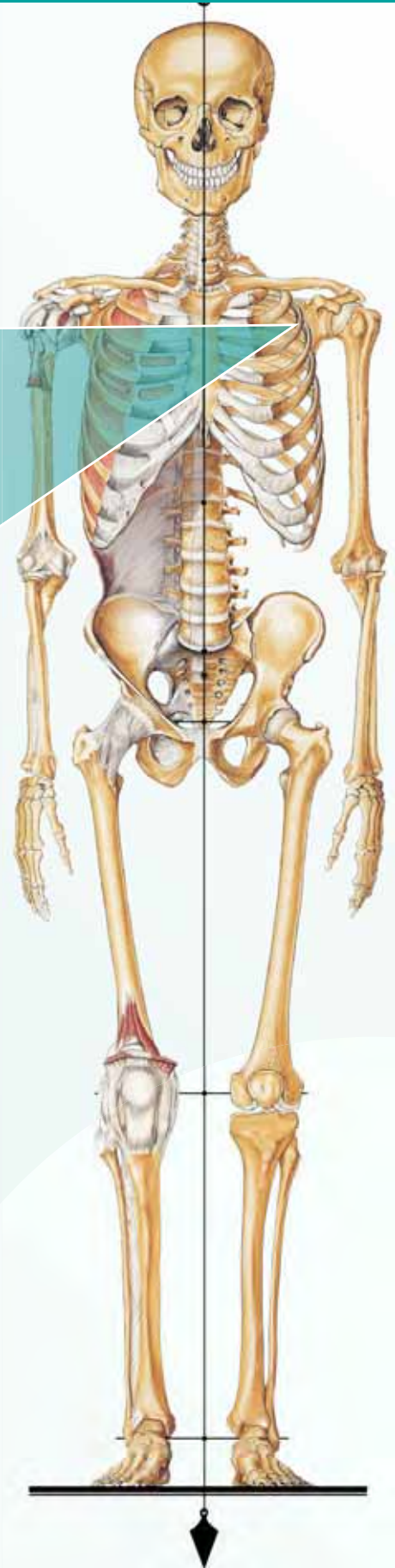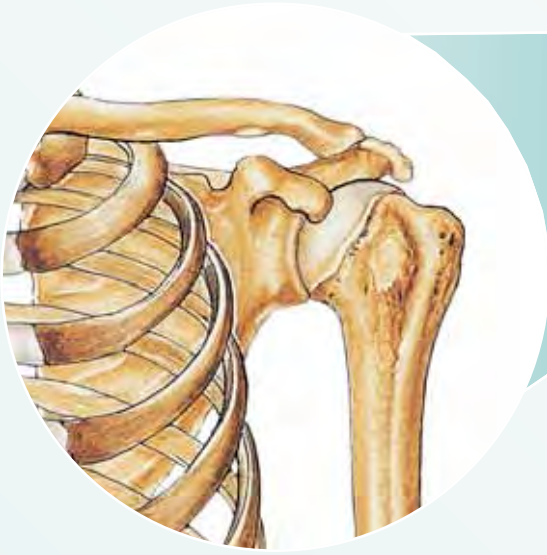
ἄΔ

Tui

Tuik

Épaule

# Shoulder Hollow



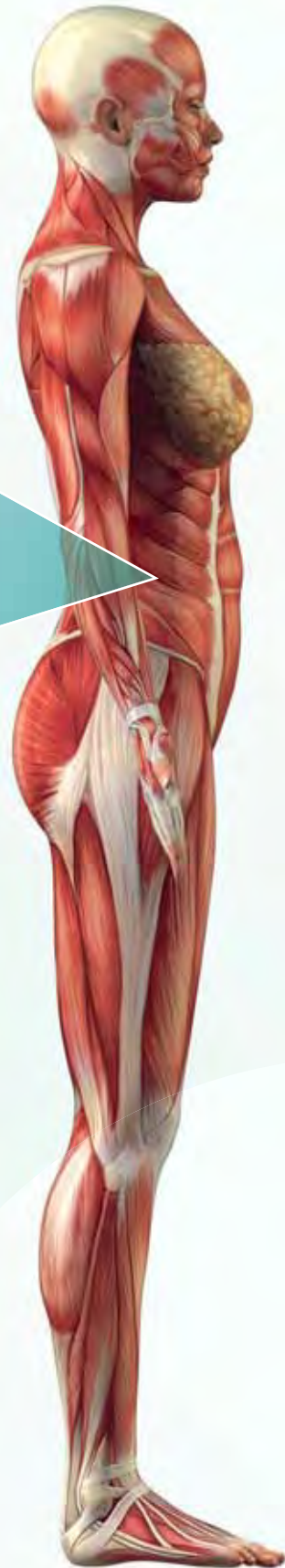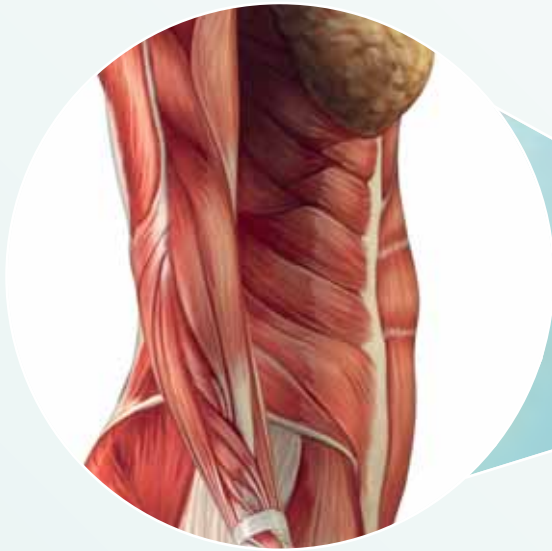Irji

Angmaniq

Côté de la tête,  
creux de l'épaule



# Side of the Body, Flank



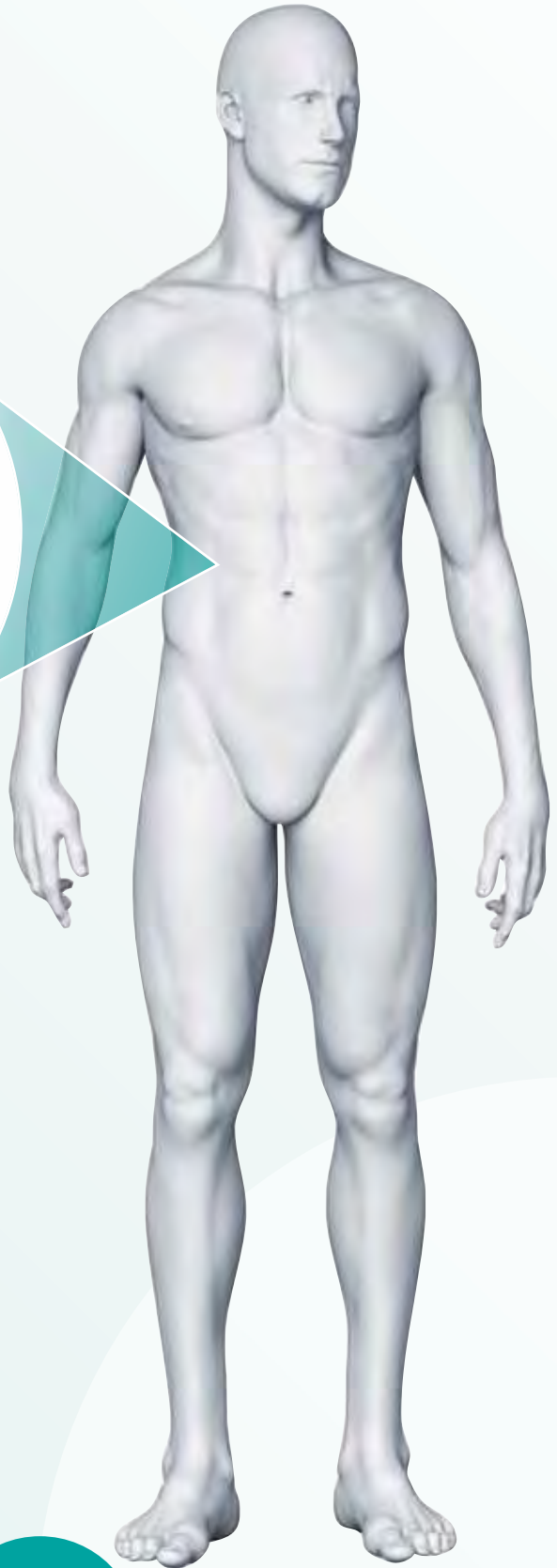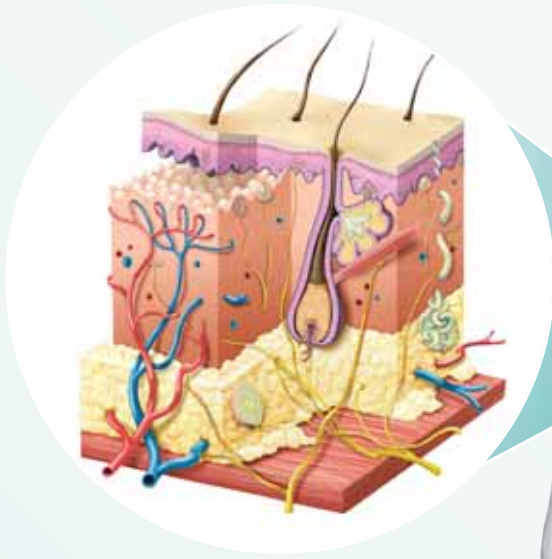
ሴናራቅ

Saniraq

Haniraq

Côté, flanc

# Skin



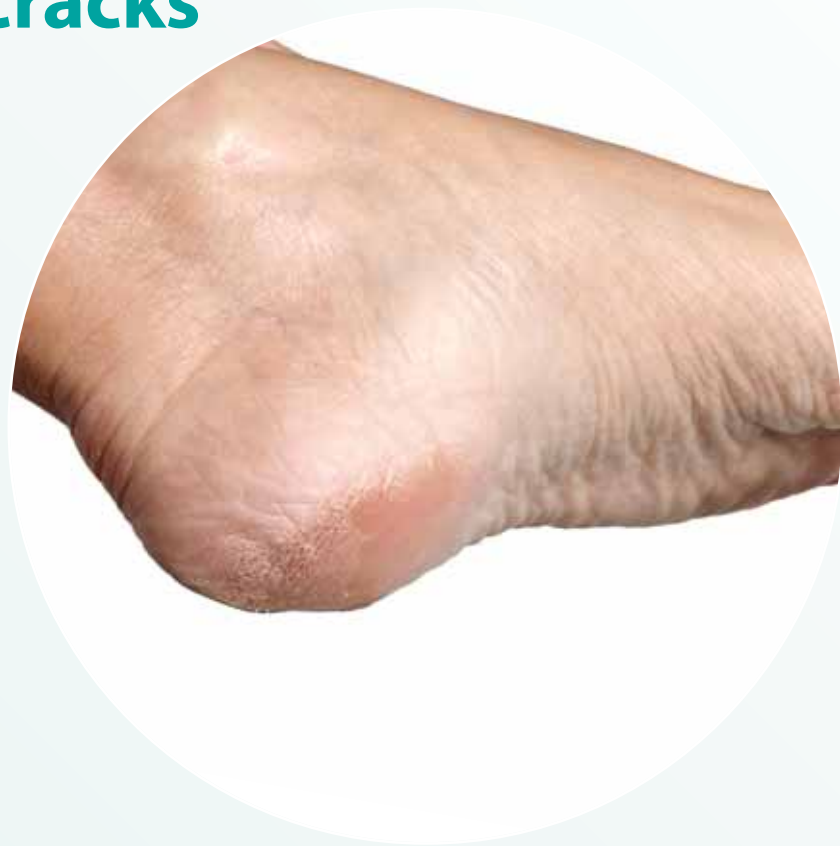▷Δσ<sup>b</sup>

Uvinik

Uvinik

Peau

# Skin Cracks



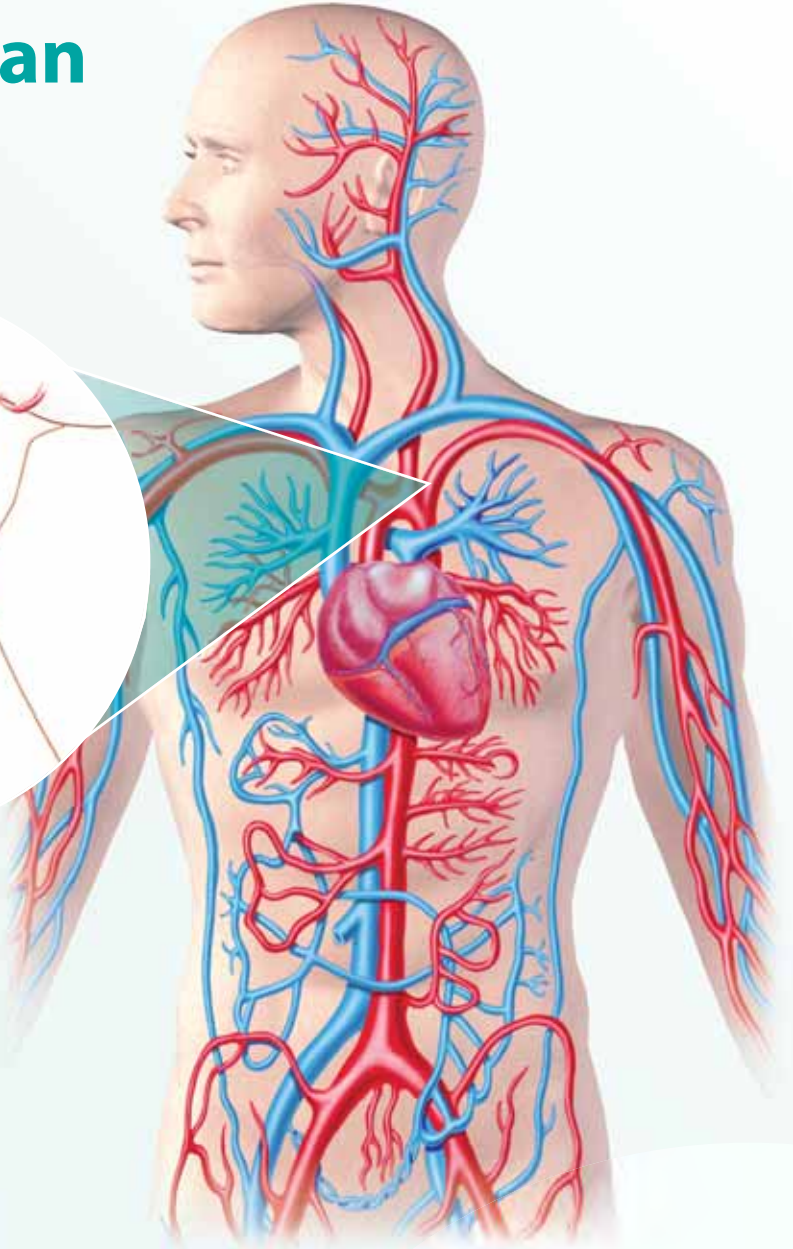
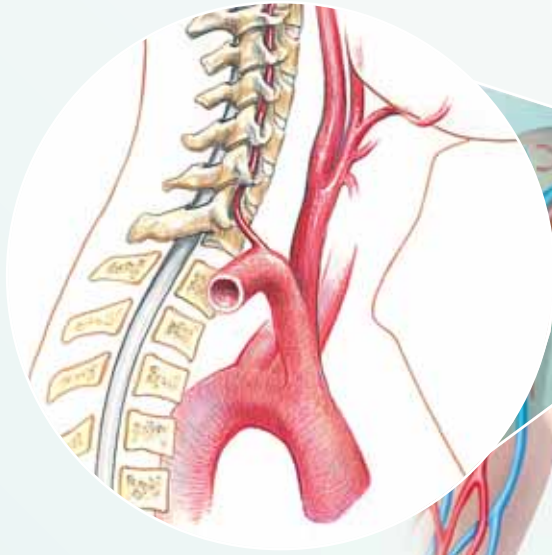
ᐱᐸᐸᐸᐸᐸᐸᐸᐸᐸᐸ

Siggiatiqsimajut

Qublurniq/Amirliqtuq

Gerçures

# Subclavian Fossa



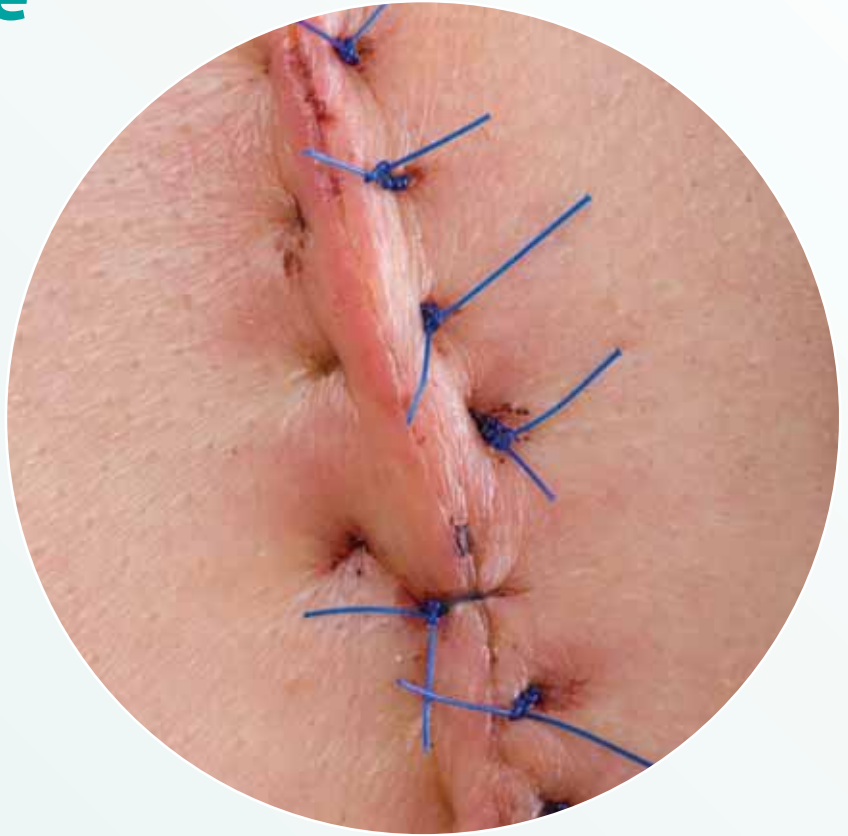ΔρϑΔβ

Isirviik

Itirvik

Salières

# Suture



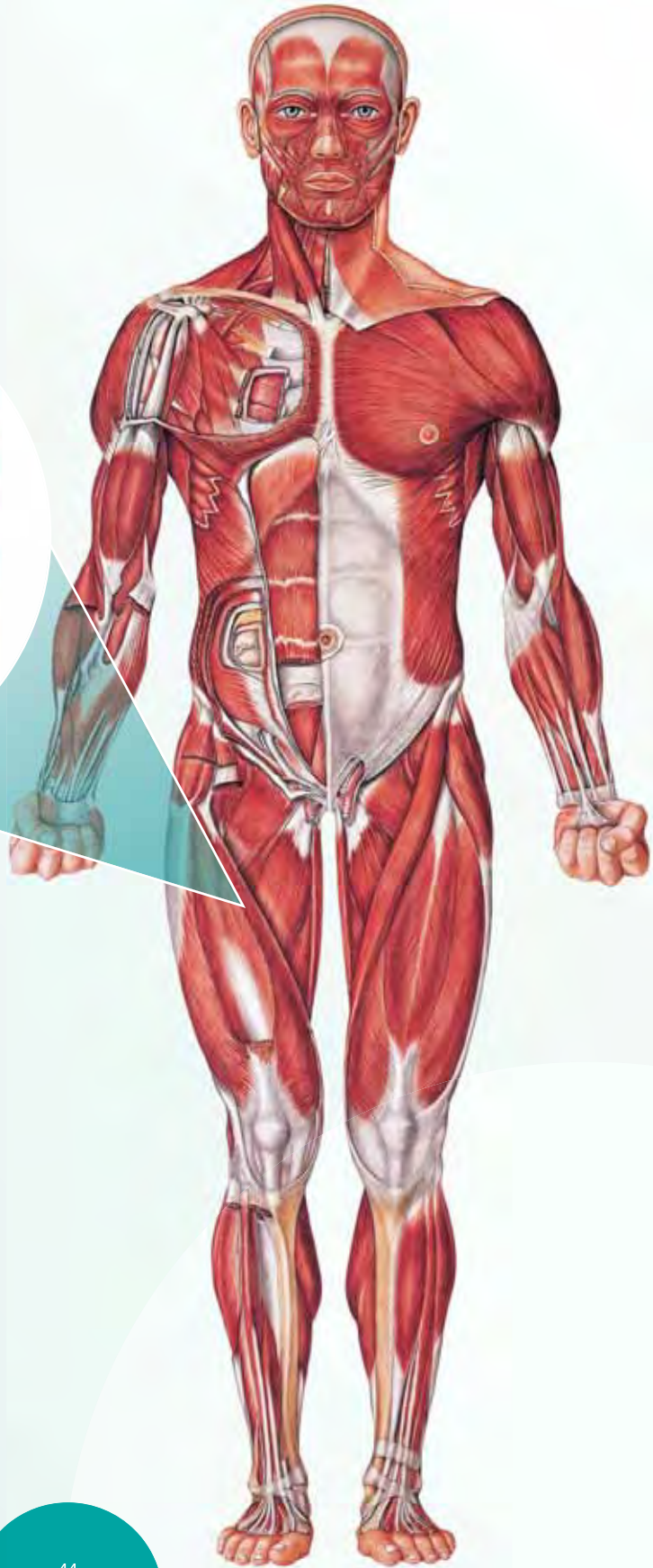
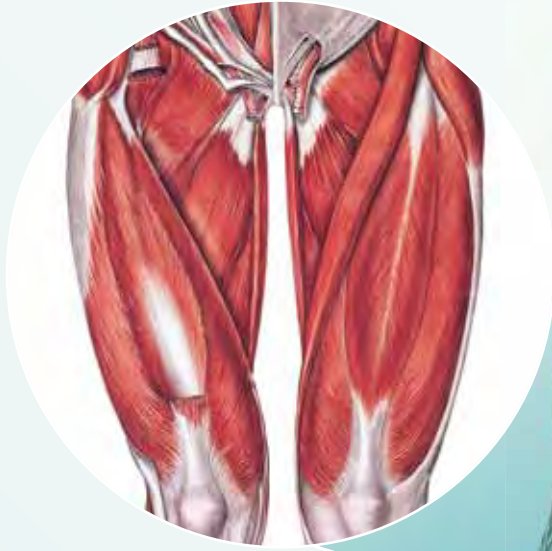𐑆𐑇

Kilu

Kiluit

Suture

# Thigh



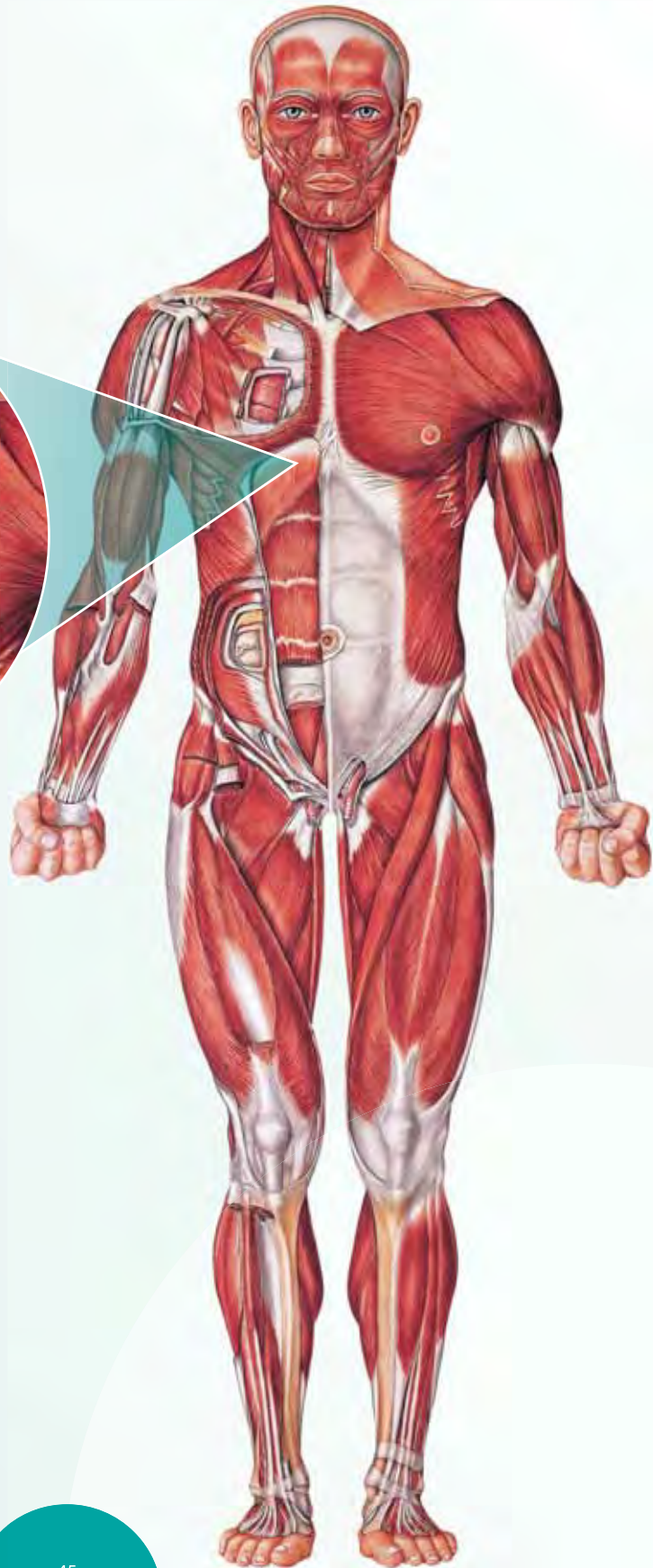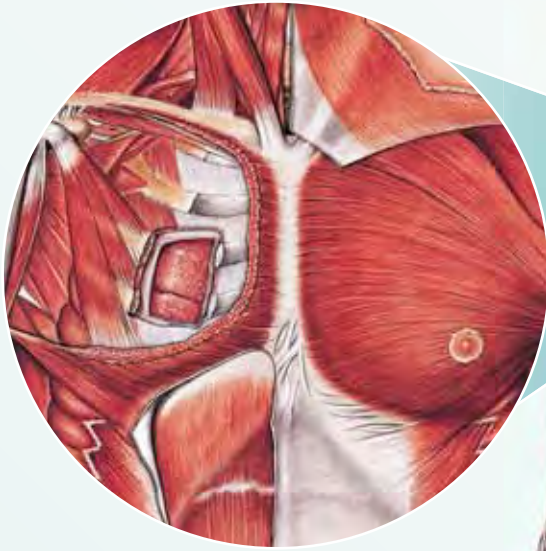
ᠶᠢᠨᠲᠡᠭᠦᠨ

Qukturaq

Mimiq

Cuisse

# Trunk



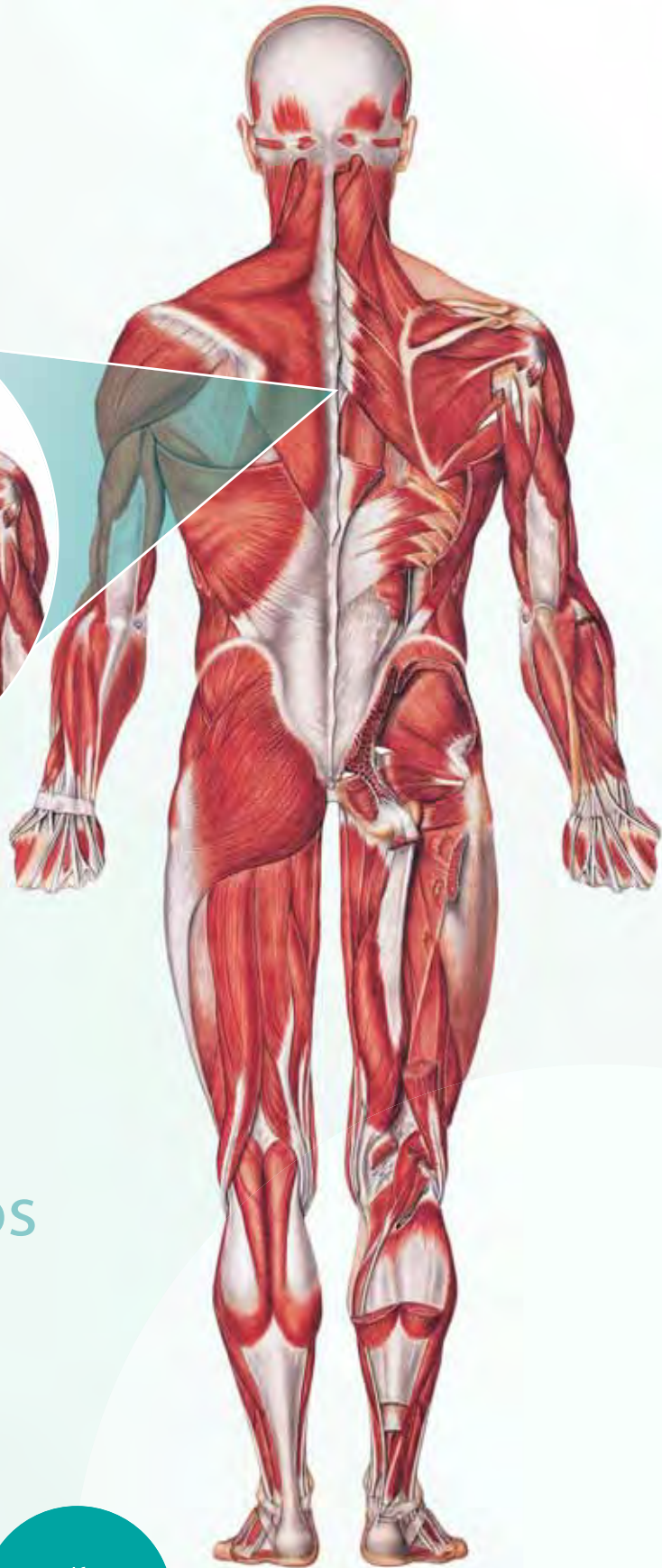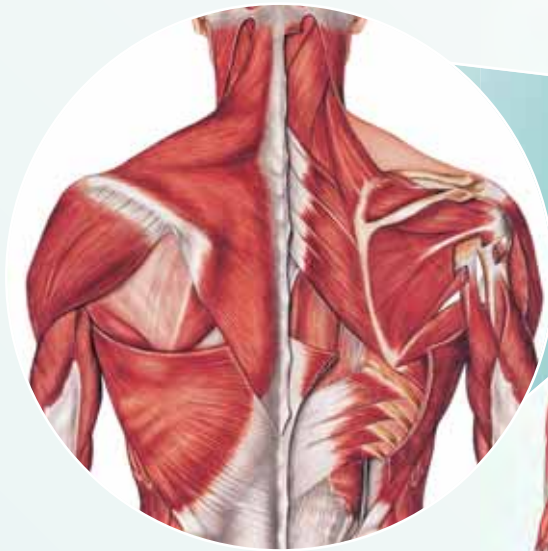ᑭᐱᑎ

Kiati

Qatiggaaq

Tronc

# Upper Back



ᐱᐱᐱᐱᐱ

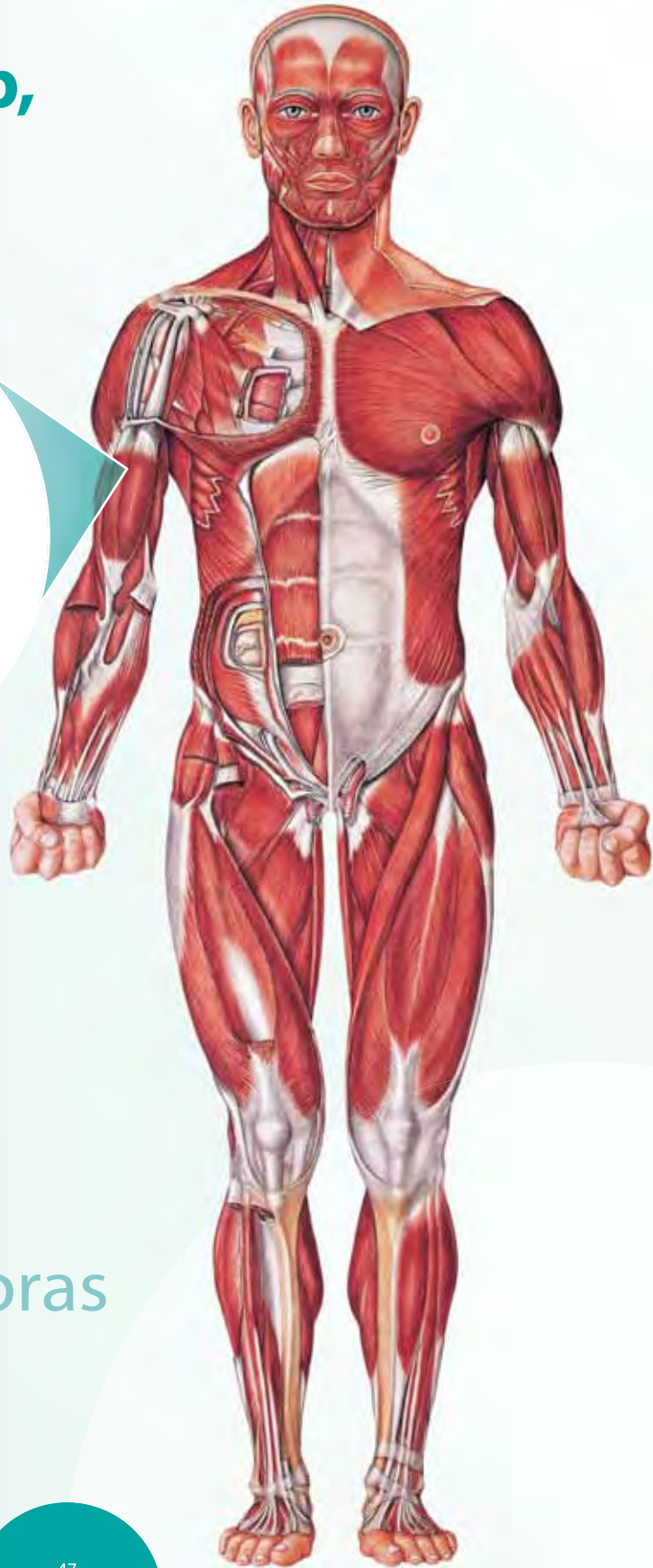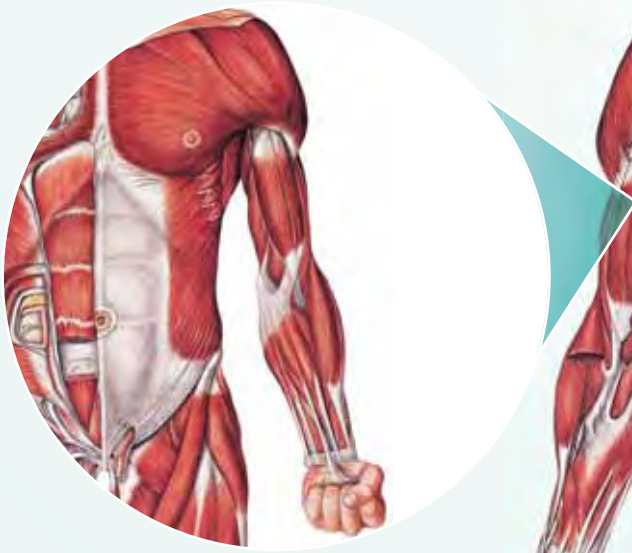Aariak

Aaridjak

Haut du dos



# Upper Limb, Arm



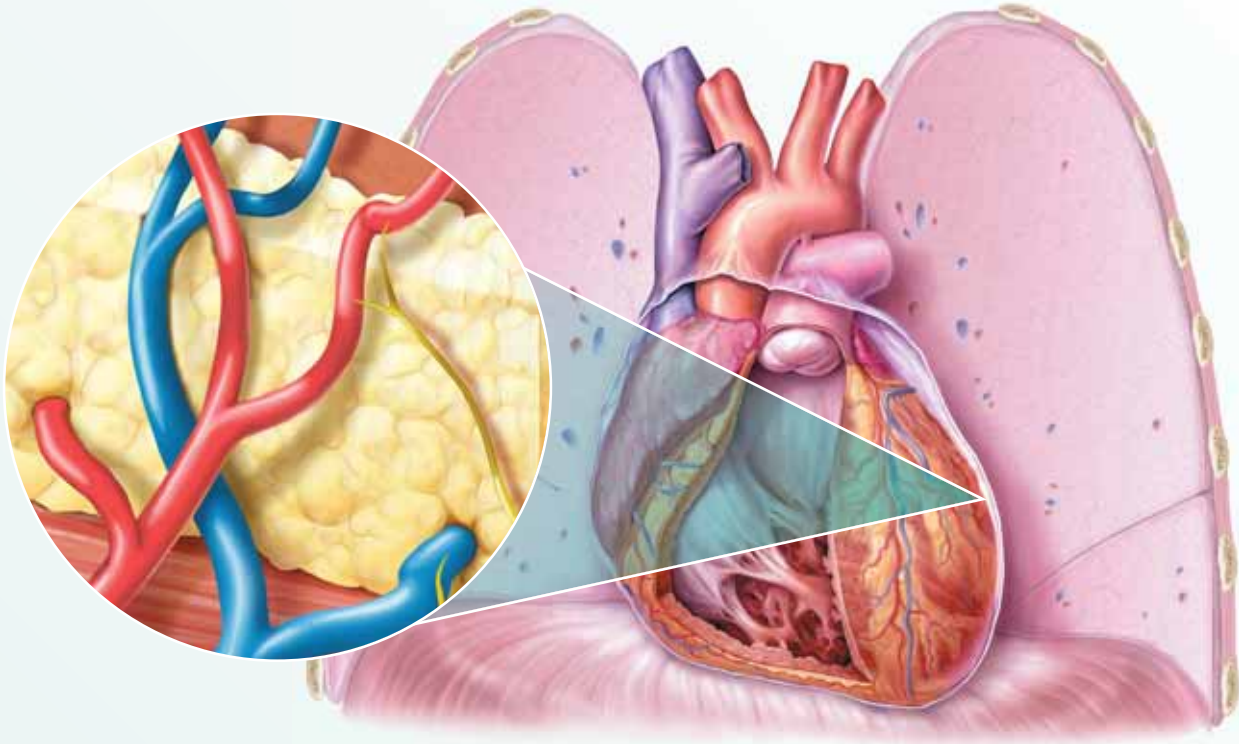
ᐱᓂᓴᓴᓂᓴᓂᓴᓂᓴ

Aksaqquq

Taliq

Membre  
supérieur, bras

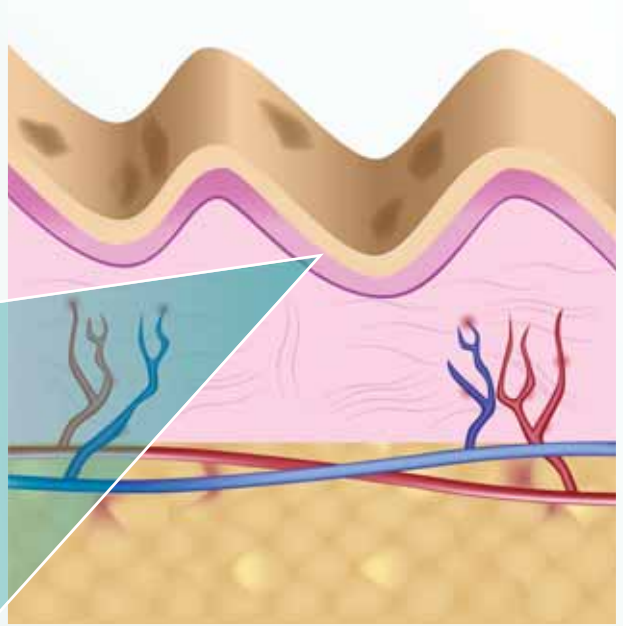
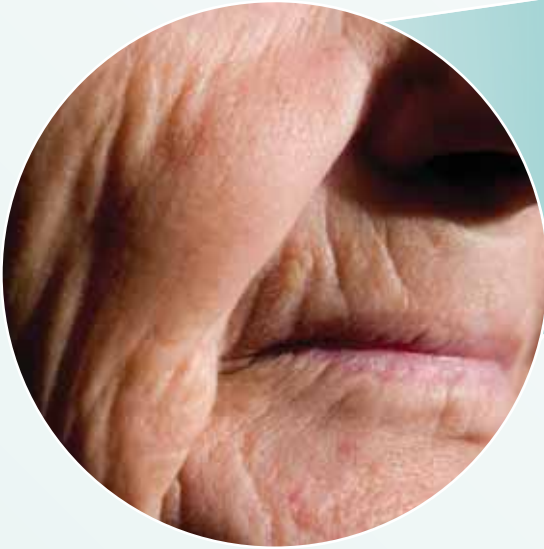# Visceral Fat



ᐃᐱᐱᐸᐱᐸᐱᐸ ᐃᐱᐱᐸᐱᐸᐱᐸ

Uummatiup Uqsunga  
Qaalitaa  
Graisse péricardique

# Wrinkle



ΔJ<sup>c</sup> 5<sup>9b</sup>

Imulluq

Imullungniq

Ride



# Feet/Hands

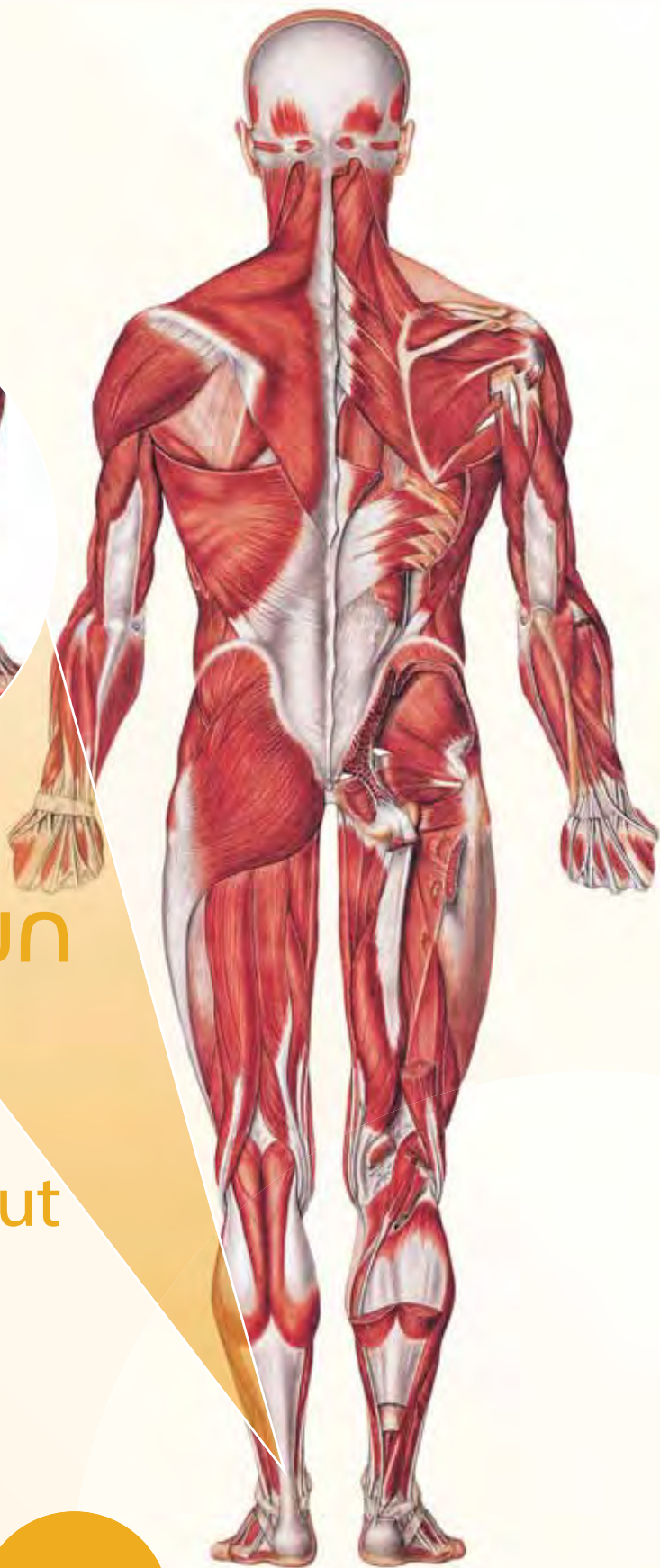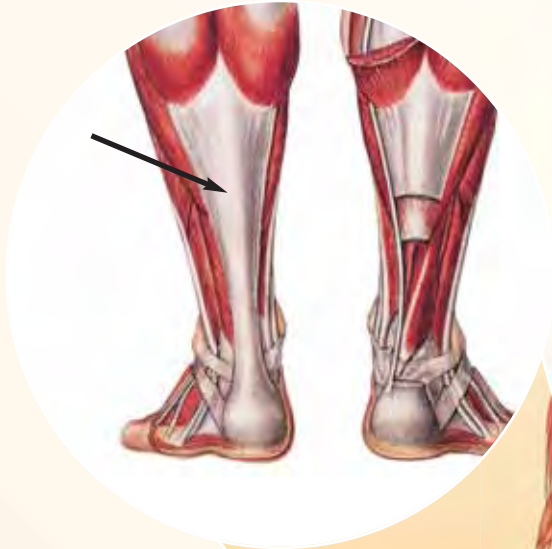ᐃᓯᑲᑲᑦ / ᐃᑭᑭᐃᑦ

Isikkat/Aggait

Itikkat/Algak

Pieds / Mains

# Achilles Tendon



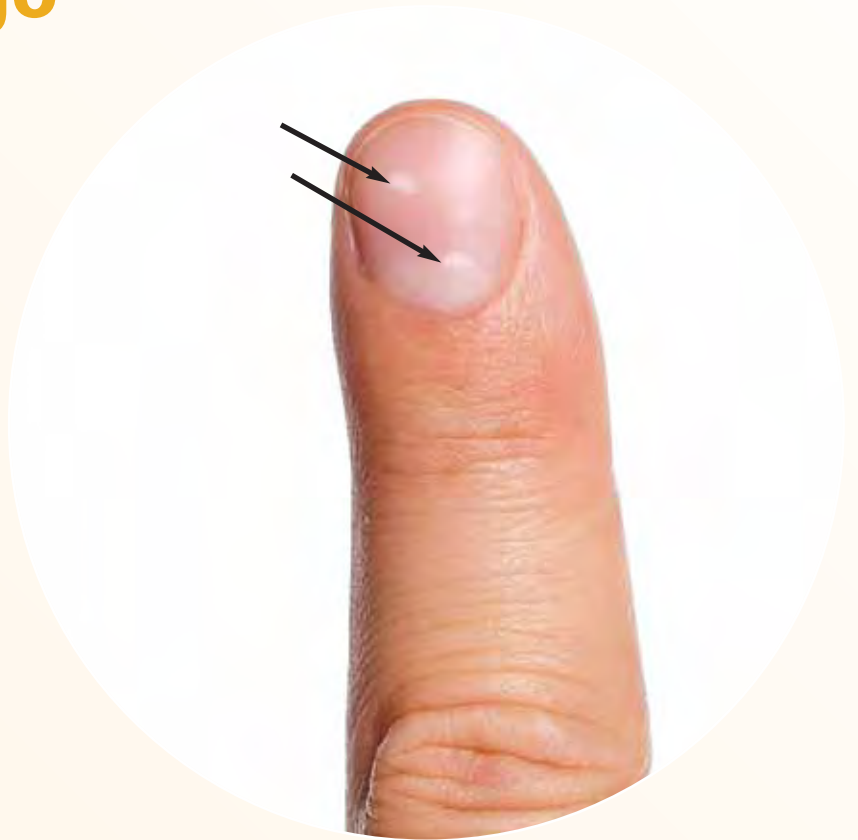
ᐅᑭᑭᑭᑭᑭᑭᑭᑭ

Kingmiq-qurluguti

Kingmitqurut

Tendon d'Achille

# Albugo



ᄒᄒᄒᄒ

ᄒᄒᄒᄒᄒᄒᄒᄒᄒᄒᄒᄒᄒᄒᄒᄒ

Kukiup

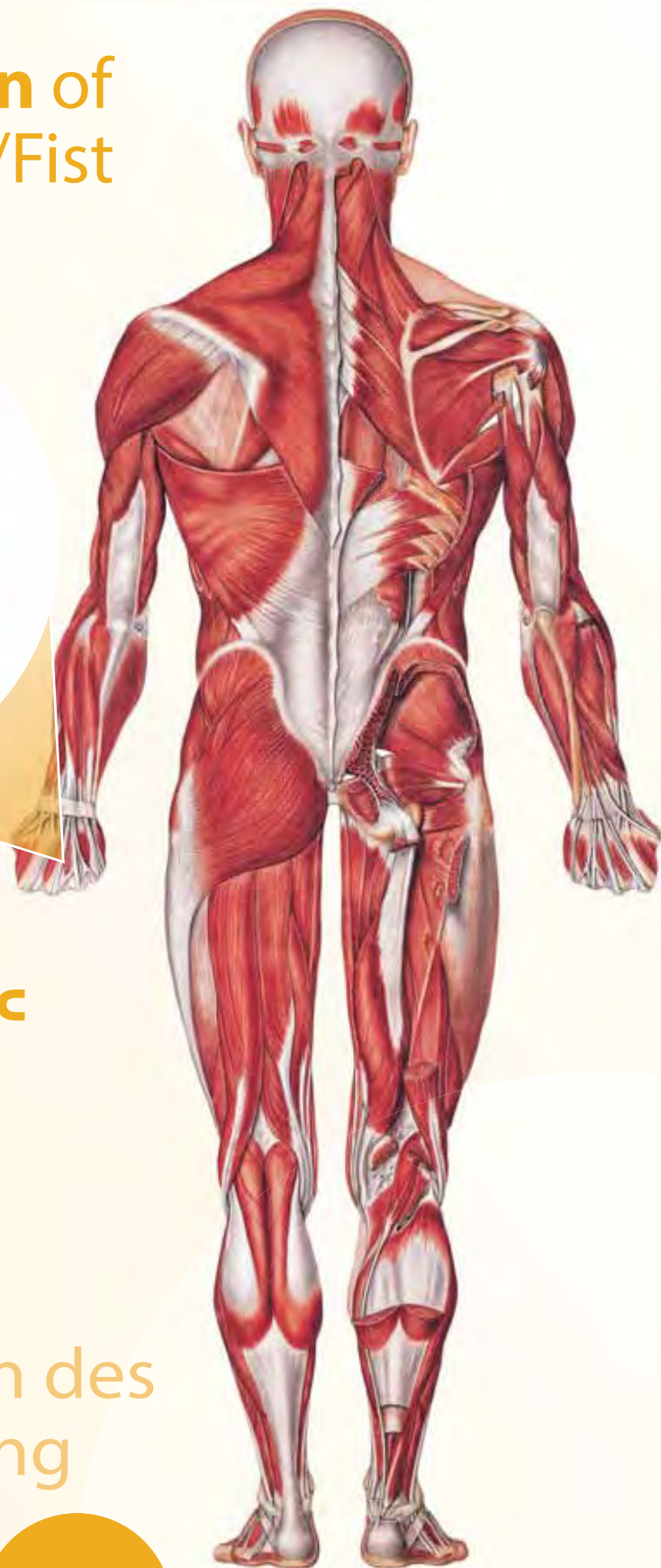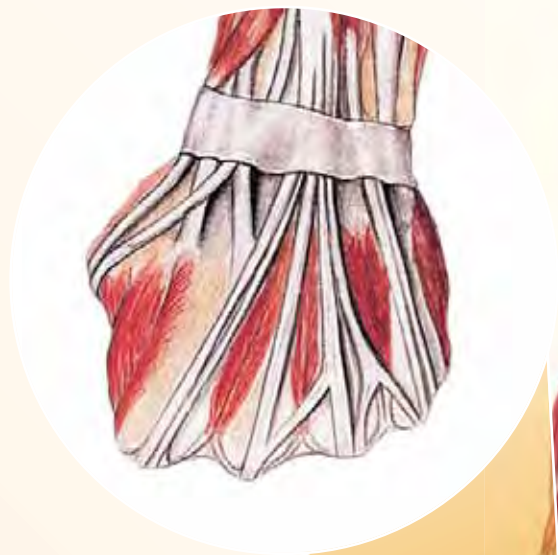Qakuqtagalaangit

Kukiup

Qakurnira

Albugo

# Articulation of the Fingers/Fist



ᐱᕐᕐᕐᐱᕐᐱ

ᐱᕐᕐᕐᐱᕐᐱᕐᐱᕐᐱ

Aggaup

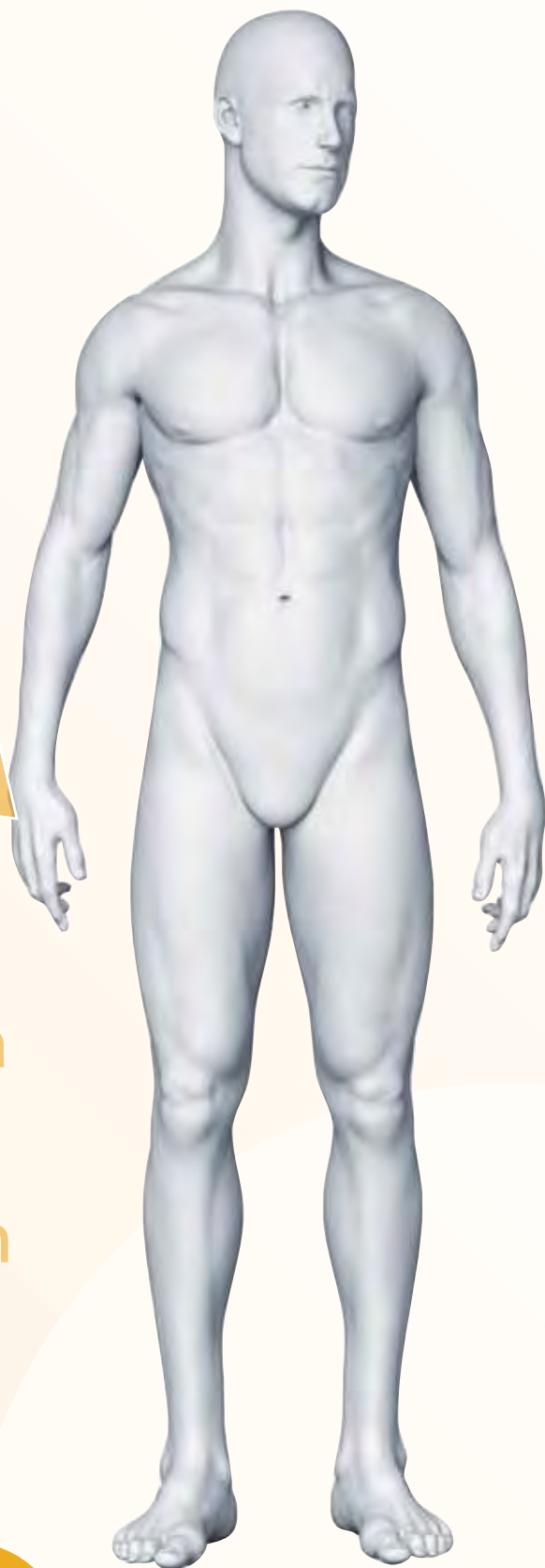Iqijarningit

Iqitaqtuq

Articulation des  
doigts, poing



# Back or Dorsum of the Hand



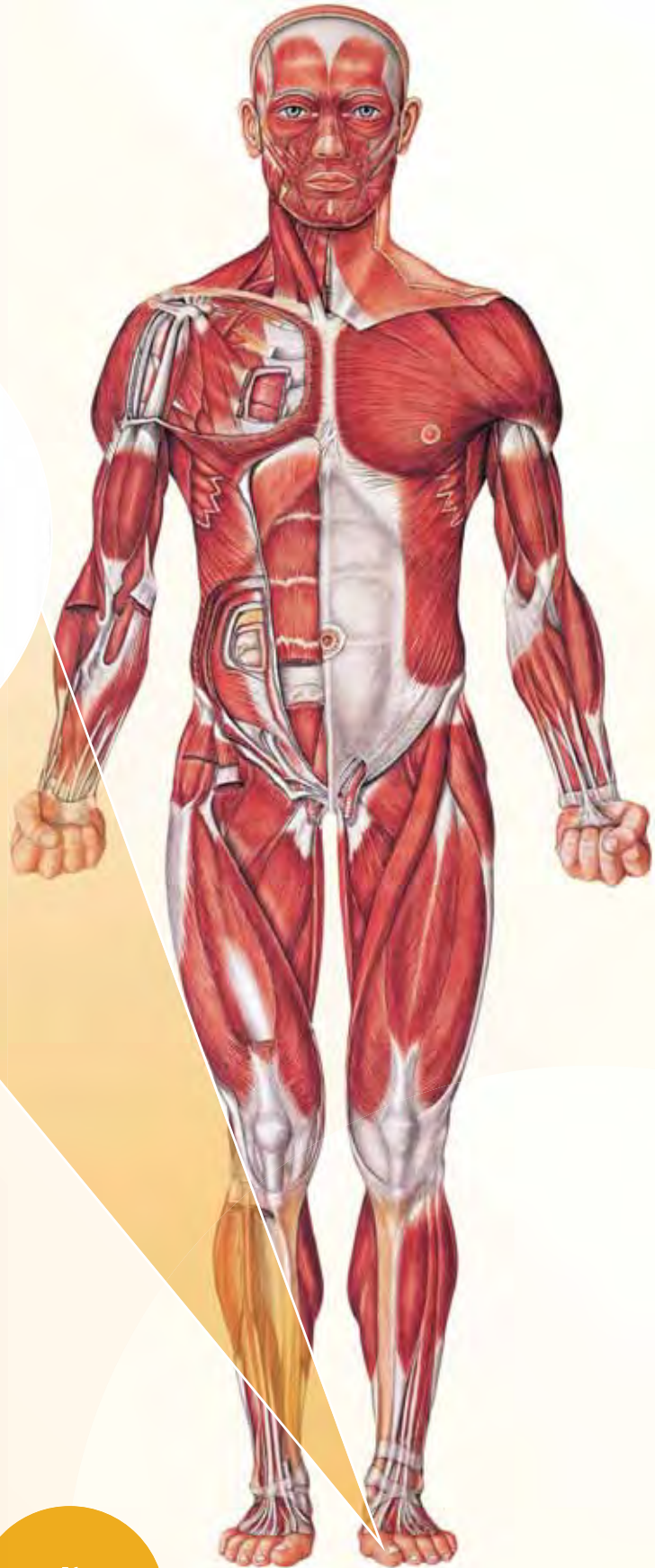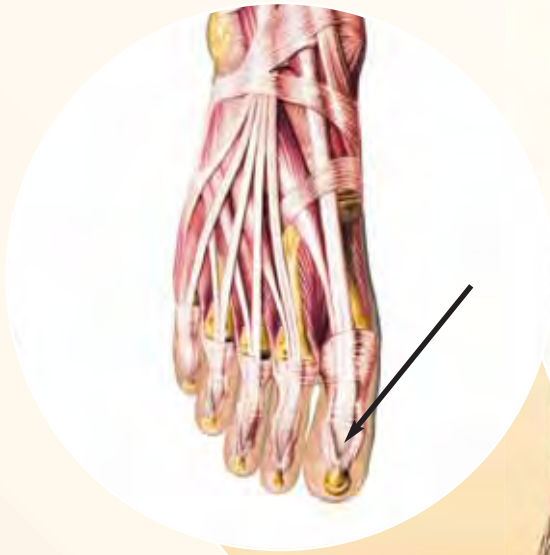ᐱᑭᑭᐱᑭ ᐅᑦᑎᑦᐱ

Aggaup Tunua

Algaup Tunua

Dos de la main

# Big Toe



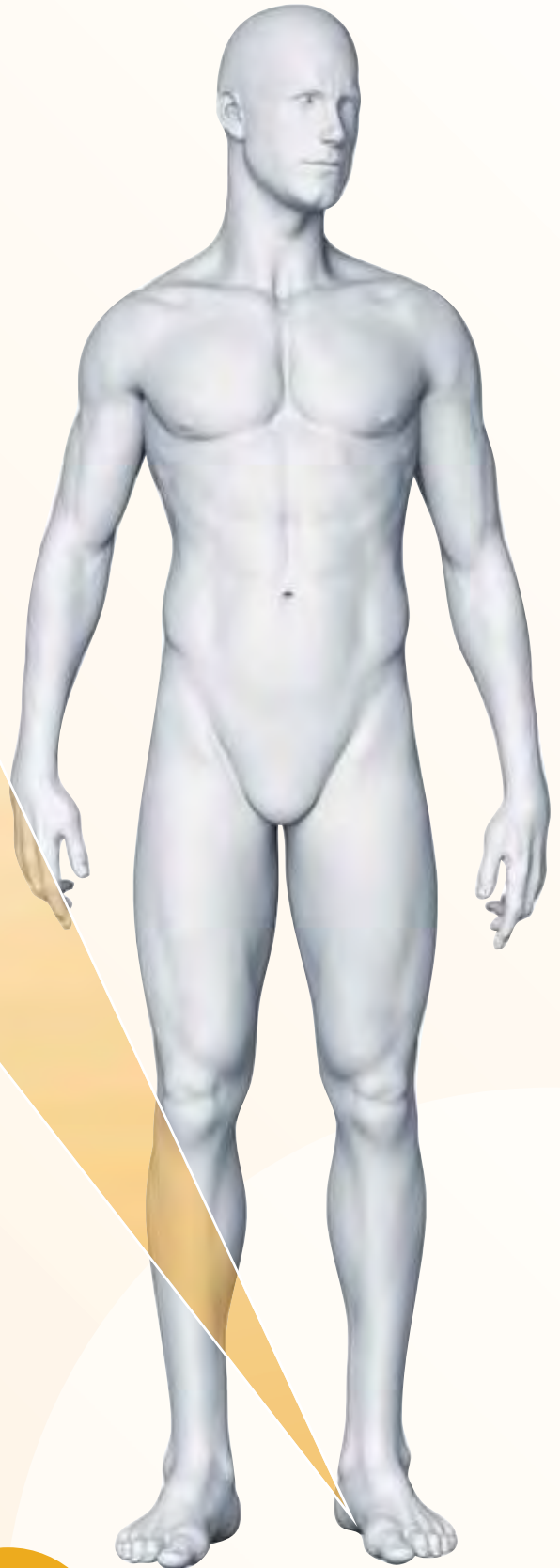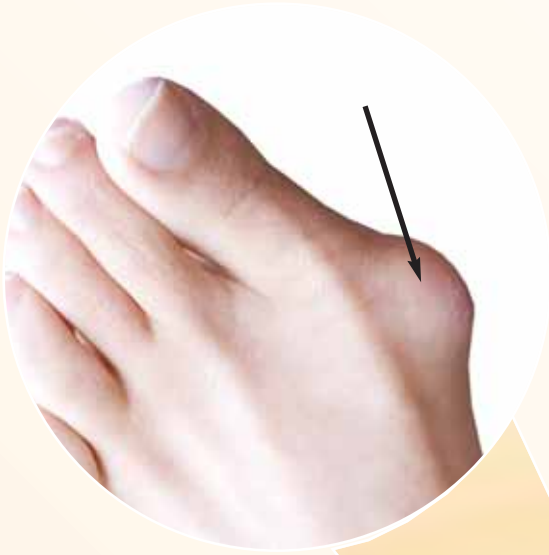ᑭᑭᑭᑭᑭᑭ

Putuguq

Putuguq

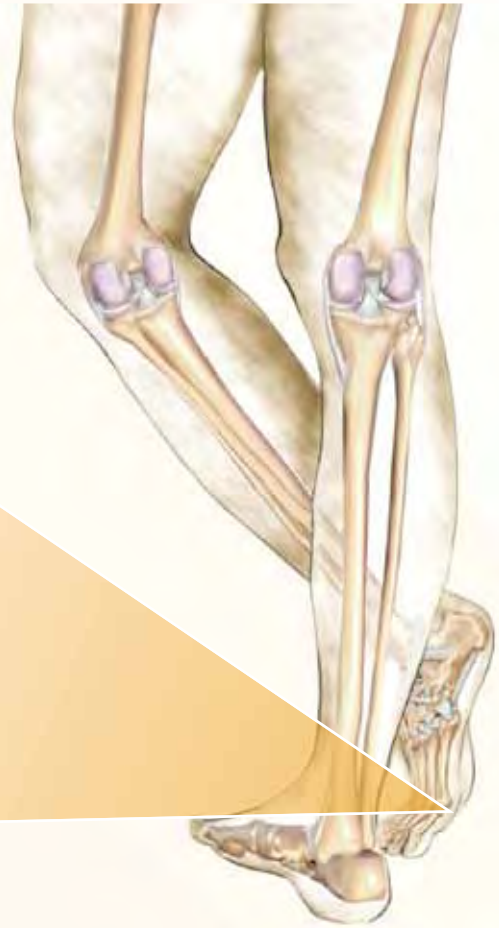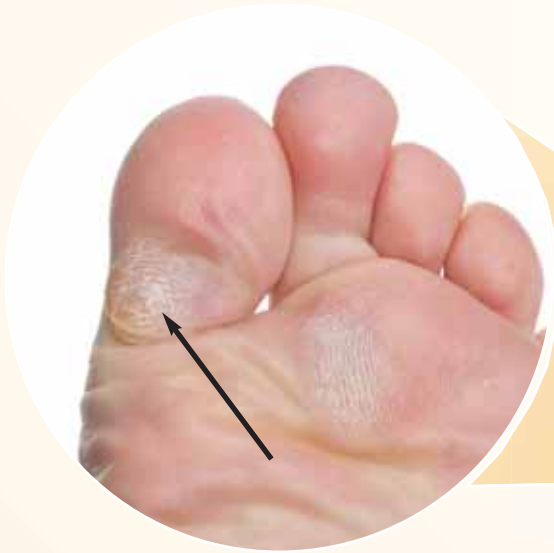Gros orteil  
(tallux)

# Bunion of the Big Toe



ᐱᓐᓴᓴᐅᐅ<sup>ᐅ</sup>  
Pingaluk  
lhugluk/  
Haunaiyaq  
Racine du  
gros orteil

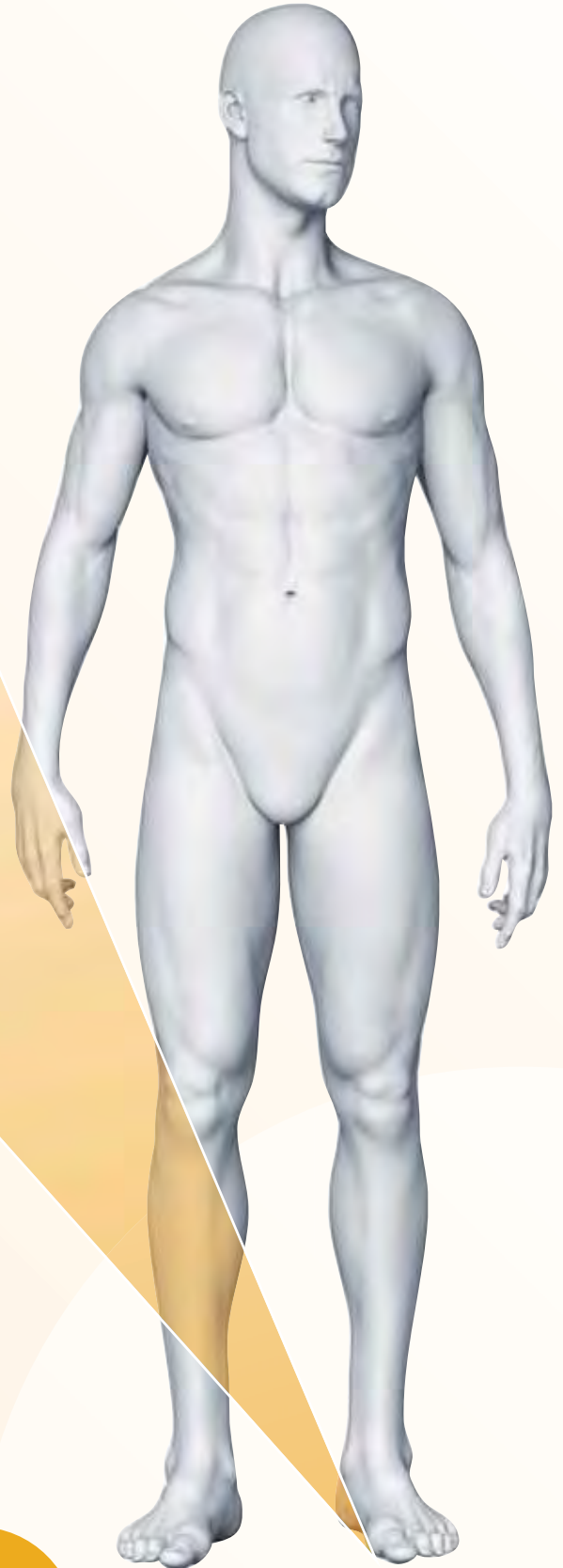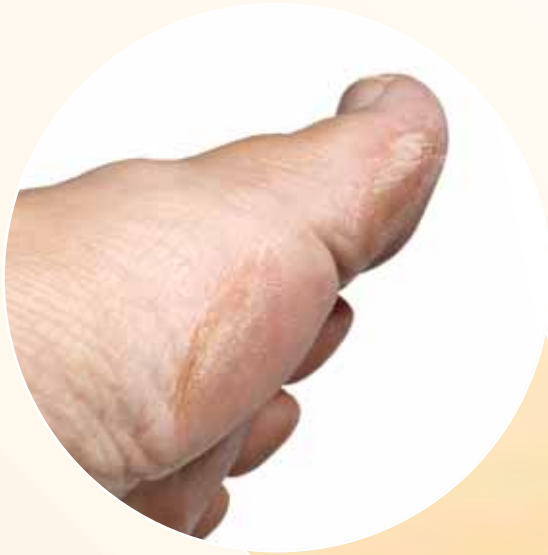# Callus, Hard Skin



ᐱᐸᐸᐸᐸᐸ ᐱᐸᐸᐸᐸᐸ ᐸᐸᐸᐸ

Aggangmilu Isigangmilu Kauk  
Alurnak  
Durillon

# Corn, Callus



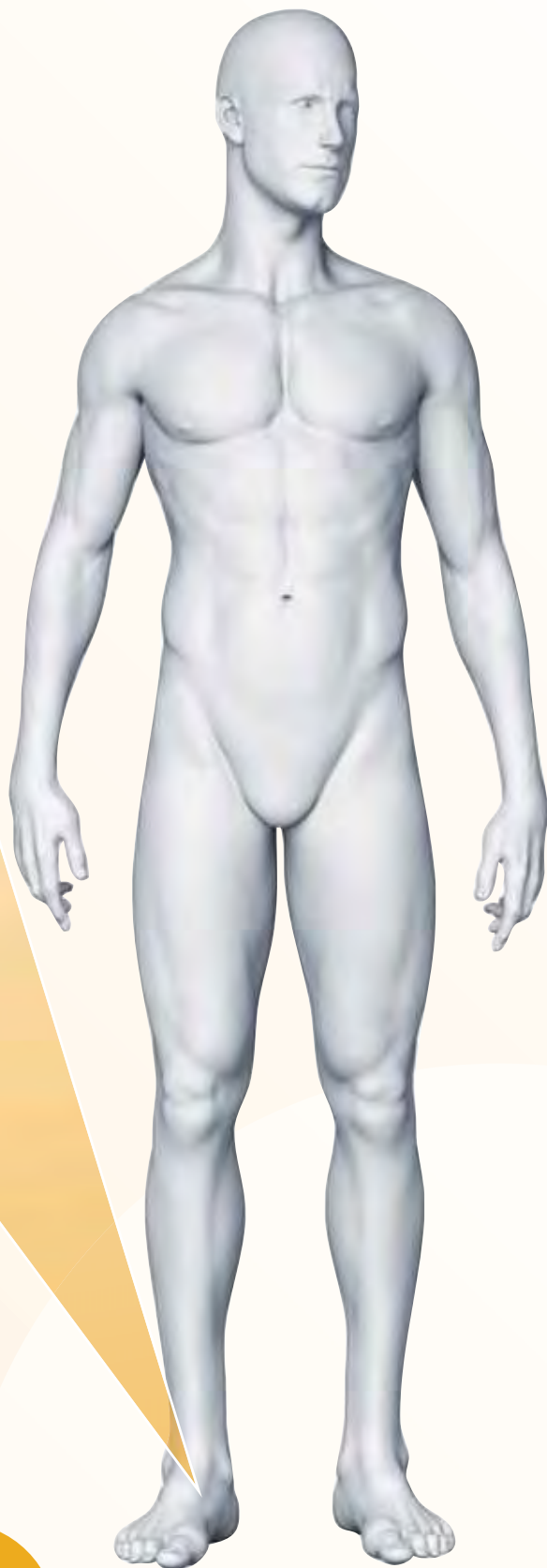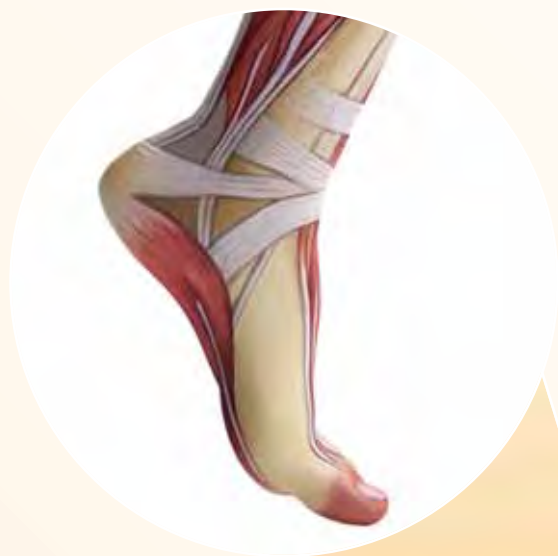ΔΡΥΣΨΓ 6Δ6

Isigangmi  
Kauk

Ammiktuq

Cor durillon

# Dorsum of the Foot



Aluup

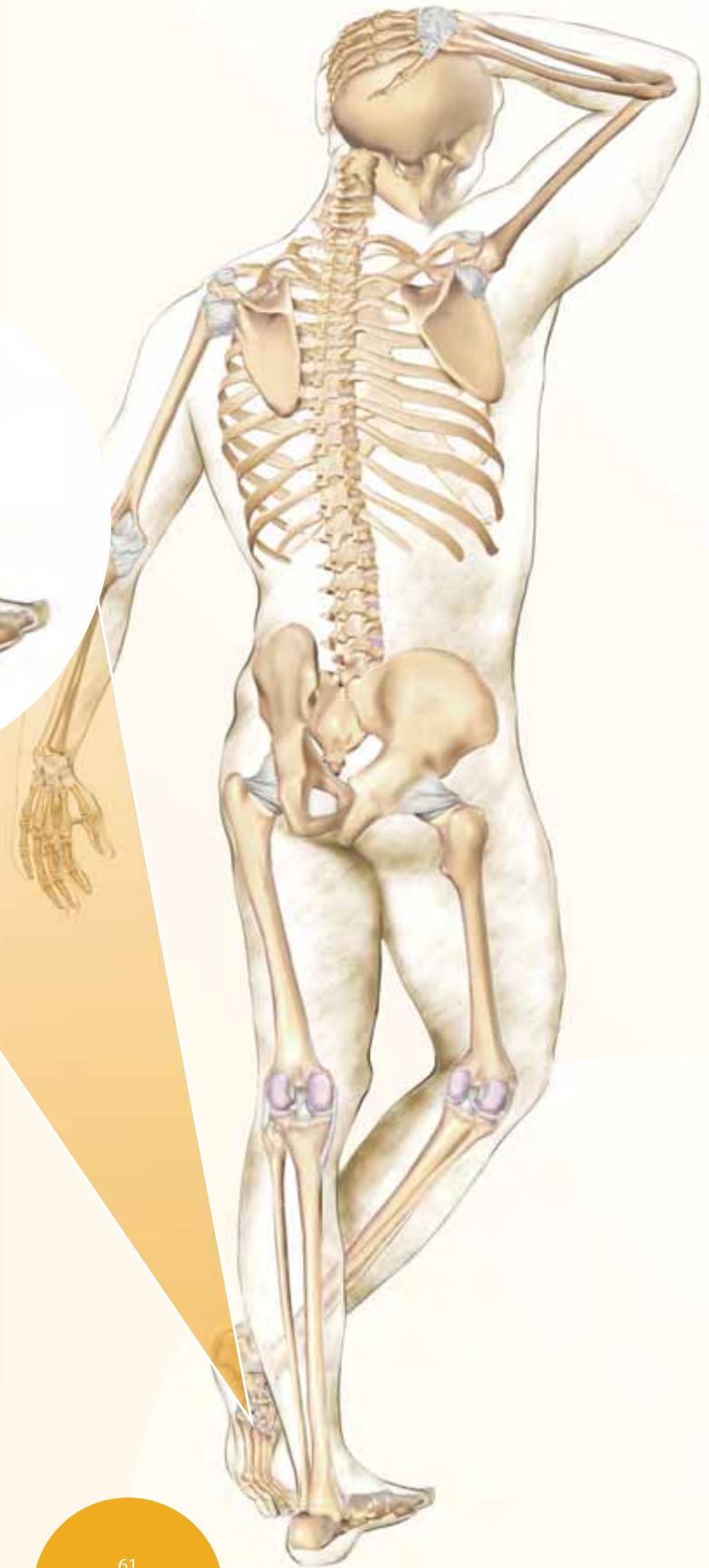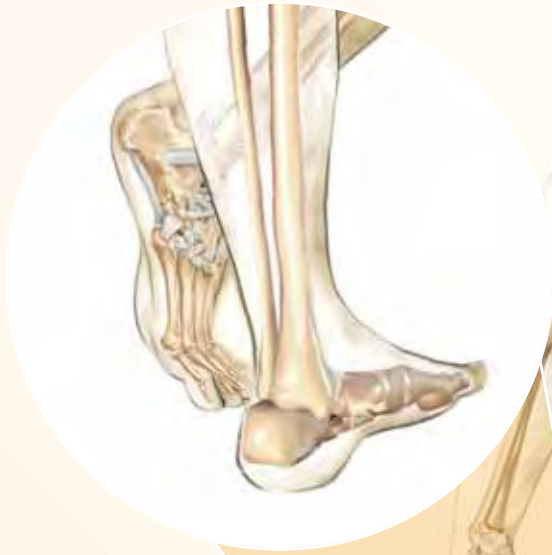Tunnganinga

Aluq

Partie externe

du pied

# Feet



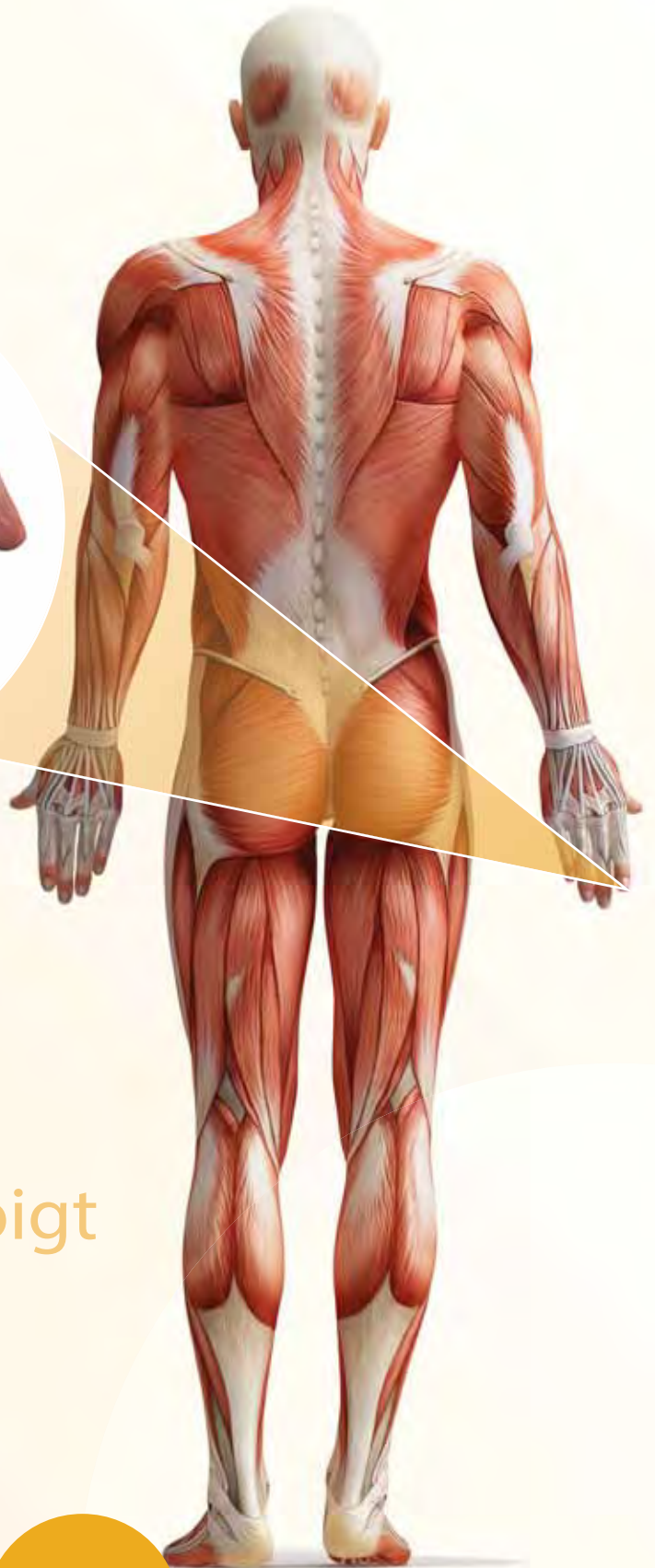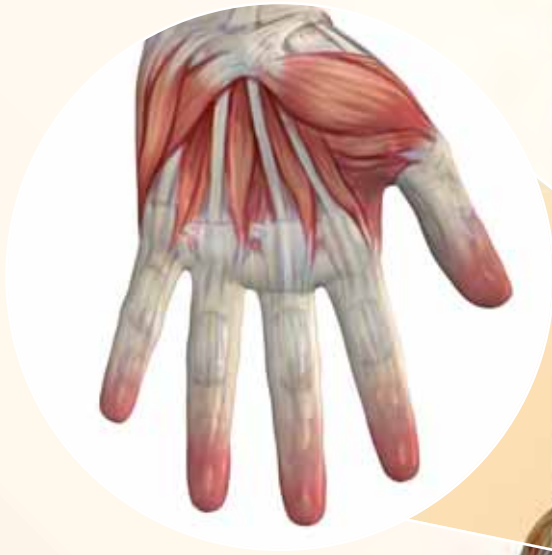ΔΡΥΔΕ

Isigait

Itikkak

Pieds

# Finger Tips



LDQΔ<sup>c</sup>

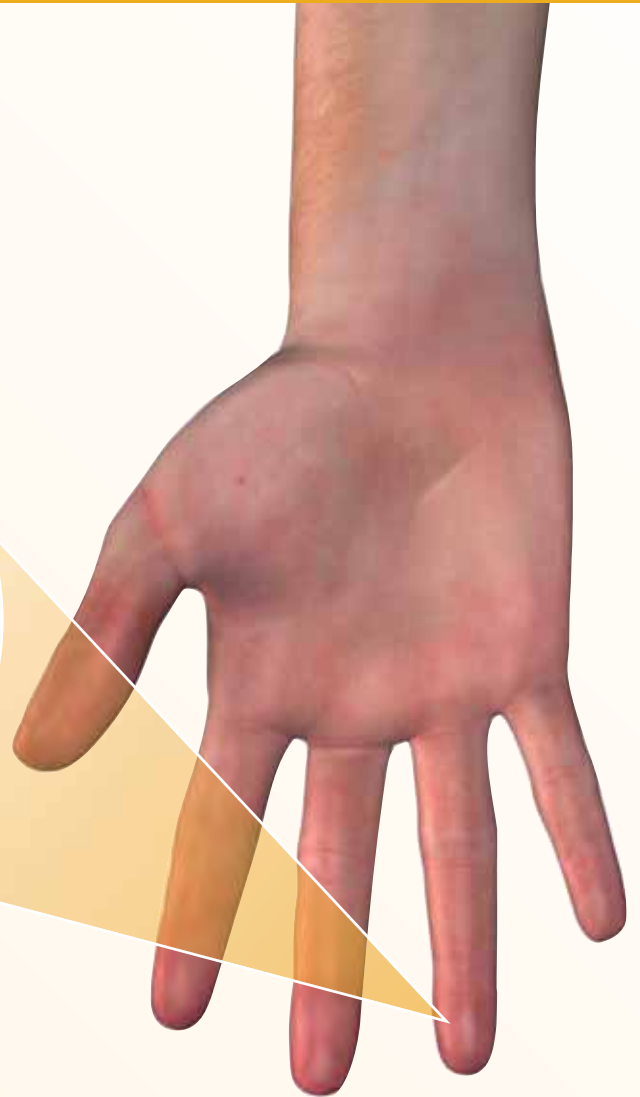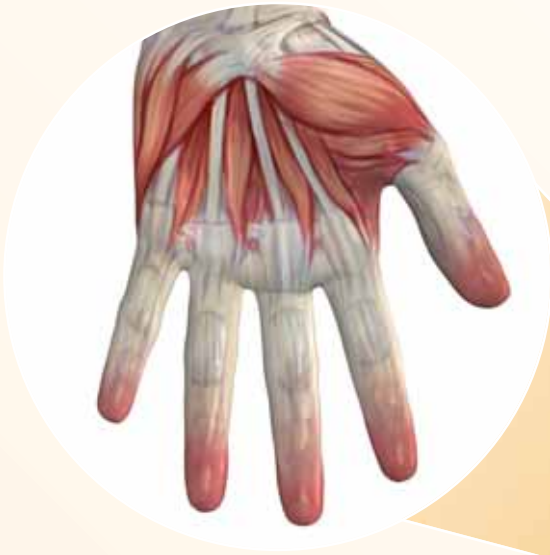Maunait

Maunat

Bout du doigt



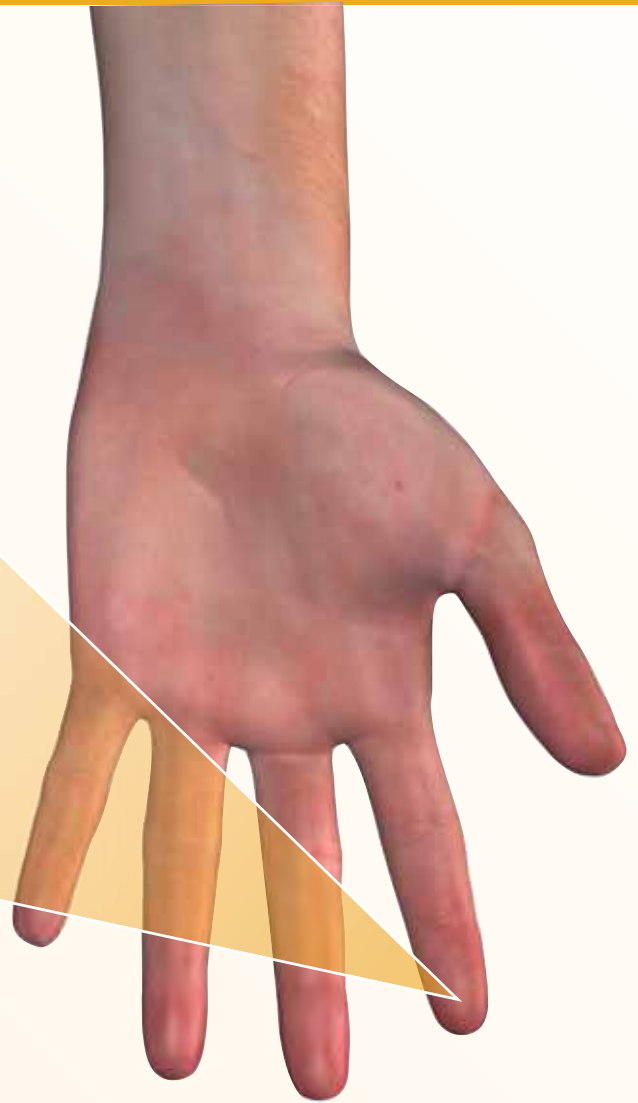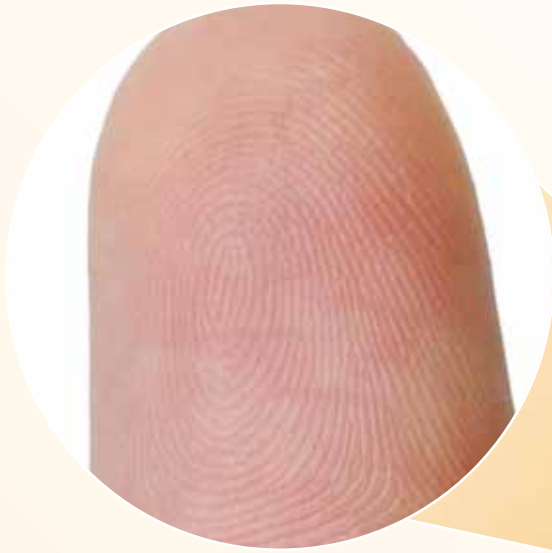# Finger Tip Tissue



ᐱᐅᑲᐅᐅᑦ  
ᐅᑲᐱᑲᑦᑲᑦᑲᑦᑲᑦᑲᑦᑲᑦᑲᑦᑲᑦ

Maunait  
Ikpingnirrarrigutingit  
Puudjuutip Ipait  
Pulpe du doigt

# Fingerprint



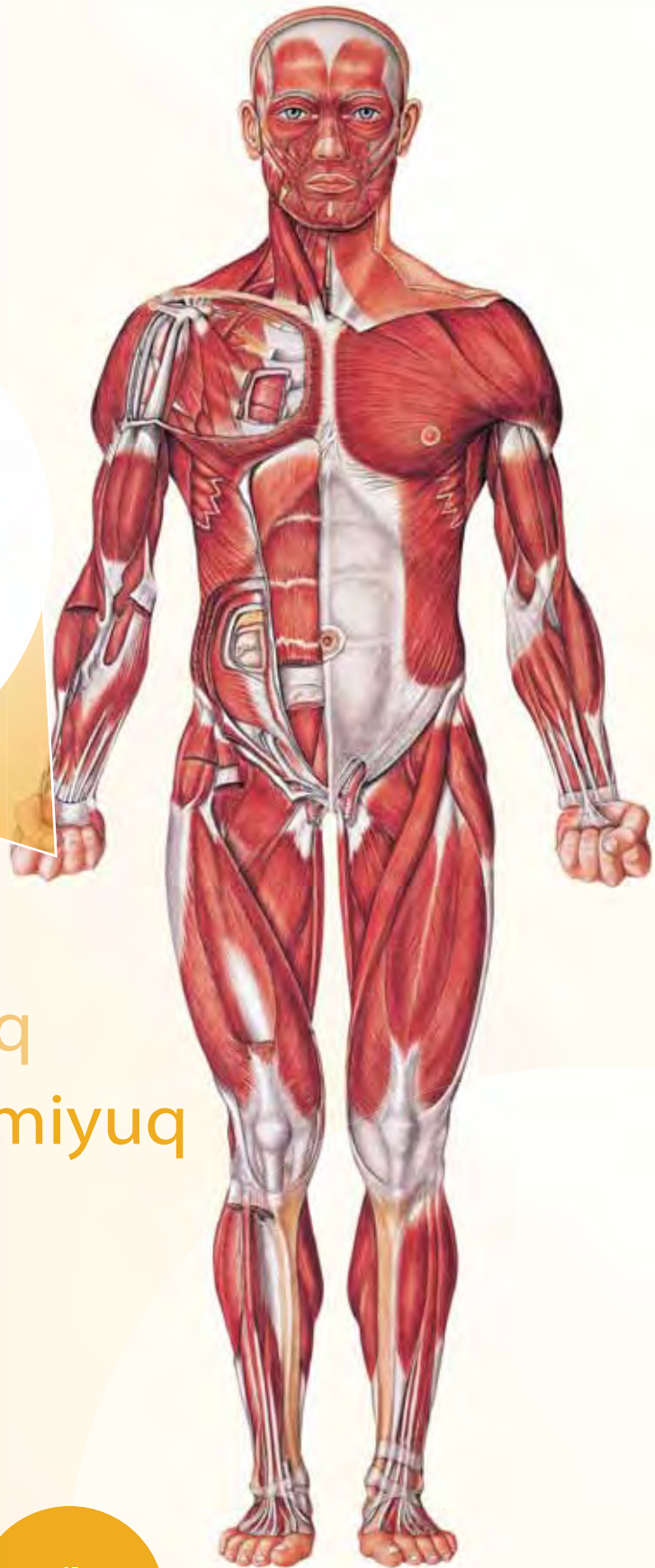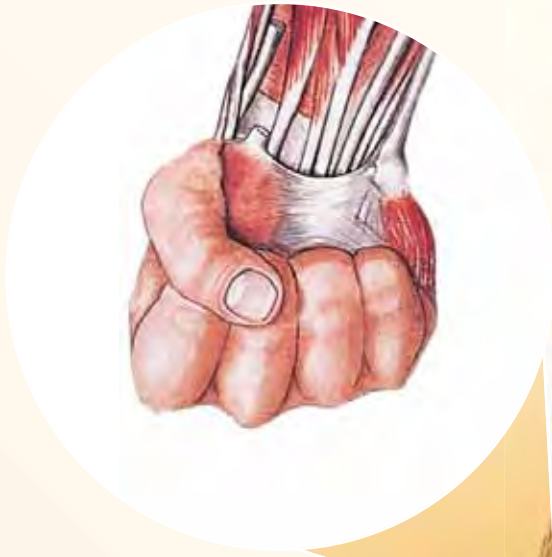
σ▷L<sup>b</sup>

Niumak

Algaup Ipait

Empreinte  
digitale

# Fist



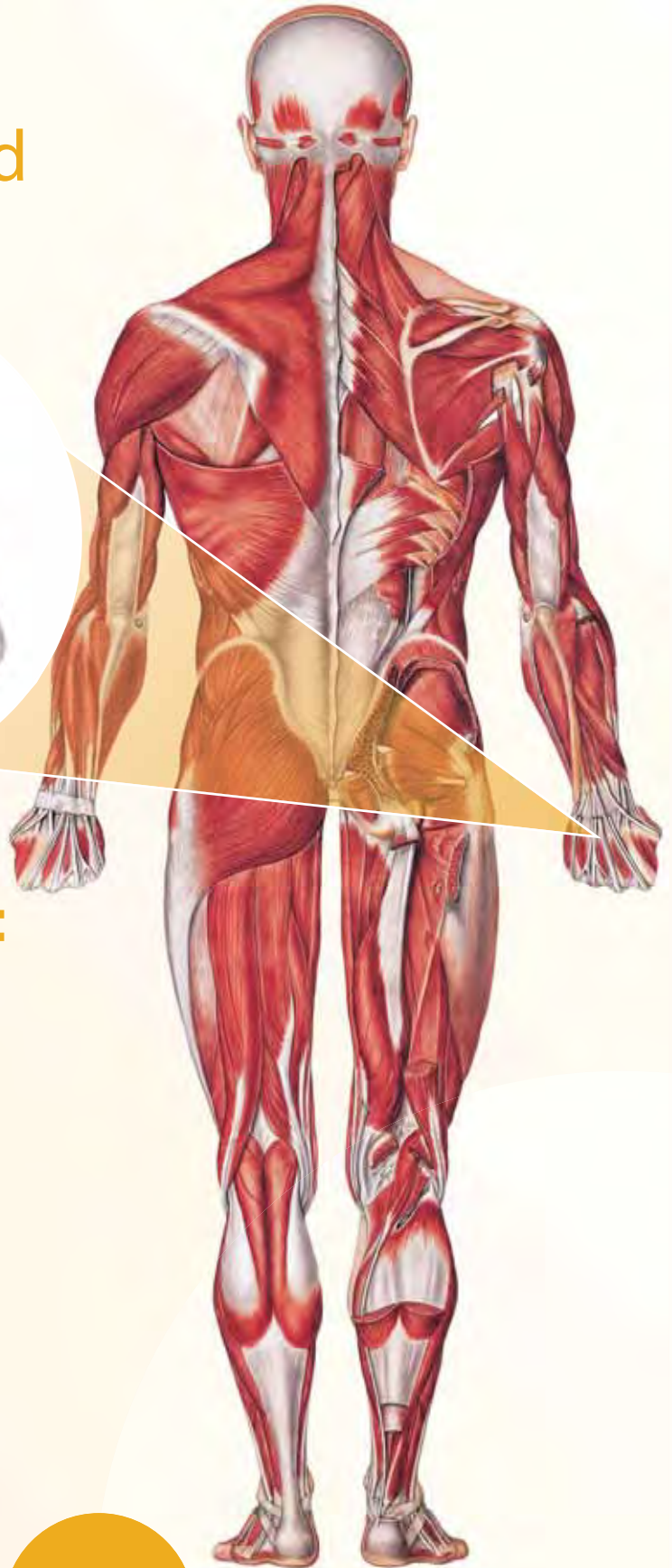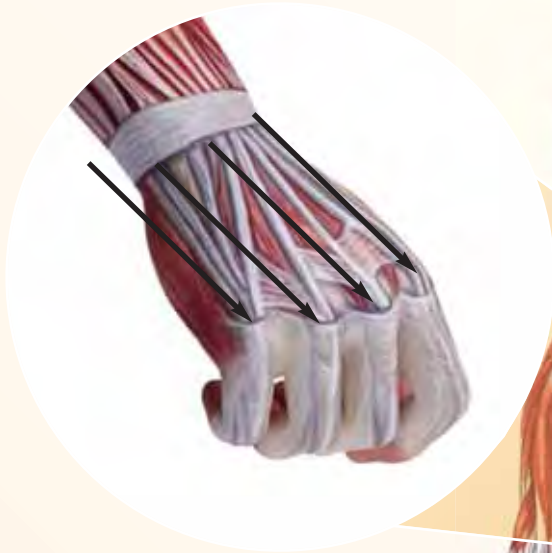
ᠨᠵᠯᠦᠷᠠᠭᠦᠨ

Tigummijuq

Algak Iqimmiyuq

Poing

# Flexion of the Hand



Δἰρῶσῶσ

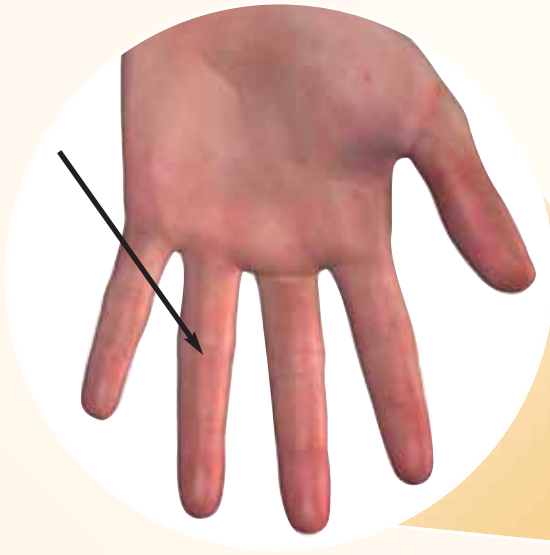Iqittarniit

Iqitaqtuq

Flexion

de la main

# Fourth Finger



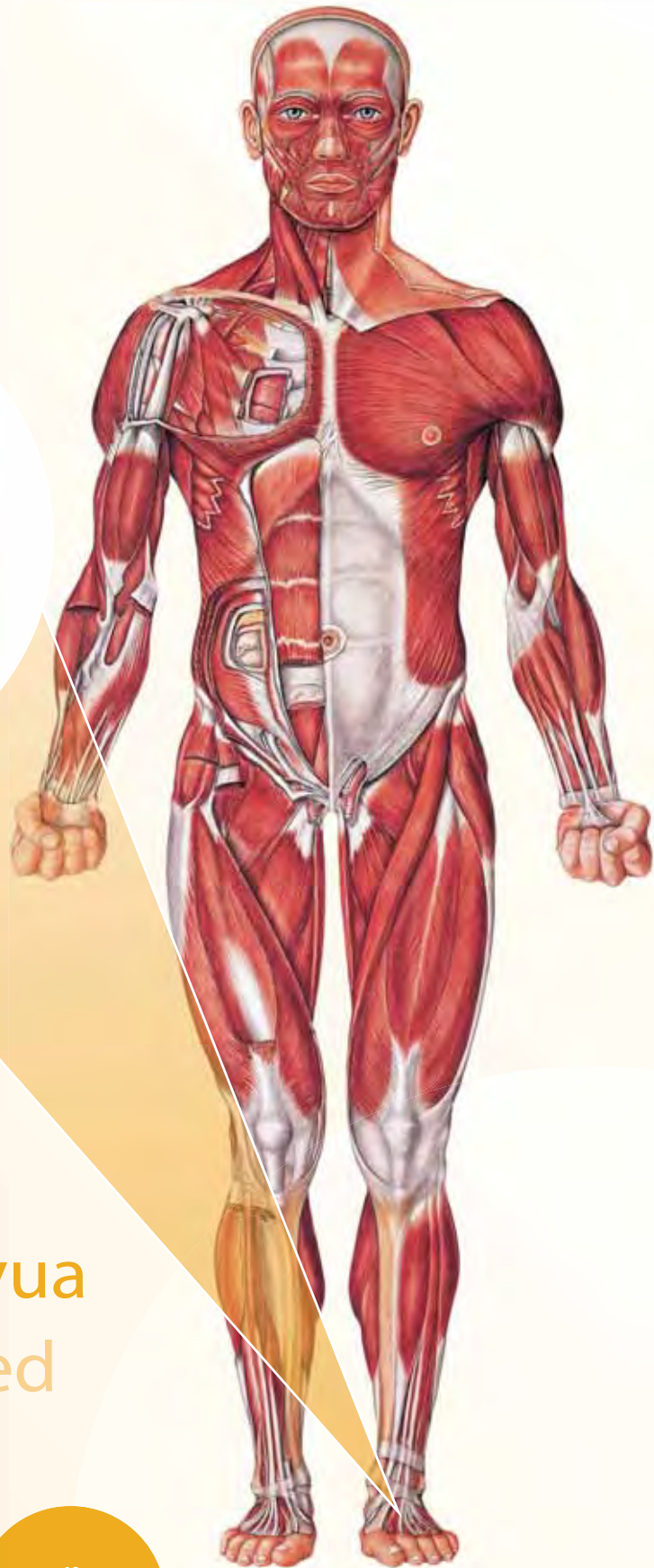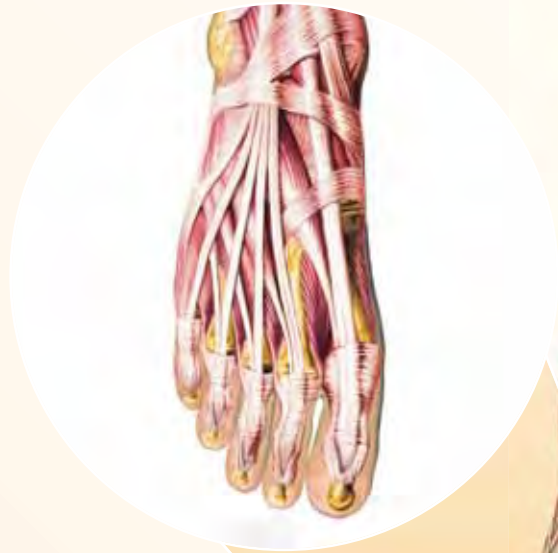ΓΡϸϻᵇ

Mikiliraq

Mikiliraq

Annulaire

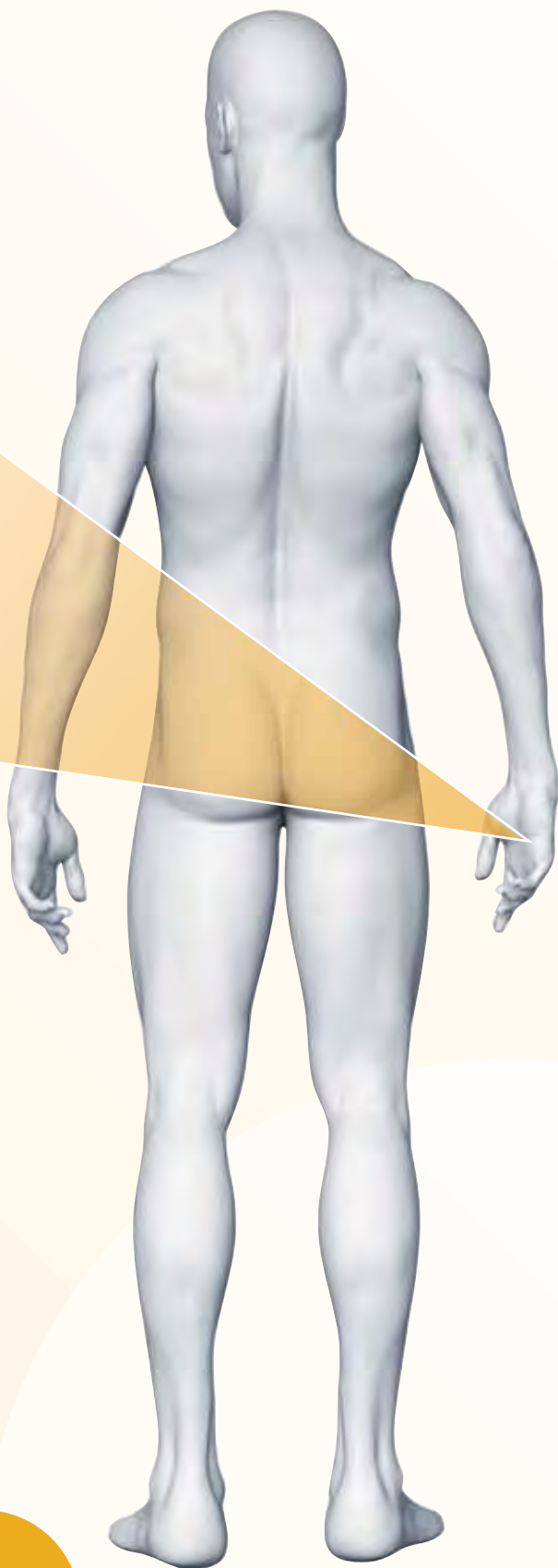# Front of the Foot



ΔΡΛΔ<  
ἴβ<ρσ<λ

Isigaup  
Qallininga  
Itikkap Nuvua  
Bout du pied

# Hand Edge



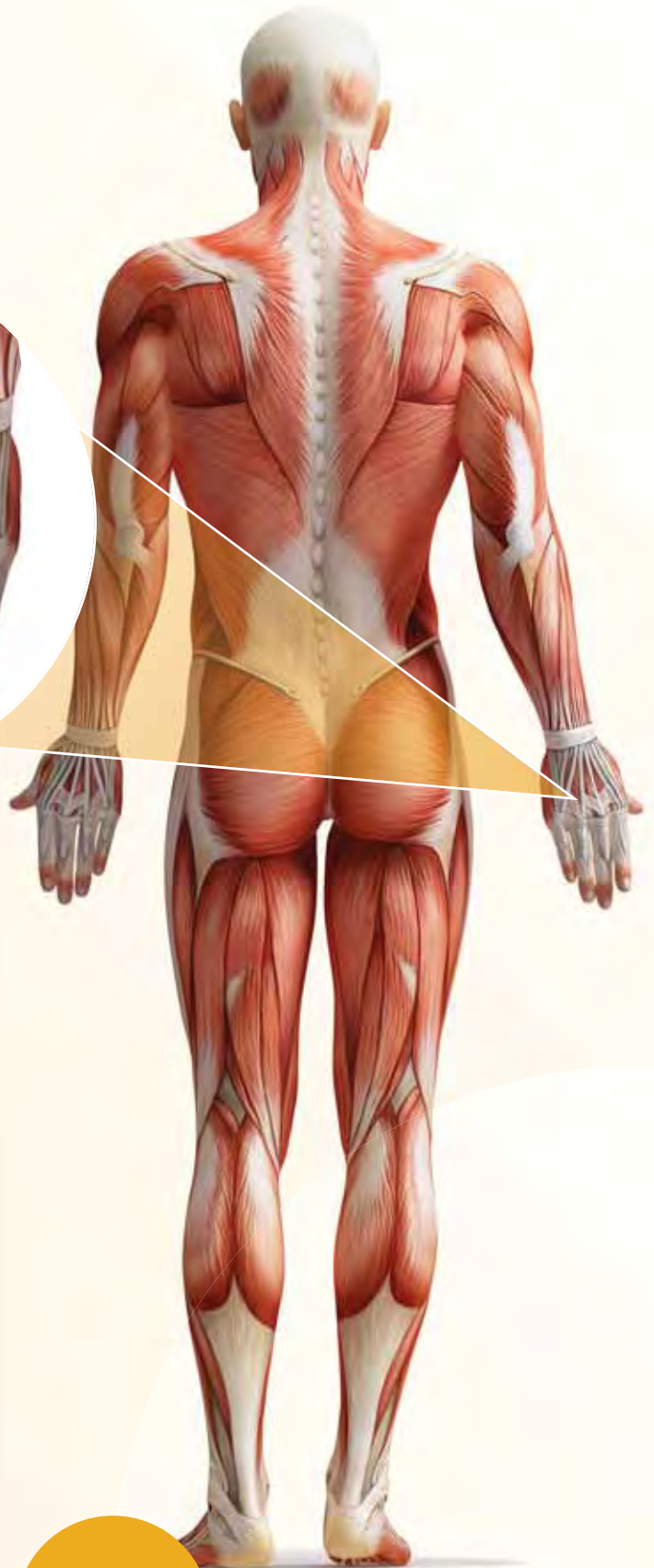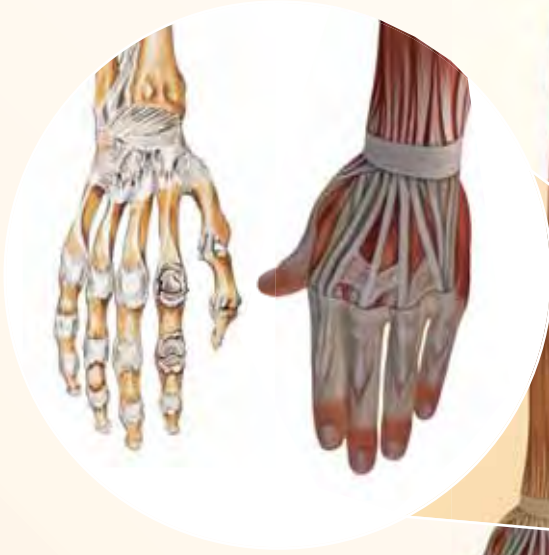ᐱᕐᕐᕐᕐᕐ  
ᐱᕐᕐᕐᕐᕐ

Aggaup  
Arvanga

Arvaq

Tranchant  
de la main

# Hands



◀◡◢◣◤◥

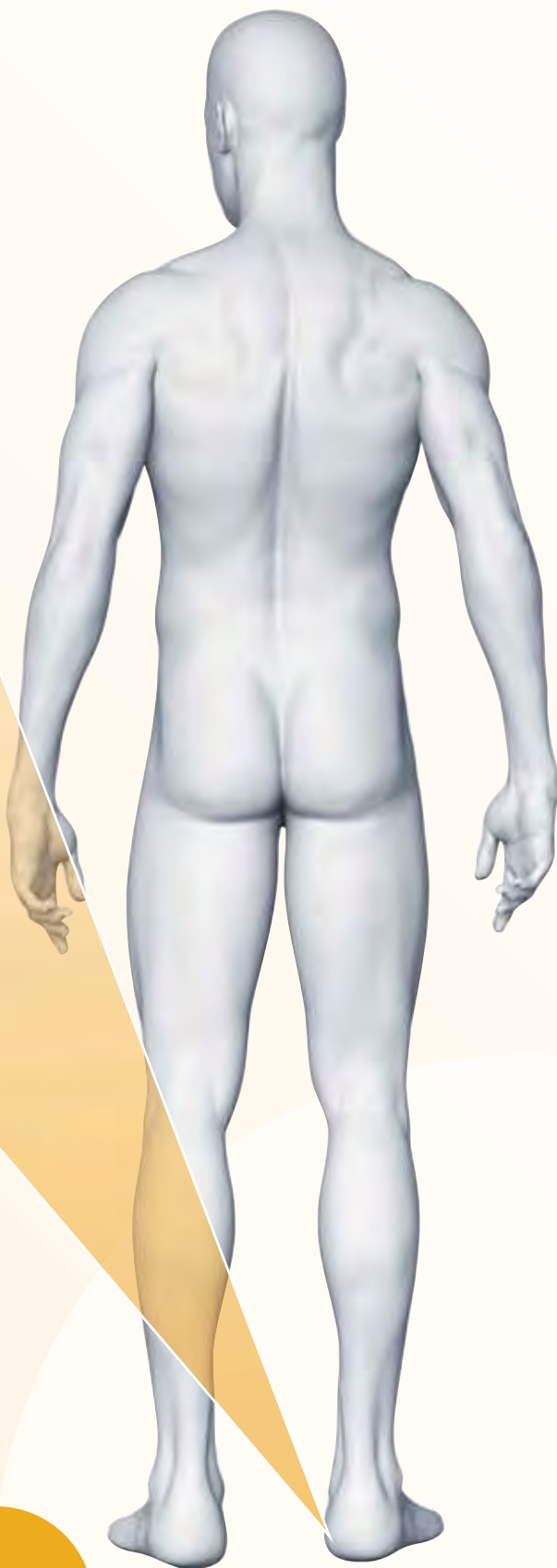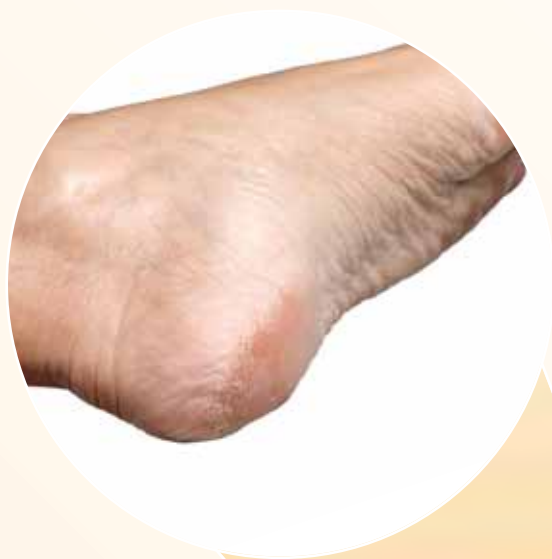Aggait

Algak

Mains



# Heel/ Back



ԲՆԴԵ

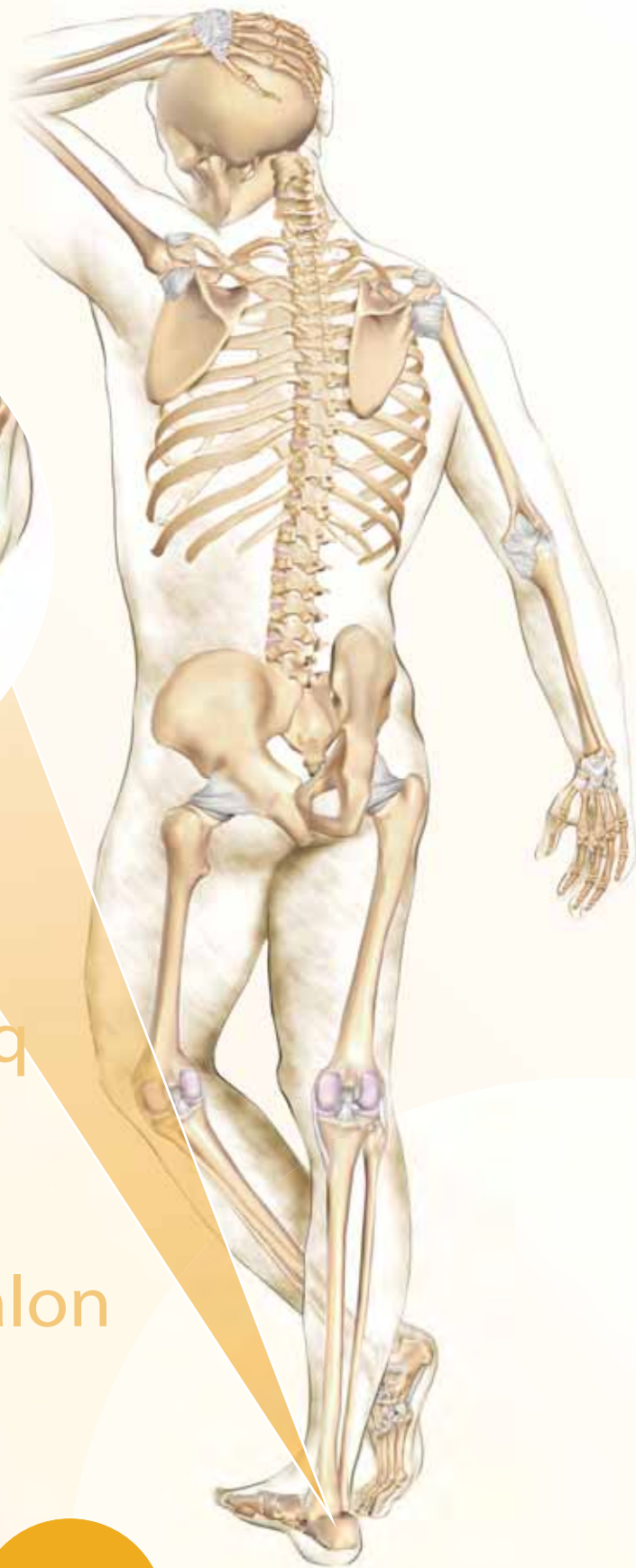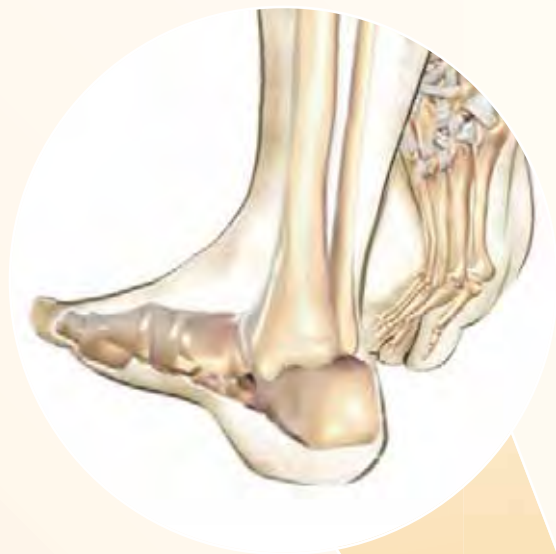Kingmik

Kingmitquq

Talon

(postérieur)

# Heel Hump



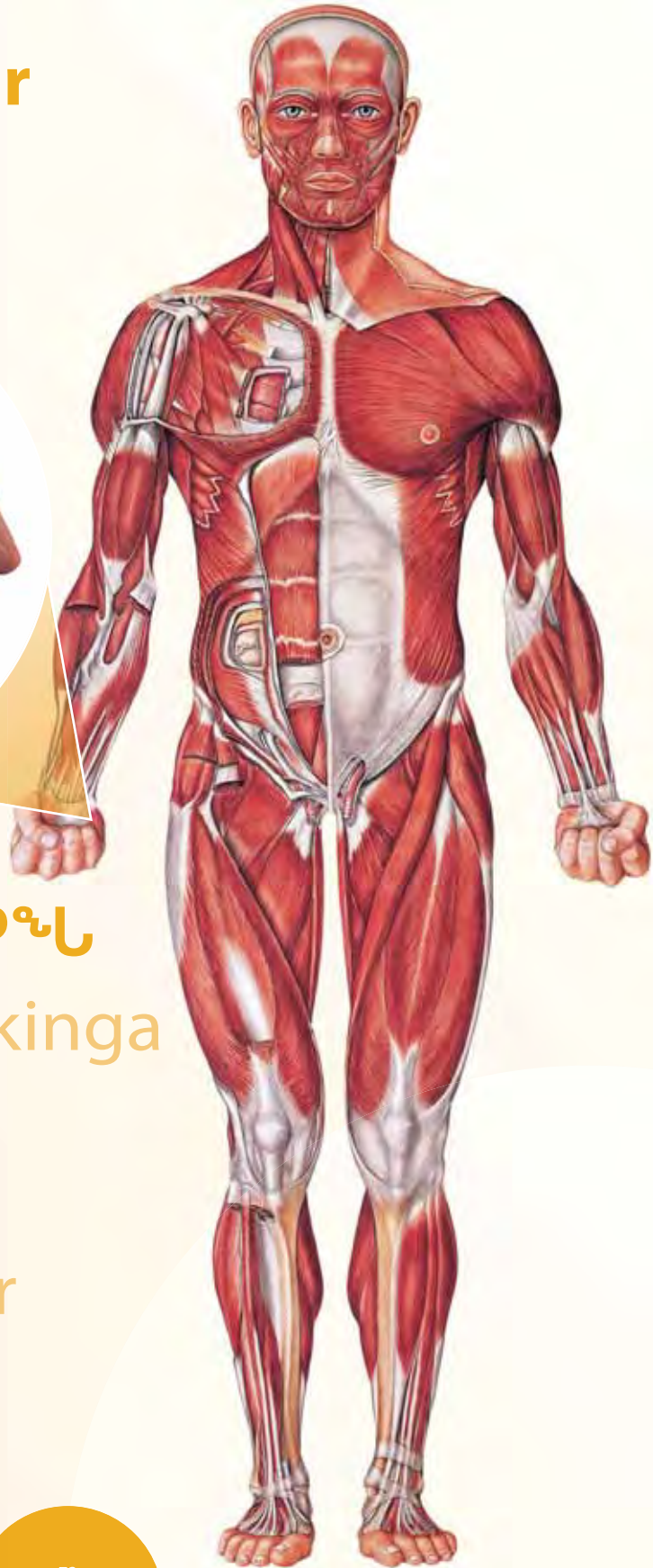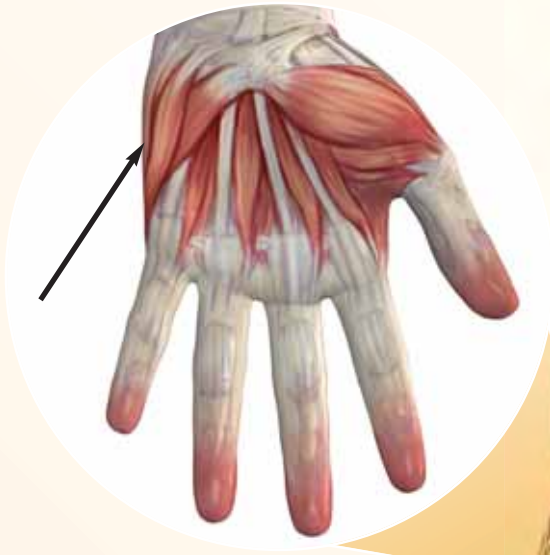ᐃᐃᐃᐃᐃᐃᐃᐃ

Kingmiqquq

Hingirniup  
lhuglua

Bosse du talon

# Hypothenar



Արձապ Նուկինգա

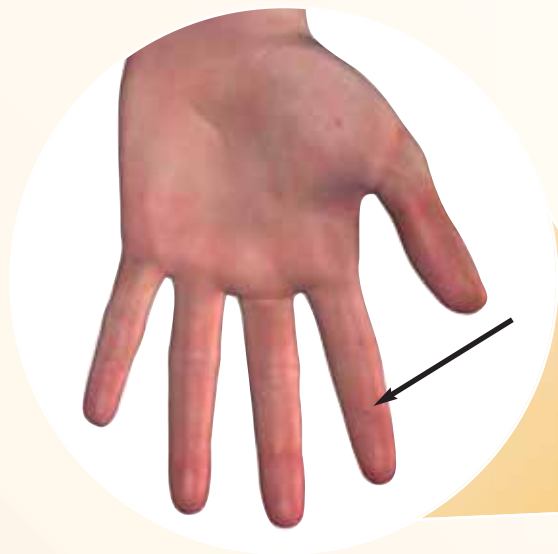Arvaup Nukinga

Arvaq

Éminence

hypothénar

# Index Finger



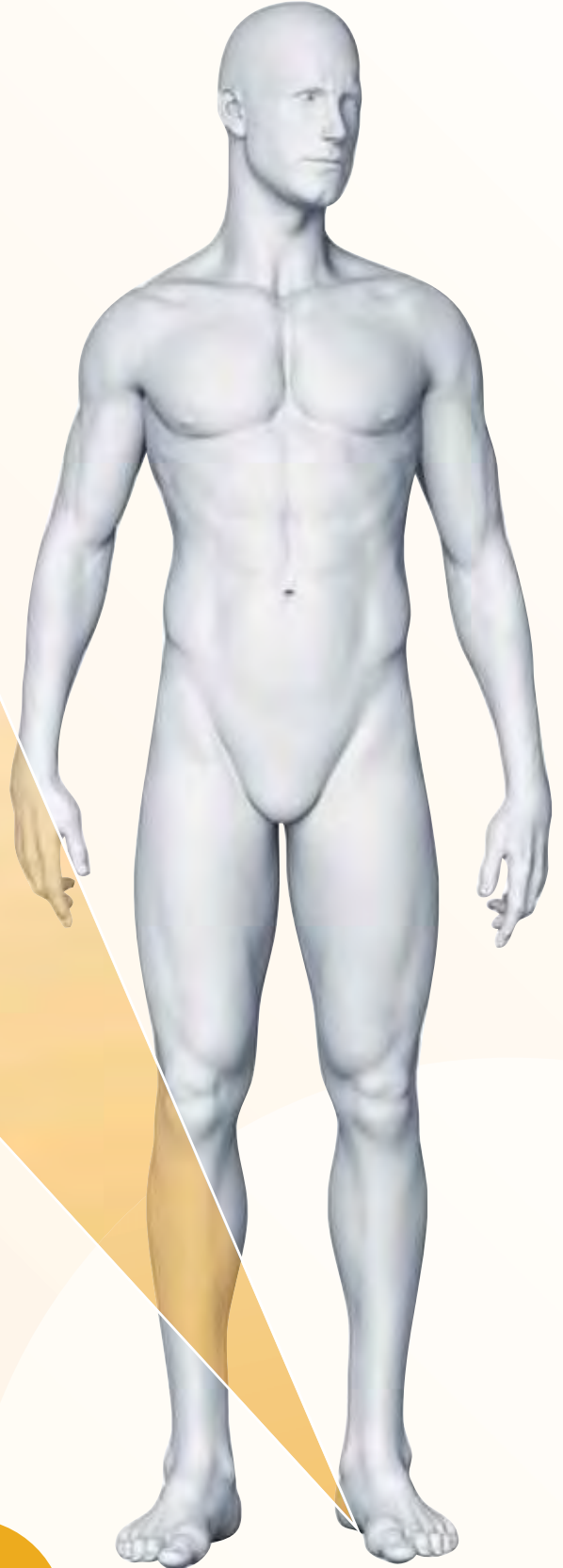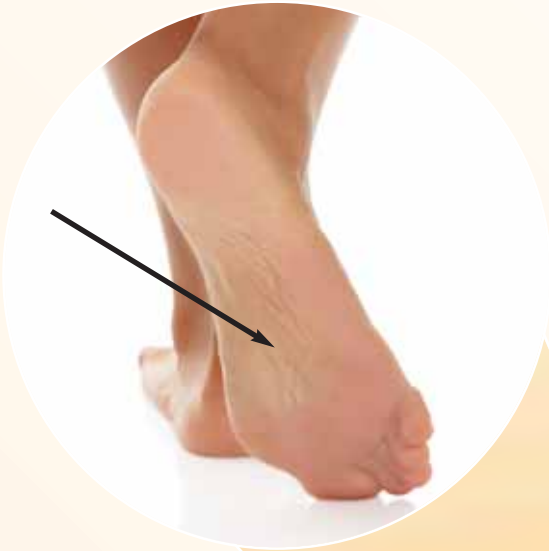ИРҶБ

Tikiq

Tikiq

Deuxième  
pouce

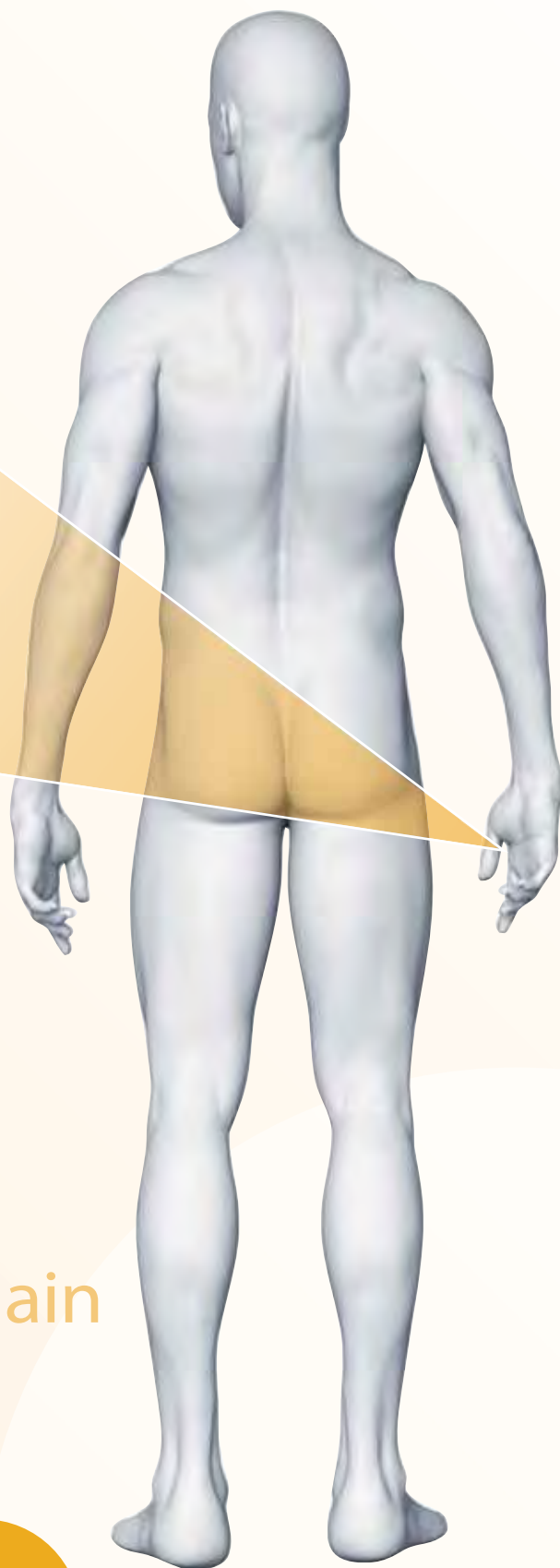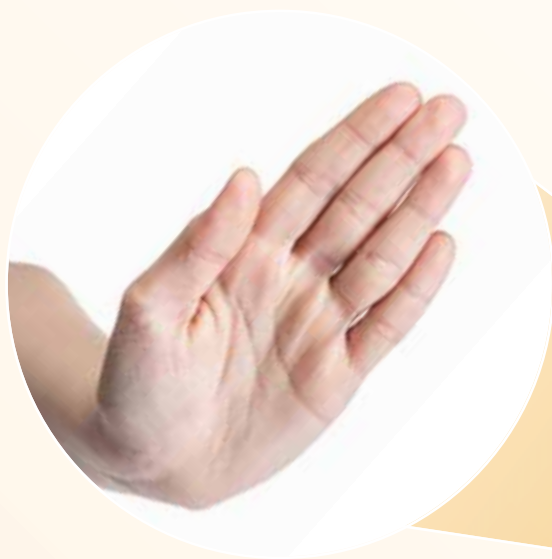# Instep



ᐱᓂᑦᑦ  
ᐱᓂᑦᑦᑦᑦᑦᑦᑦᑦᑦᑦ

Alurmi  
ilangiumaniq  
Itigaup Alua  
Cou-de-pied

# Lines of the Hand



ᐱᐅᐅᐅᐅᐅ

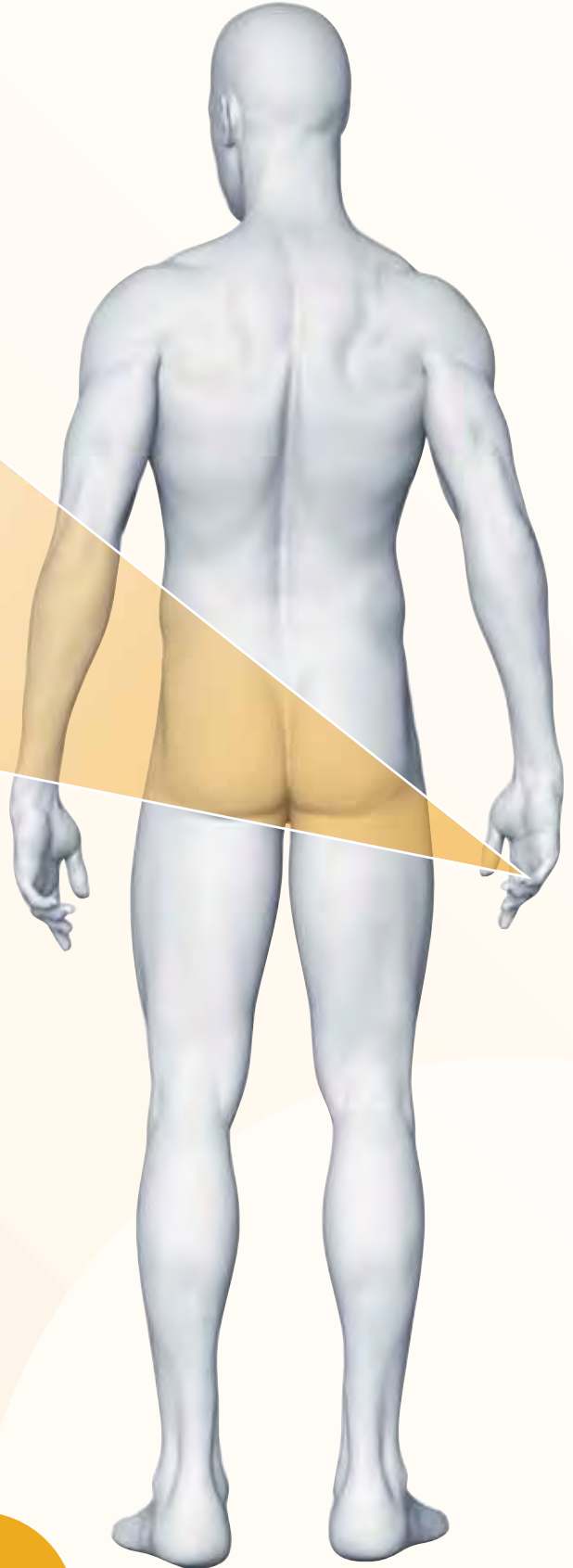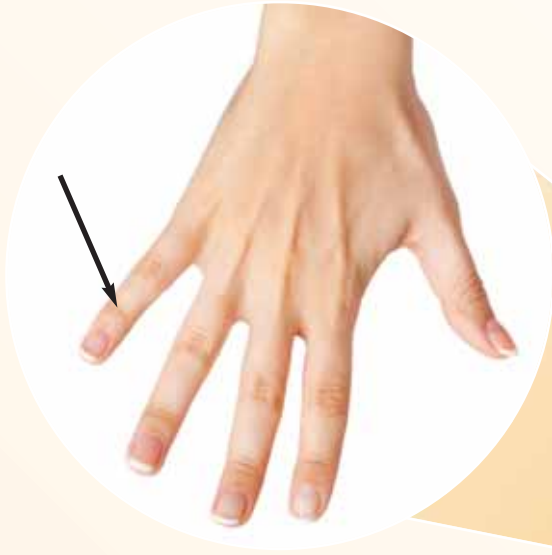Savuujaq

Itimaup

Iqinganiit

Lignes de la main

# Little Finger



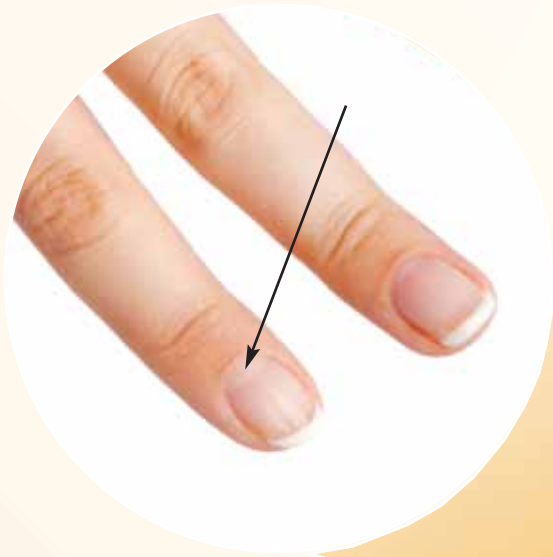Δ ς ρ ς β ρ ς β

lqiqquq

lqitquq

Auriculaire

# Lunule / Half-Moon of Finger Nail



ᑳᑭᑭᑭᑭ

ᑭᑭᑭᑭᑭᑭᑭᑭ

Kukiup

Qaullurninga

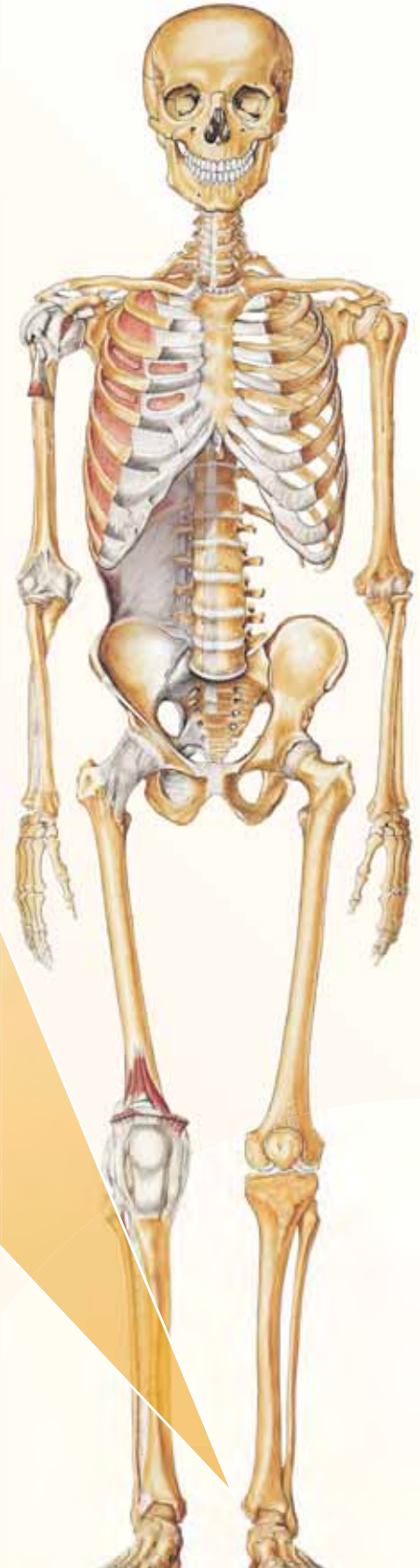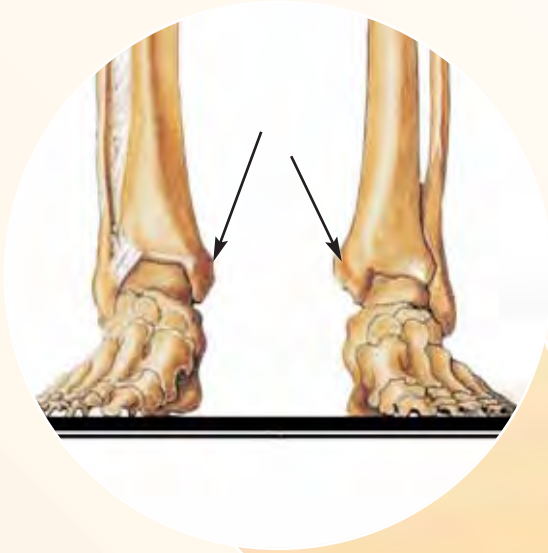
Kukiup

Qangatania

Lunule



# Malleous



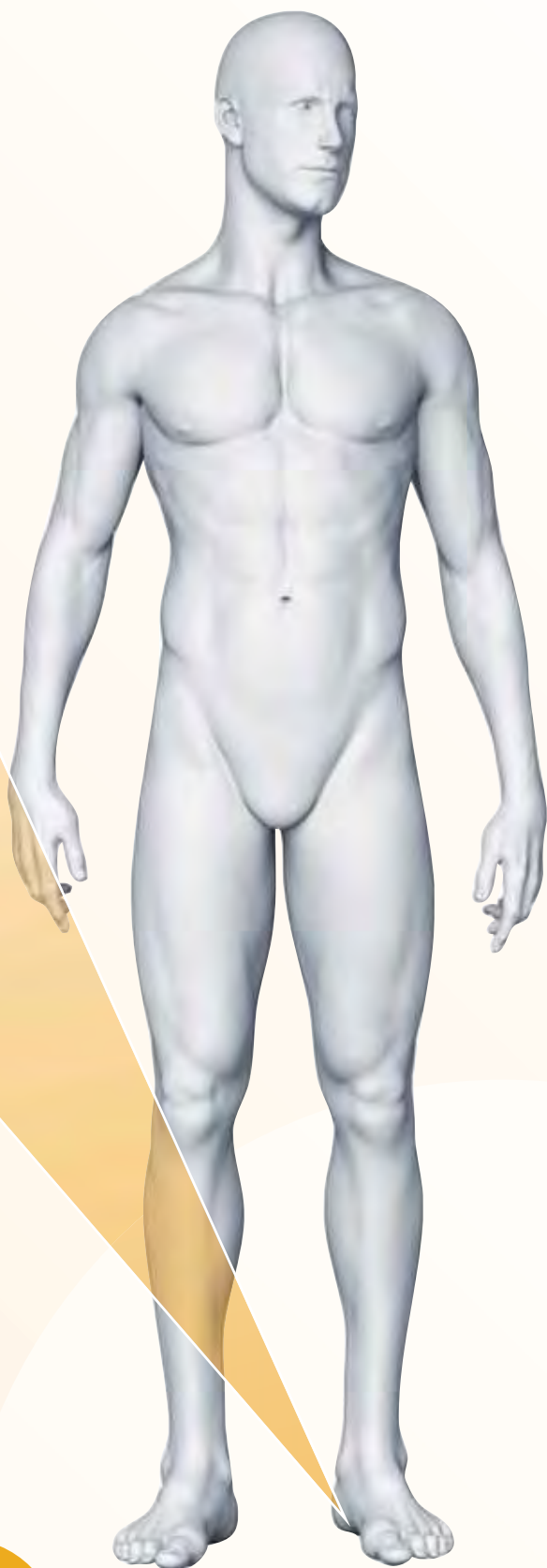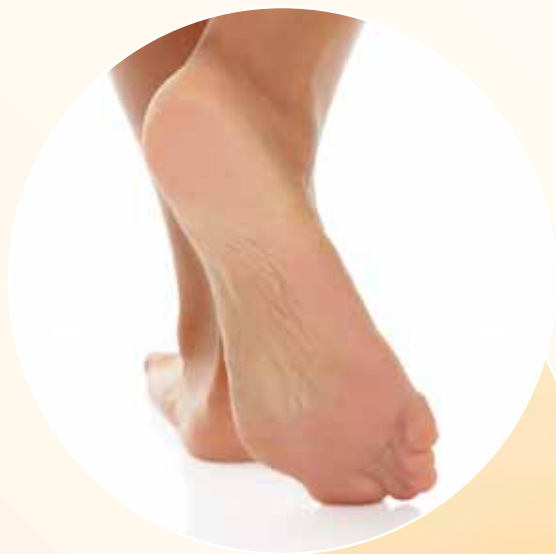ᠠᠨᠨᠭᠠᠴ

Qanngaq

Hingirniq

Cheville

# Middle of the Sole of the Foot



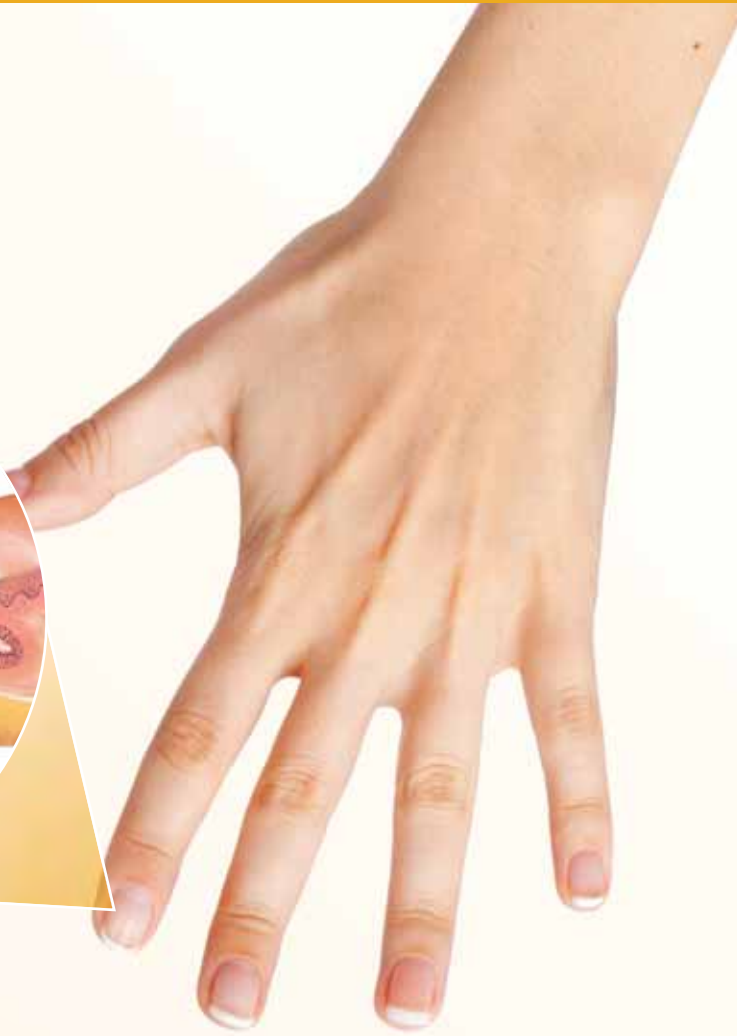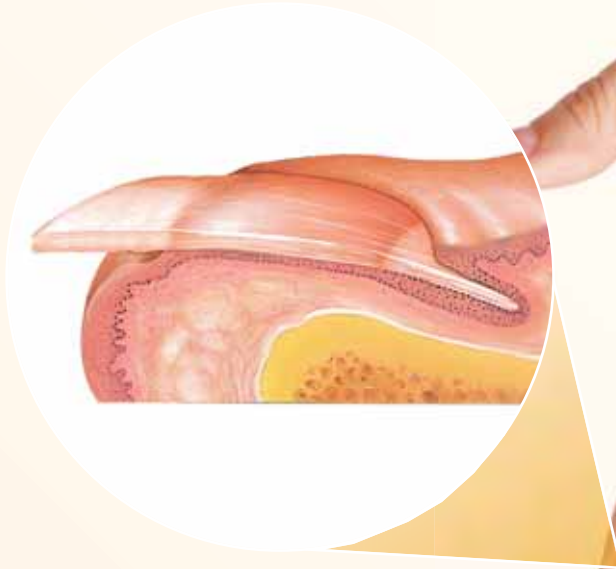
σῆΛσῆῆ

Nirimaniq

Allup Qitqa

Milieu de la  
plante du pied

# Nail



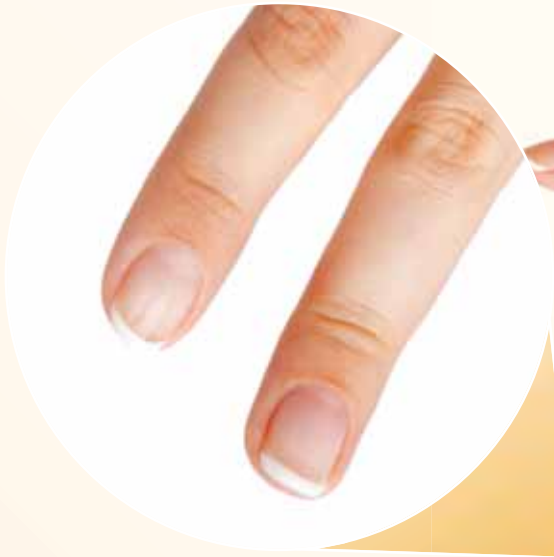дрб

Kukik

Kukik

Ongle

# Nail Tip



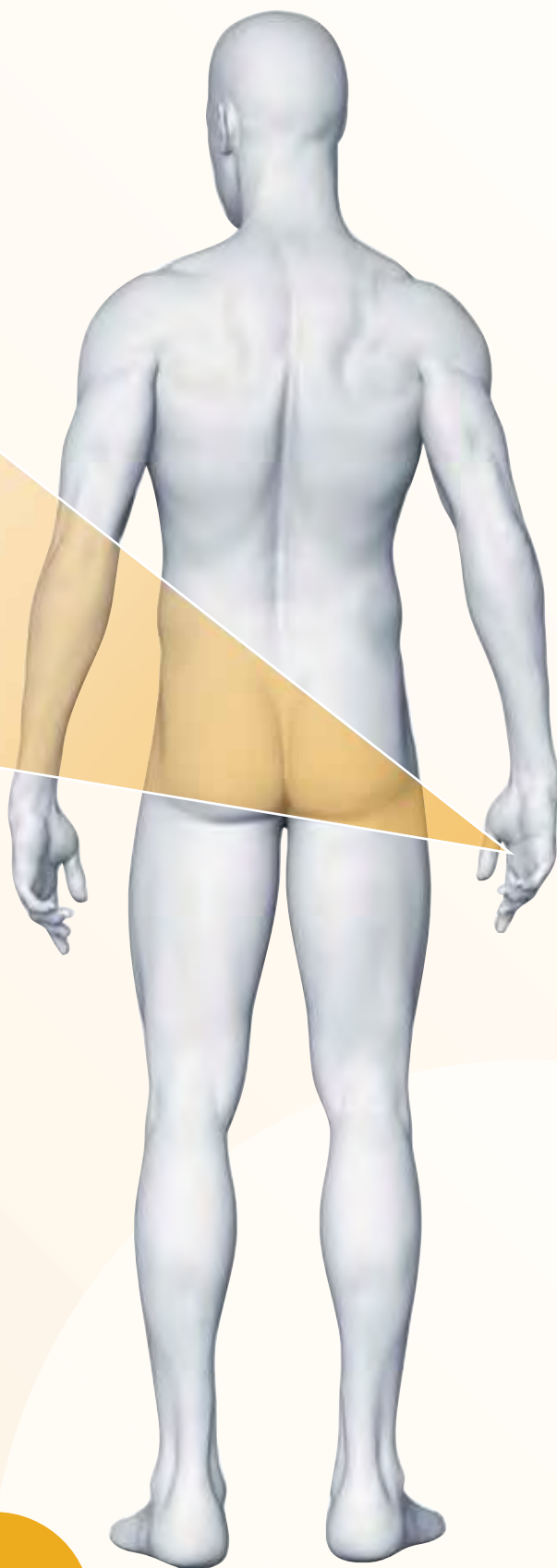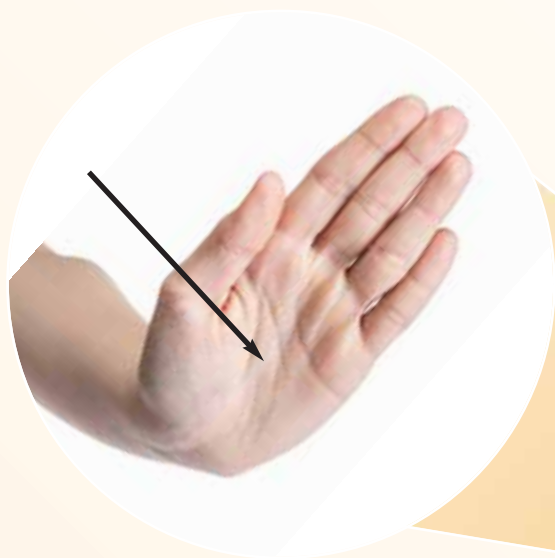ᑲᑭᑭᑭᑭ ᑭᑭᑭ

Kukiup Sinaa

Kukiup Nuvua

Bout de l'ongle

# Palm of the Hand



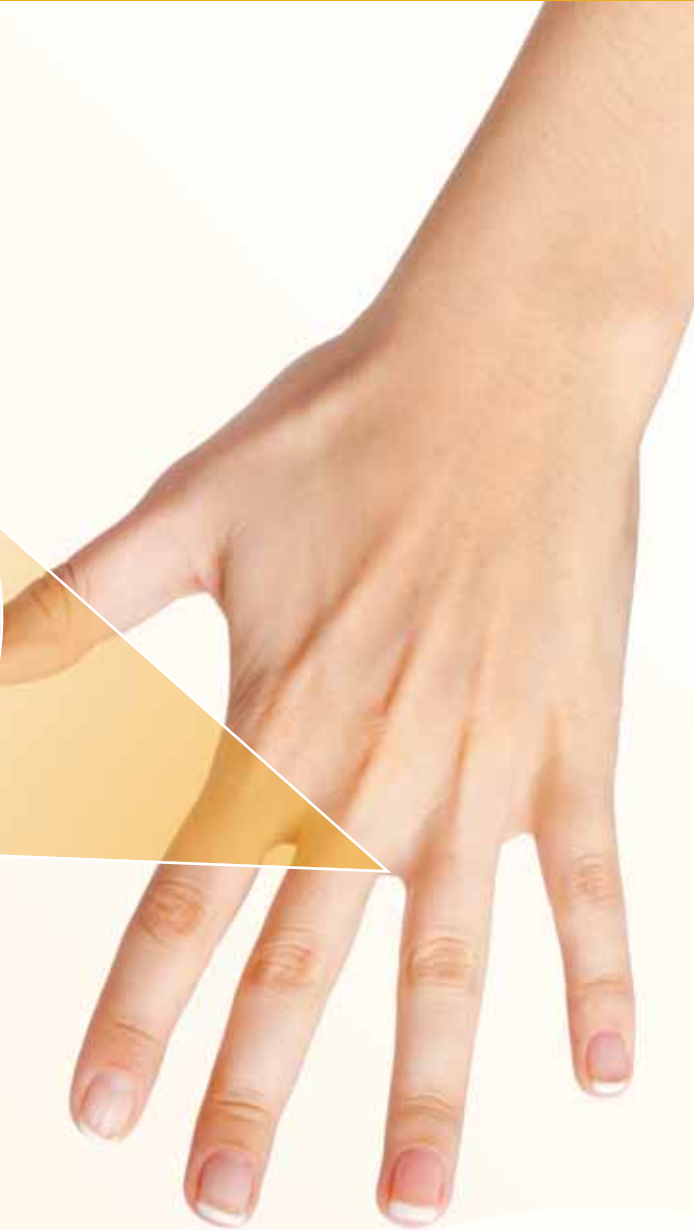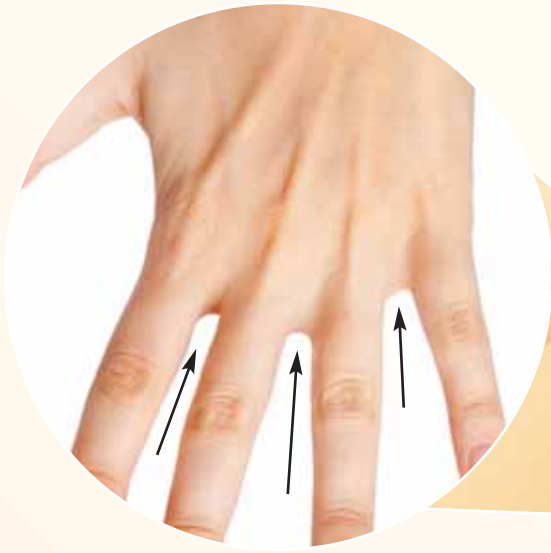ΔΟΛ<sup>6</sup>

Itimak

Itimak

Paume de  
la main

# Part Between Fingers



ᑭᑦᑲᑦᑲᑦᑲᑦᑲᑦᑲᑦ

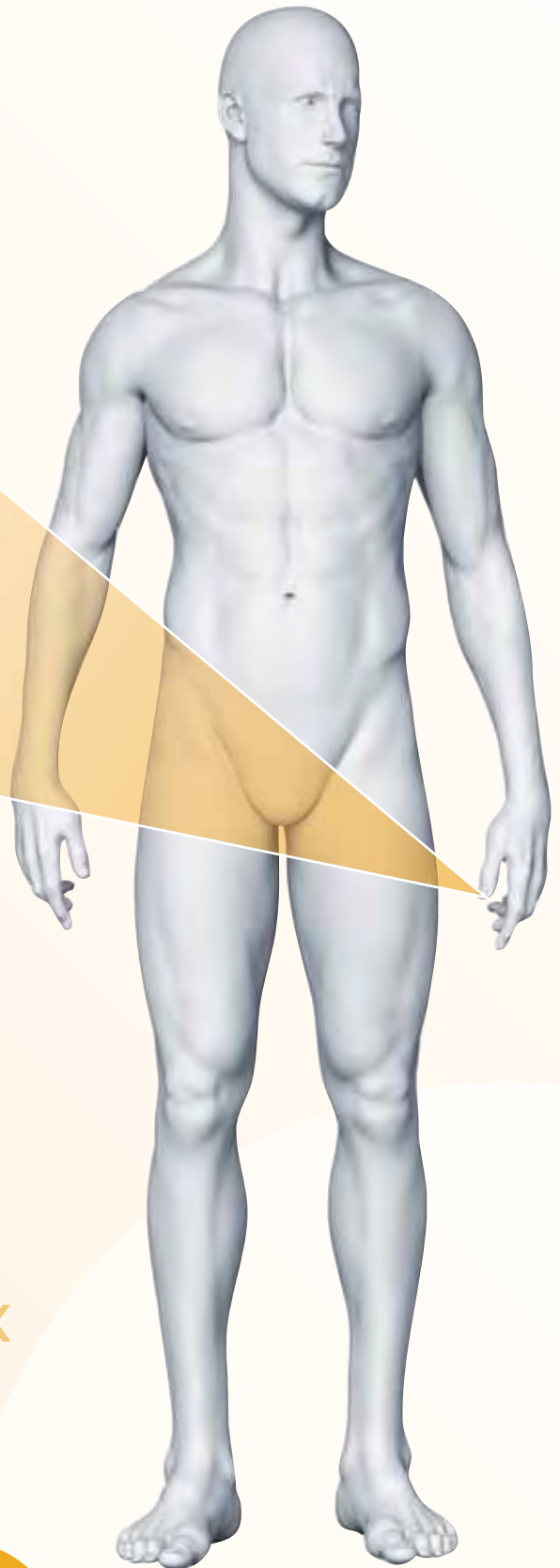Qunnaujaat

Algaup

Quppauyaangit

Entre-Doigts

# Pinscher

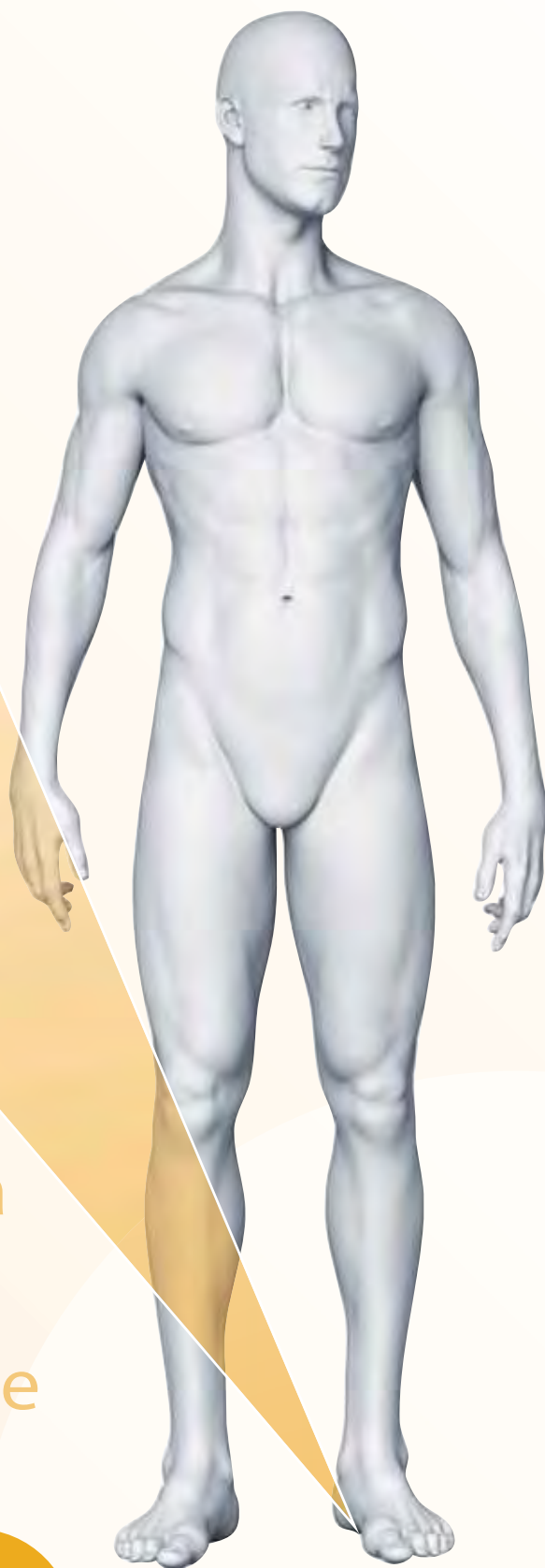
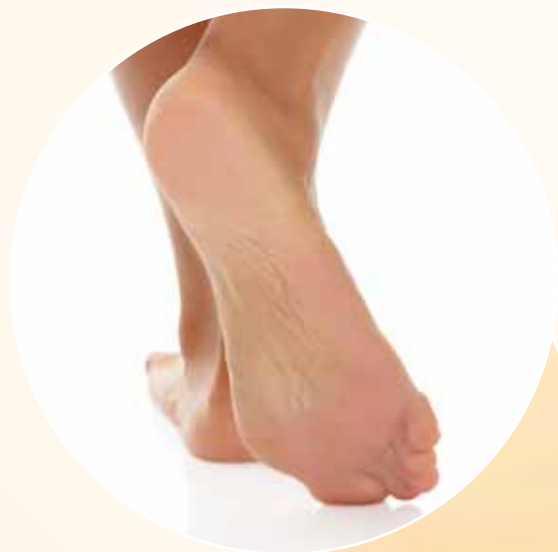
Pujjuk

Puudjuk

Bout du doigt  
pouce et index  
(pince)

# Plantar Arch / Vault

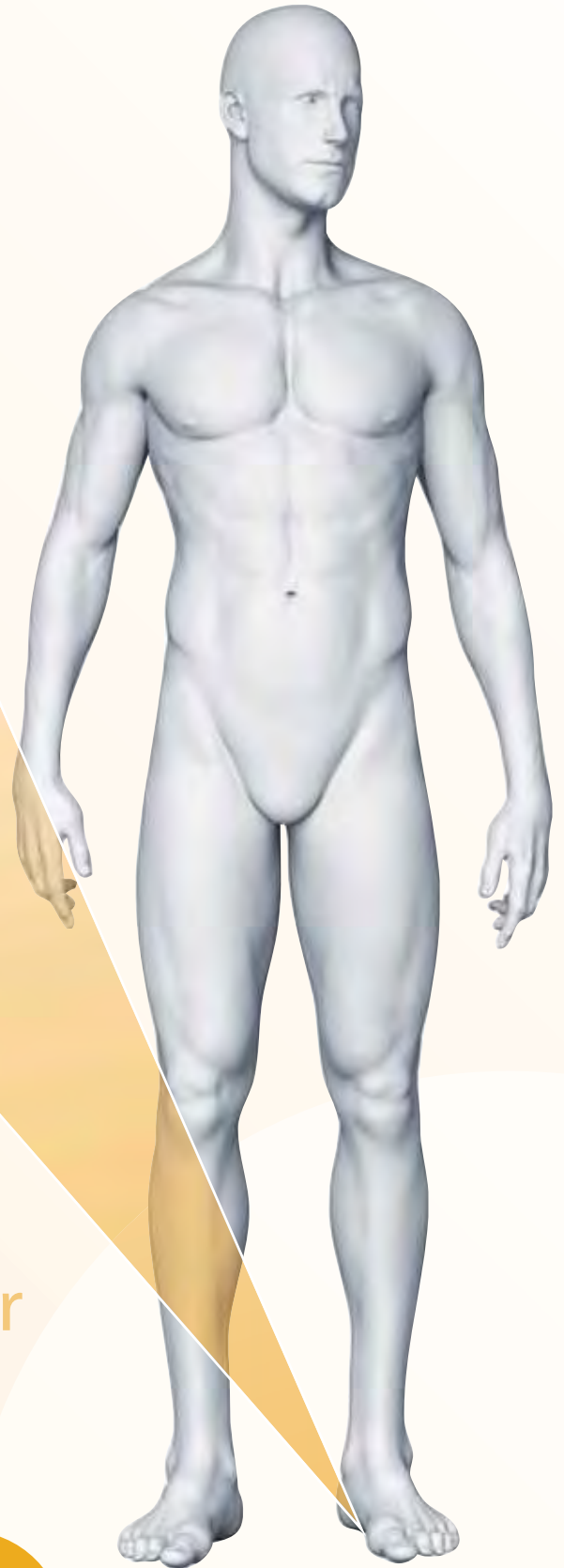
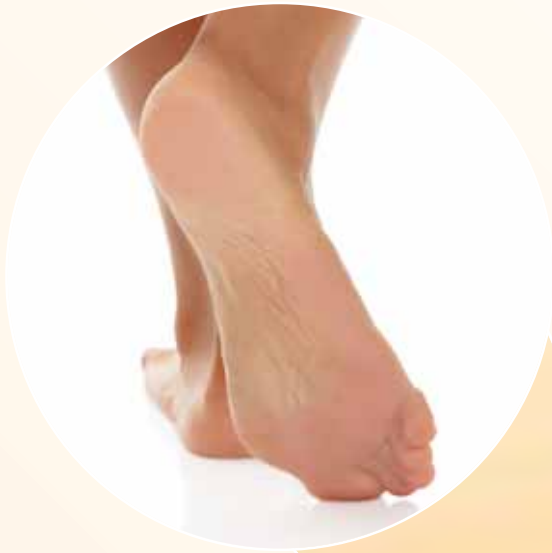
ΔΡΥΣΔ<  
ፍጅግጎርፍጎጎ

Isigaup  
Qangataninga  
Alurnağ  
Voûte plantaire



# Plantar Surface



ᐱᐱᐱᐱᐱᐱ

Aluq

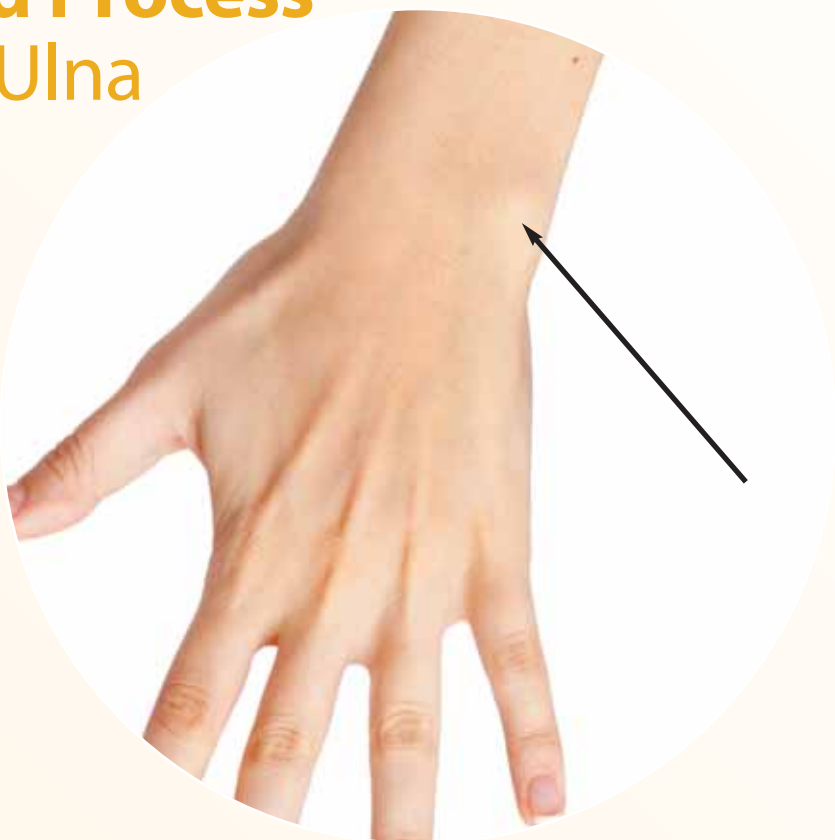Itigaup

Maunaa

Talon antérieur



# Styloid Process of the Ulna



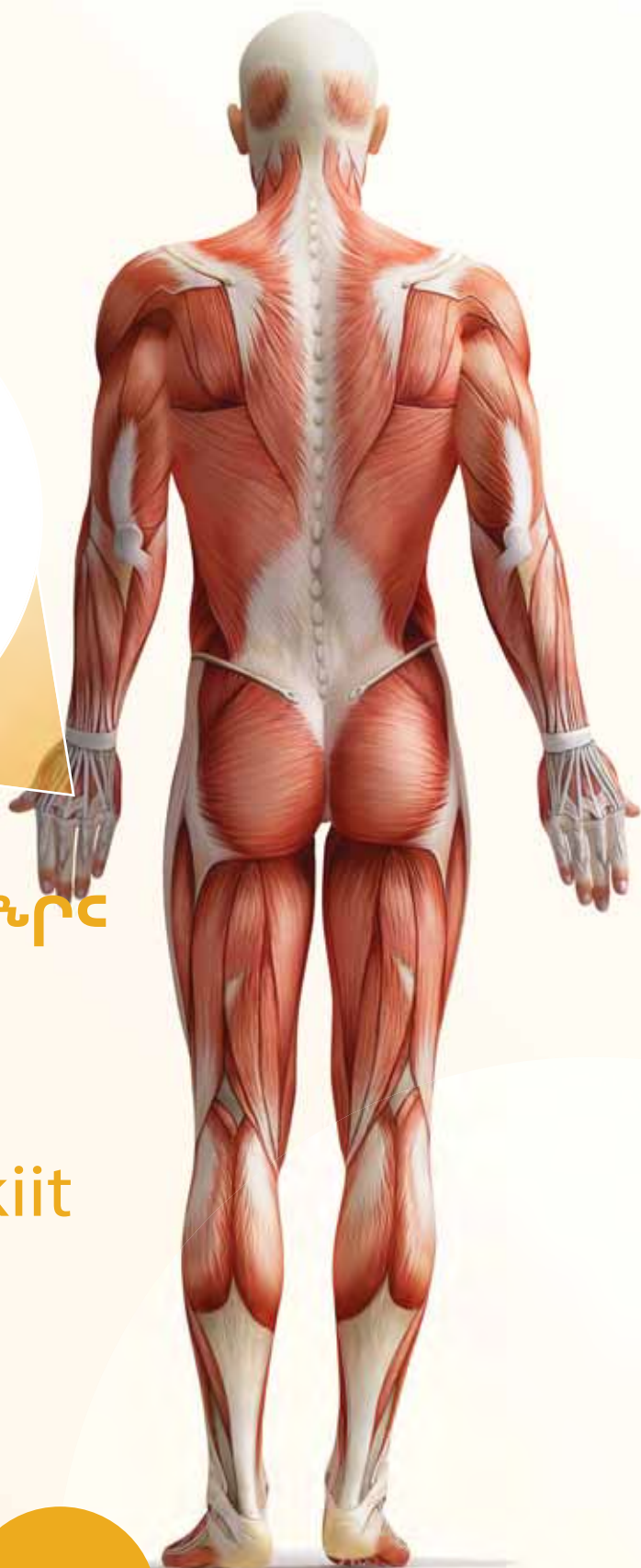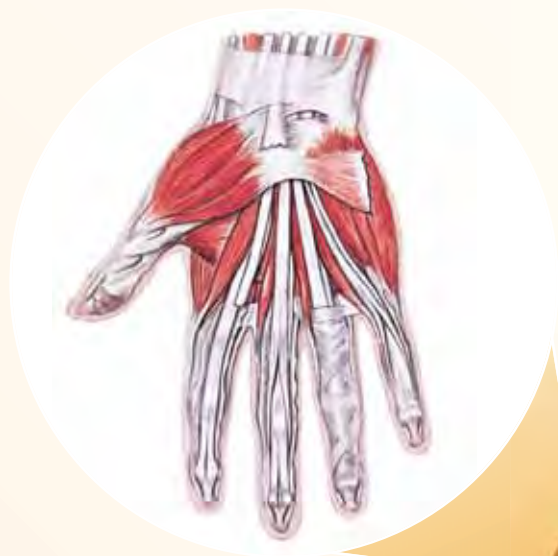ᐱᕐᕐᕐᕐᕐ  
ᕐᕐᕐᕐᕐᕐᕐ

Aggaummi  
Qattingniq

Algautip Ihuglua

Bosse du poignet  
(tête de l'ulna)

# Tendon of the Hand



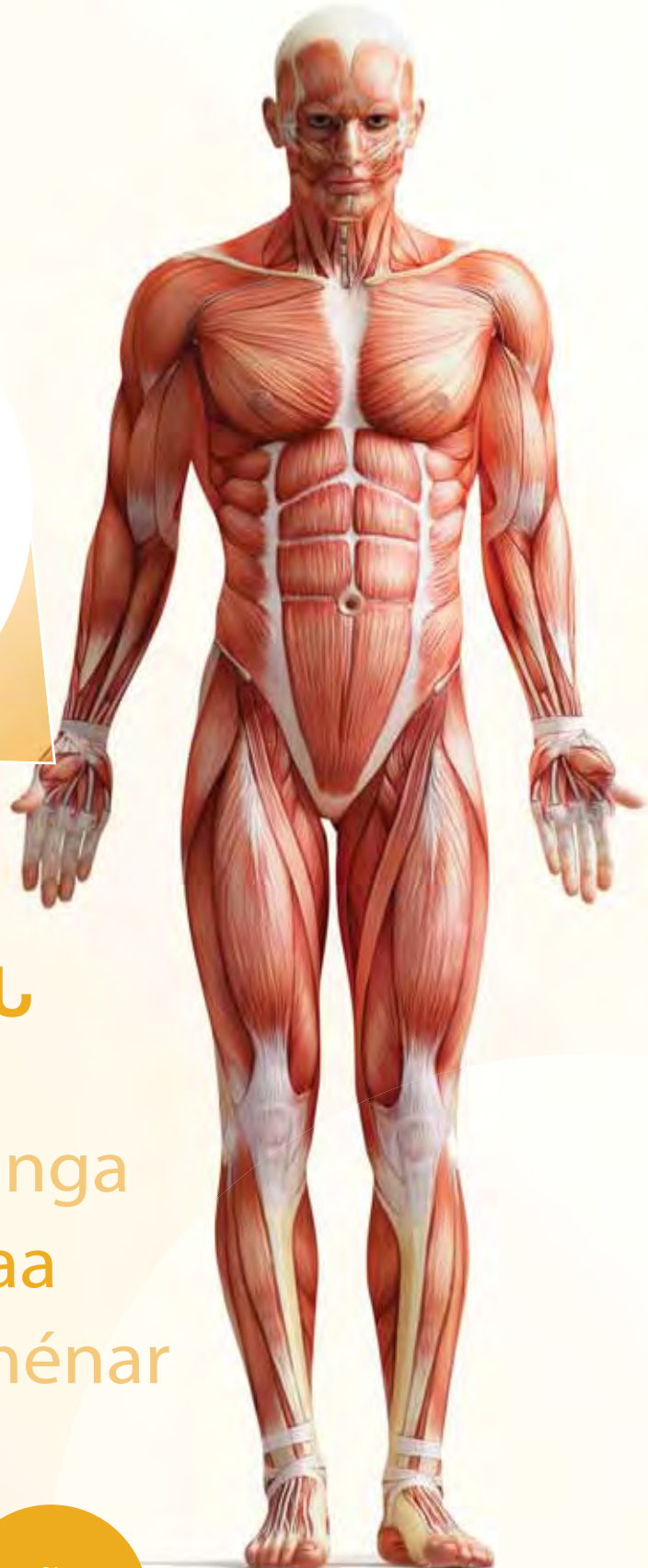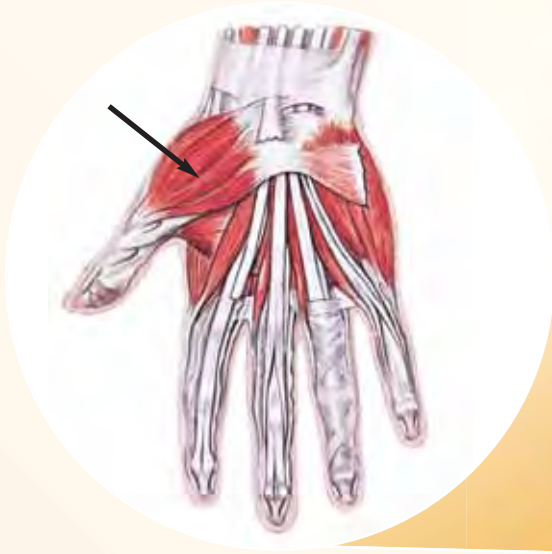ᐱᕐᕐᕐᕐᕐᕐ ᐃᕐᕐᕐᕐᕐᕐ

Aggaup  
Nukingit

Algaup Nukiit

Tendon de  
la main

# Muscle Thenar



ԺԷՀՁ

ՏԳԵԵՆԸՍՏՄԵՆ

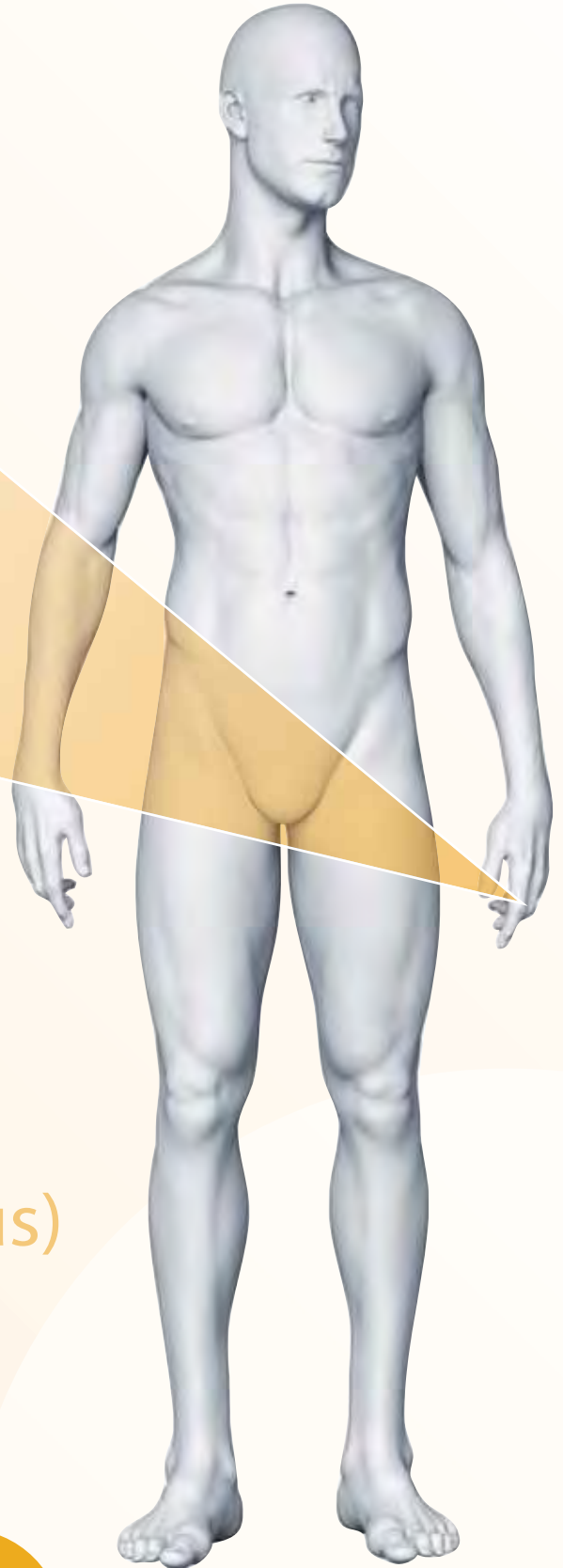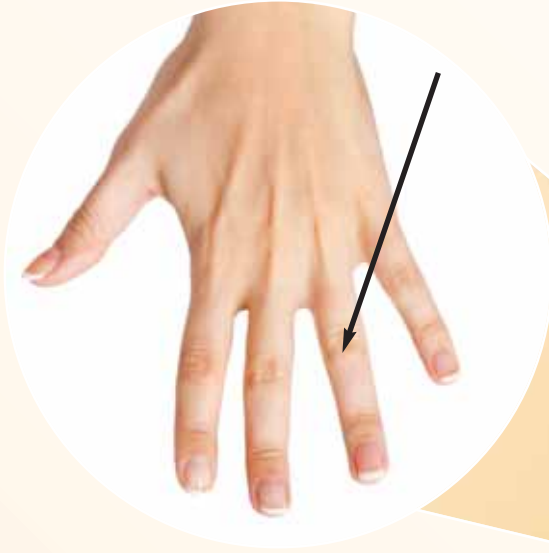Kulluup

Niqqaringninga

Kublup Niqaa

Éminence thénar

# Third Finger



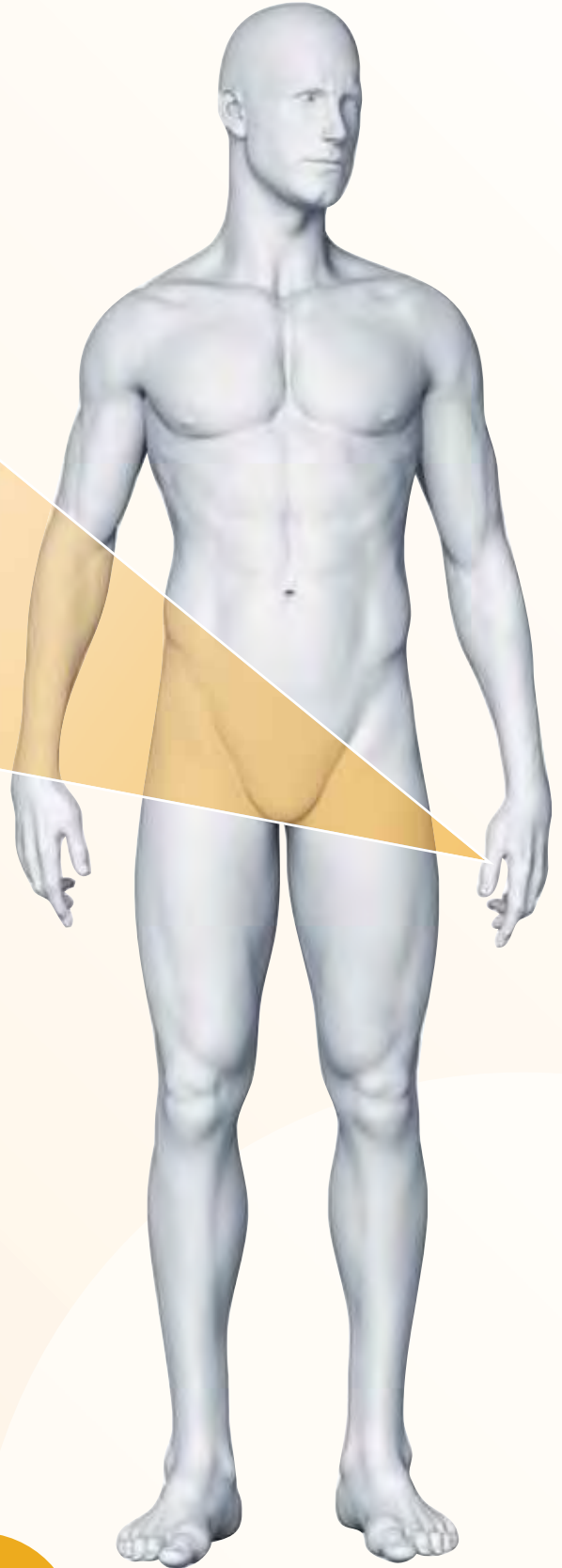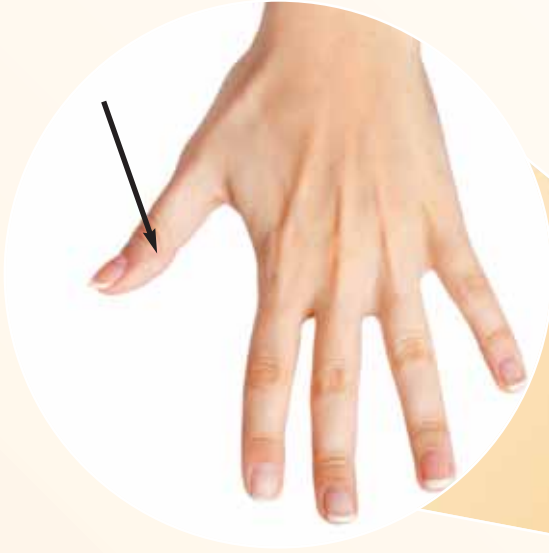ᠰᠢᠷᠨᠢᠭᠢ

Qitiqlıq

Qitiqhiq

Majeur (médius)

# Thumb



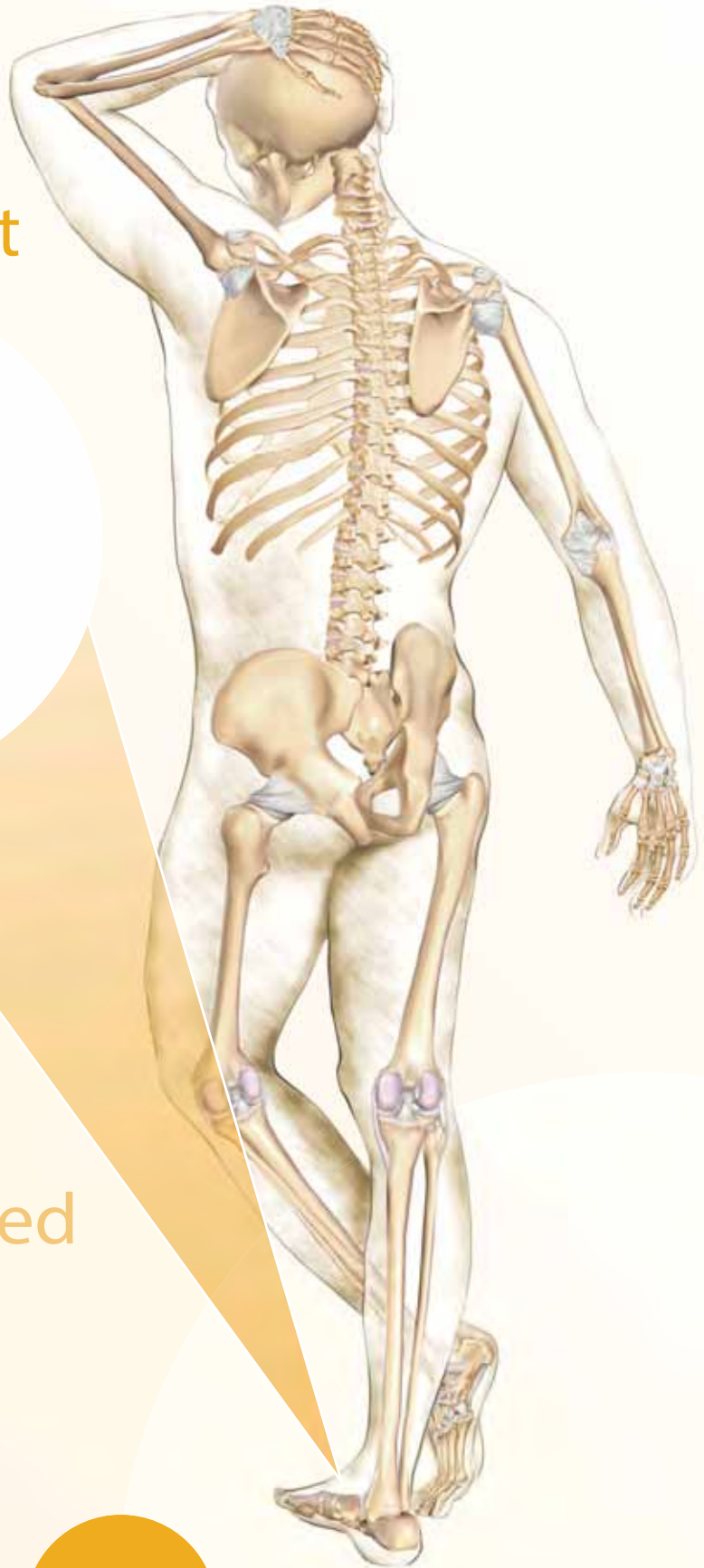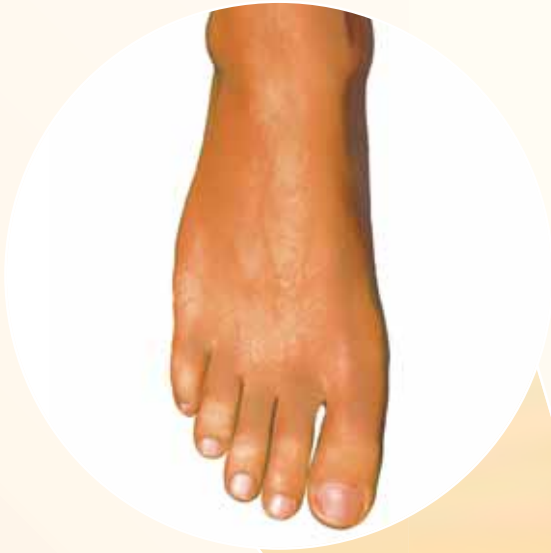كُـلـلـو

Kullu

Kublu

Pouce

# Top or Dorsum of the Foot



ᄃᄆᄇᄈᄉᄊ

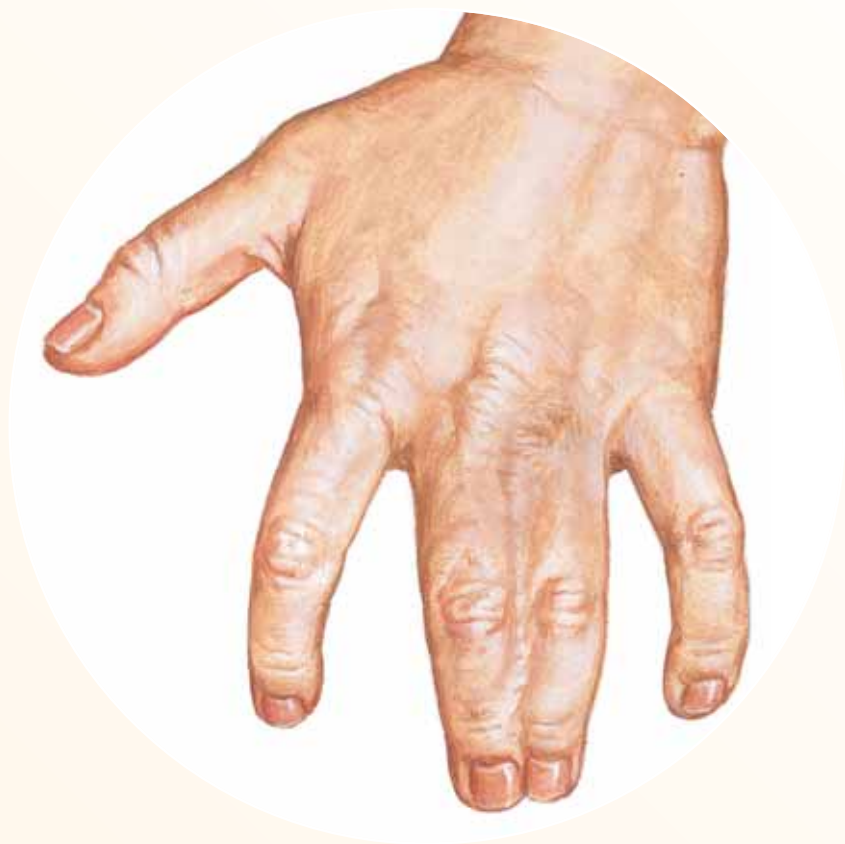Qalliniq

Qalliniq

Dos du pied



# Web



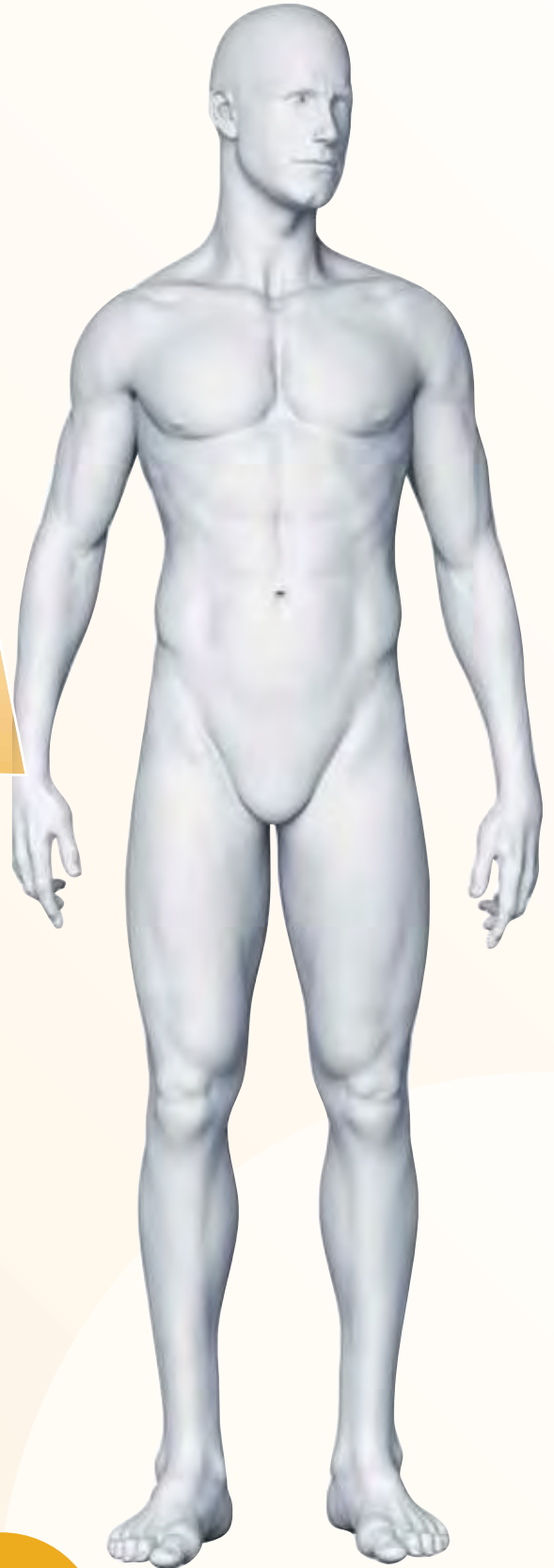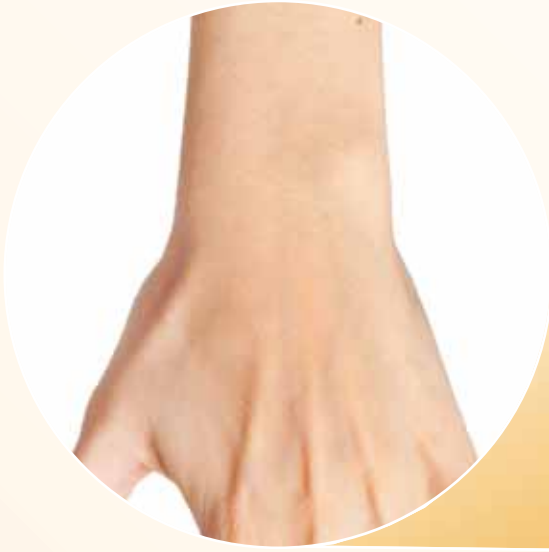ᐱᑭᐱᑦᑭᐱᑦ ᑭᐸᑭᐱᑦᑭᐱᑦ  
ᑭᐸᑭᐱᑦᑭᐱᑦ

Aggaup qunnaujaangik  
Nipinngajuuk

Algaup quppiuyanga  
nipin'ngayuk

Palmure

# Wrist



◀◡◢▶◣

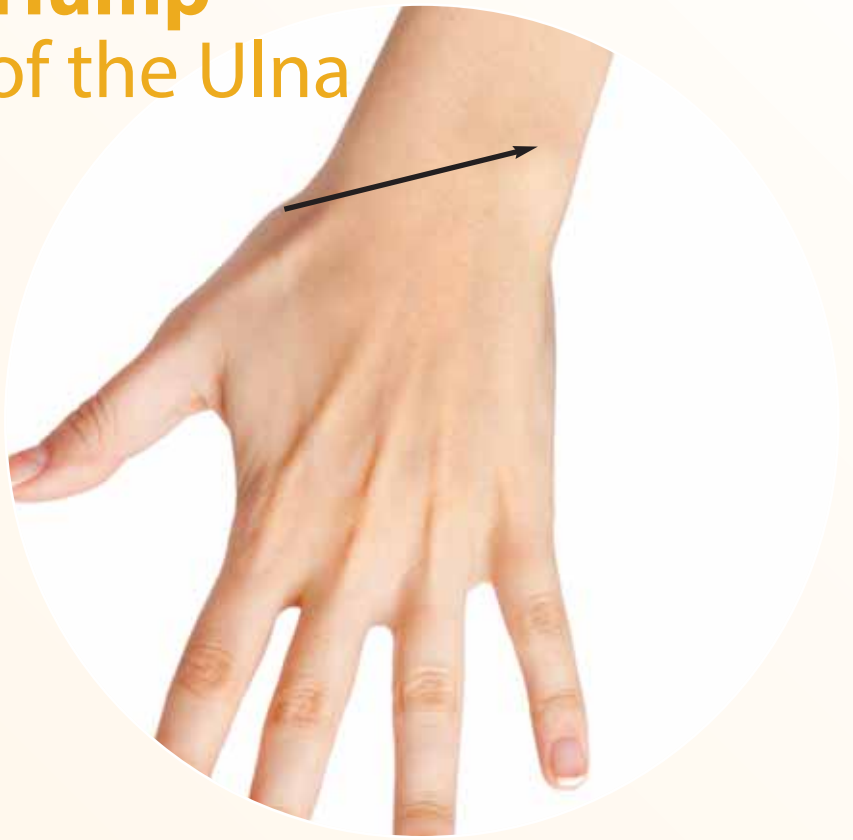Aggaut

Algaut

Radius et  
avant-bras,  
poignet

# Wrist Hump

## Head of the Ulna



ᐱᕐᕐᕐᕐᕐᕐᕐ  
ᕐᕐᕐᕐᕐᕐᕐᕐᕐ

Aggautiup  
Qattiktunga

Algautip Ihuglua

Bosse du poignet  
(tête de l'ulna)



# Genitals/Reproductive

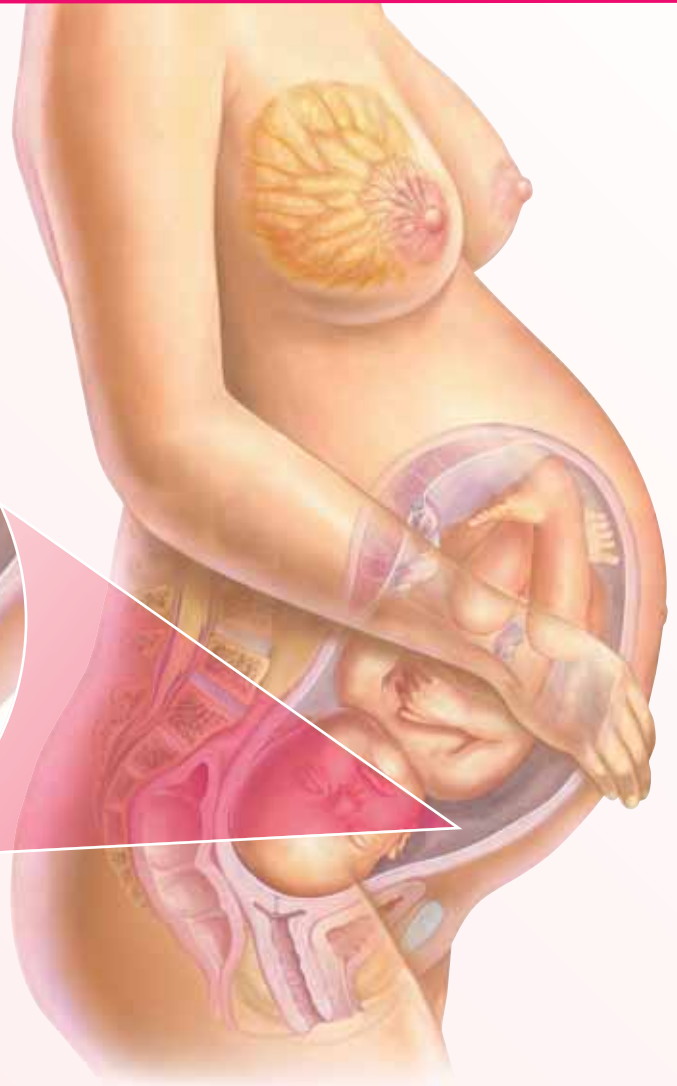
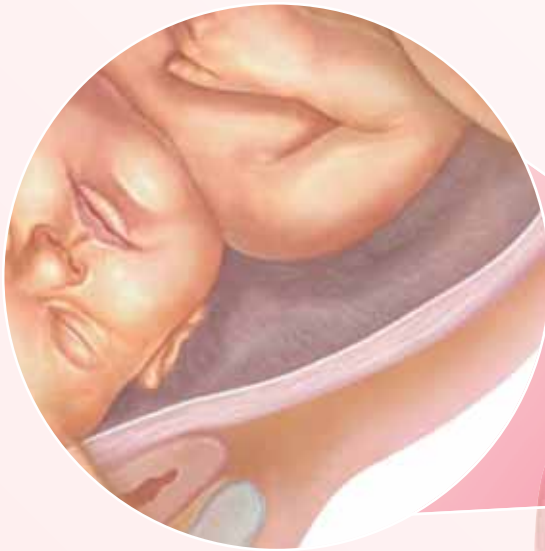ᐱᓄᓚᓂᓕ / ᑖᓯᓂᑖᓄᓯᓯᓂᓯᓂ

Angmaniit/Qiturnngiuruti

Ingilrutit/Nutarannualiurutit

Organes génitaux /  
Appareil génital

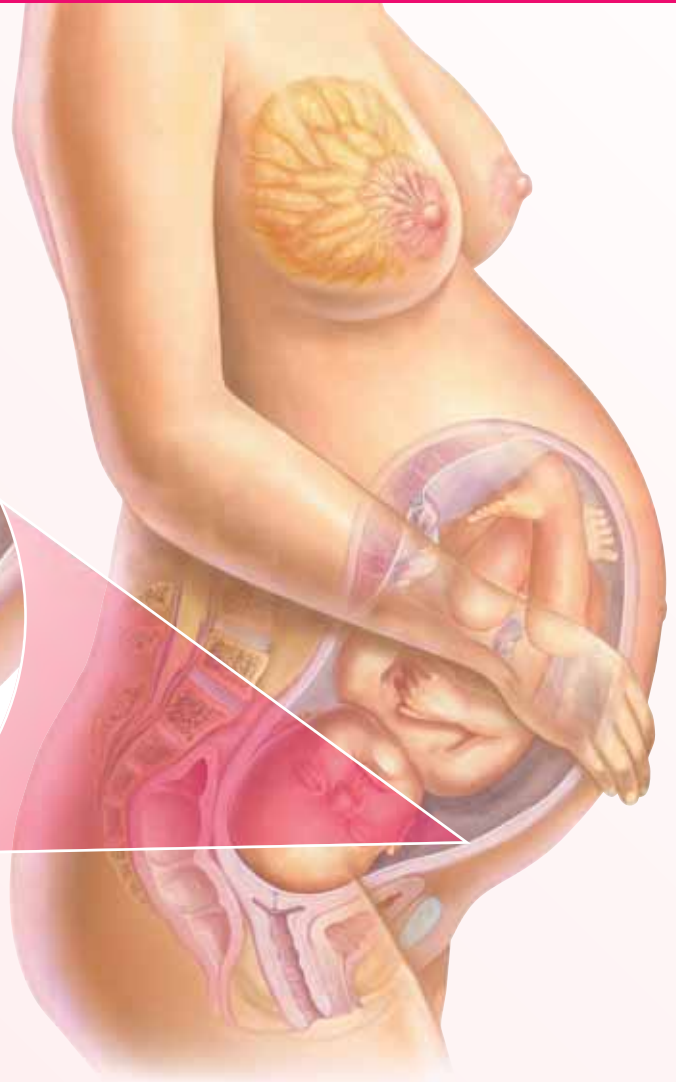
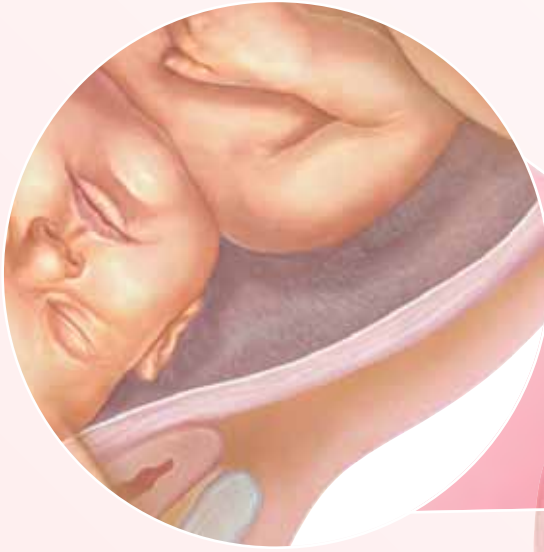# Amniotic Fluid



ᐃᑦᑕᑦᑲᑦᑲᑦᑲᑦ  
ᐃᑦᑲᑦᑲᑦ

Nutaraksaup Imanga  
Imaqutaa Ilumiuttap  
Liquide amniotique

# Amniotic Sac

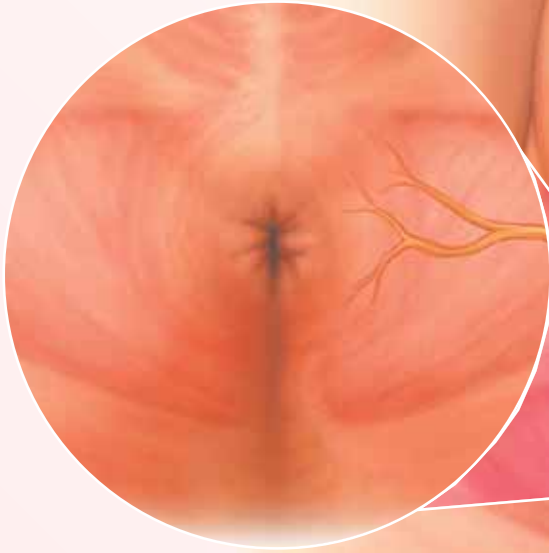


Puupaaq

Imaqutip Puunga

Poche des eaux

# Anus



Δἰῶς

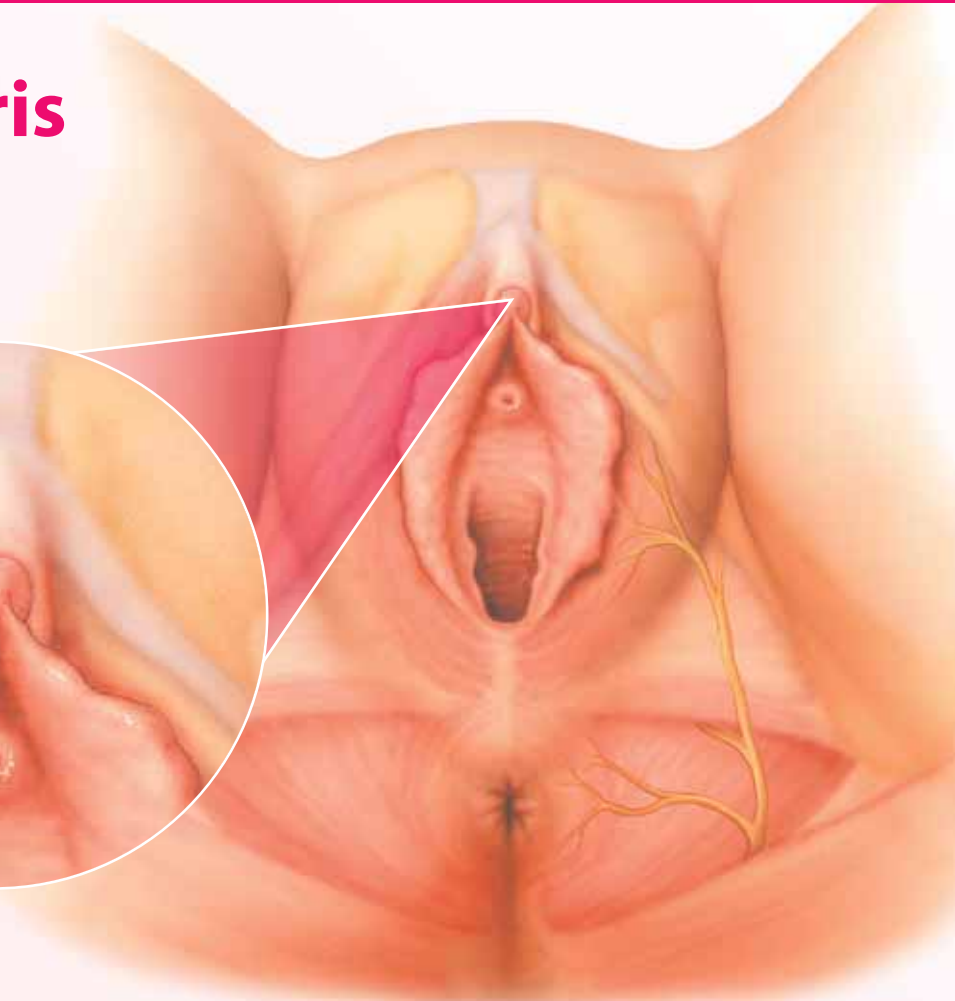
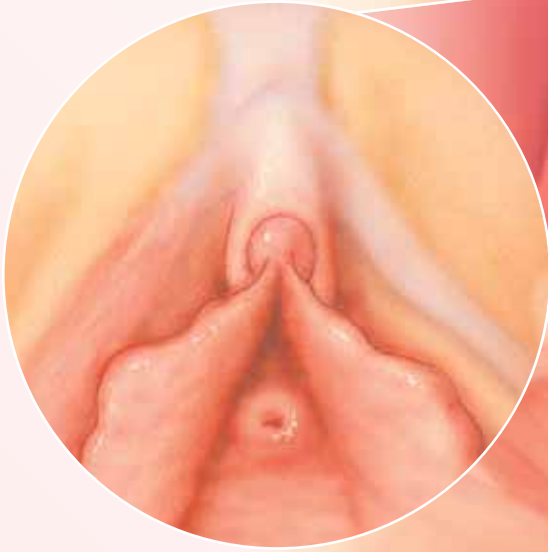Itiq

Itiq

Anus



# Clitoris



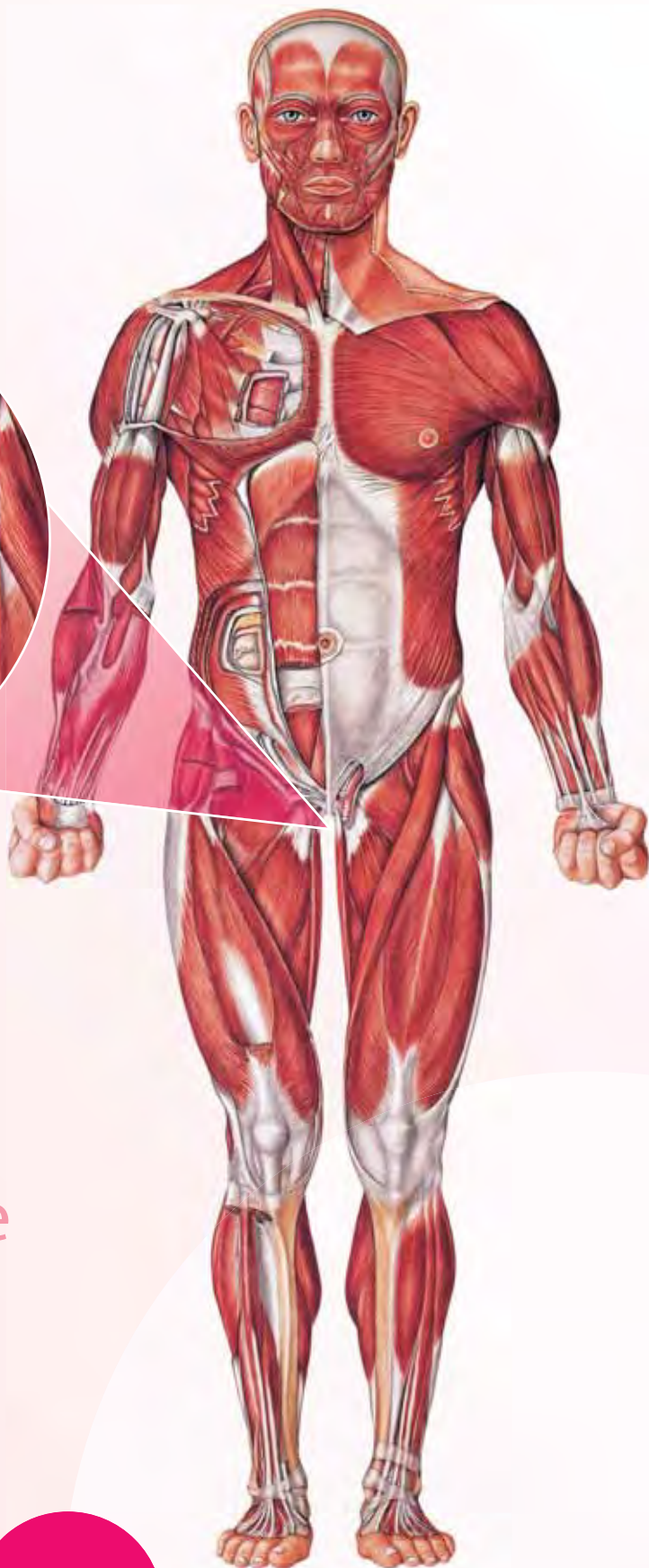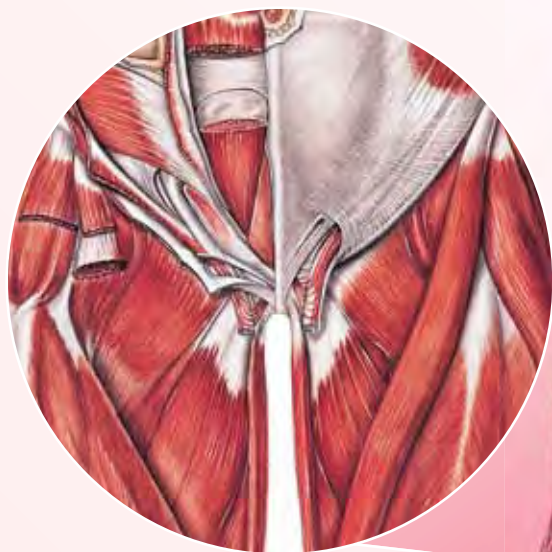
▷ 6 ▷ 9b

Uviuq

Uhuuyaq

Clitoris

# Crotch



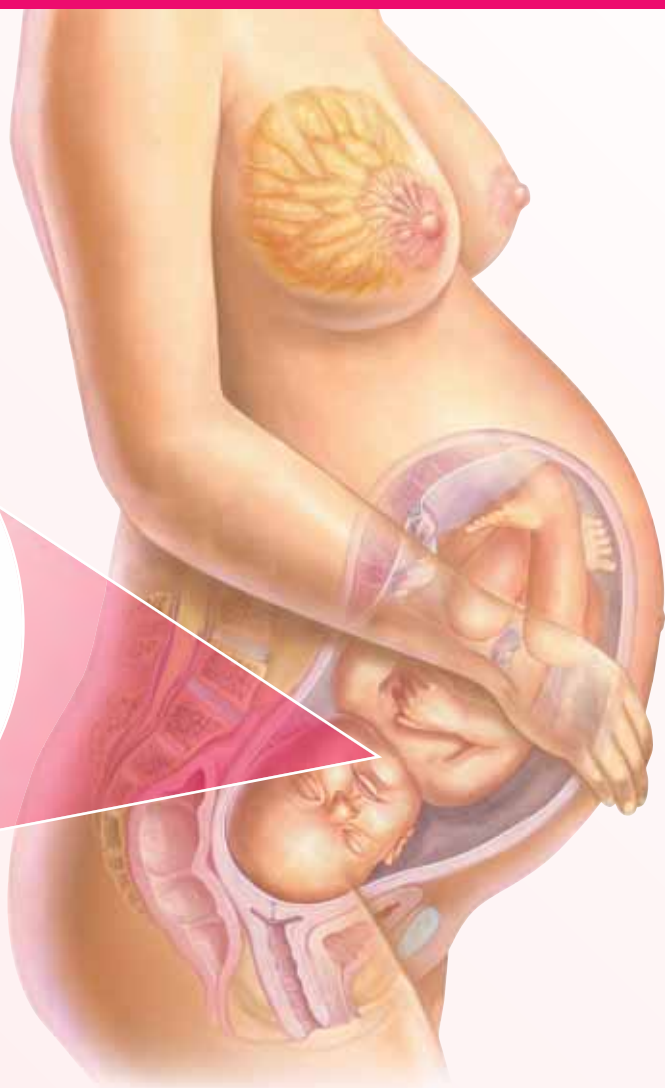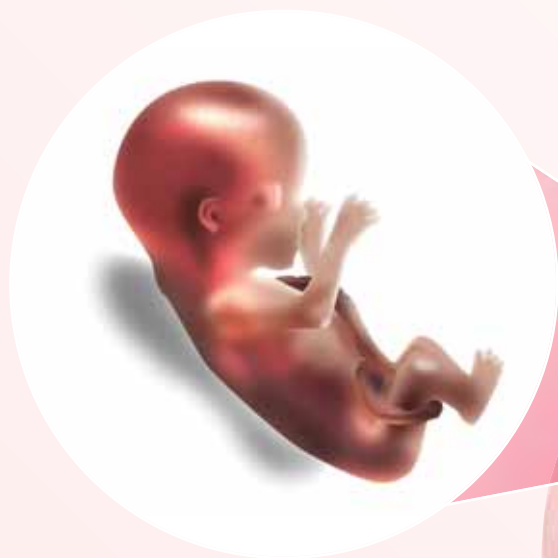ᐱᑦᑦᑦᑦᑦᑦ

Akunnaak

Akunnaak

Entrejambe

# Embryo, Fetus



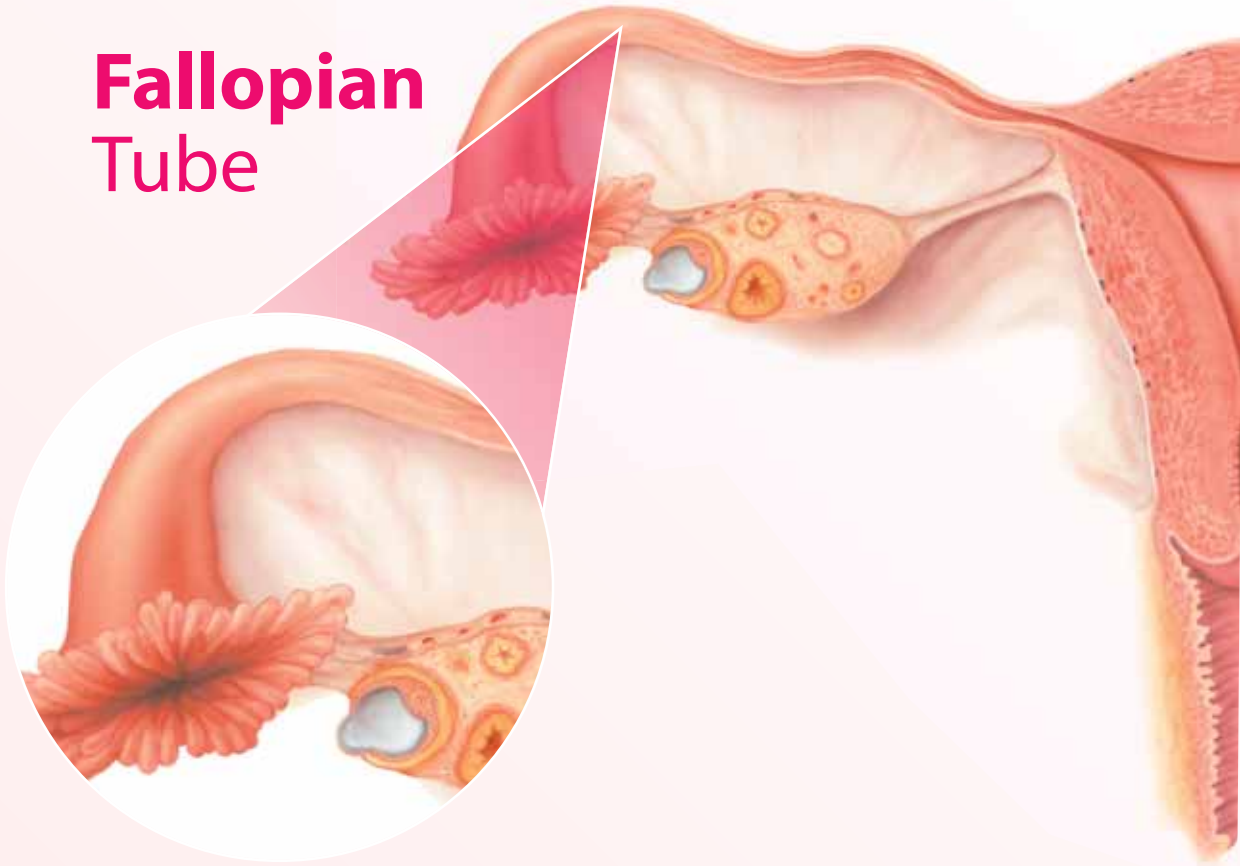
ᑭᓴᓴᓴᓴᓴᓴ

Najjiaq

Ilumiaq

Embryon, foetus

# Fallopian Tube



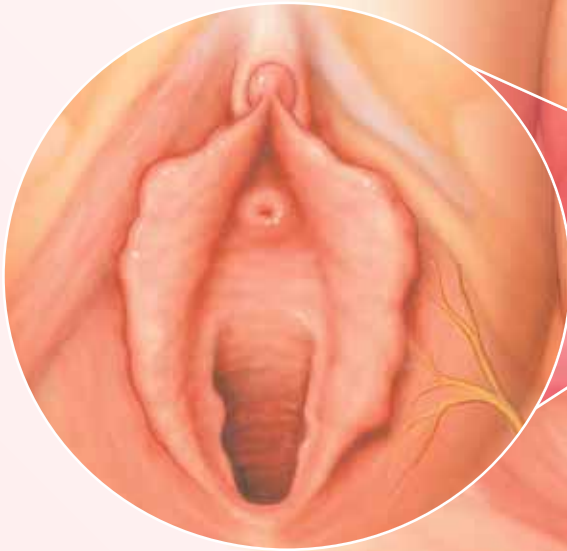
Արճակ Գճֆրֆ

Igliap Attunginga

Nutarakhaup Nauvia

Trompe de fallope

# Female Genital Vagina / Vulva



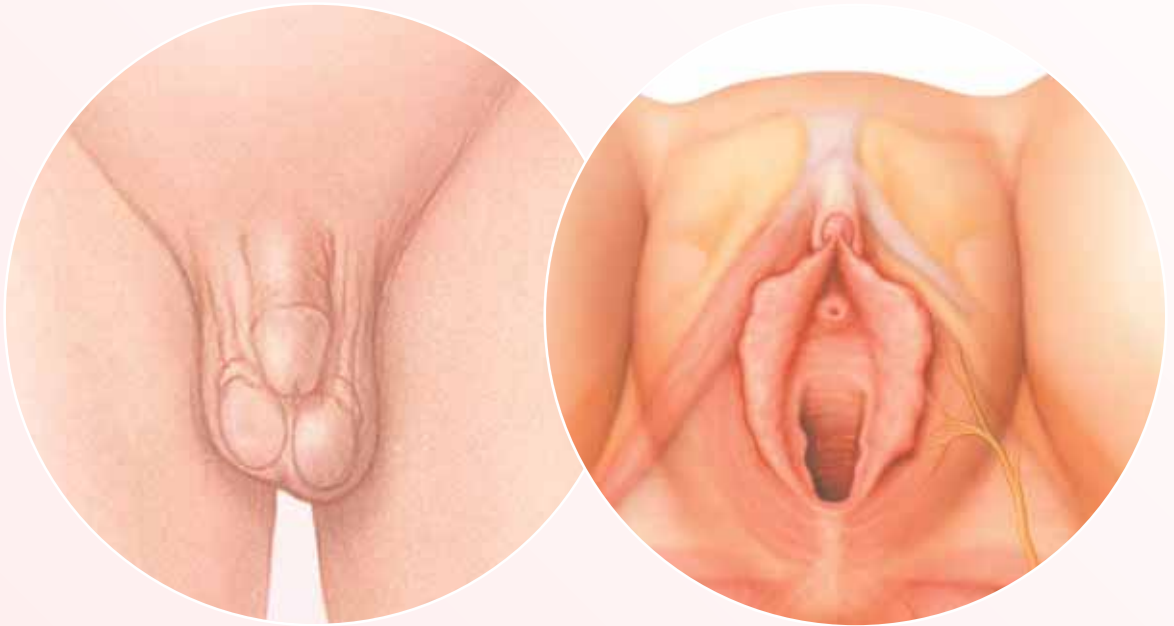
ᐱᓐᓇᓂᓐ ᐱᓐᓇᓂᓐ

Arnaup Angmaningit

Uttuuk

Organe sexuel féminin  
(vagin, vulve)

# Genitals – Male and Female



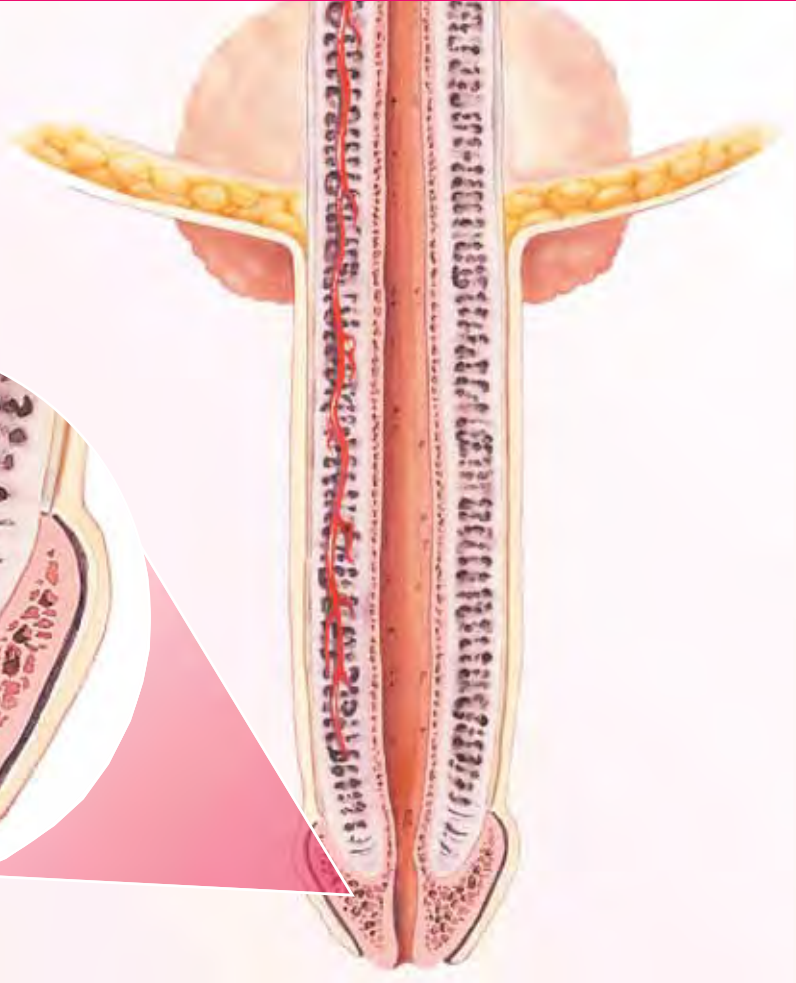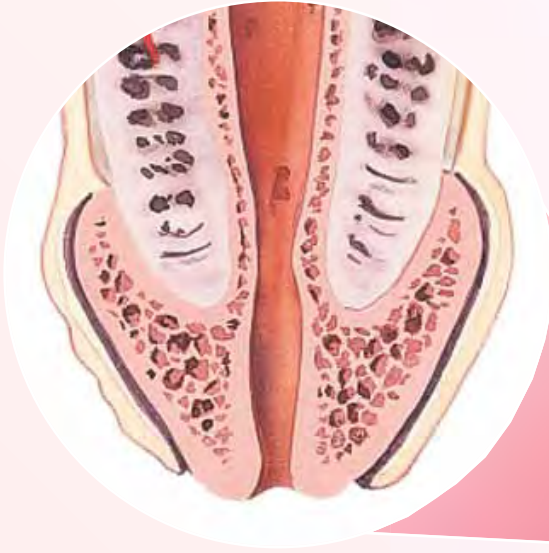ᐱᑦᐱᑦᐱᑦᐱᑦ ᐱᑦᐱᑦᐱᑦᐱᑦ

Angutiup Arnallu

Angutit Arnallu Ingilrutait

Génitaux – mâle et femelle

# Glans Penis



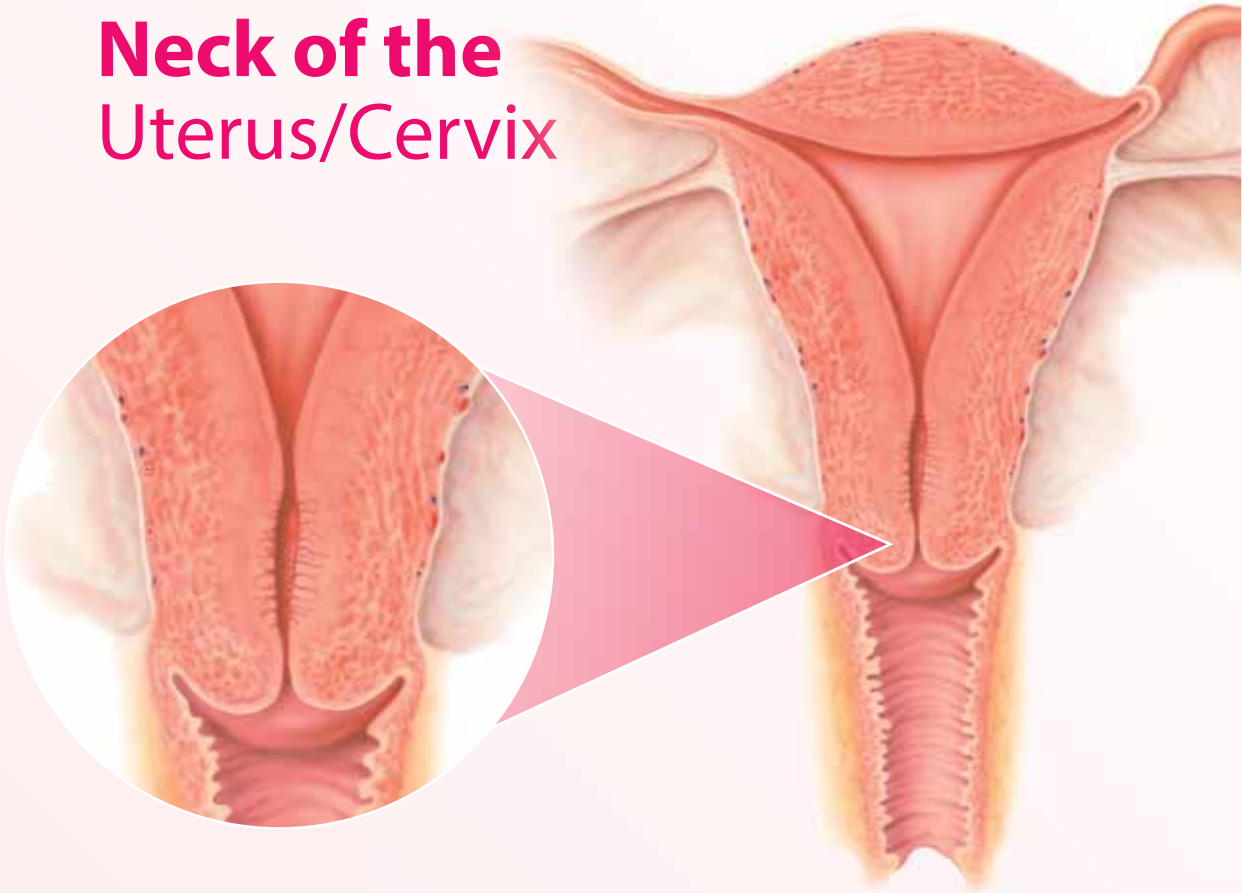
ᐃᑦᑦᑦᑦᑦᑦ

Ulivvaq

Uhuup Nuvua

Gland

# Neck of the Uterus/Cervix



ᐃᓕᐱᐸ ᑲᐃᑲᑲᑲᑲ

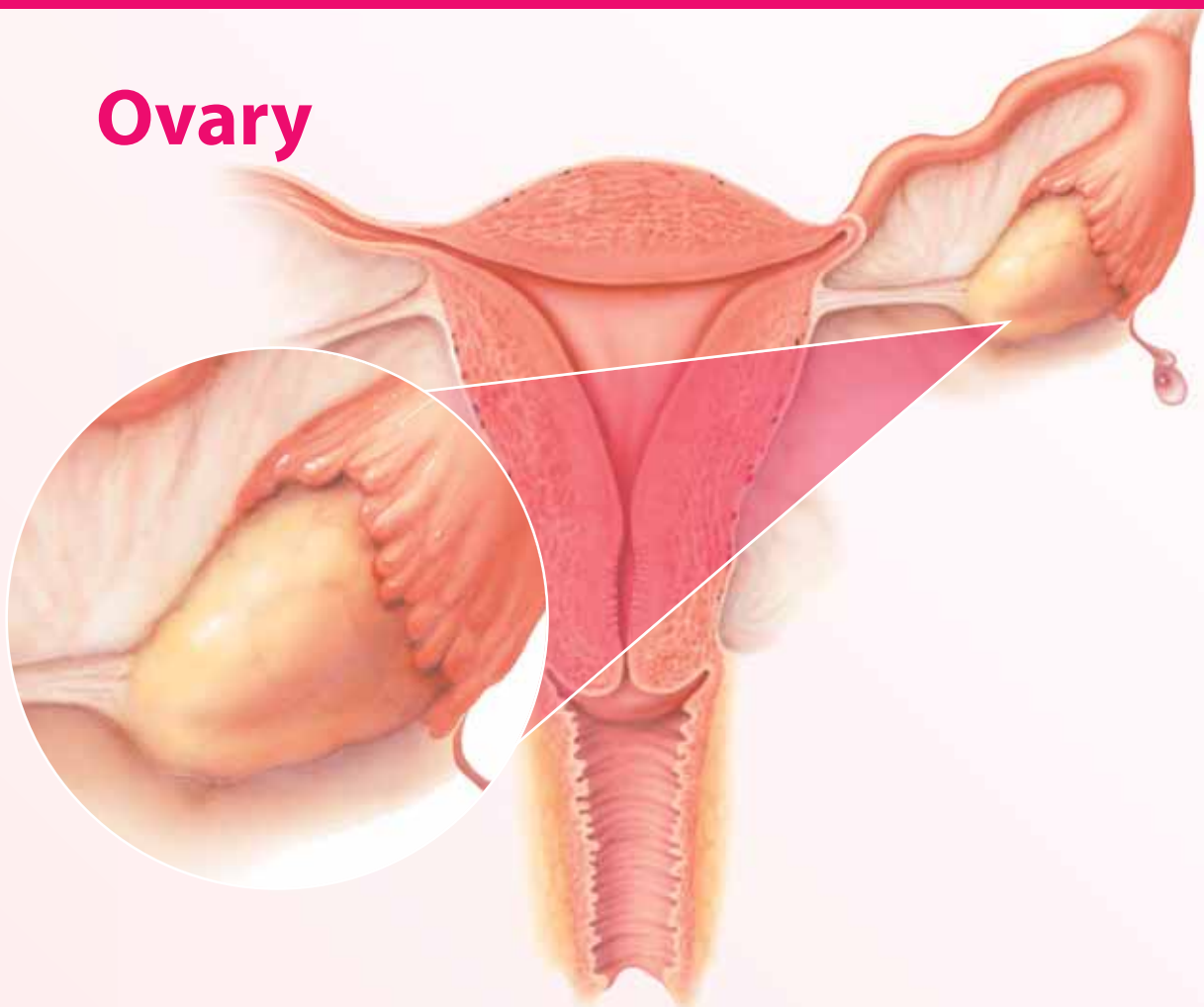
Igliap Quuqqanga

Igliap Qaanga

Col de l'utérus



# Ovary



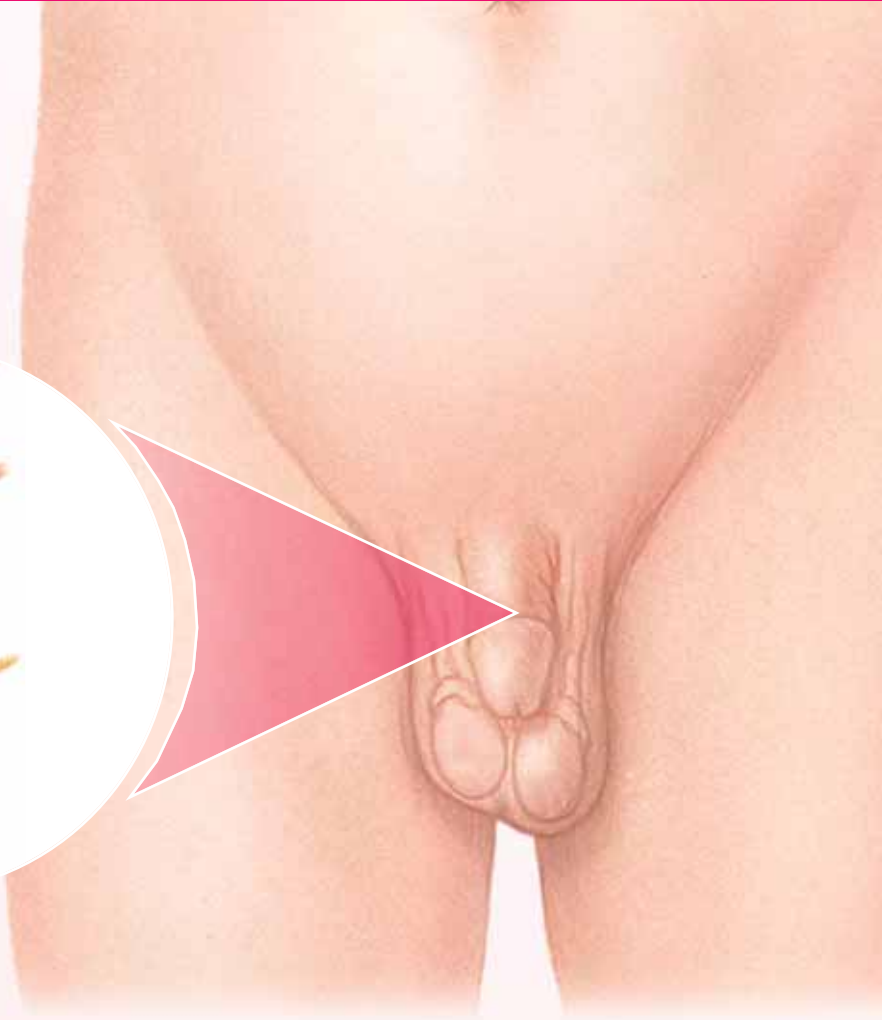
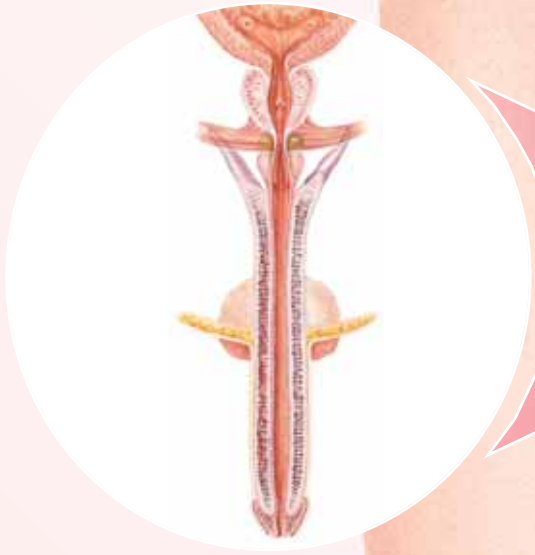ᐱᓃᓄᐅᓃ ᐱᓃᓃᓃᐅᐱᓃᓂ

Arnaup Manniqautinga

Igliaq

Ovaire

# Penis



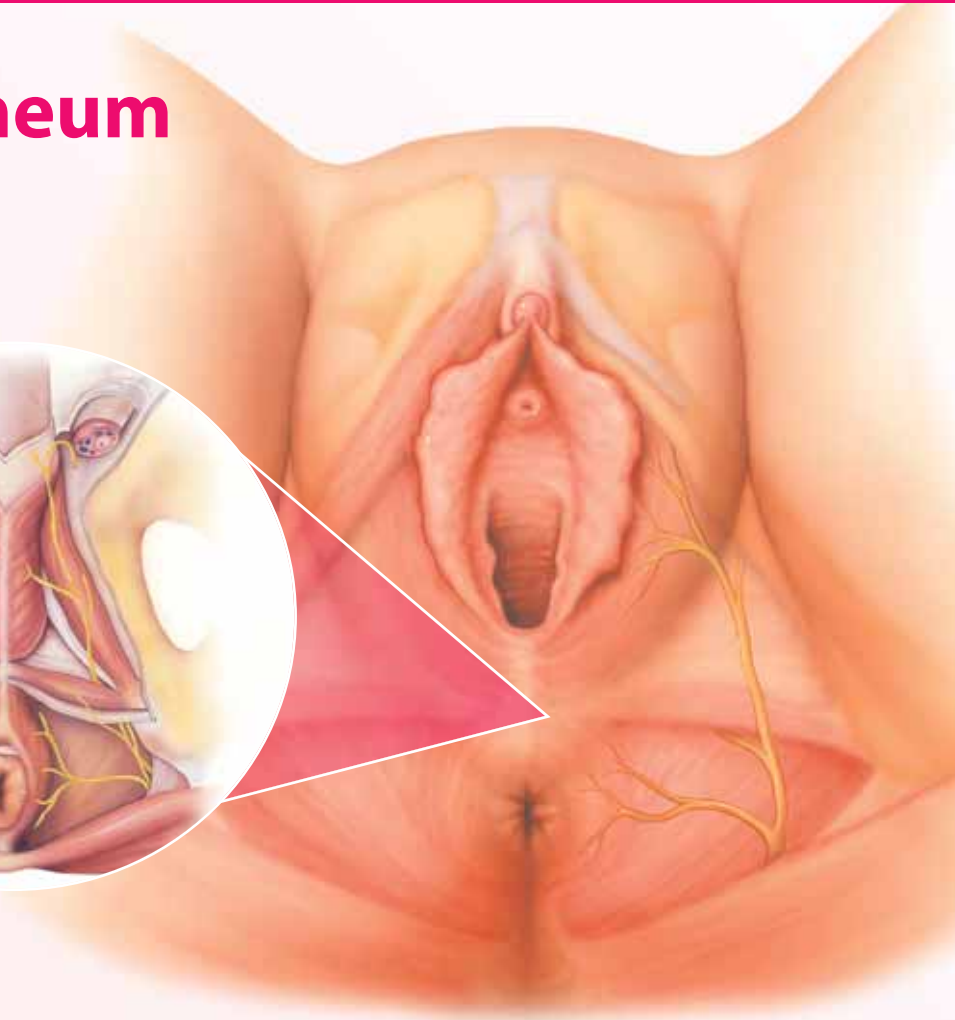
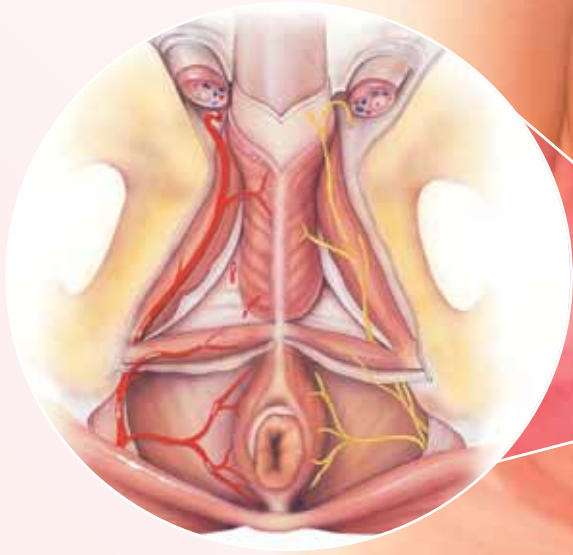
بَلَد

Usuk

Uhuk

Pénis

# Perineum



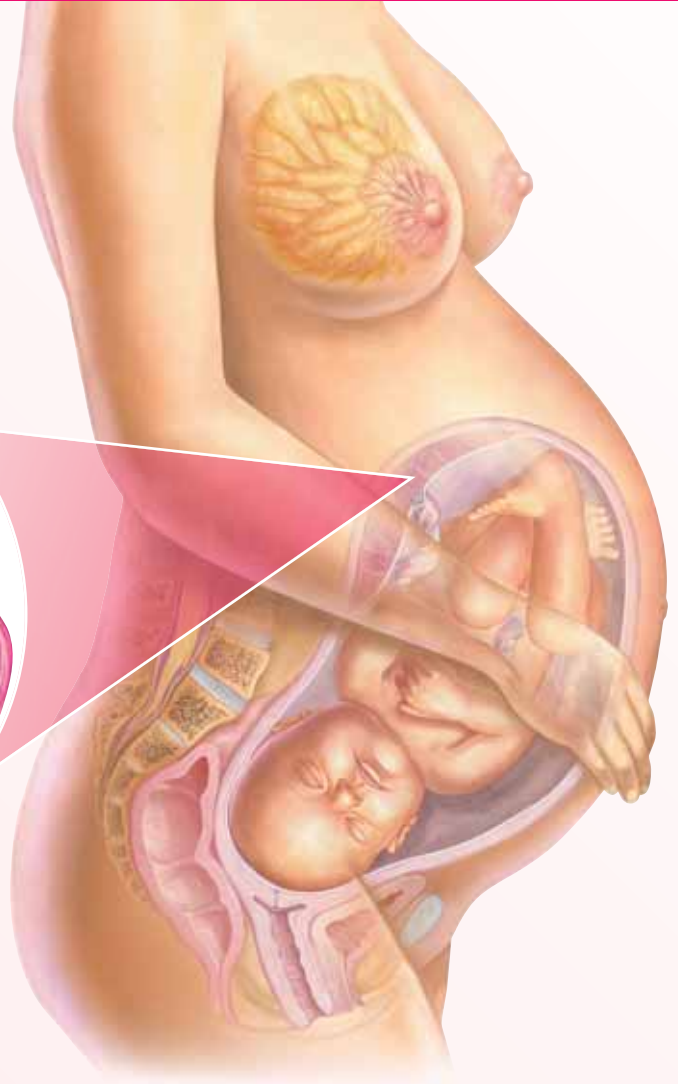
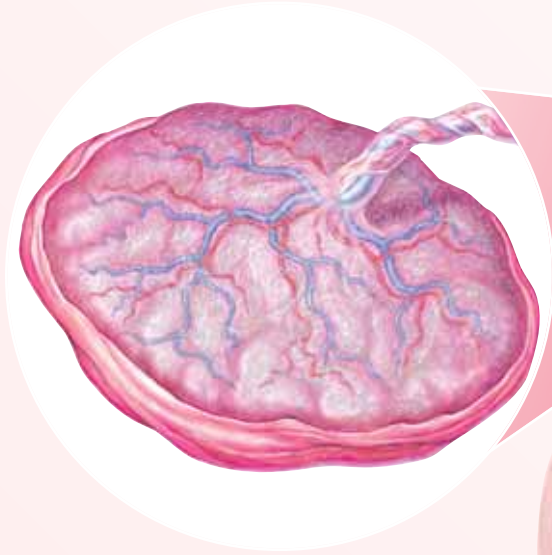
ᐱᐱᐱ ᐱᐱᐱ

Qilluaq

Attakilruq

Périnée

# Placenta



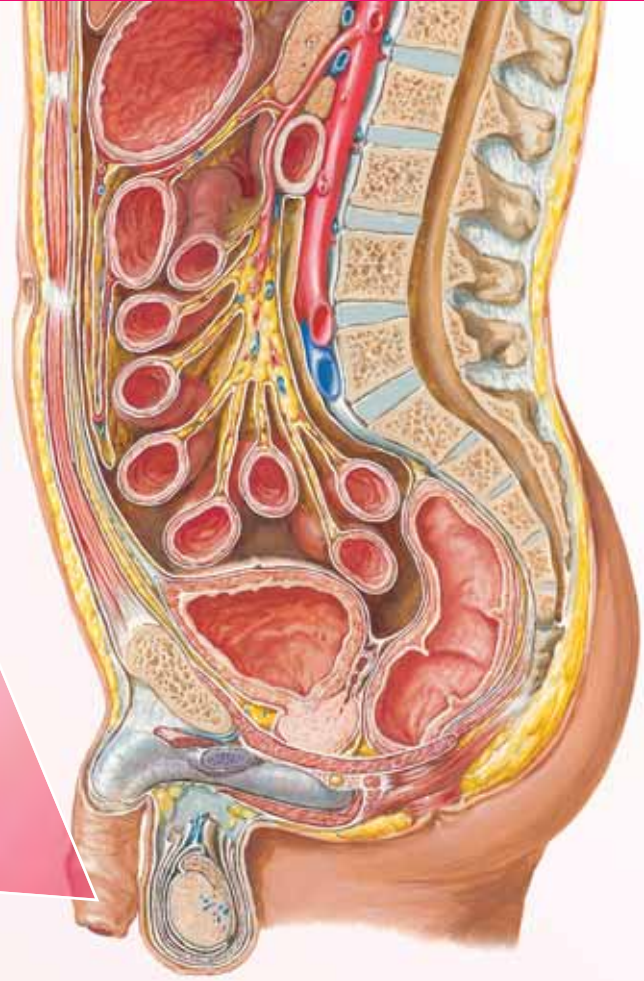
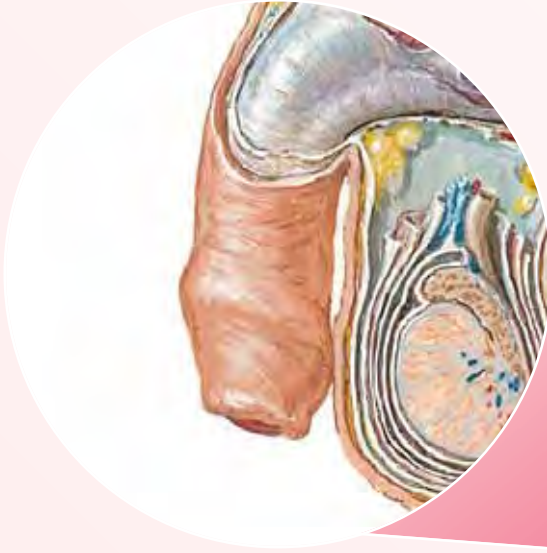
ᐱᕐᕐᕐᕐᕐ

Arraaq

Alraaq

Placenta

# Prepuce / Foreskin



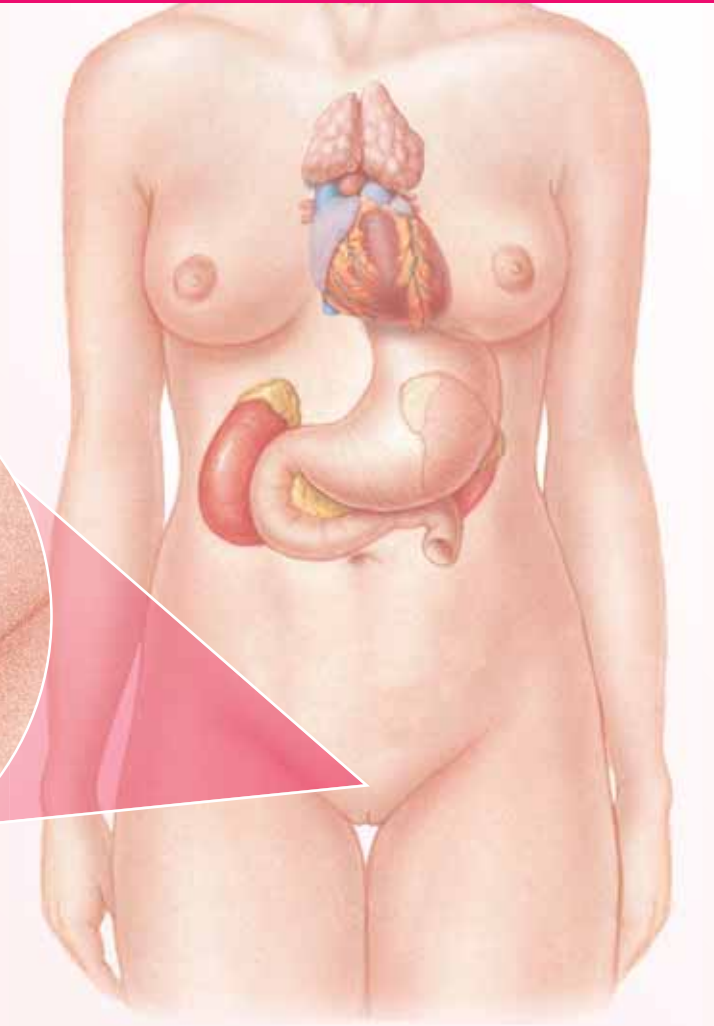
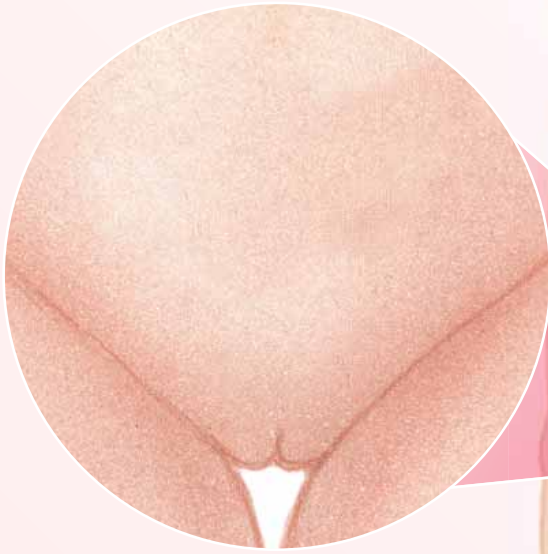
ᐱᐱᐱᐱᐱᐱ

Paasiniq

Puungata Nuvua

Prépuce

# Pubic Area



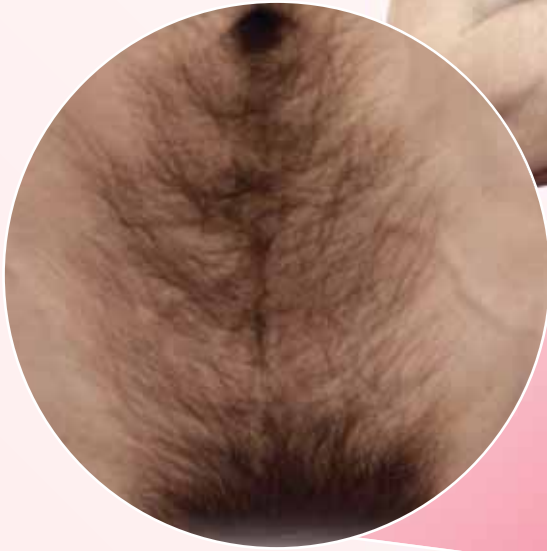ᐃᓴᓂ

Ingi

Ingik

Région pubienne

# Pubic Hair



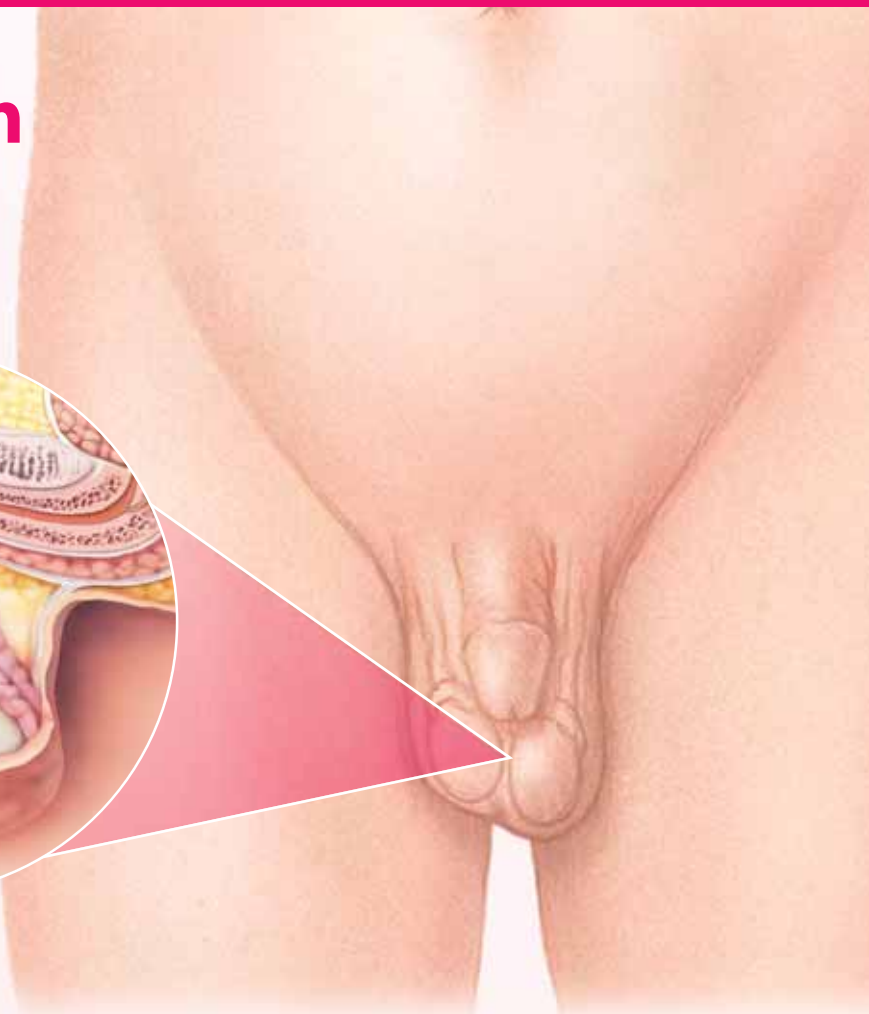
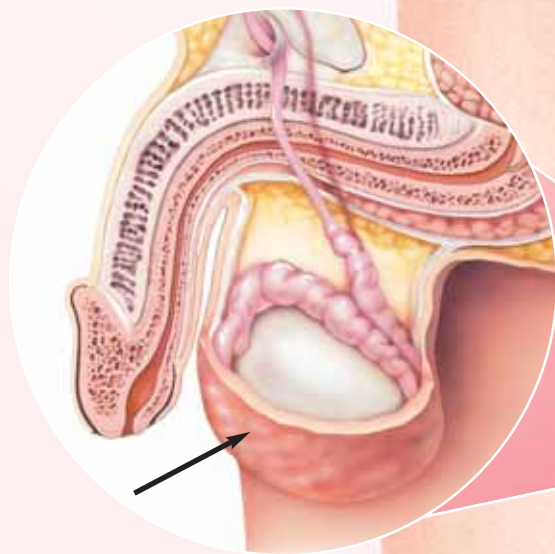
Ո՞՛ՐԸ

Tingit

Tingiq

Poils pubiens

# Scrotum



Δᵐᵗᵑᵑᵑᵑᵑ

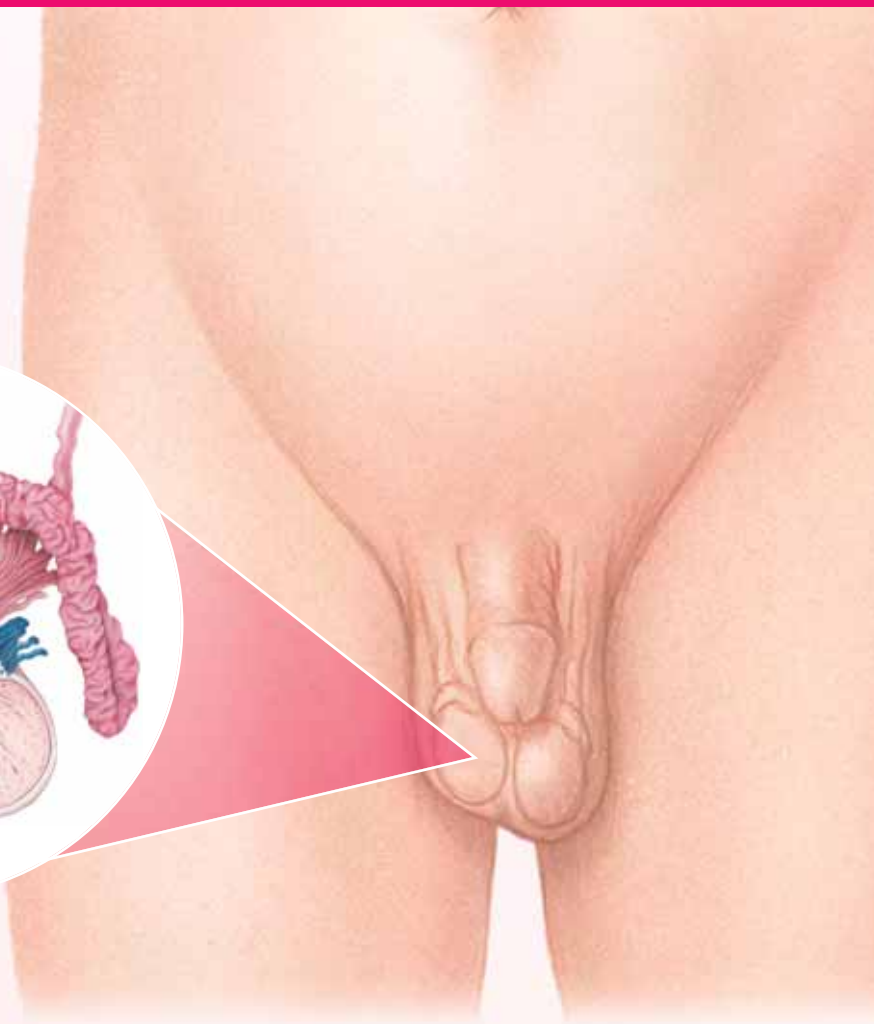
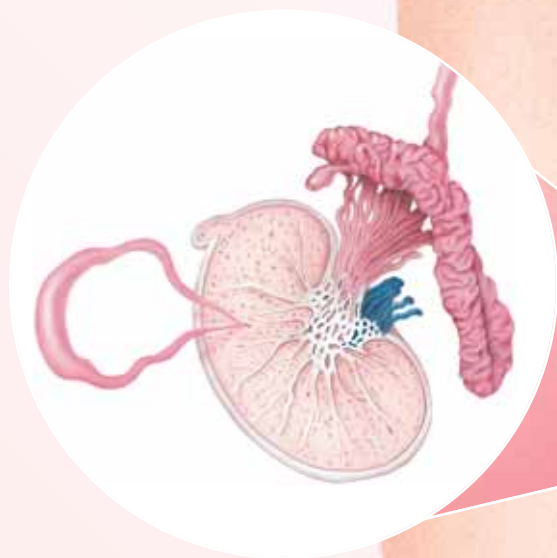Igjuqauti

Igyuup Puunga

Scrotum



# Testicle



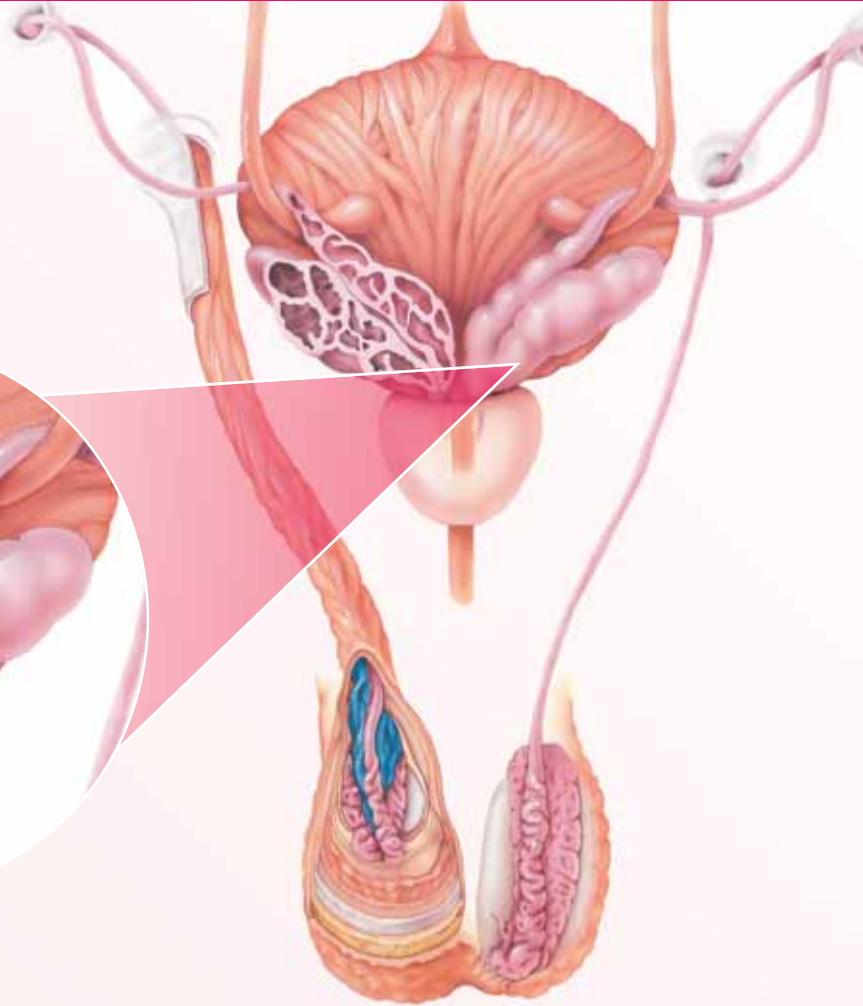
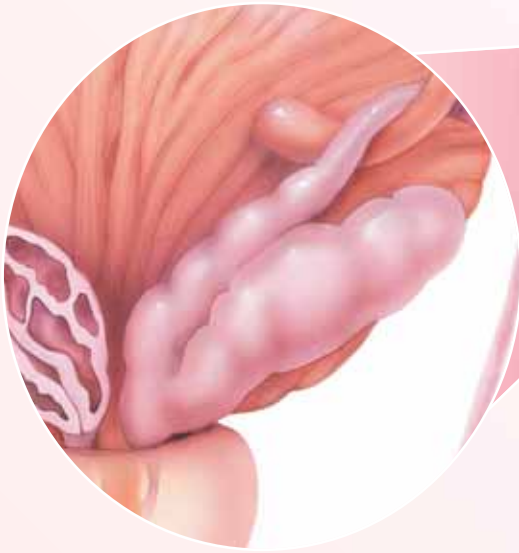Δἆῤῖḅ

Igjuk

Igyuuk

Testicule

# Testicle Seminal Gland



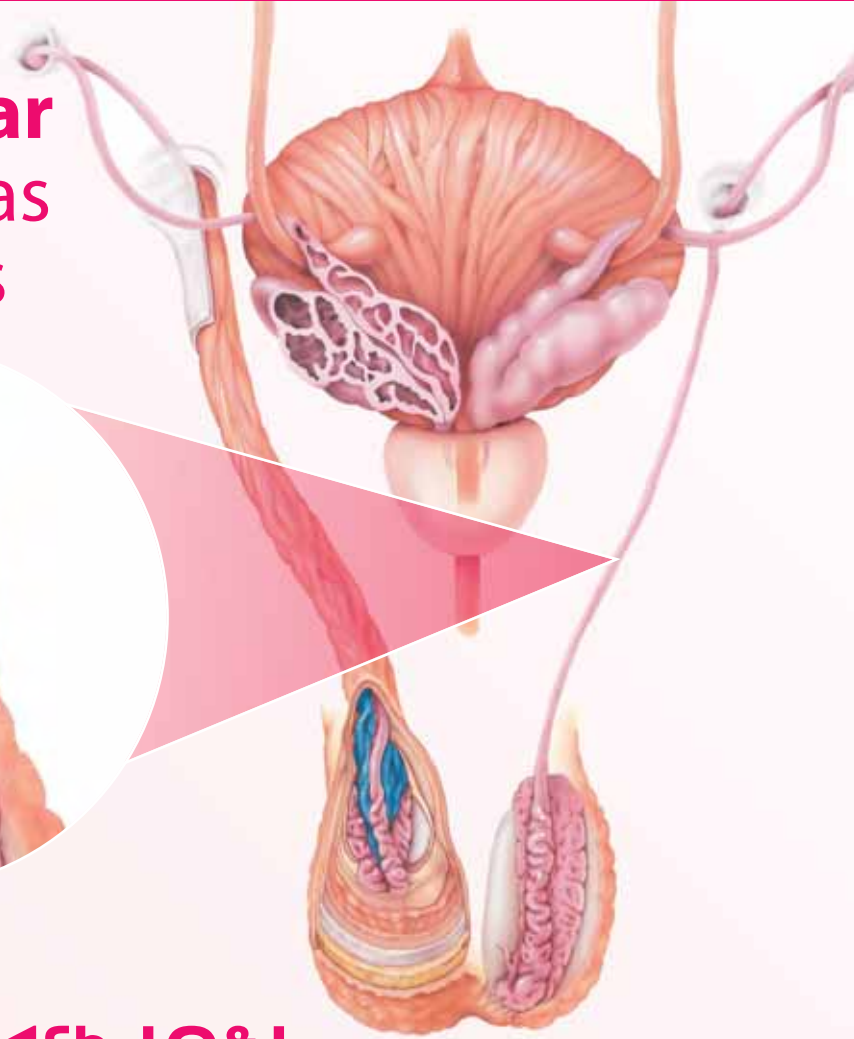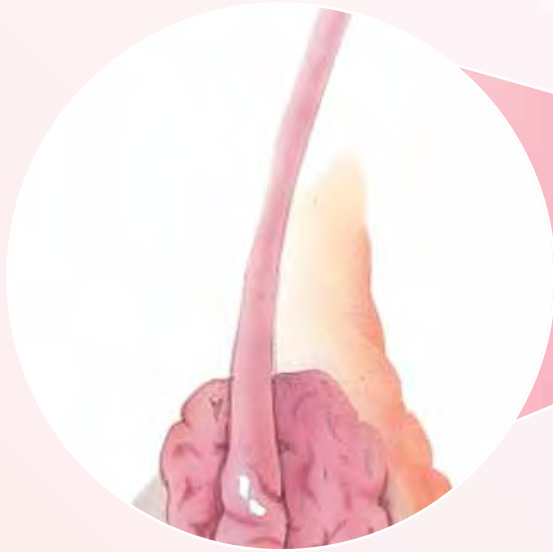ᐃᐸᐸᐸ ᐸᐸᐸᐸᐸᐸᐸᐸ

Igjuup Qapaliurutinga

Qapuliurut

Testicule, glande séminale

# Testicular Duct / Vas Deferens



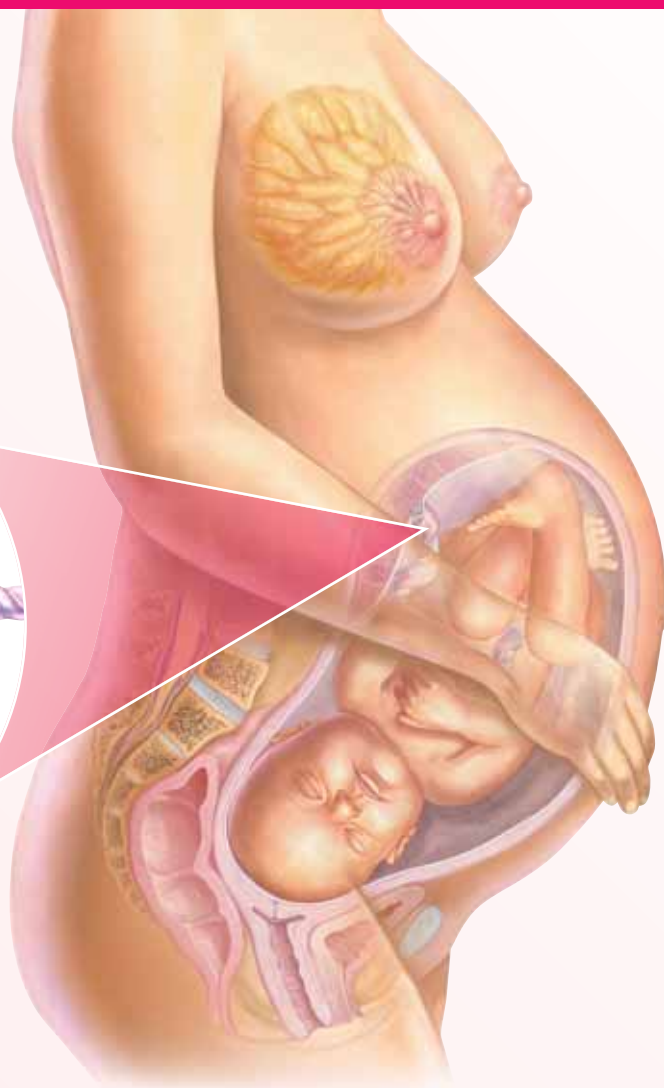
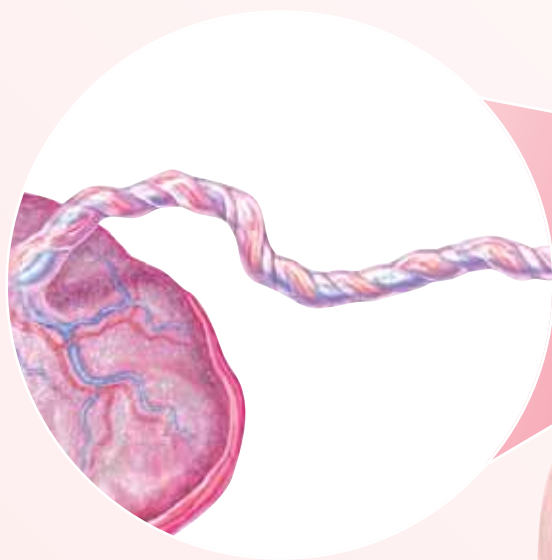
ፍጥጥር ጥገና ጥገና

Qapaup Aqqutinga

Qapuup Apqutaa

Canal déférent

# Umbilical Cord



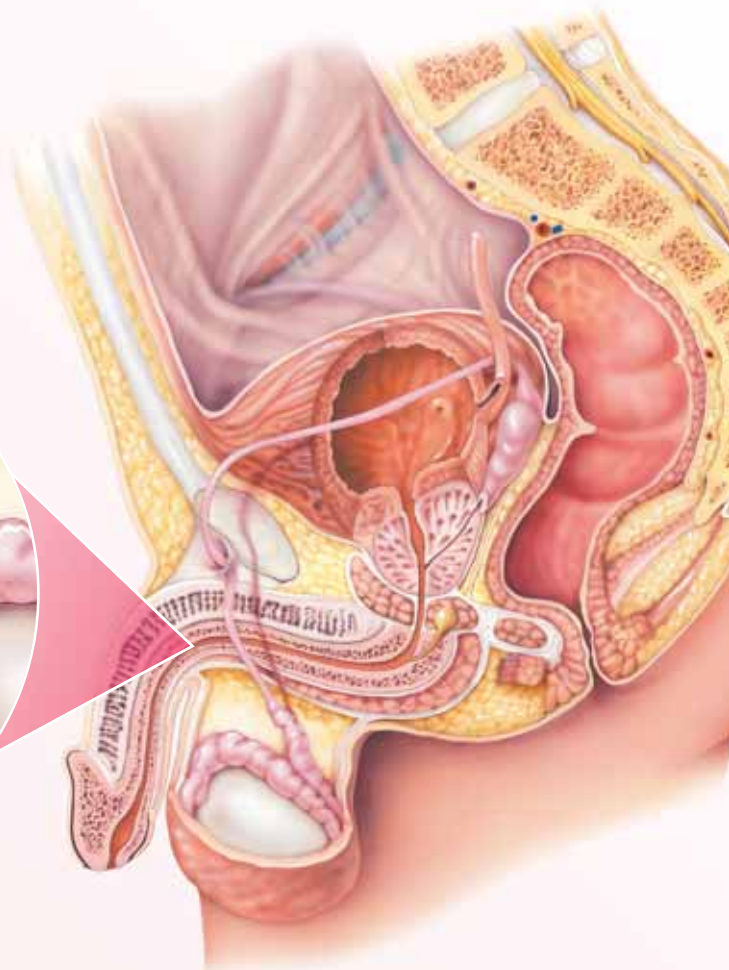
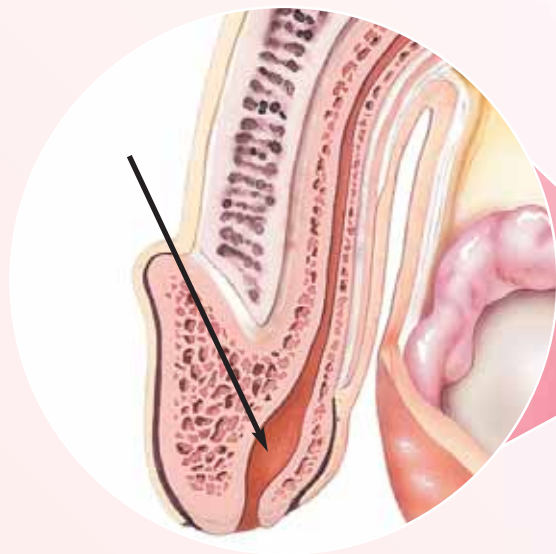
ᠮᠢᠬᠢᠶᠠᠴᠢ

Mik᠊ᠯᠢᠶᠠᠴᠢ

Mikhᠢᠶᠠᠴᠢ

Cordon ombilical

# Urethra



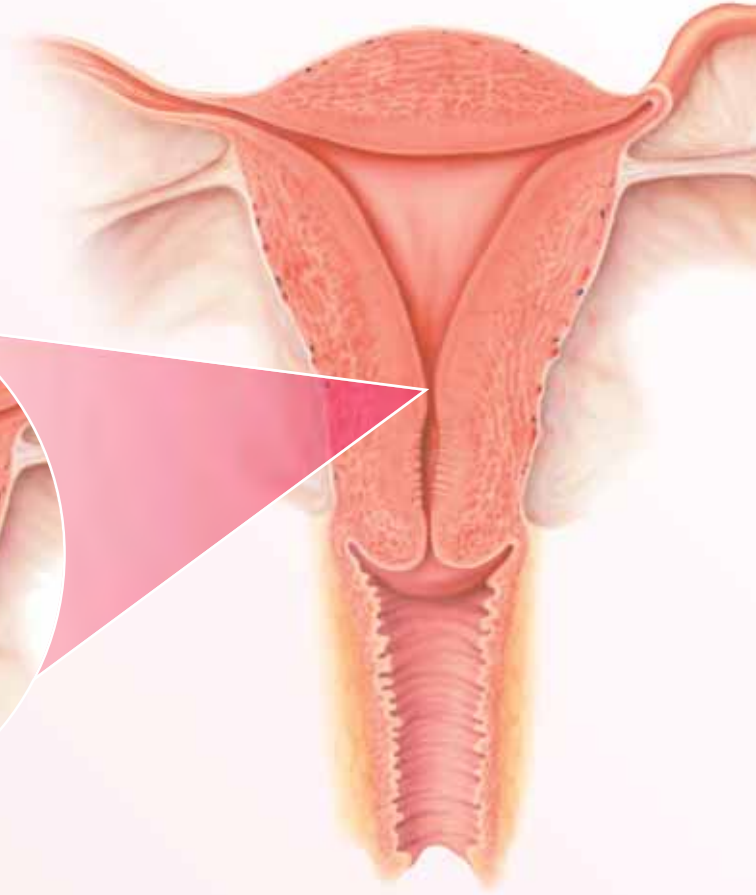
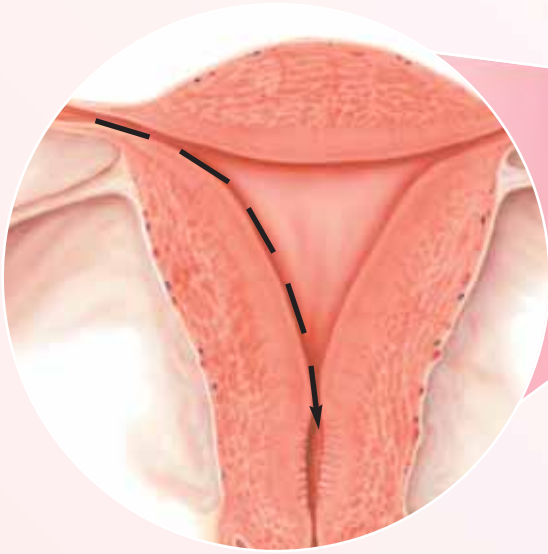ᑦᑭᑦᑎᑦᑲᑦ

Qurrivik

Quivik

Urètre

# Uterine Tube



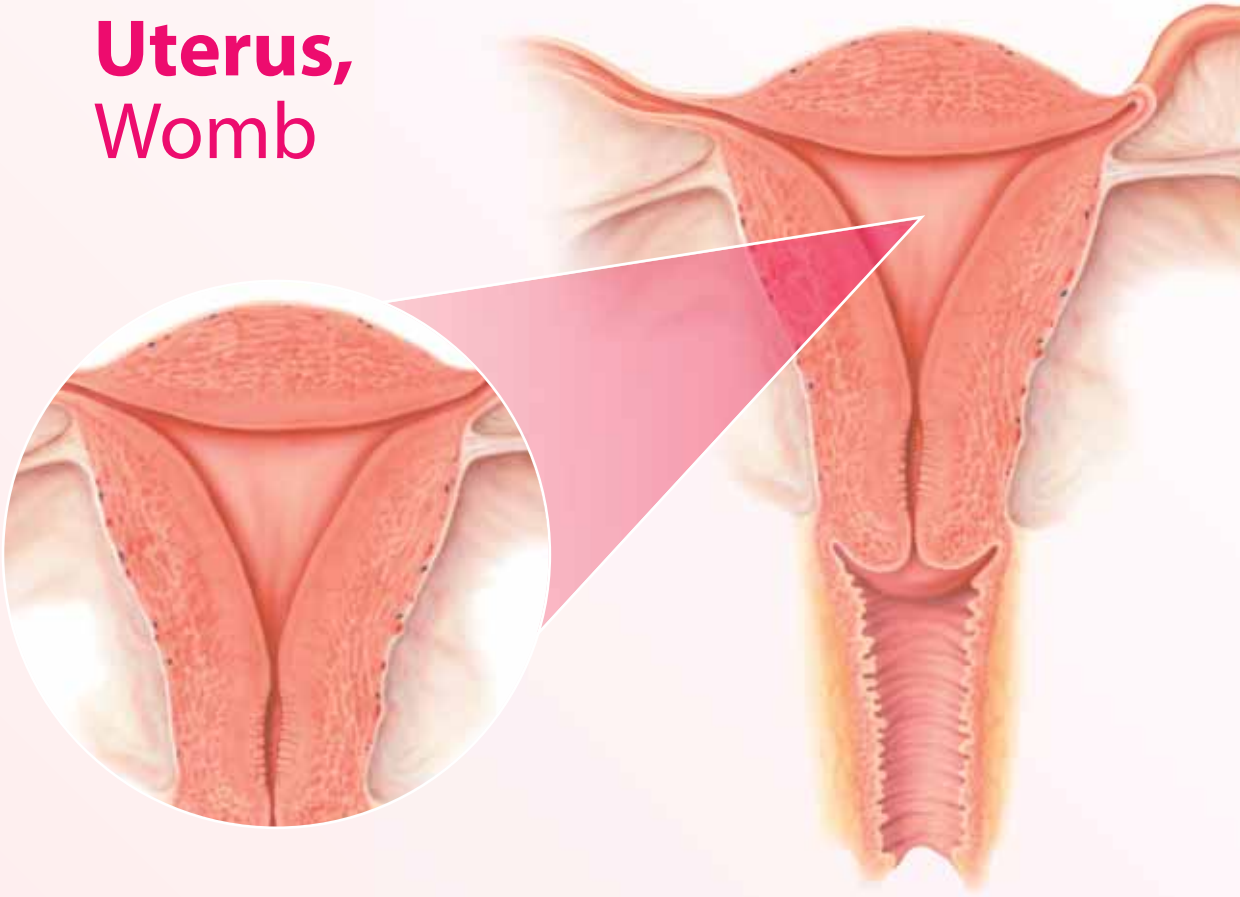
Լ՞օժՏՃՁ Վ՞ԳԵԺՈ՞Ն

Manniup Aqqutinga

Igliap Tuqhuanga

Trompe utérine

# Uterus, Womb



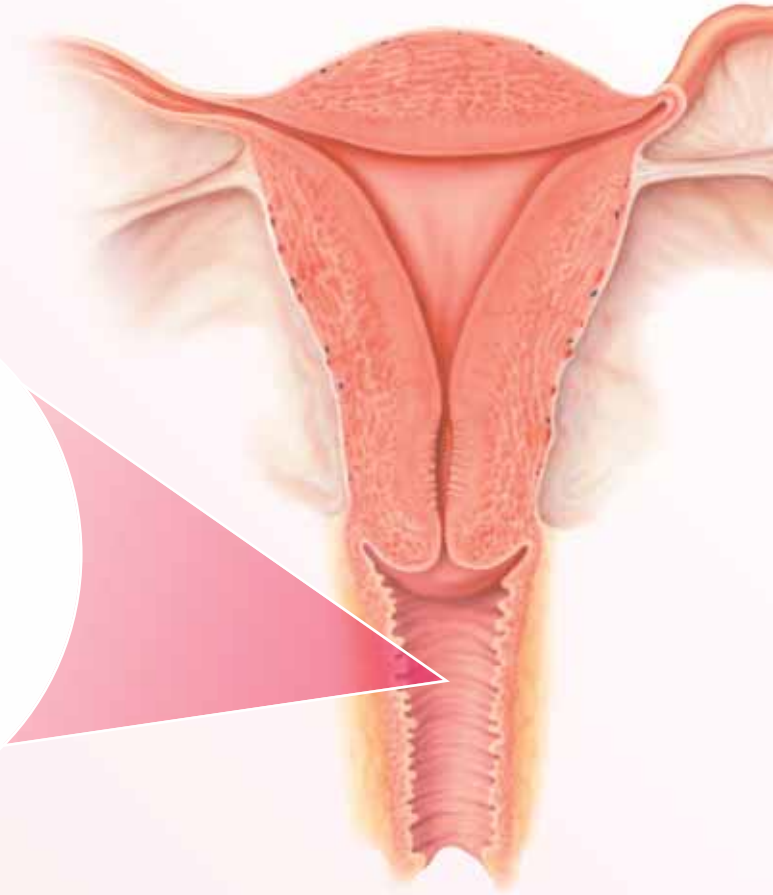
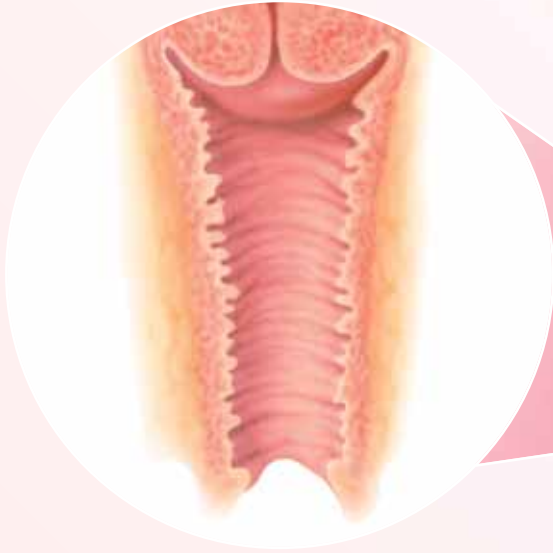ᐃᐅᐅᐅᐅᐅᐅ

Igliaq

Igliaq

Utérus, matrice

# Vagina



ᑲᑦᑲᑦ

Kavvik

Uttuuk

Vagin



# Glands/Fluids/ Excretions/Secretions

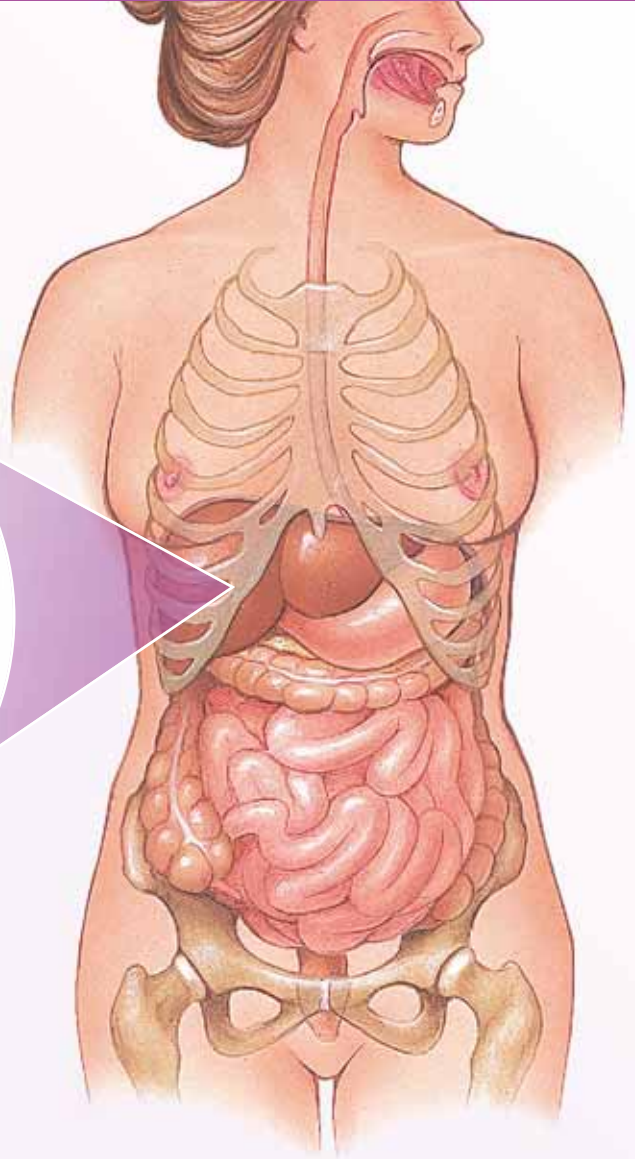
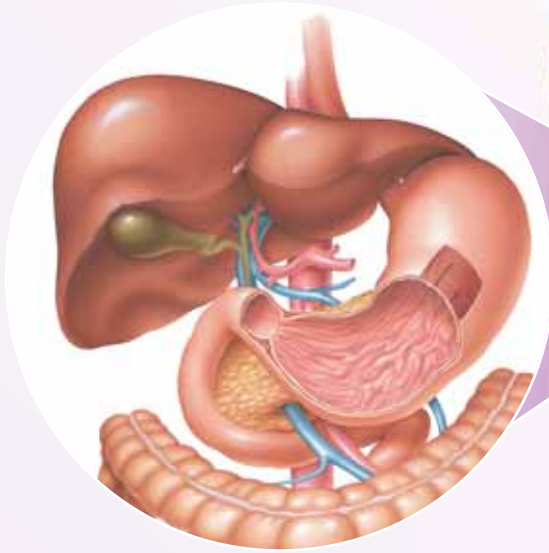ᖃᕈᕋᕐᕐᕐ/ᕐᕐᕐ/ᕐᕐᕐ/ᕐᕐᕐ,  
ᕐᕐᕐ/ᕐᕐᕐᕐᕐᕐ

Qiliqsinaq/Issiit/Itiruq,  
Anaq/Issaaqiniit

Qiniqhinit/Imaquatat/Maqiniit

Glandes / Liquides / Excrétions /  
Sécrétions

# Bile / Gall / Gall Bladder



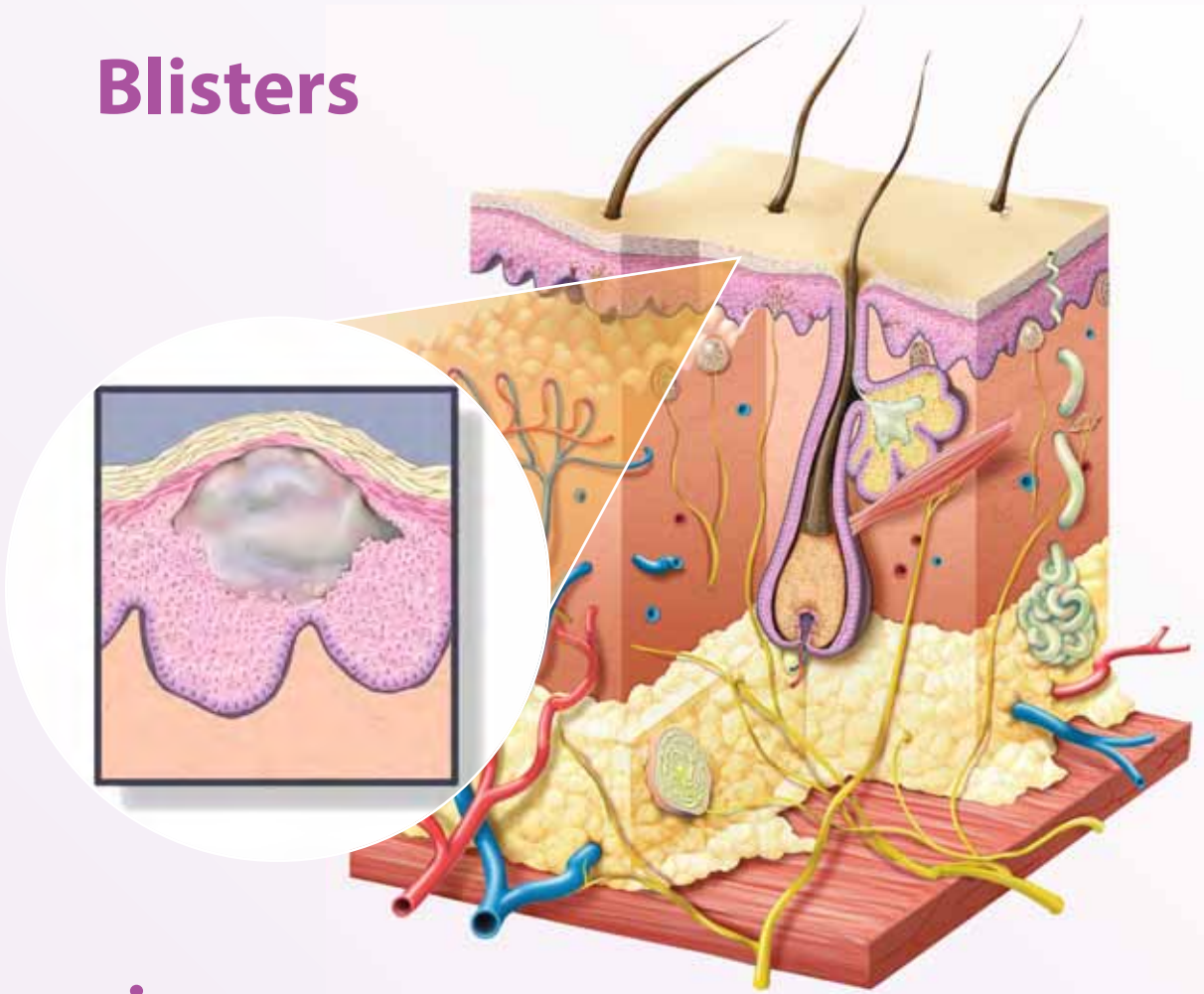
سۇنغاق

Sungaq

Hungaq

Bile, vésicule  
biliaire

# Blisters



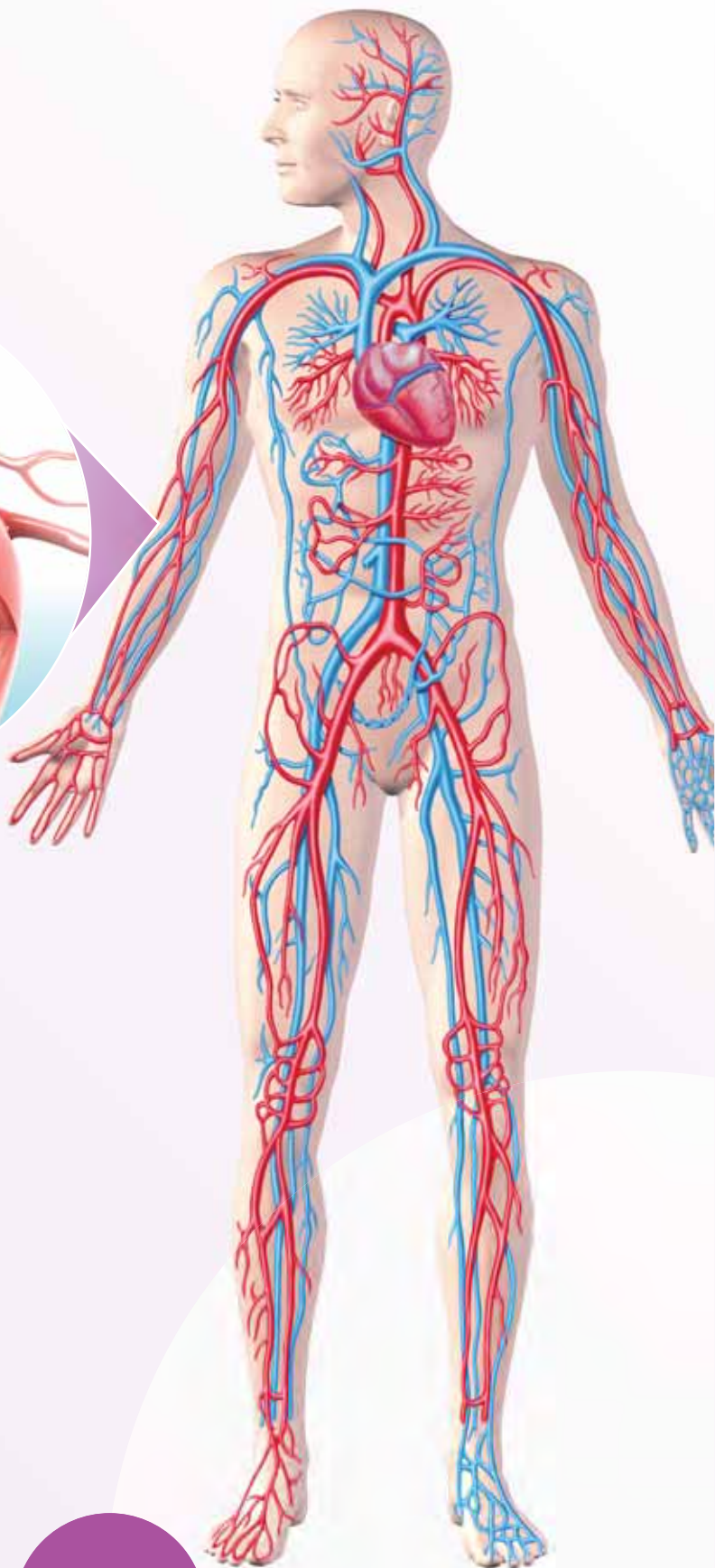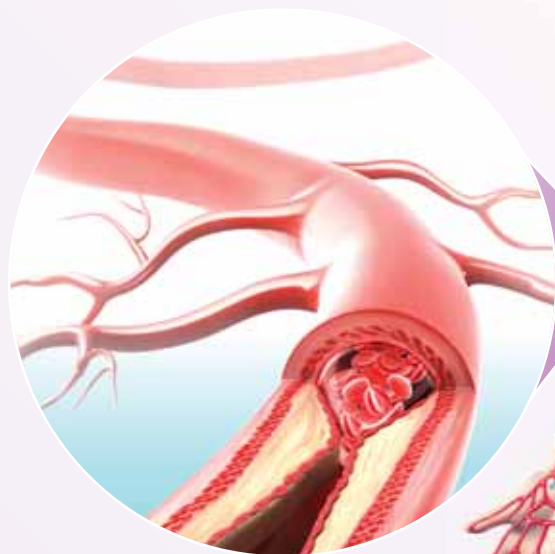
ᑭᑭᑭᑭᑭᑭᑭᑭ

Qaaqsurniit

Qaaqhuqtuq

Ampoules  
aux mains

# Blood



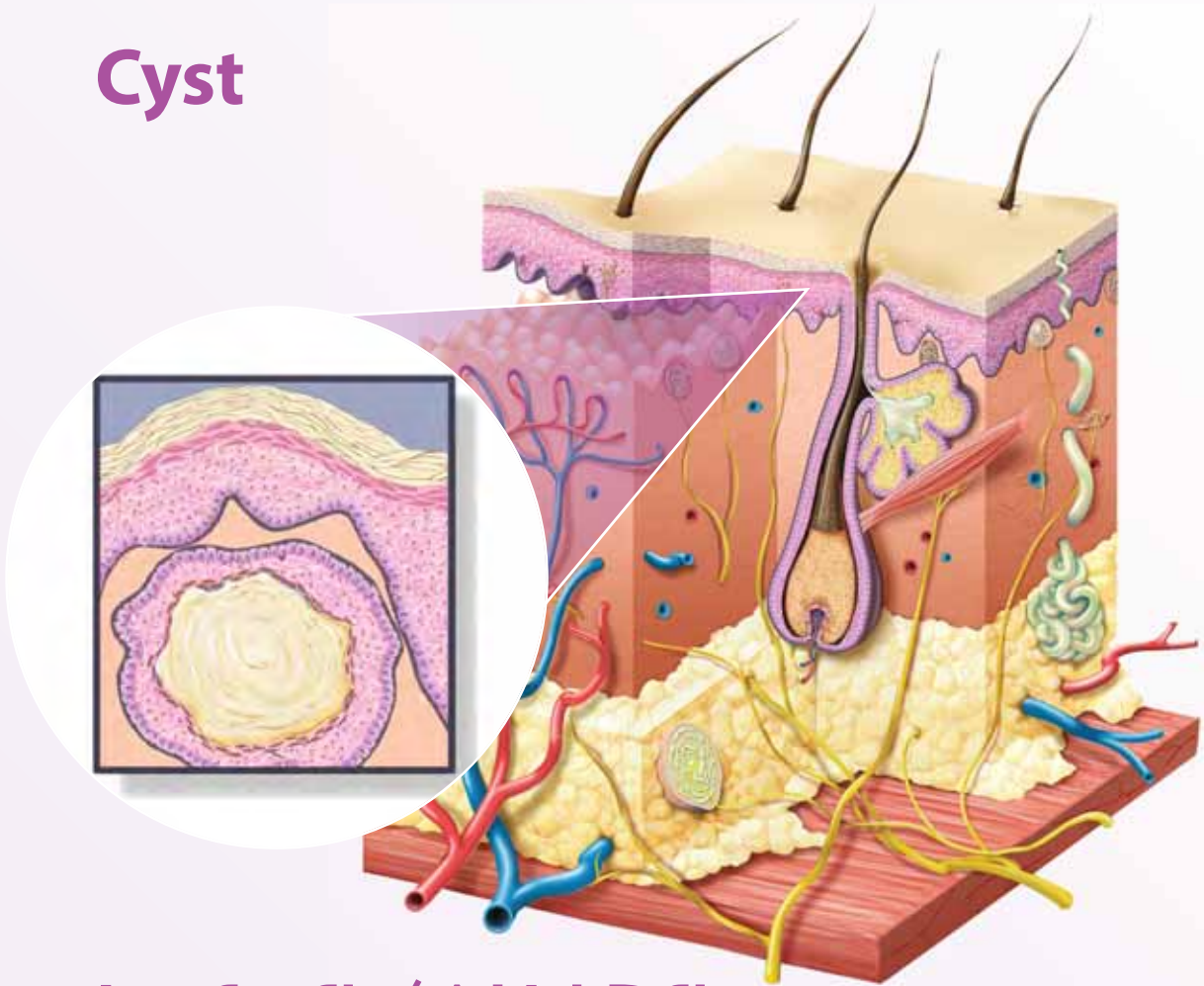
◀▶<sup>b</sup>

Auk

Auk

Sang

# Cyst



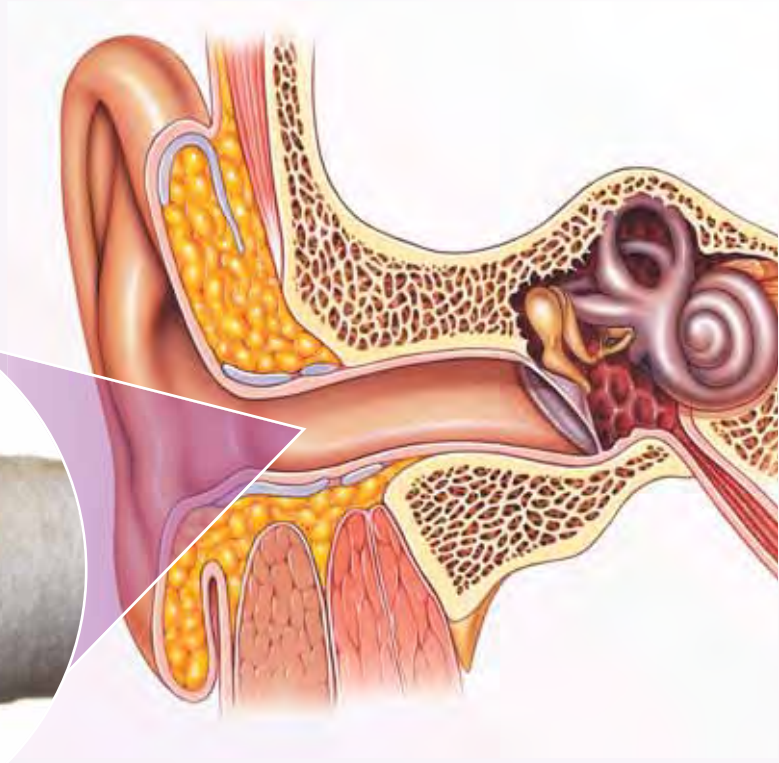
ԼժճՊճԵ / ՃԼԼԵԾճԵ

Manirnaq/immaktuq

Nauyiniq

Loupe

# Ear Wax



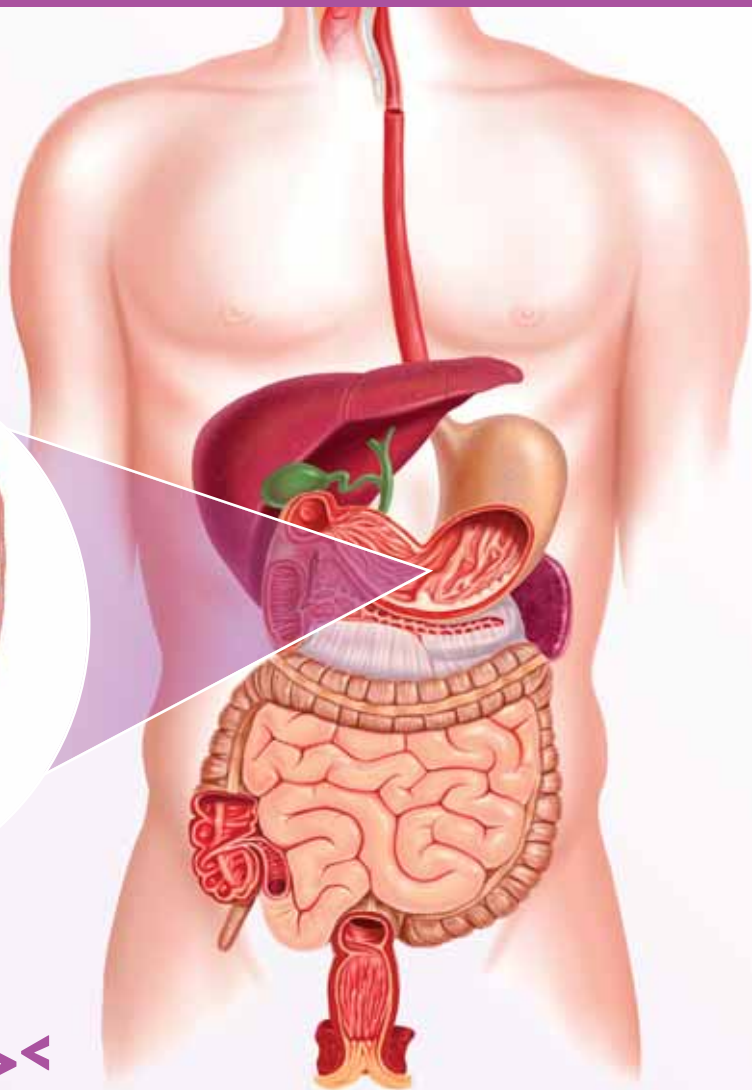
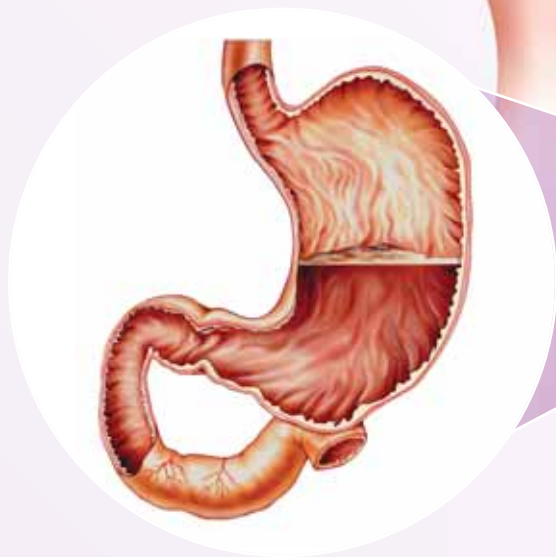ᑭᐃᑎᑦ ᐃᑭᑦᑭᑦ

Siutimit issaaqijuq

Hikhik

Cérumen/Tympan

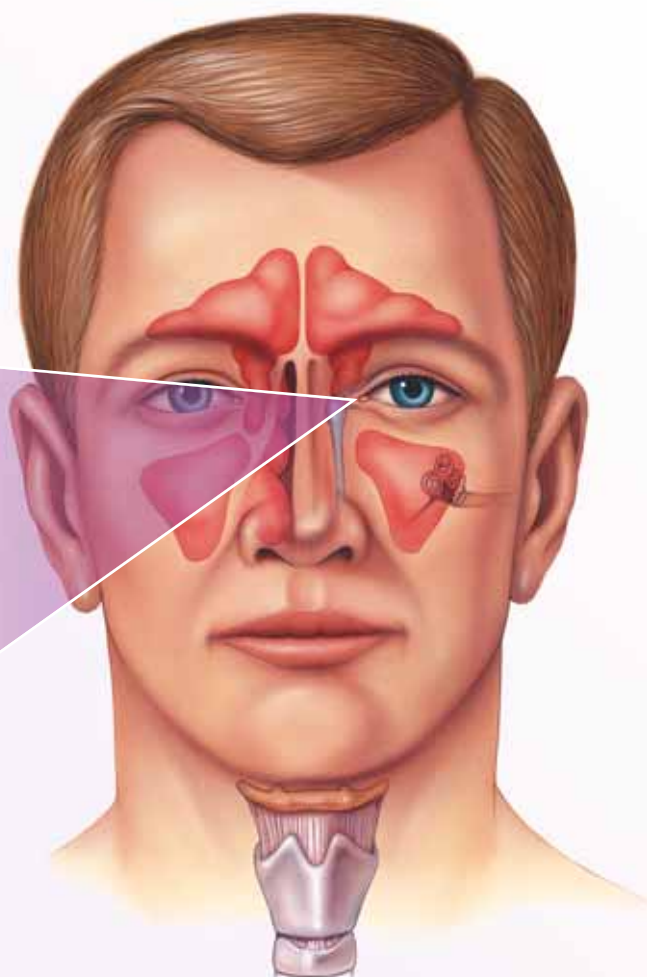
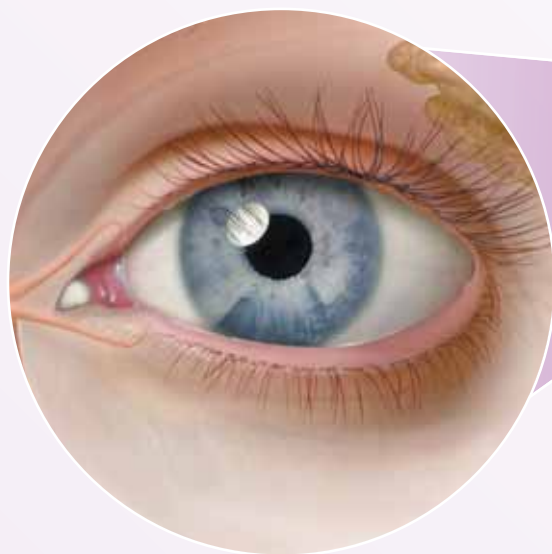
# Gastric Juice



ᐱᑦᓱᐱᓱᑦᓴᐱᑦ  
ᐱᑦᓱᑦᓴᐱᑦᓴᐱᑦ

Aqiarurmiup  
Aqilisautinga  
Hiirlan'nguniq  
Suc, muqueuse  
gastriques

## Gum at the Corner of the Eye



ⲓⲑⲡⲓ

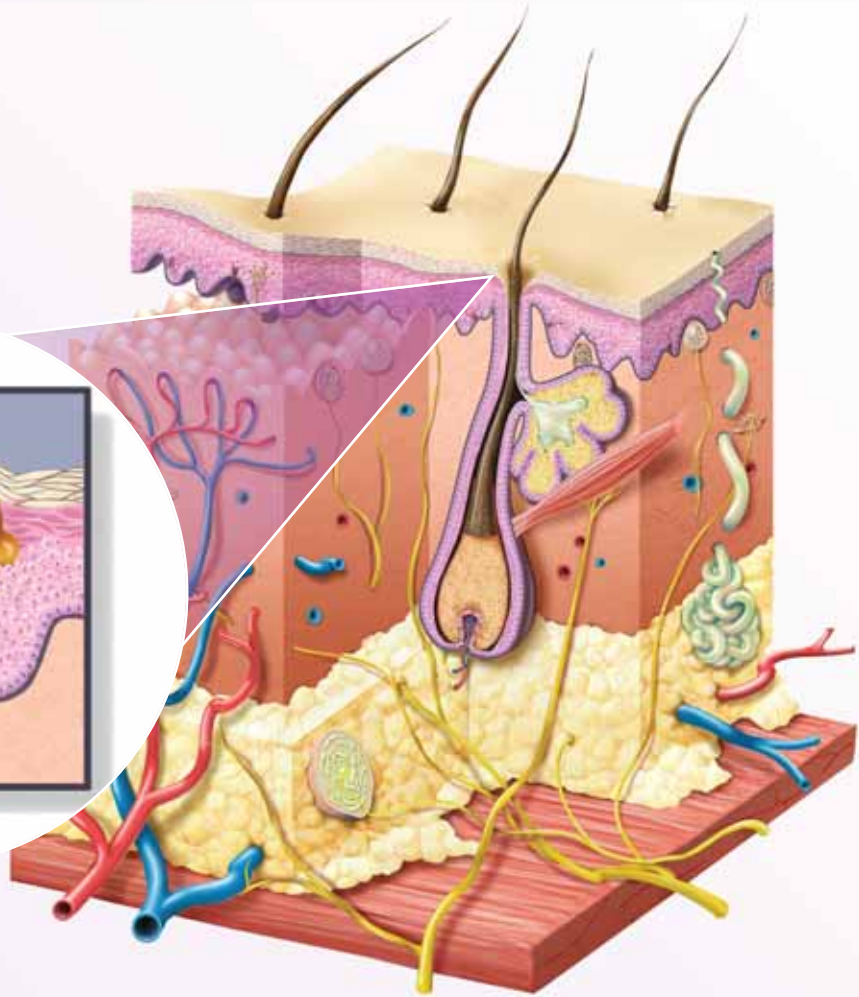
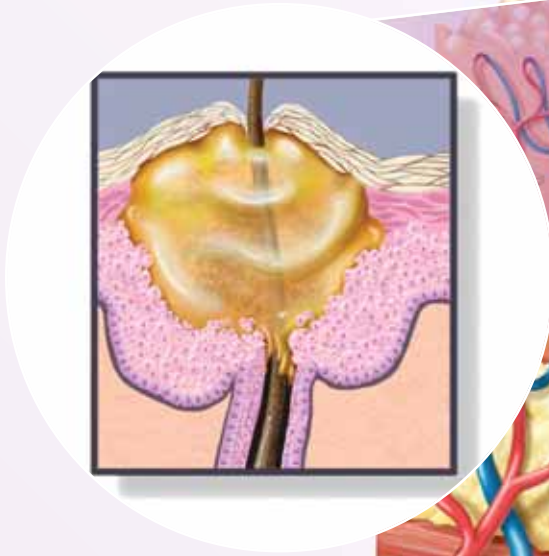
Siqpi

liluk

Sécrétion dans  
le coin de l'œil



# Pus



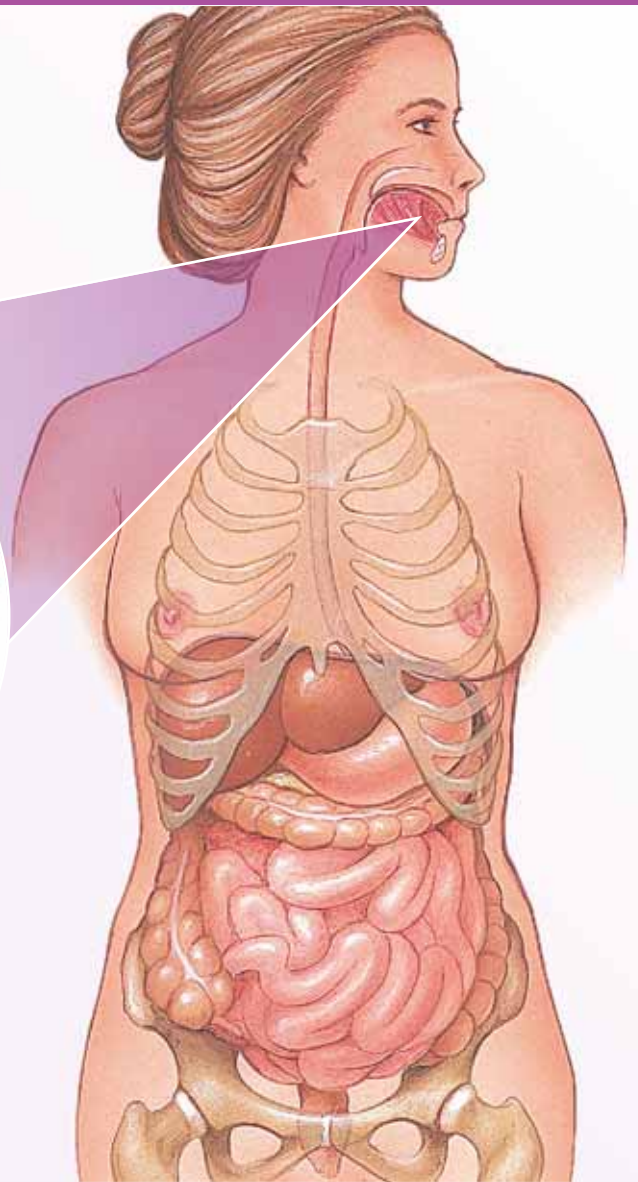
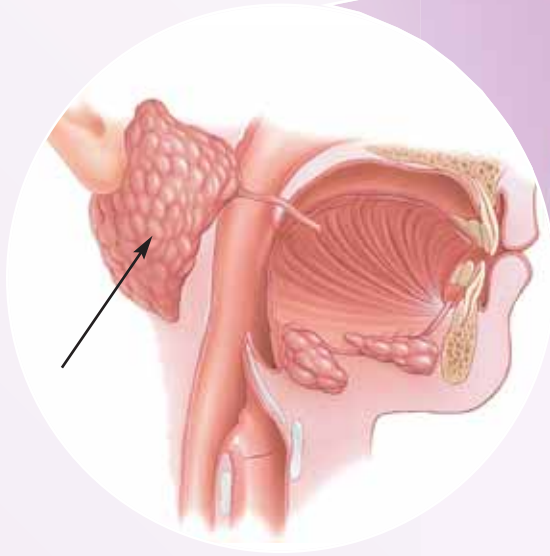
ΔΛ<sup>ε</sup>σ<sup>ς</sup>β

Immangniq

Qaquviraq

Pus

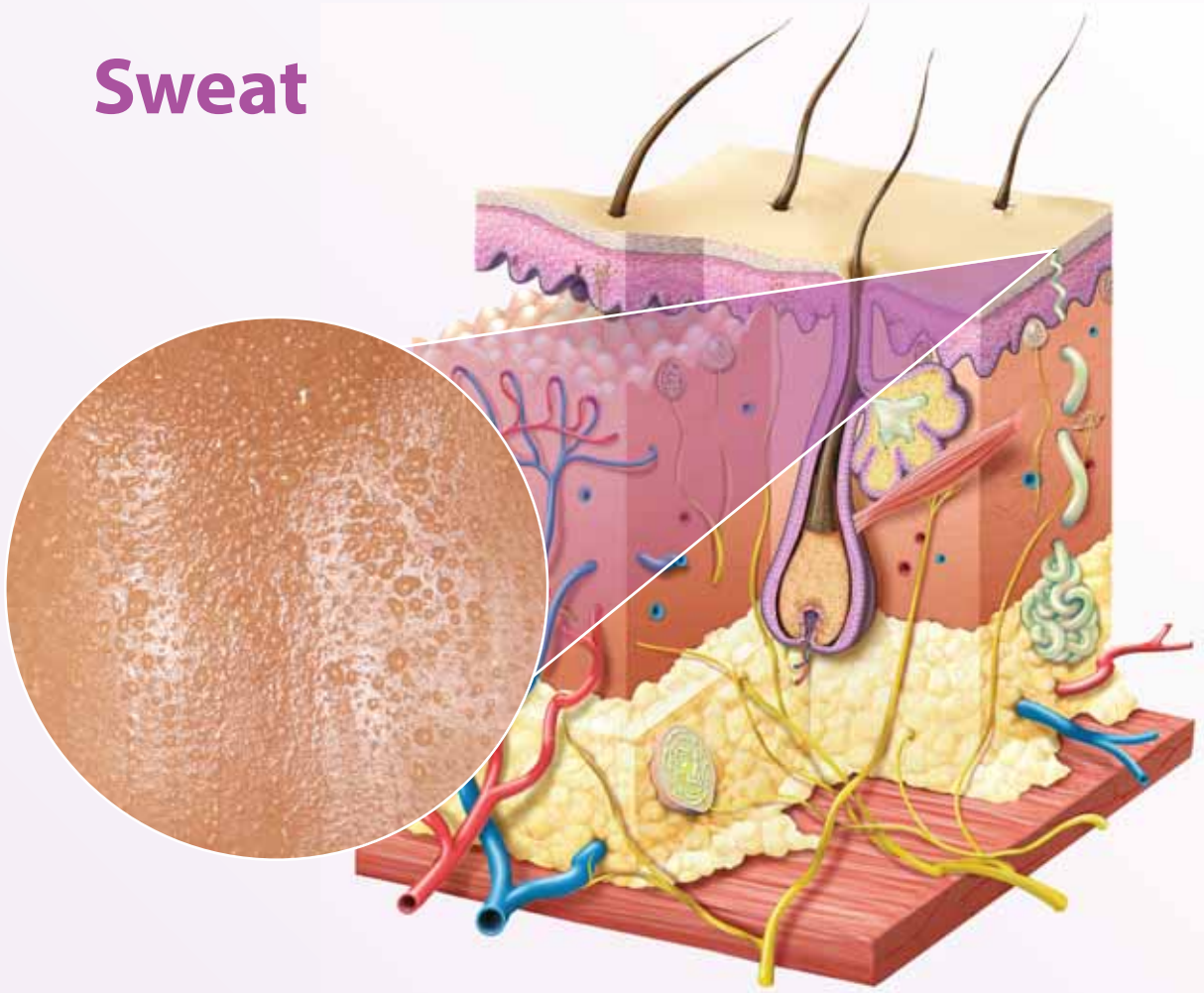
# Salivary Gland



ᑦᓱᑦᑕᑦᑕᑦᑕᑦᑕᑦ  
ᑕᑦᑕᑦᑕᑦᑕᑦᑕᑦᑕᑦ

Qiliqsinaq Nuvvaksarvik  
Nuvaqaut  
Glande salivaire

# Sweat



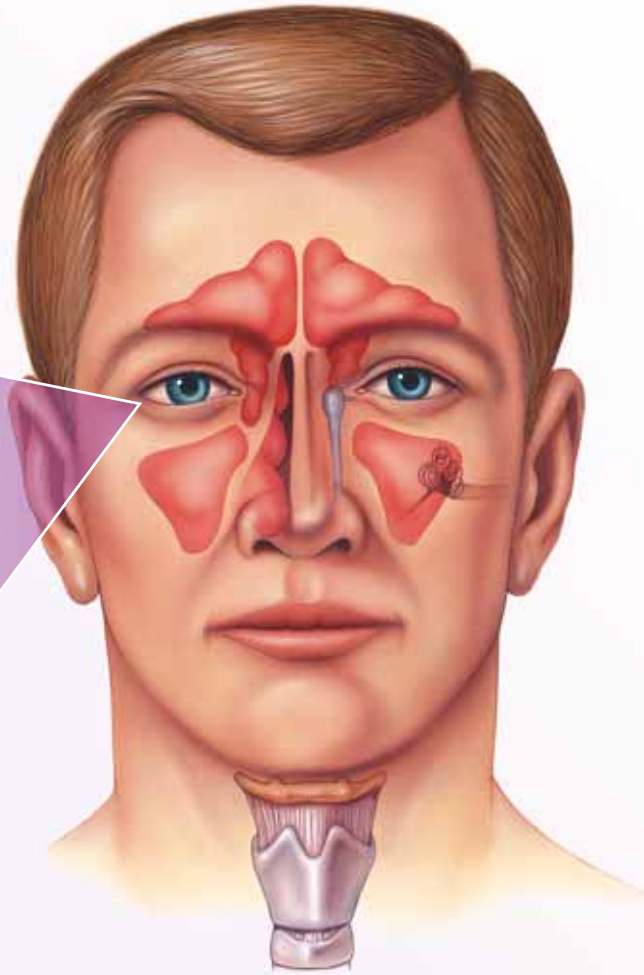
ᑭᓴᑦᑎᓴᑦᑎᓴᑦ

Kiaktisimajuq

Aumaallak

Sueur

# Tear



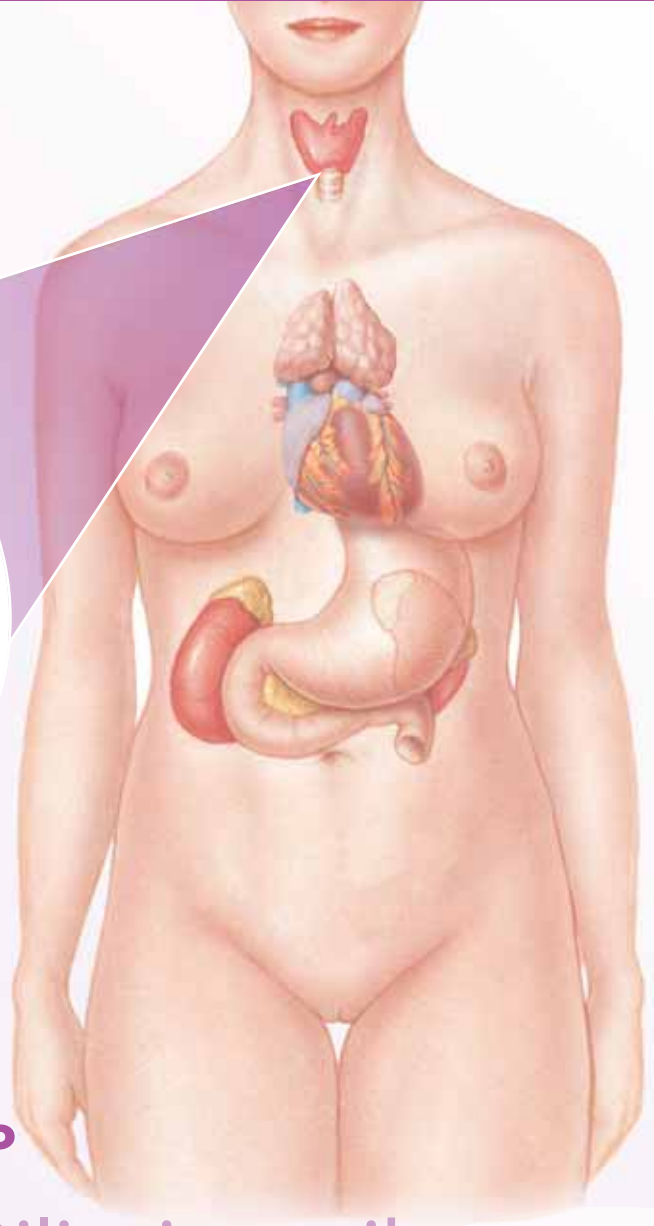
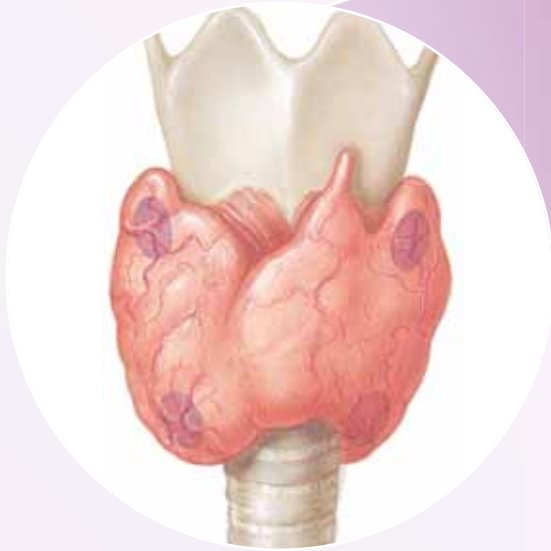
ᑭᑭᑭᑭᑭᑭ

Quvviq

Qulvik

Larme

# Thyroid and Parathyroid Glands



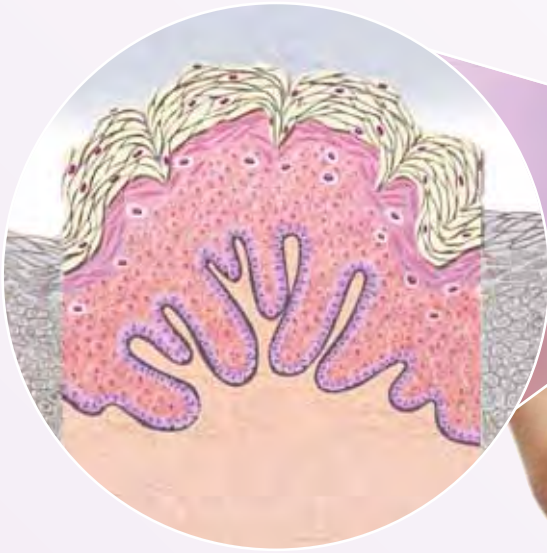
ᑕᑦᑲᑦᑲᑦᑲᑦ  
ᑦᑲᑦᑲᑦᑲᑦᑲᑦ

Tuqqujaap Qiliqsinangik

Tupquyaaq Qiniqhiit

Glands tyroïdes et  
parathyroïdes

# Wart



▷ ႁႃႈႁႃႈ

Unnguq  
Un'nguq  
Verrue

# Head/Face/Teeth/ Tongue

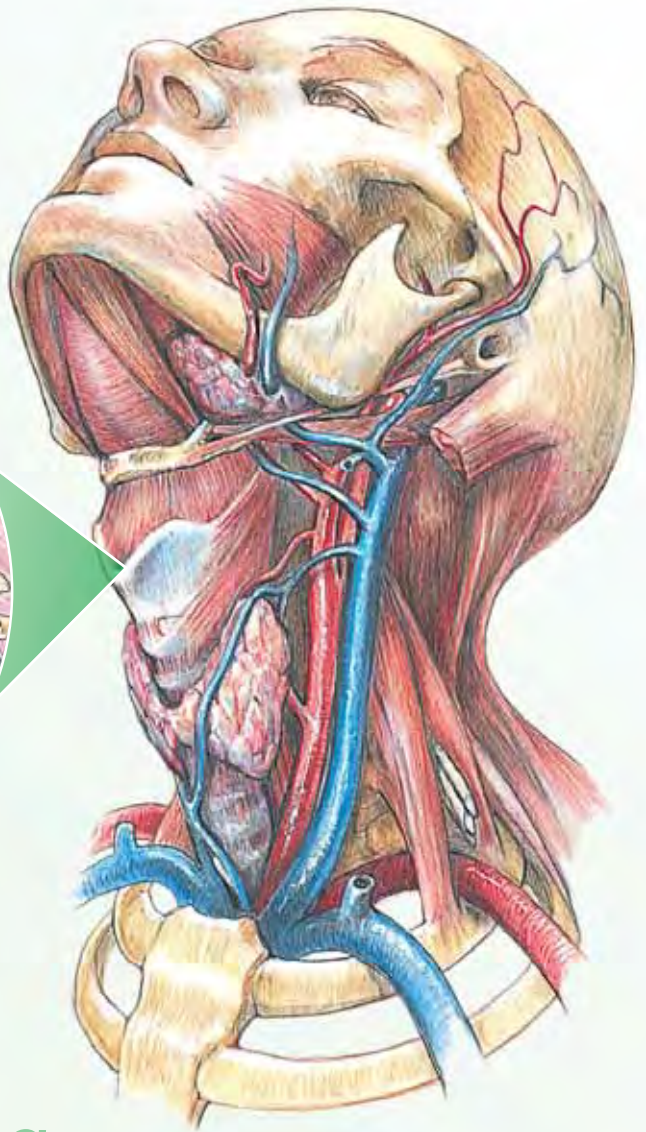
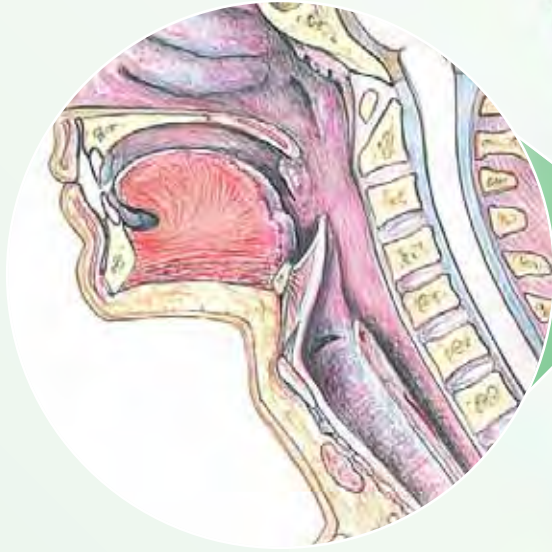σᐱᐅᐅᐅᐅ / ᐅᐅᐅᐅᐅᐅ / ᐅᐅᐅᐅᐅᐅ / ᐅᐅᐅᐅᐅᐅ

Niaquq/Kiinaq/Kigutit/Uqaq

Niaquq/Akuliak/Kigutit/Uqaq

Tête / Face / Dents / Langue

# Adam's Apple



ᐱᑦᑭᑦᑭᑦᑭᑦᑭᑦᑭᑦ

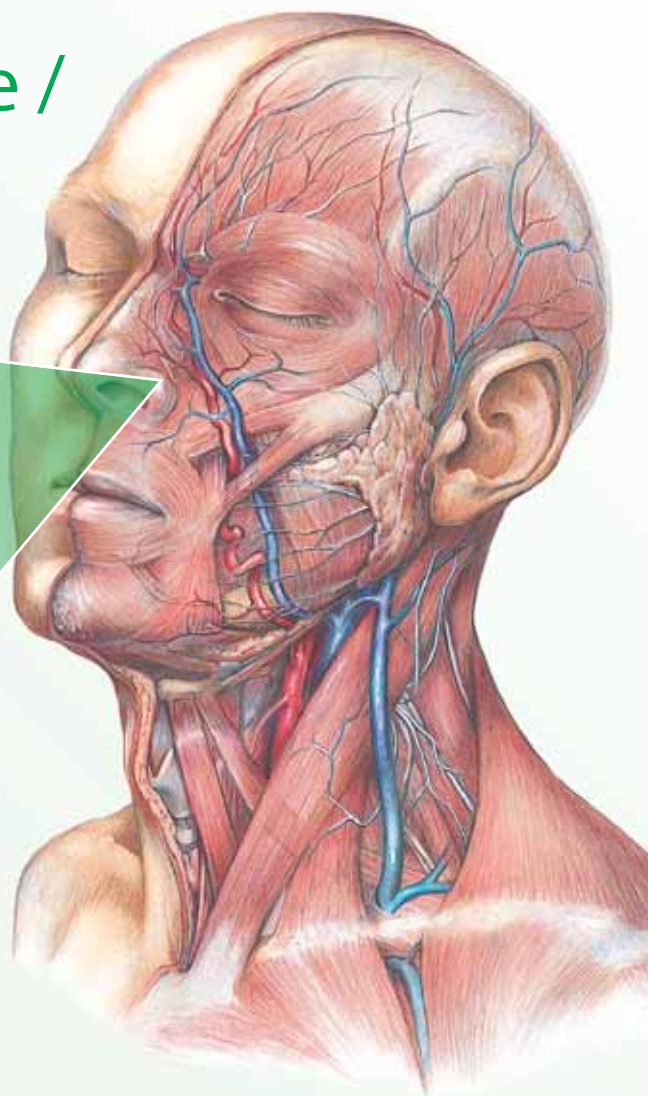
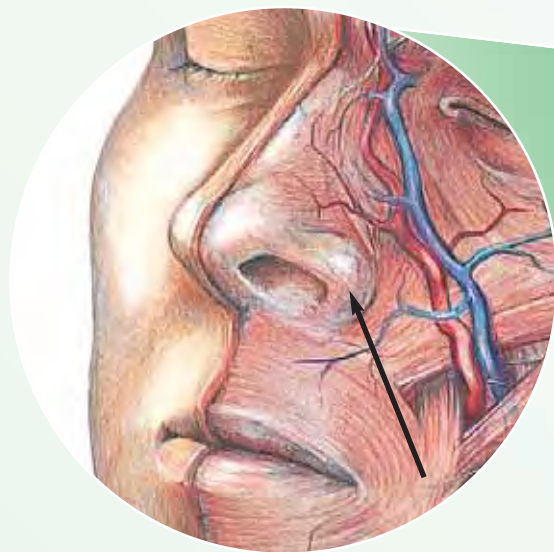
Qingannuaq

Iggialhuq/Iggiaqquq

Pomme d'Adam



# Ala of the Nose / Nose Wing



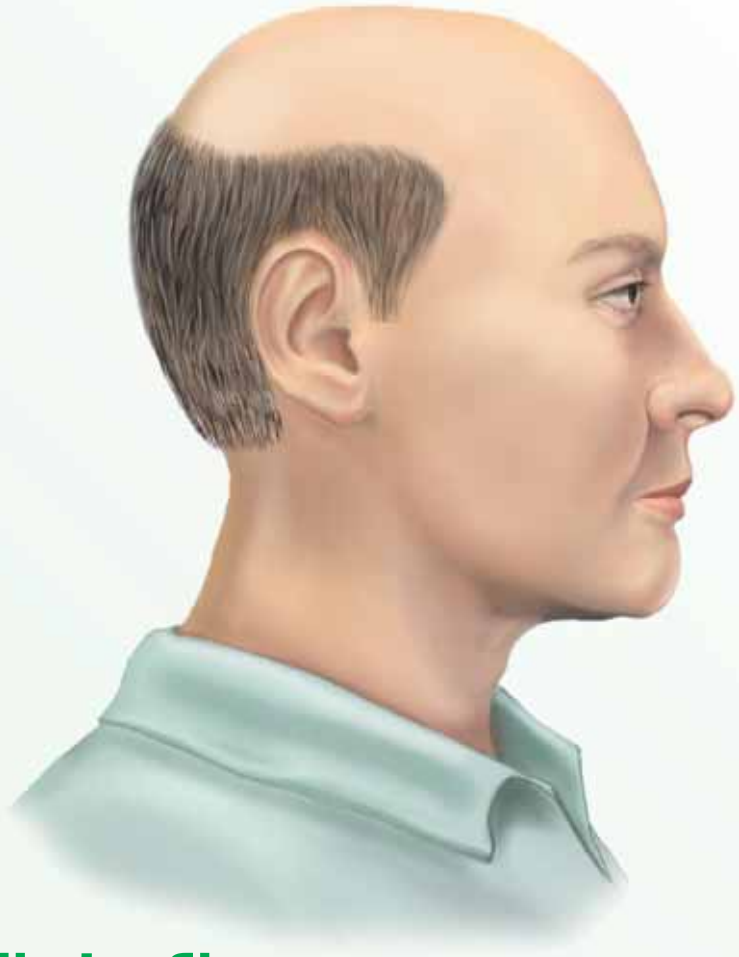ᑕᑦᑲᑦᑕᑦᑲ

Taqpaq

Natatquaq

Aile du nez

# Bald



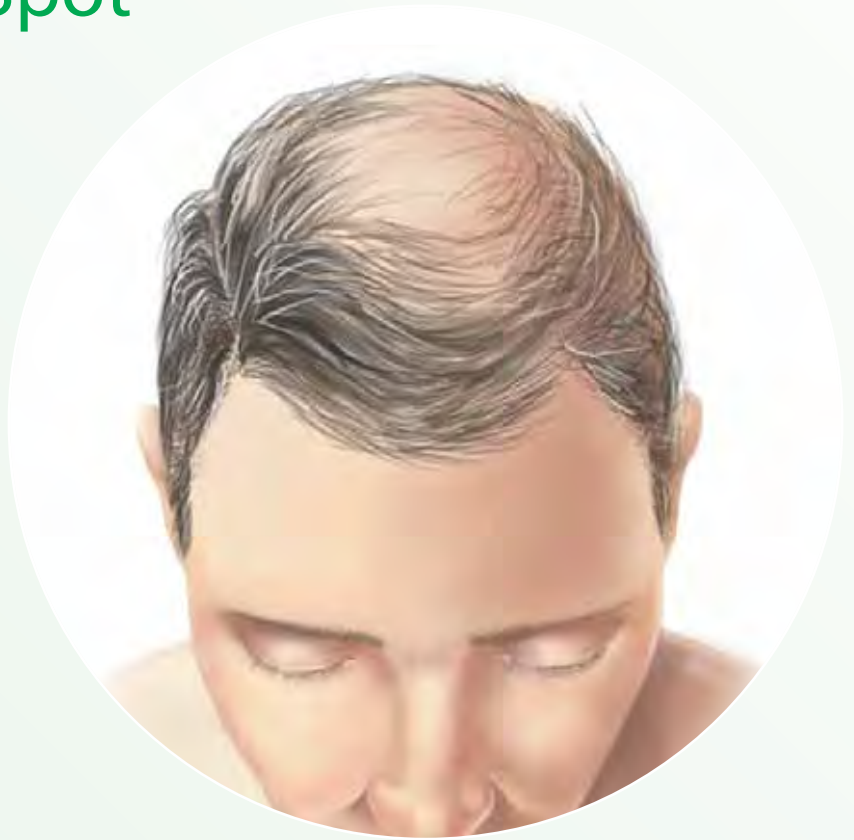
ᐱᐸᐃᐸᐃᐸᐃᐸᐃᐸ

Miqquiqsiniq

Mitquirniq

Chauve (être)

# Bald Spot



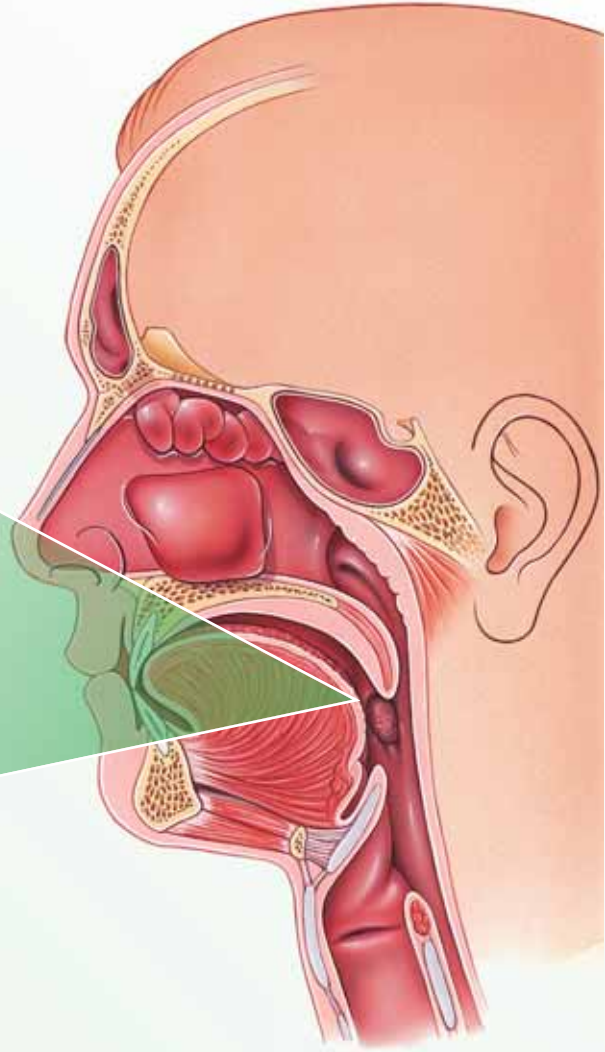
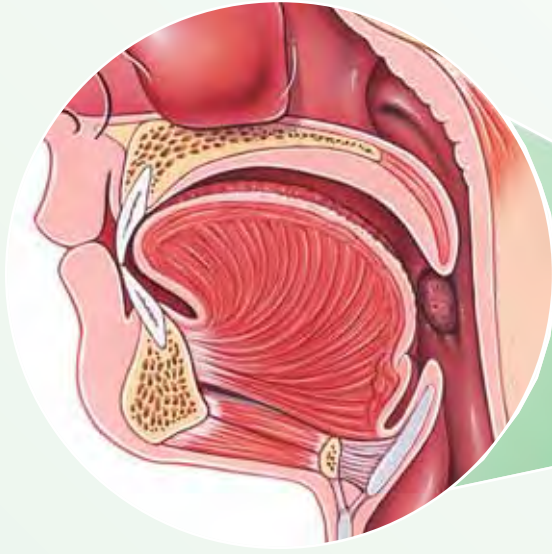ᐱᐱᐱᐱᐱᐱᐱᐱᐱᐱ

Miqquiqtuq

Mitquirniq

Chauve, sans poil (être)

# Base of the Tongue



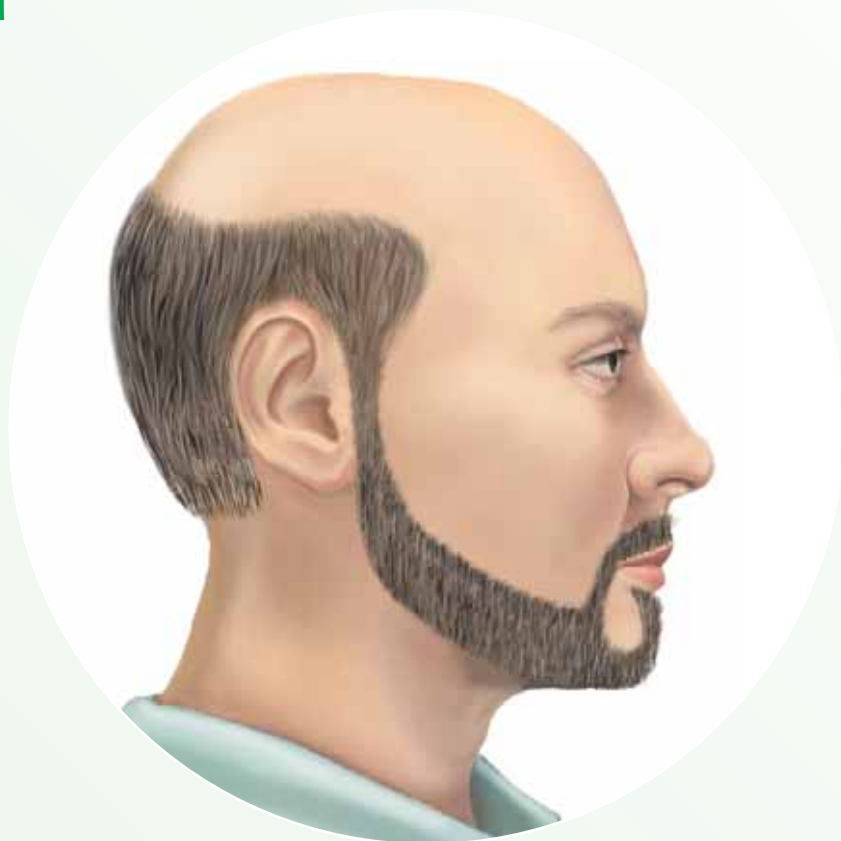ᐅᑦᑲᐅᑦ ᑲᑦᑦᑦᐅ

Uqaup Kangia

Uqaup Nuqirutaa

Base de la langue

# Beard



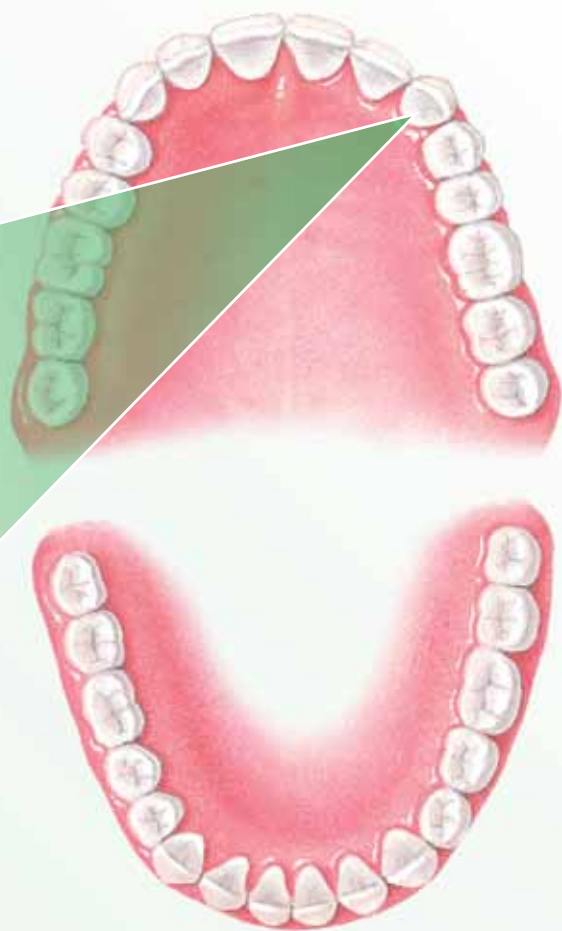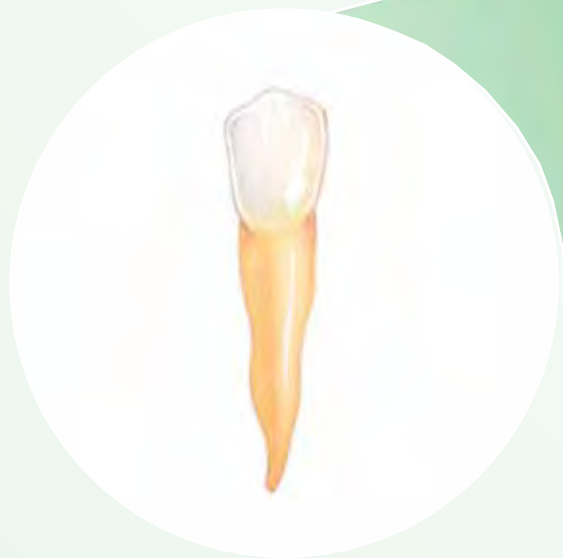▷Гб

Umik

Umik

Barbe

# Canine



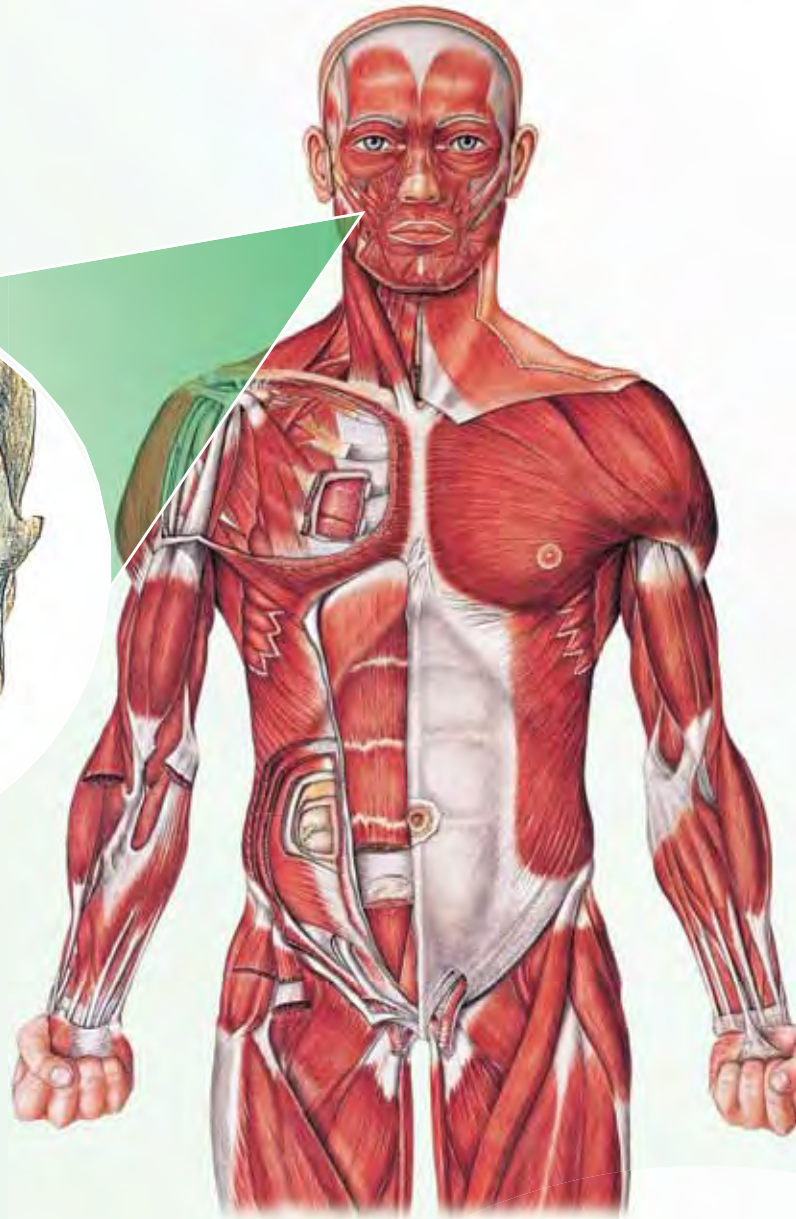
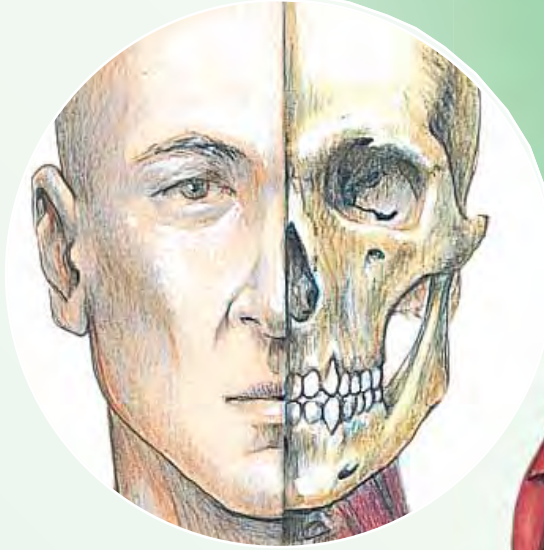تولوریاق

Tuluriaq

Tuluriaq

Canine

# Cheek



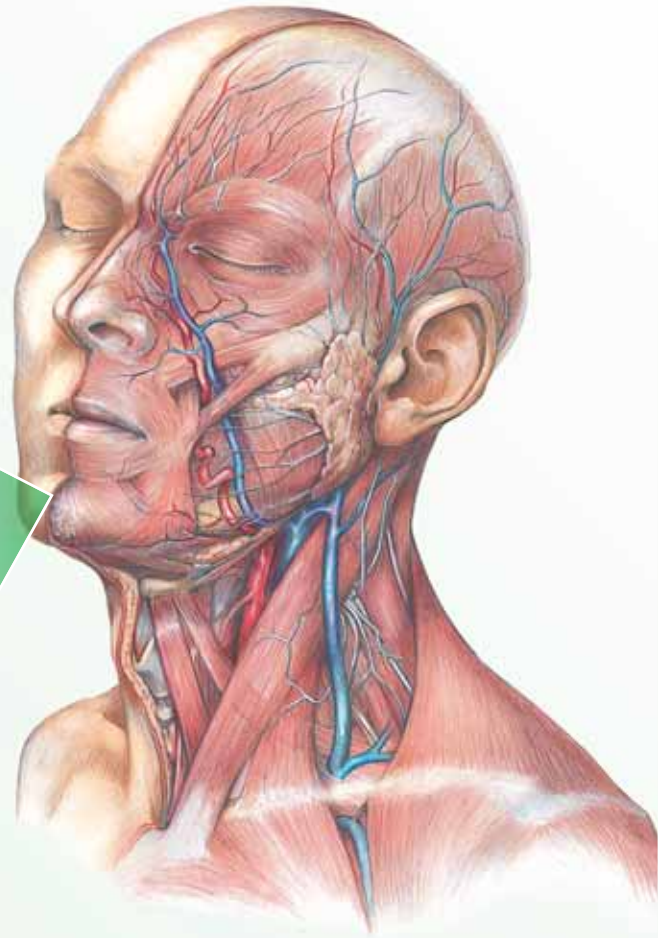
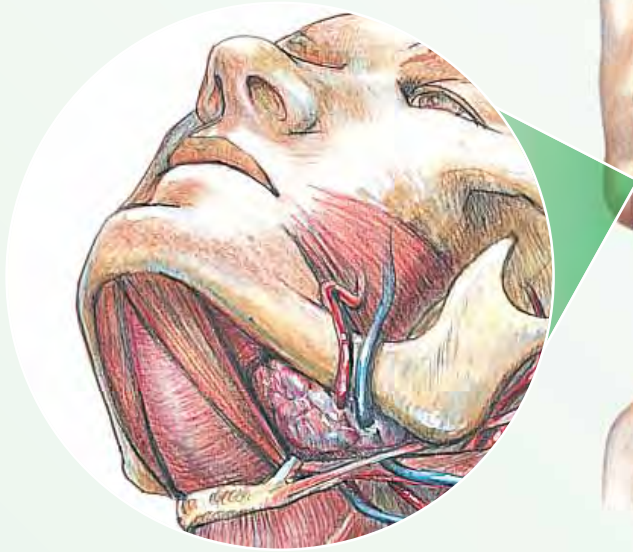Uluak

Uluak

Uluak

Joue

# Chin



چن

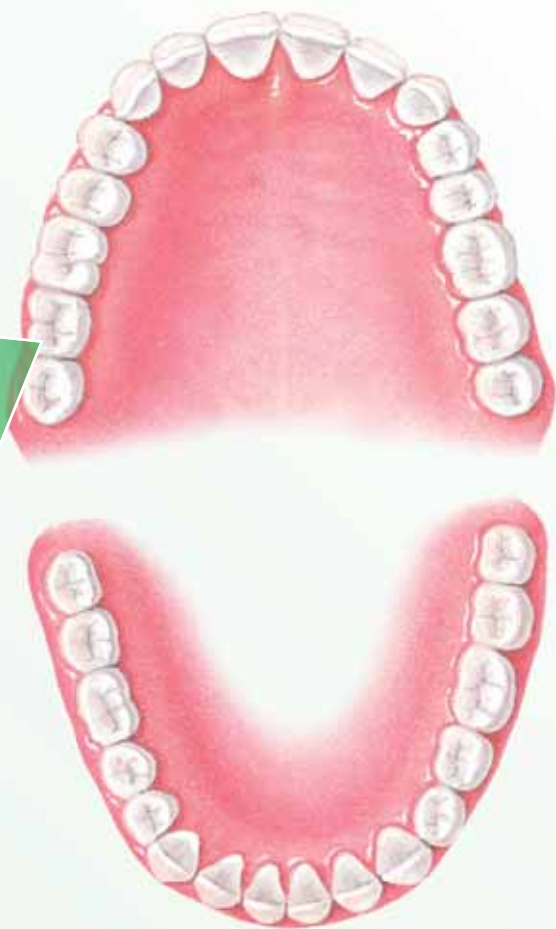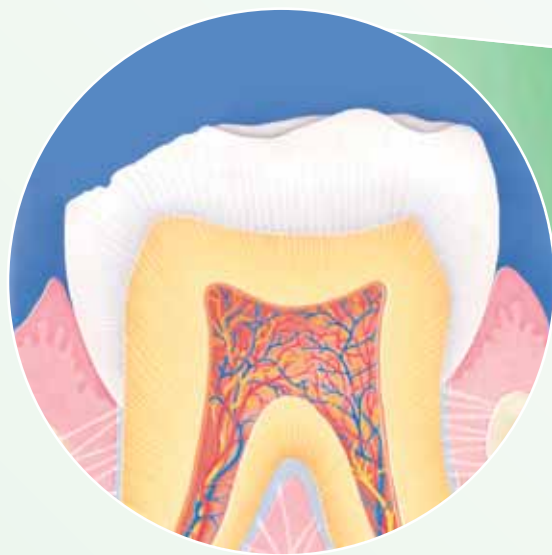Tallu

Tablu

Menton



# Chipped Tooth



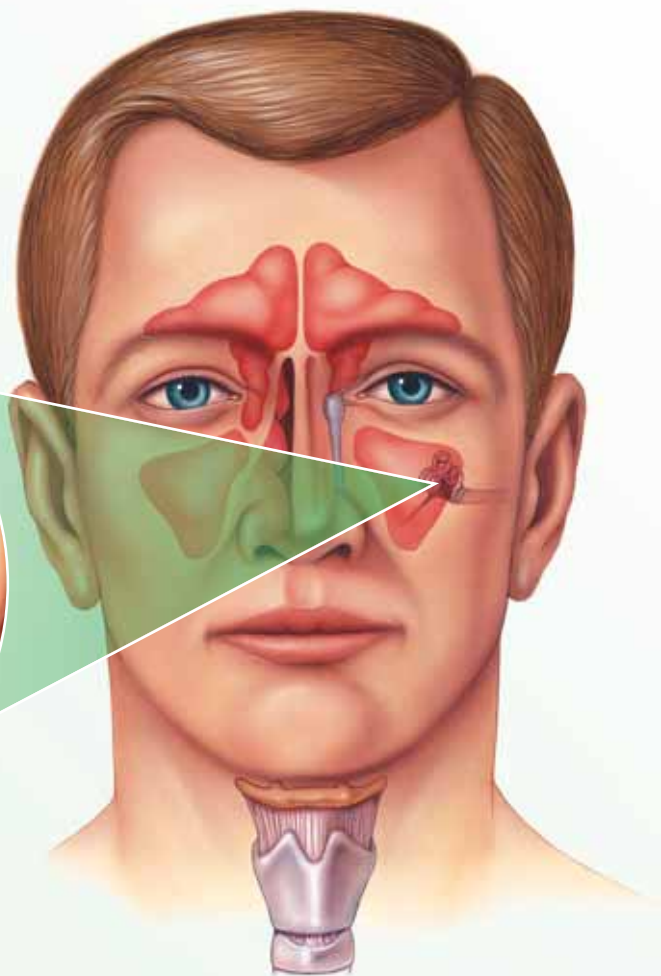
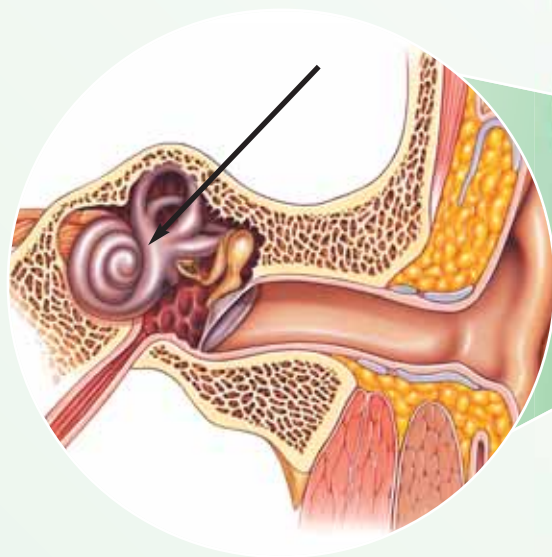
ᐃᑦᑕᑦᑕᑦᑕᑦᑕᑦ

Uliqsimajuq

Kigutip Ahiqua

Dent ébréchée

# Cochlea



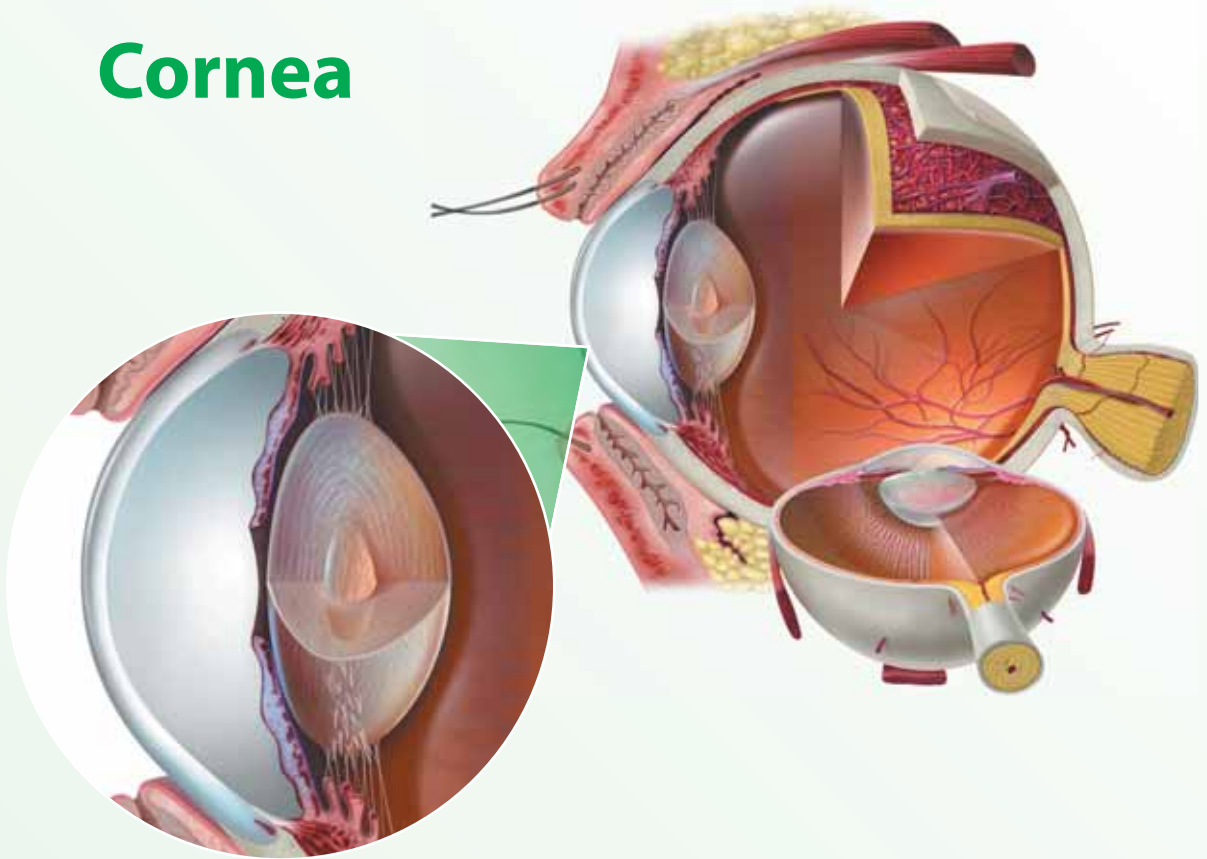
ᐱᐅᐅᐅᐅᐅ

Siunnaq

Hiutip Kapihianga

Cochlée ou limaçon

# Cornea



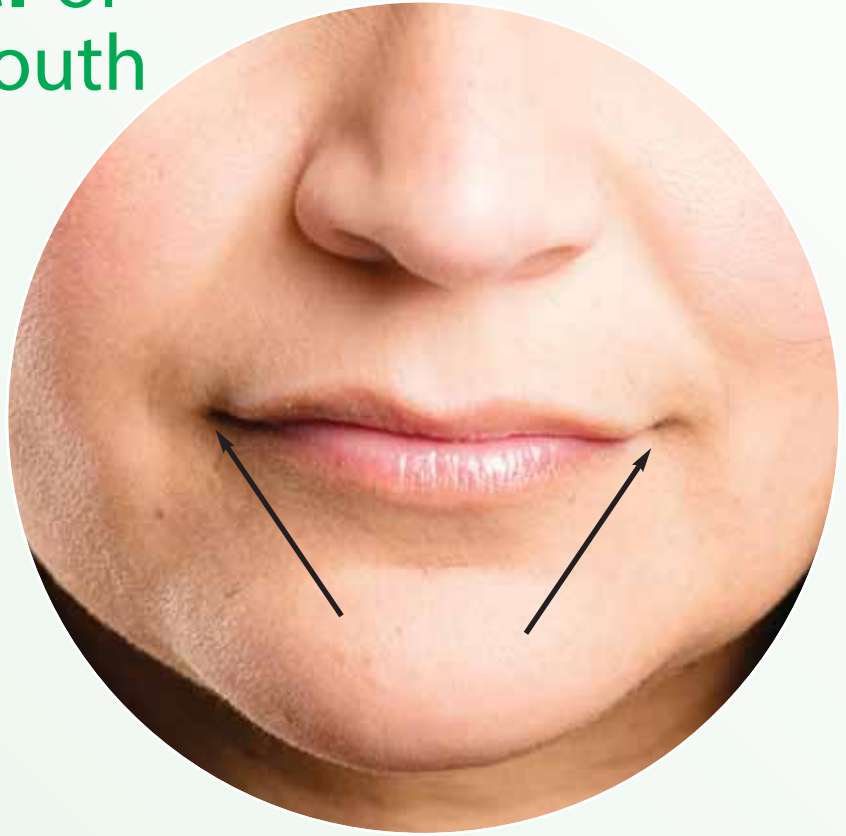ᐃᓱᐃᑦ ᐃᓕᓕᐃᓴᓴᓴᓴᓴᓴᓴᓴ

Ijiup Igalaujanga

Iyip Kapihianga

Cornée

## Corner of the Mouth



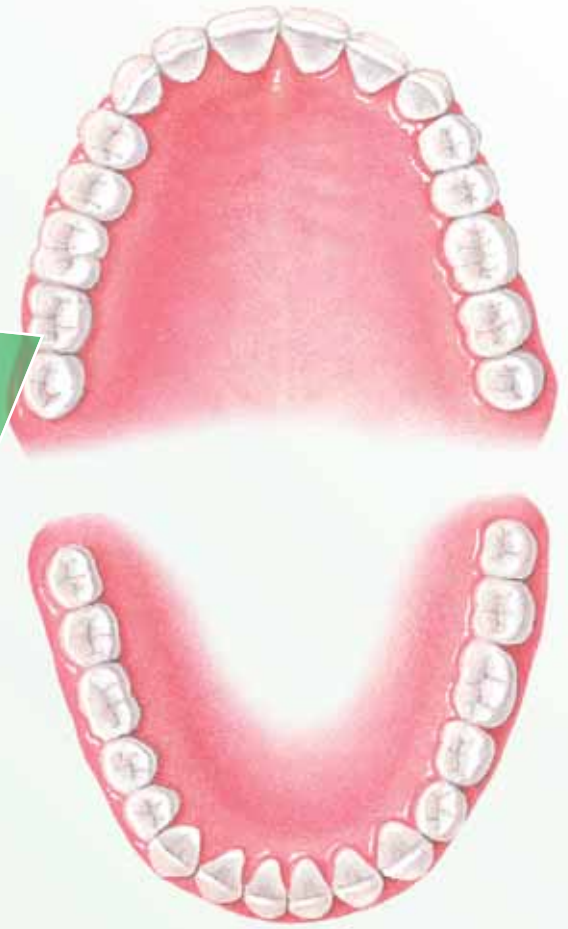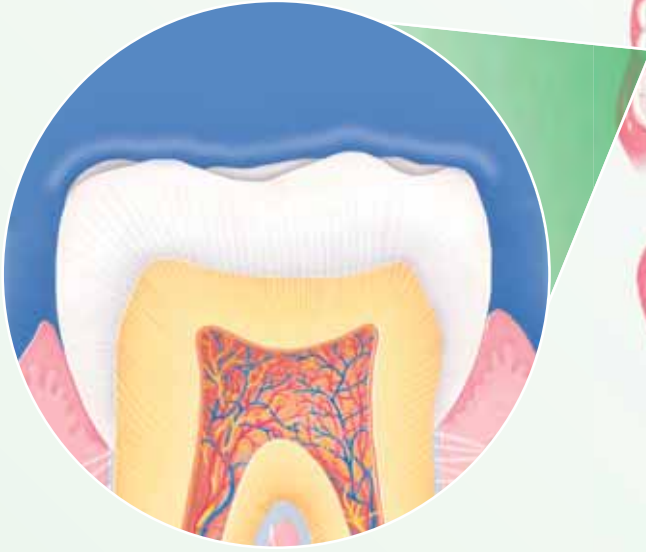
Δ<sup>ϕ</sup>ρ

lqi

lqik

Commissure des lèvres

# Crown of the Tooth



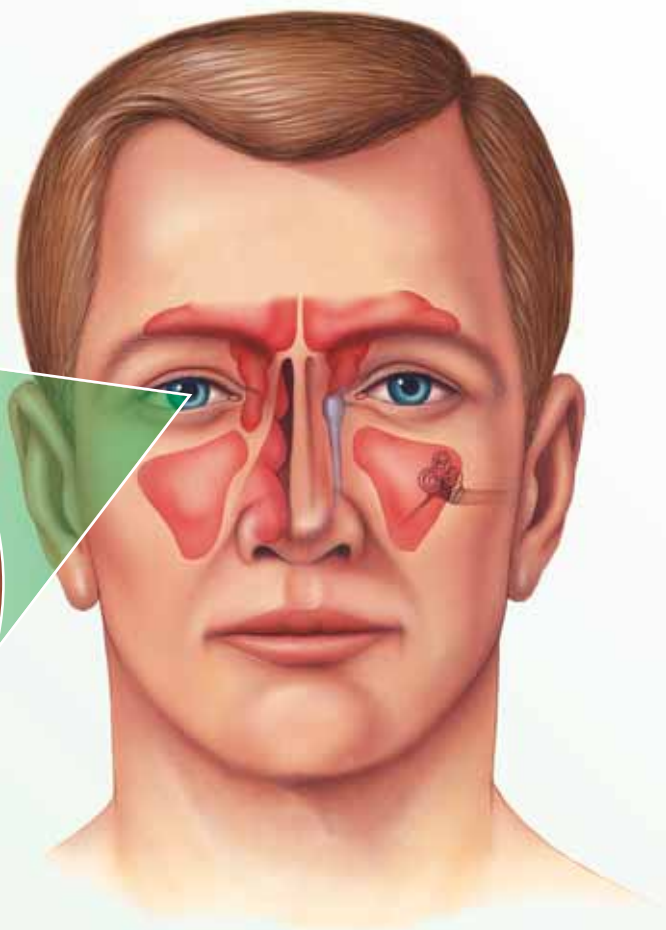
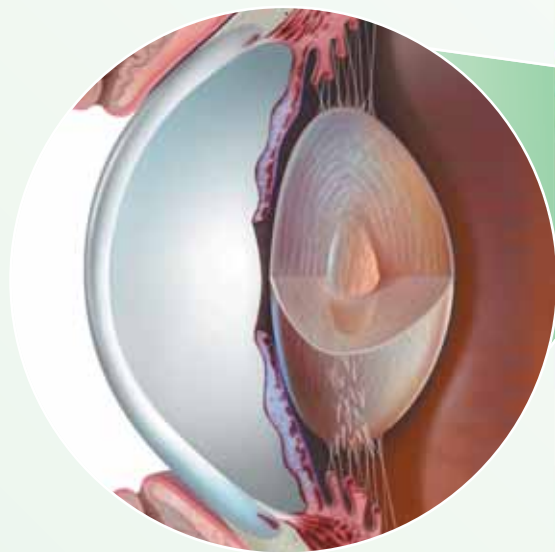
ᐱᑭᑦᑲᑦᑲᑦ ᑦᑲᑦᑲᑦ

Kigutiup Qaanga

Kigutip Qaanga

Couronne de la dent

# Crystalline Lens / Pupil



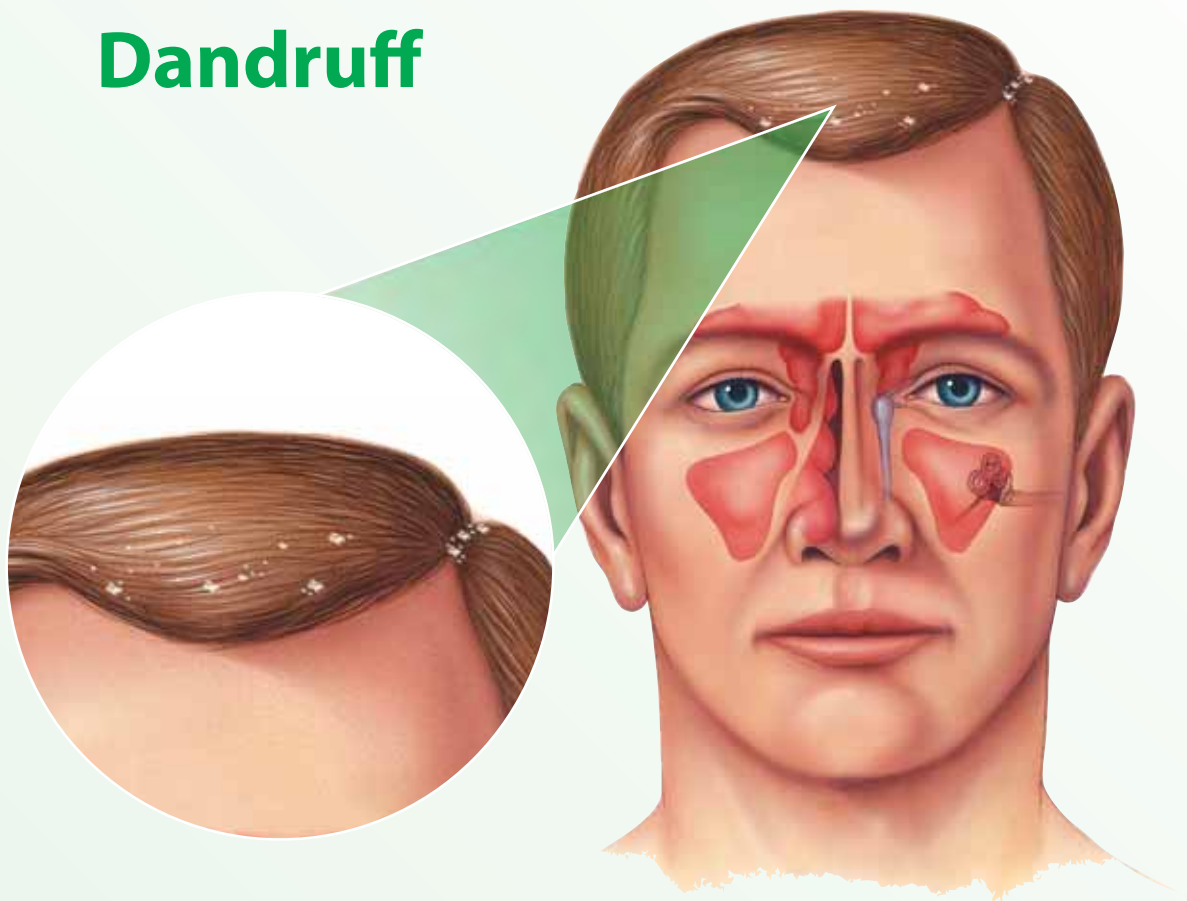
Δ↳P◁ᵇ

Ijaruvak

Takkuvik

Cristallin (pupille)

# Dandruff



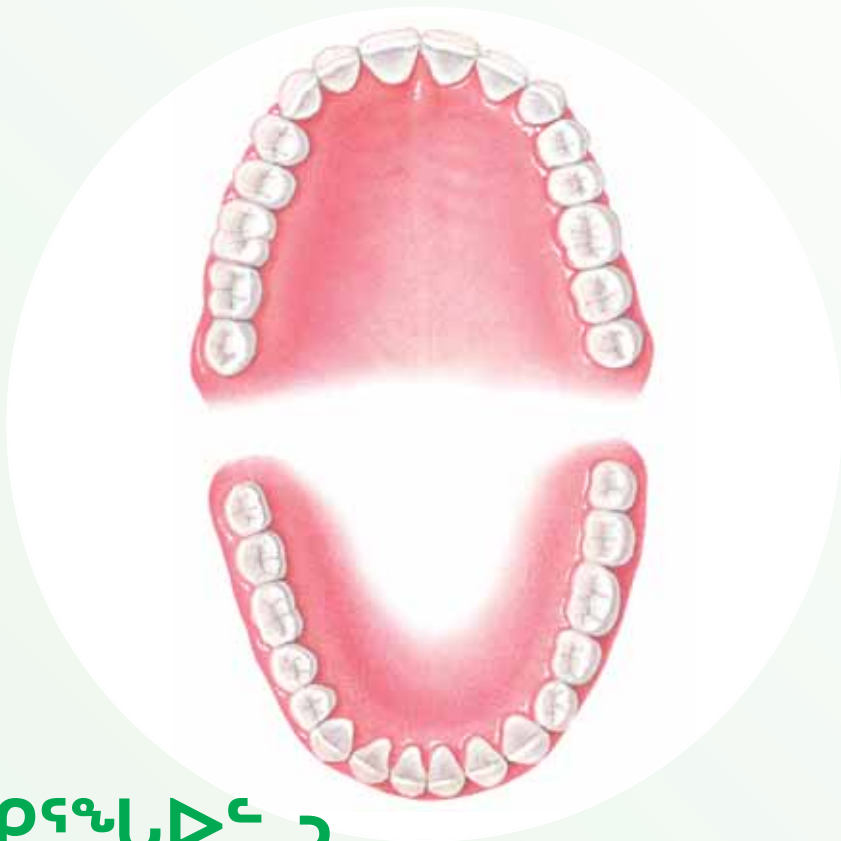ЛІ ԳԵ

Mamaaq

Qaglik

Pellicules

# Dental Arches



ՄԱԳԻՐՆԵՆԻՍԻՆ

ՎԵՆԵՐՆԻՍ ԿՆԵՐՆԻՍ

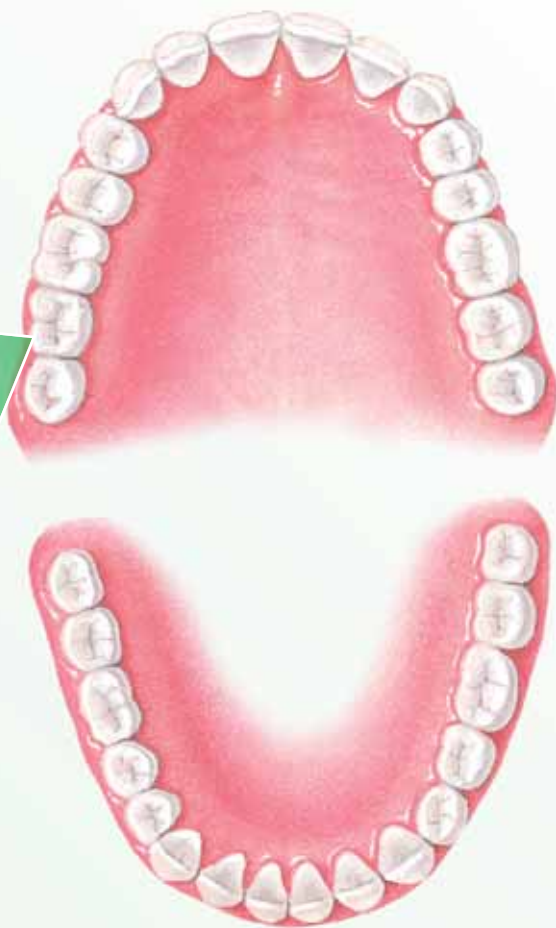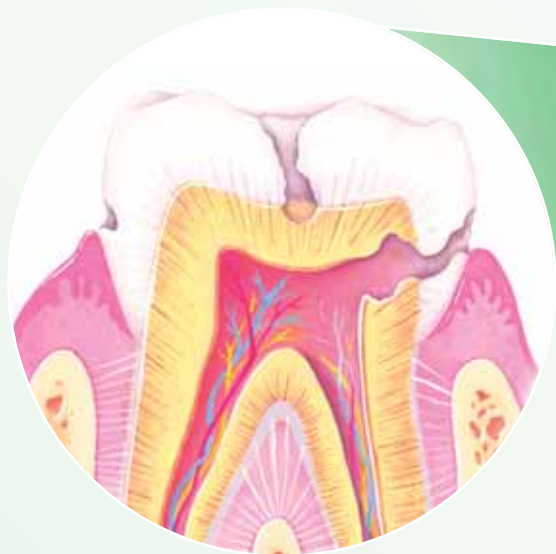
Niaqqirngaullu Agliruullu  
Apuqtarninga

Kigutiqarvik

Arcades dentaires



# Dental Carie



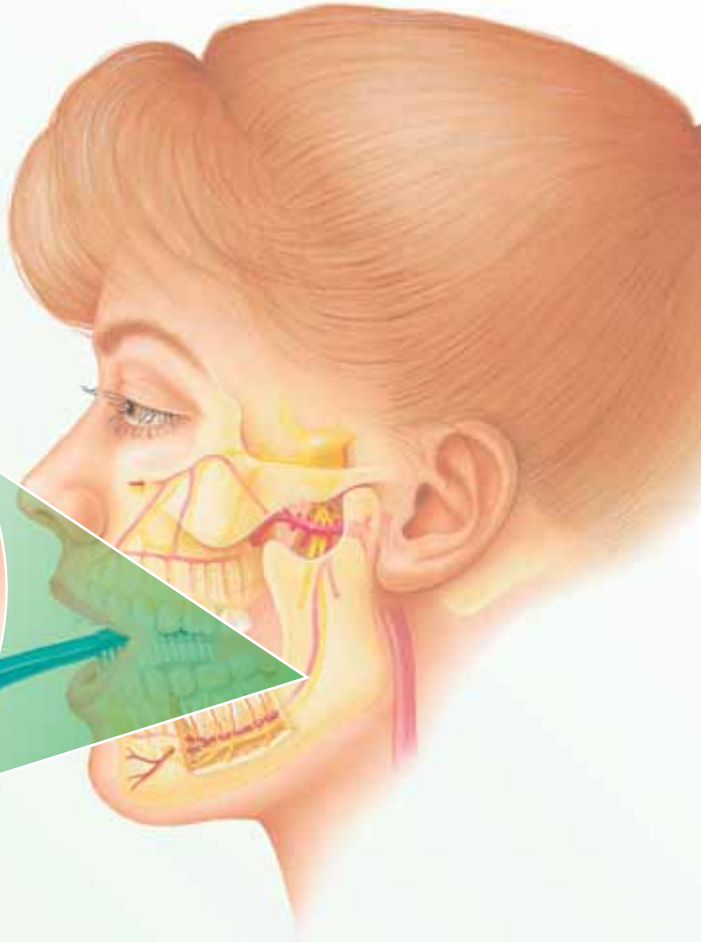
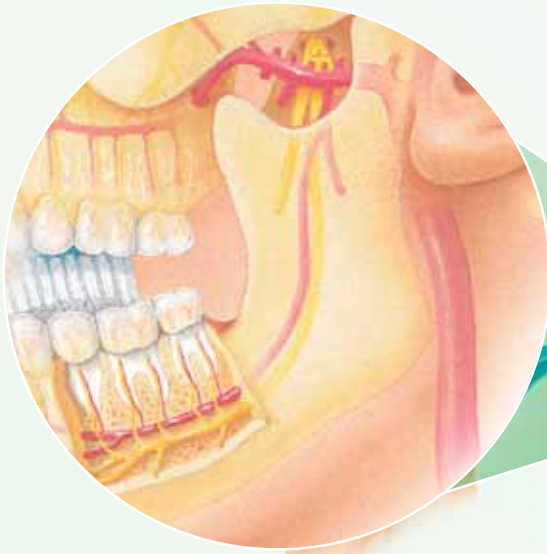ԲՅՈՒՆՆԵՐ ԿԻՏՈՒՄ

Kigutiup Auninga

Kigut Auhimayuq

Dent cariée

# Dental or Alveolar Nerve



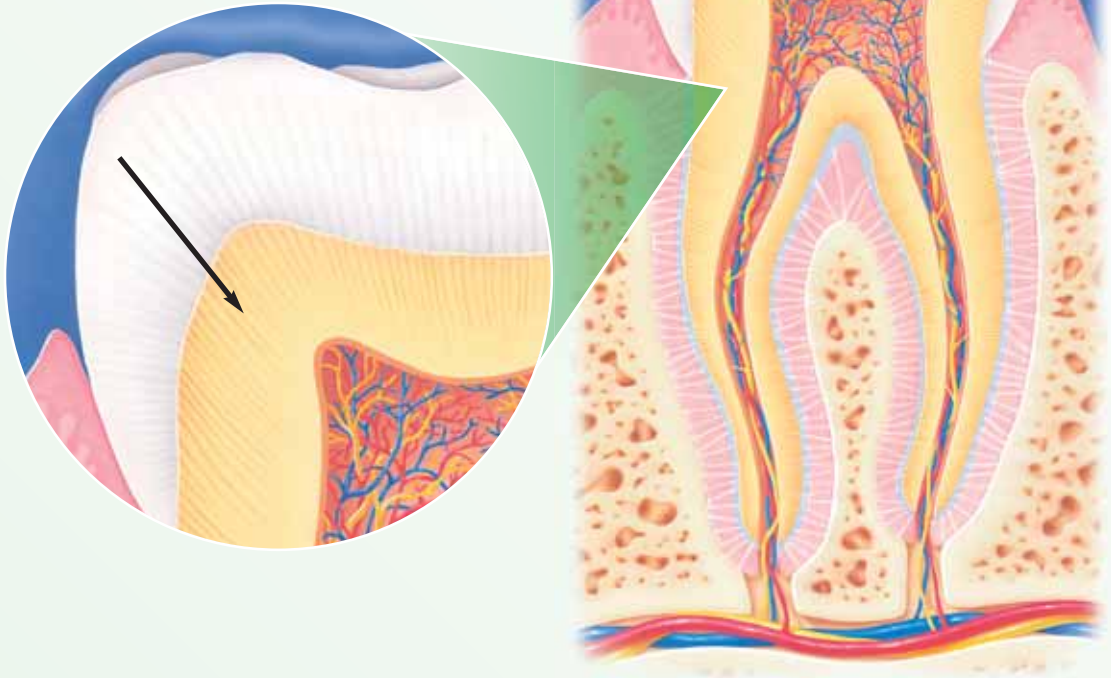
ΡΥΚΟ Δ<sup>β</sup>Λ<sup>α</sup>σ<sup>α</sup>Δ<sup>λ</sup>ρ<sup>ο</sup>ρ<sup>ο</sup>

Kigutit Ikpingniajjutingit

Kigutip Attataa

Nerf dentaire ou alvéolaire

# Dentin, Ivory



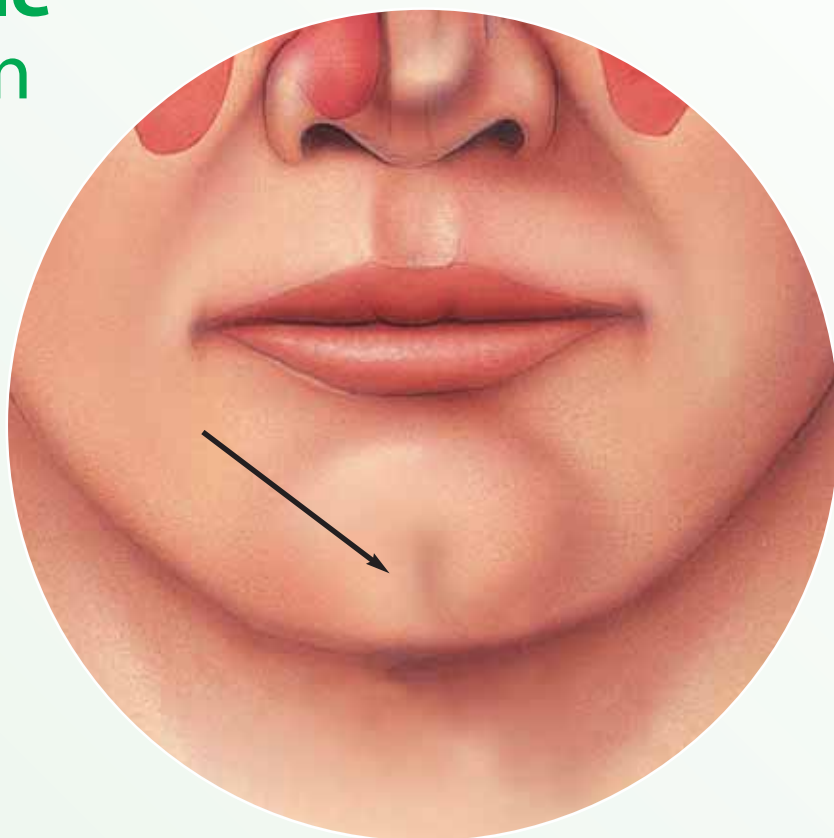
ᑭᑭᑭᑭᑭᑭ ᑭᑭᑭᑭᑭᑭ

Kigutiup Aqinninga

Kigutip Qaanga

Couronne de la dent

# Dimple of Chin



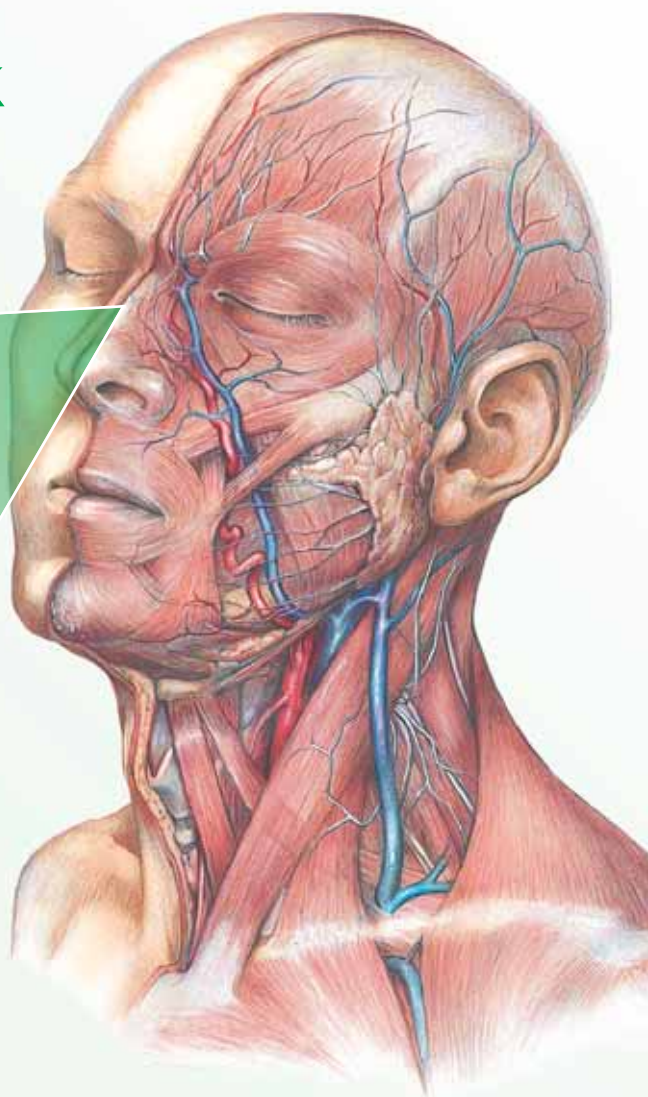
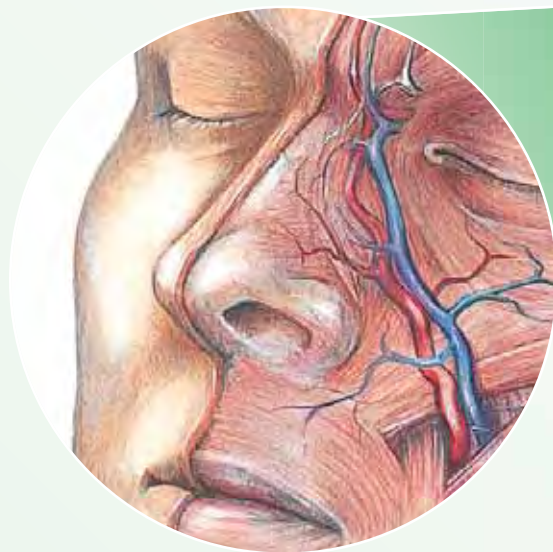ᑕᑦᑭᑦ ᐃᑭᑦᑲᑦᑲᑦ

Talluup Iluqsanga

Tablurut

Fossette

## Dorsum / Back of the Nose



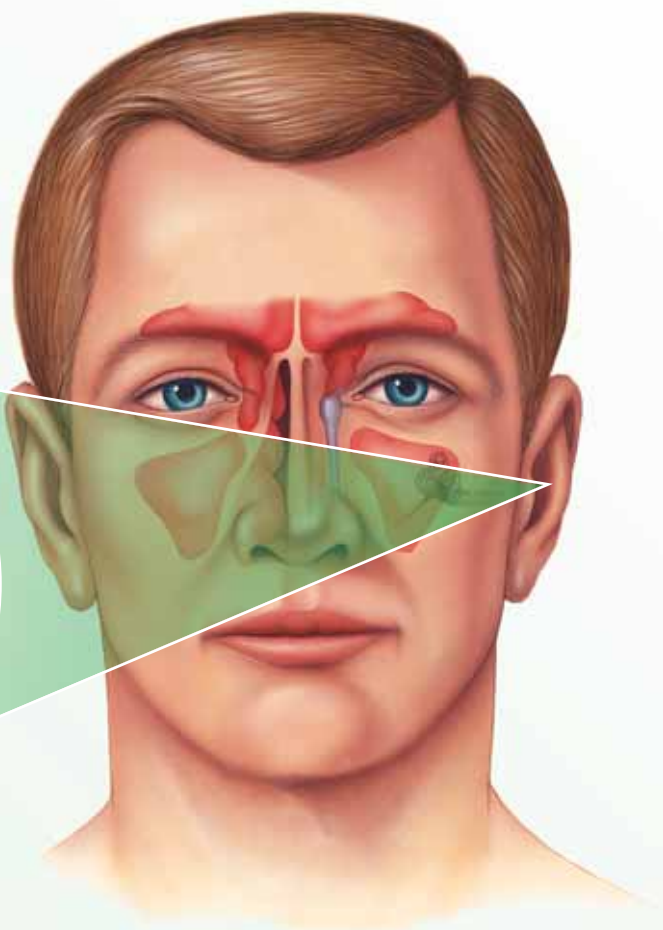
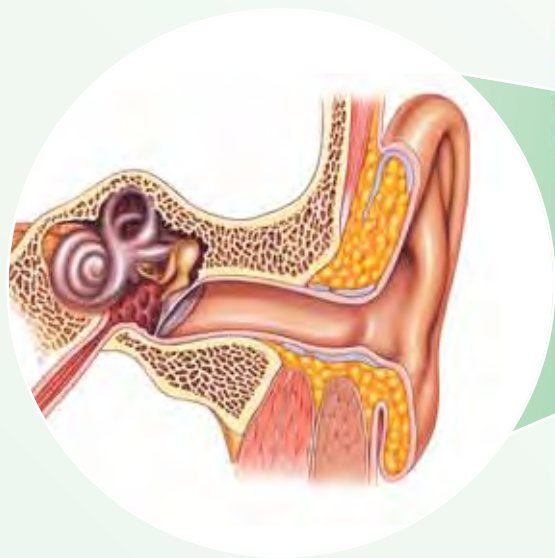ᐱᑭᑦᑎᑦᑎᑦ

Sivuraq

Qingaulhuk

Dos du nez

# Ear



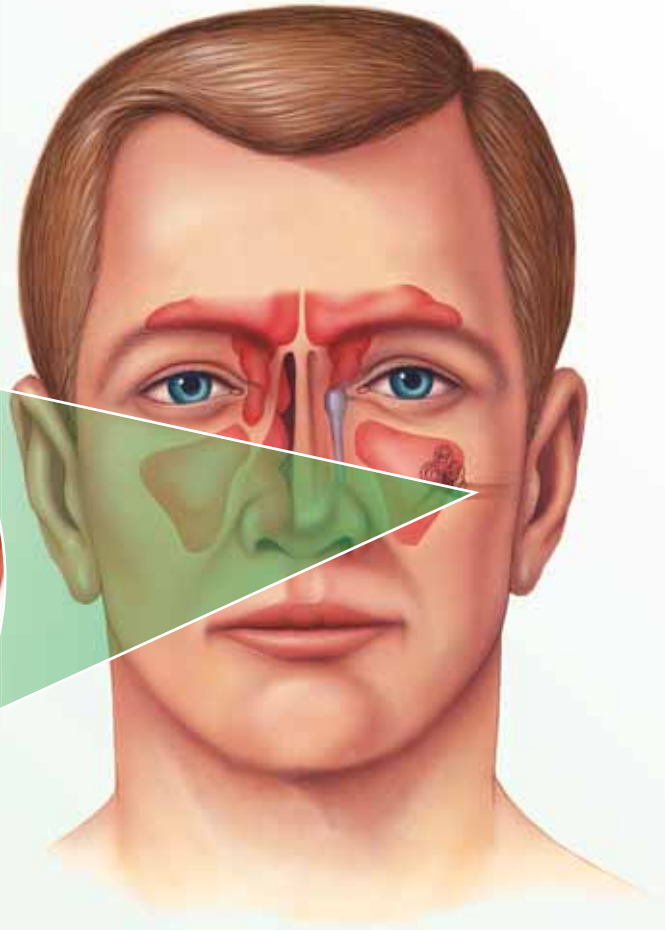
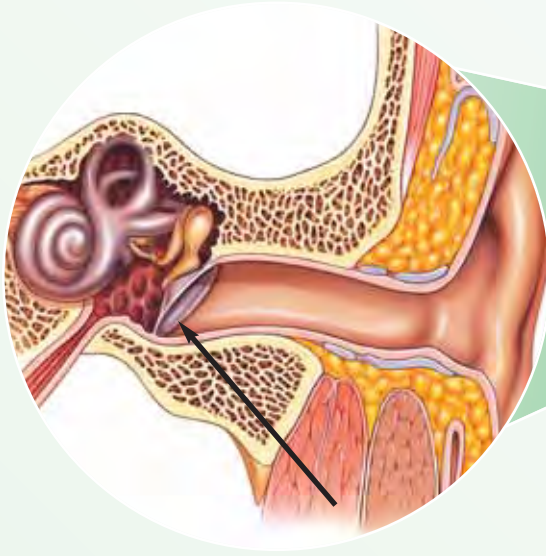𐌿𐌸𐌰

Siuti

Hiut

Oreille

# Ear Drum



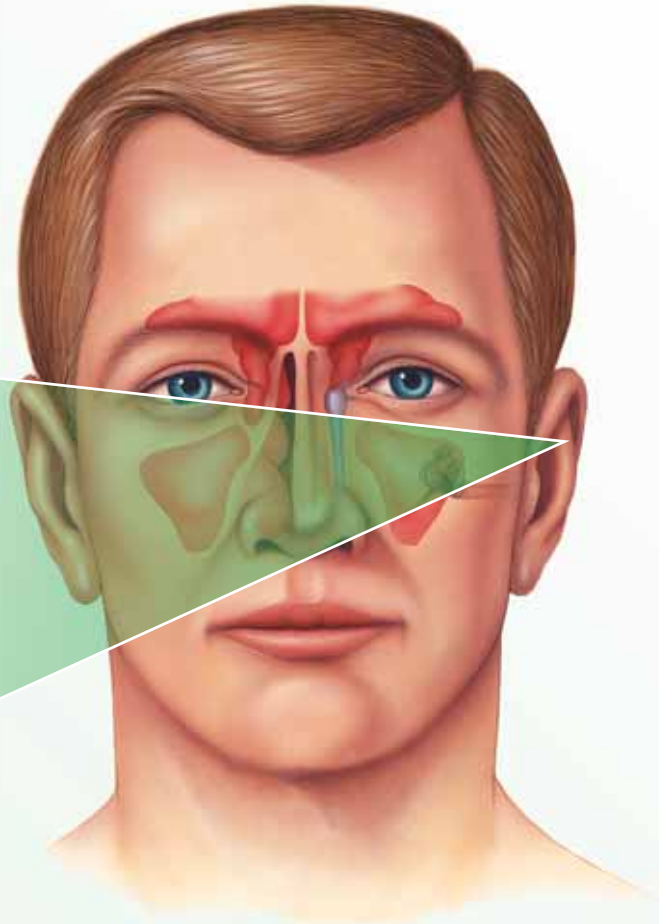
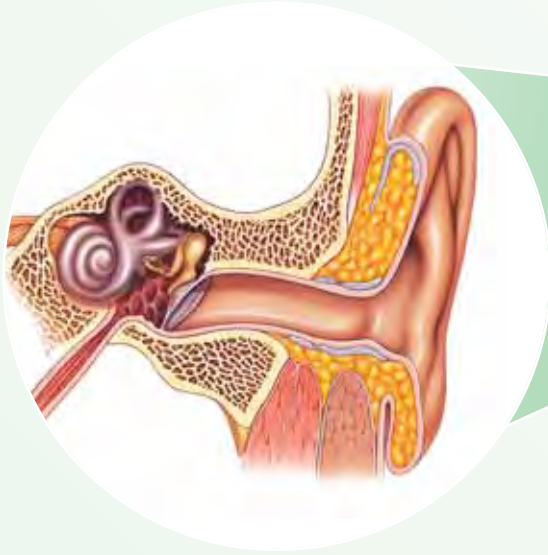ΔΛϸ▷↳ᄁᄂ

Igalaujaq

Kapihiaq

Tympan

# Ear Pavilion



ᐱᐱᐱᐱᐱᐱ ᐱᐱᐱᐱᐱᐱ

Siutiup Nataqqua

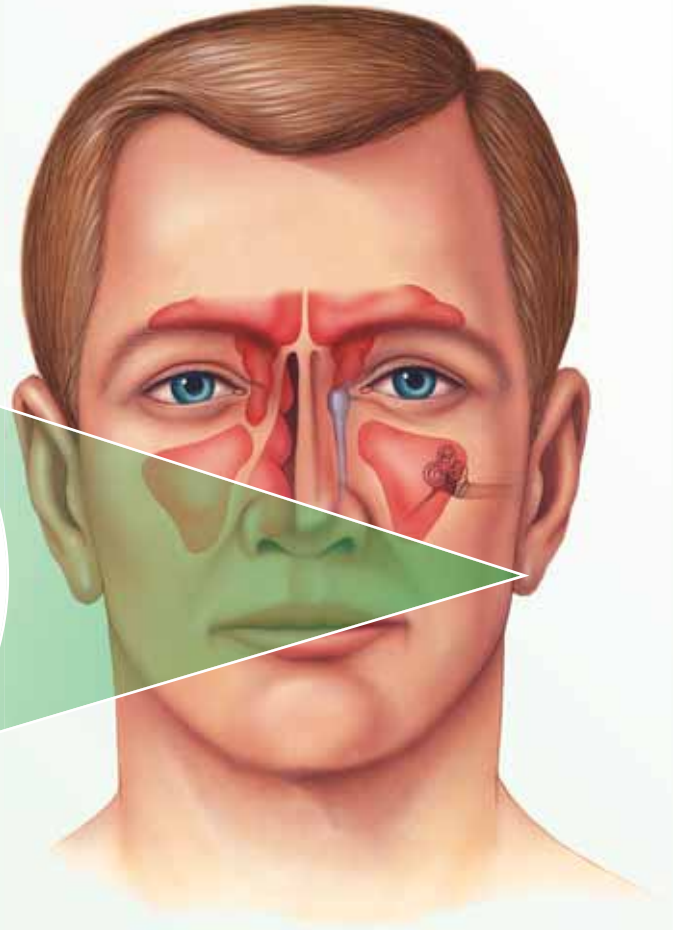
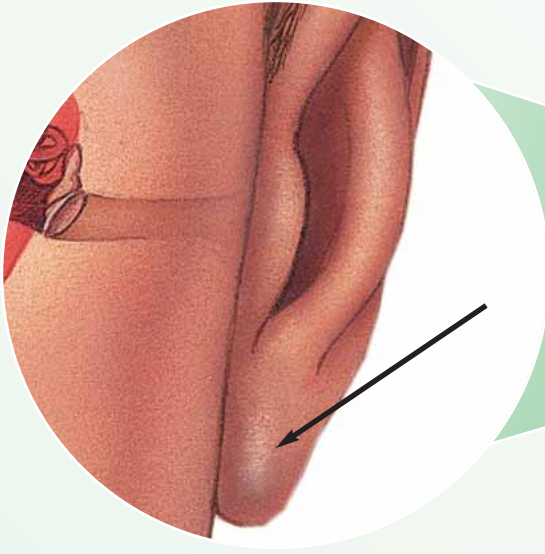
Hiutip Avataa/Hiutip

Qaqqulaanga

Pavillon de l'oreille



# Earlobe



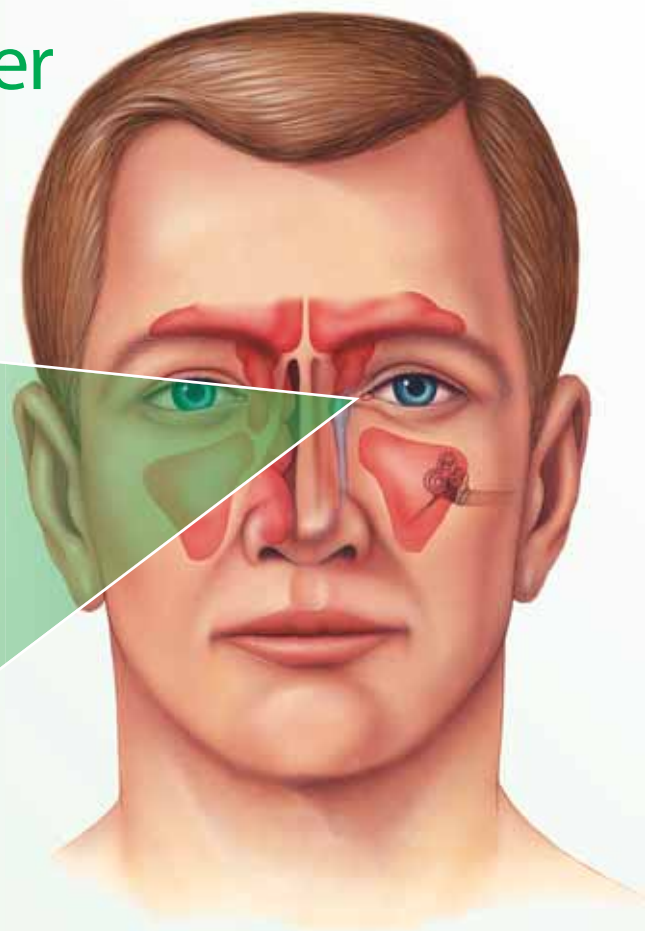
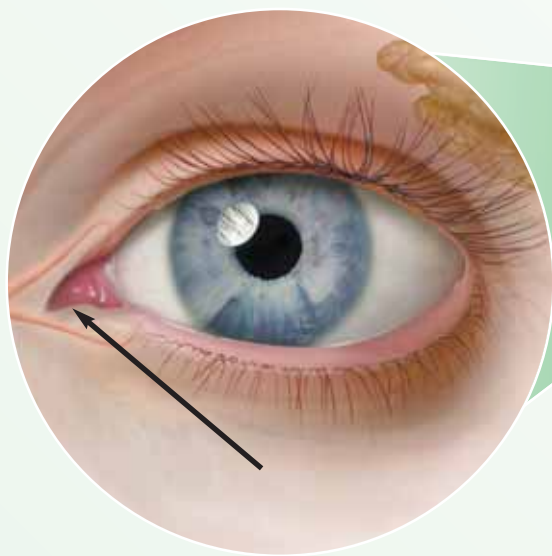
ᐱᑦᑕᑦ

Matsa

Hiutiruk

Lobe de l'oreille

# Internal Corner of the Eye



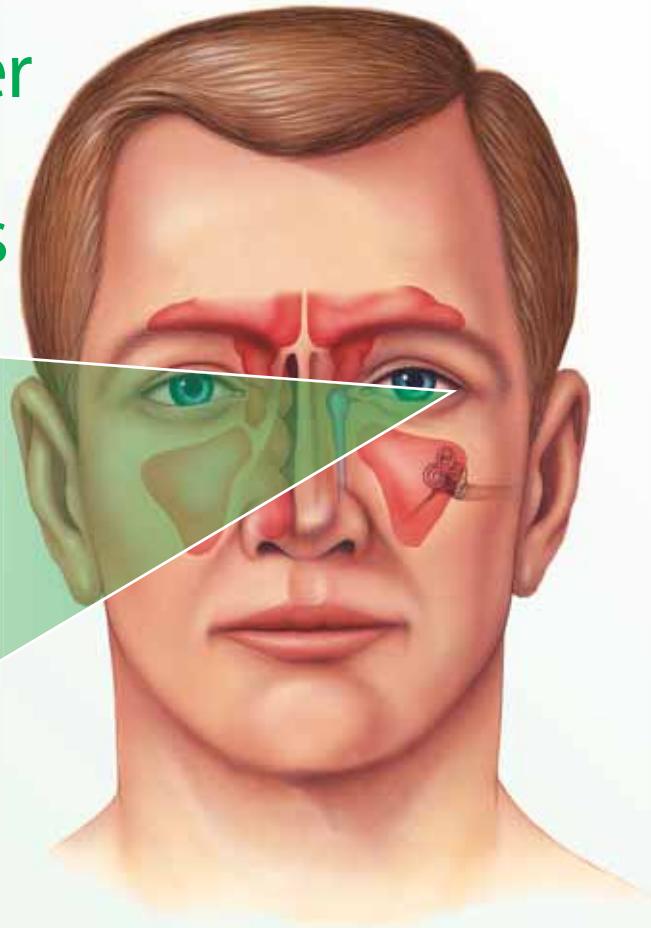
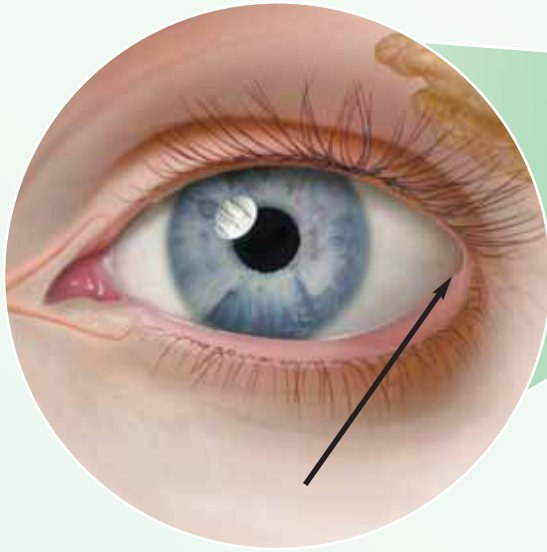
Δ<sup>ε</sup>ᵛᵛᵛᵛ

Illuriuti

Qipaluaq

Coin interne de l'œil

# External Corner of the Eye or Lateral Canthus



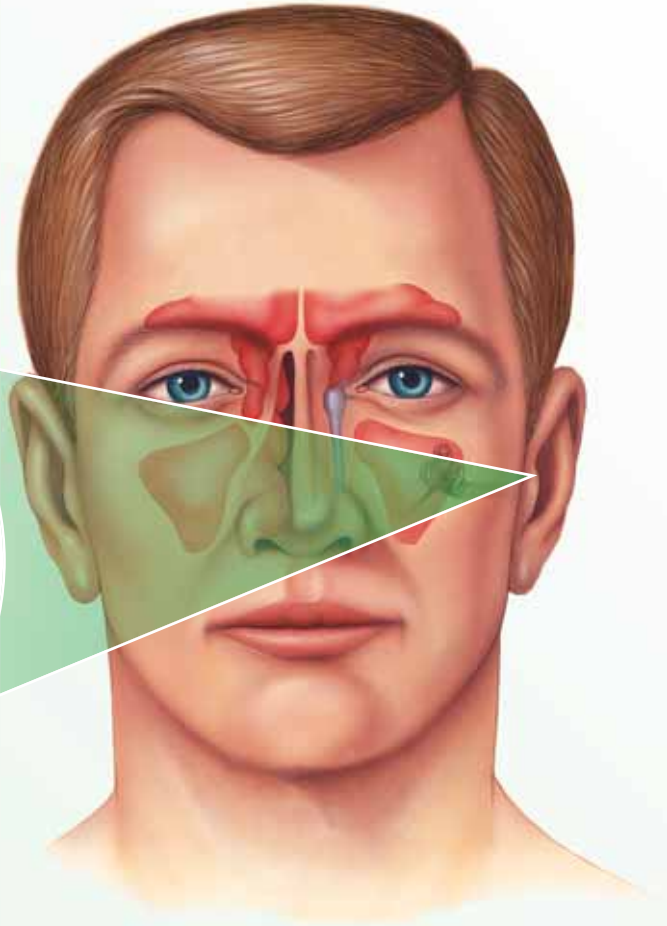
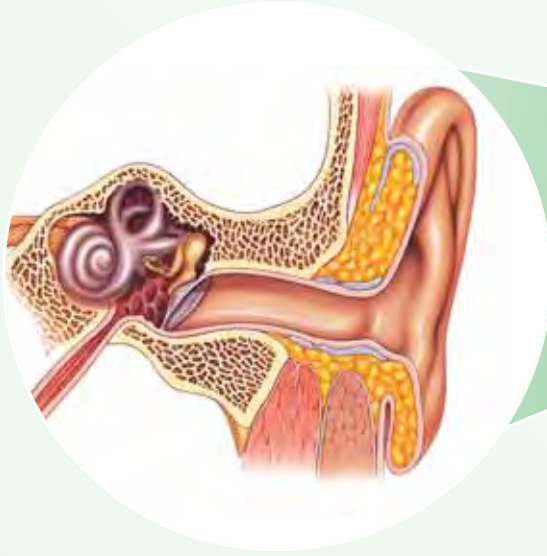ᐅᐃᐅᐅᐅᐅᐅᐅᐅ

Qipaluaq

Qipaluaq

Coin externe de l'œil

# External Ear Foramen



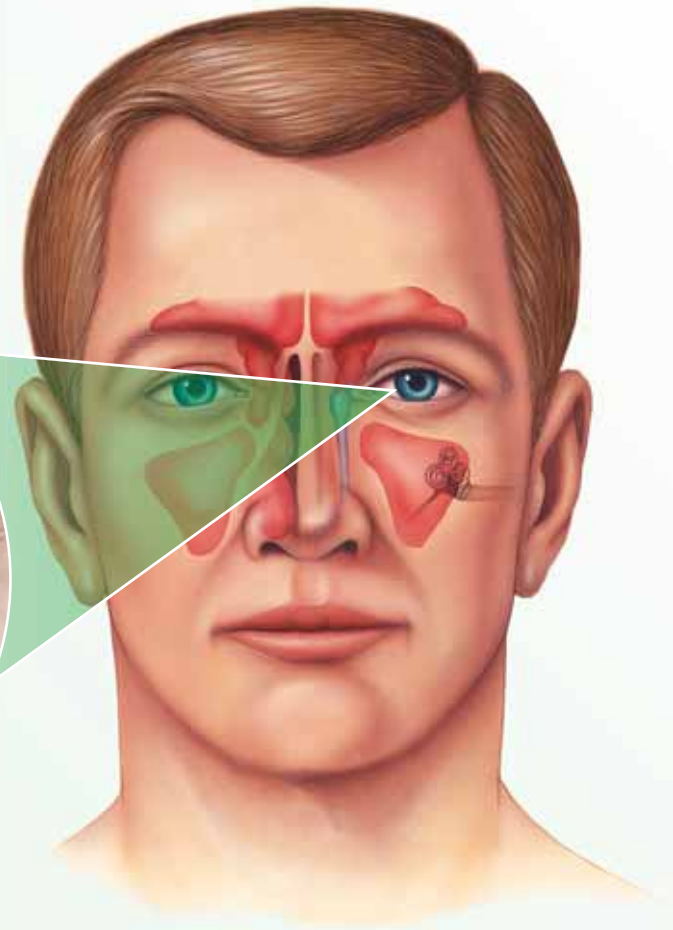
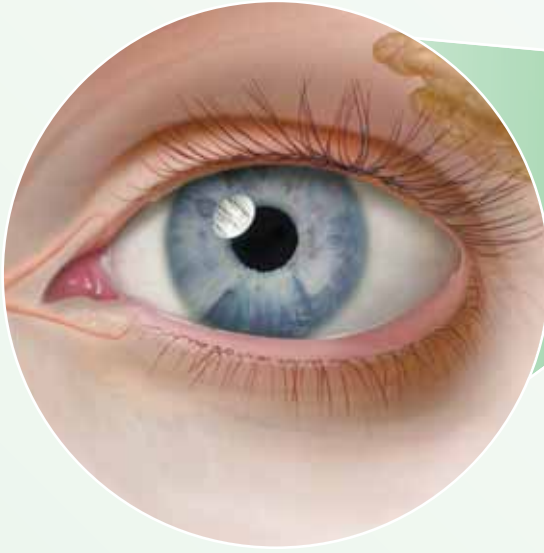
ᐱᐅᐅᐅᐅᐅ ᐱᐅᐅᐅᐅ

Siutiup Sullunga

Huitip Angmania Ilunmut

Conduit auditif externe

# Eye



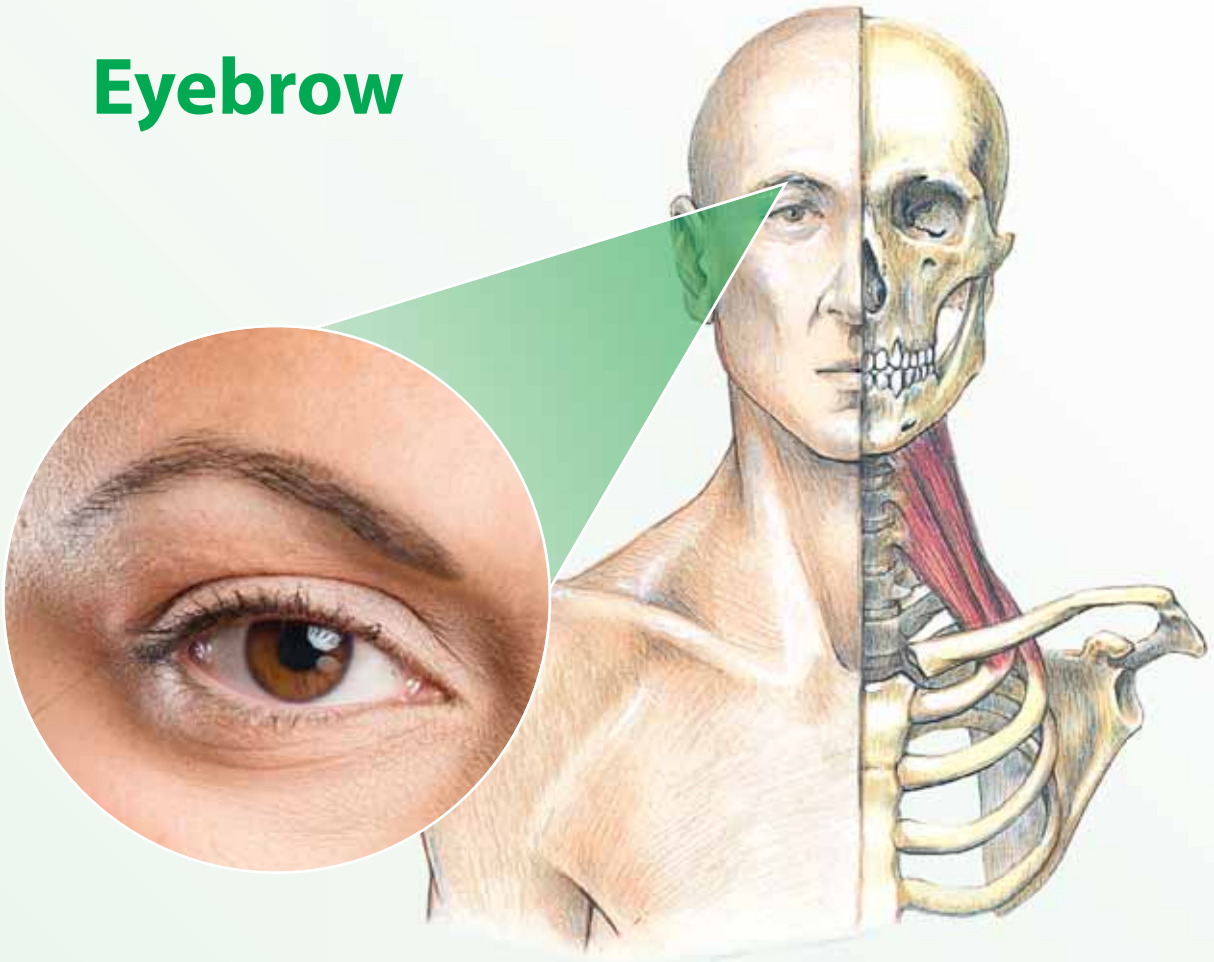
ΔΡ

Iji

lyi

Oeil

# Eyebrow



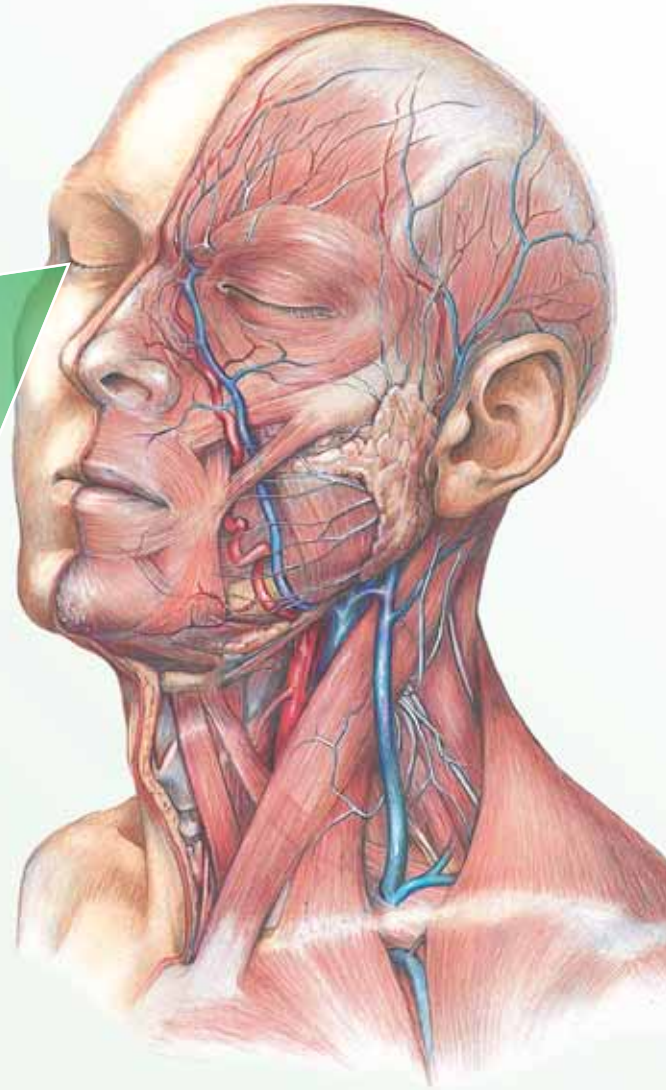
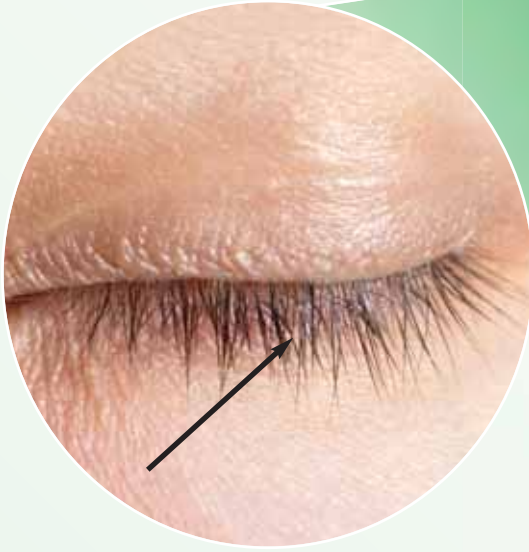ጻፍ

Qallu

Qablu

Sourcil

# Eyelashes



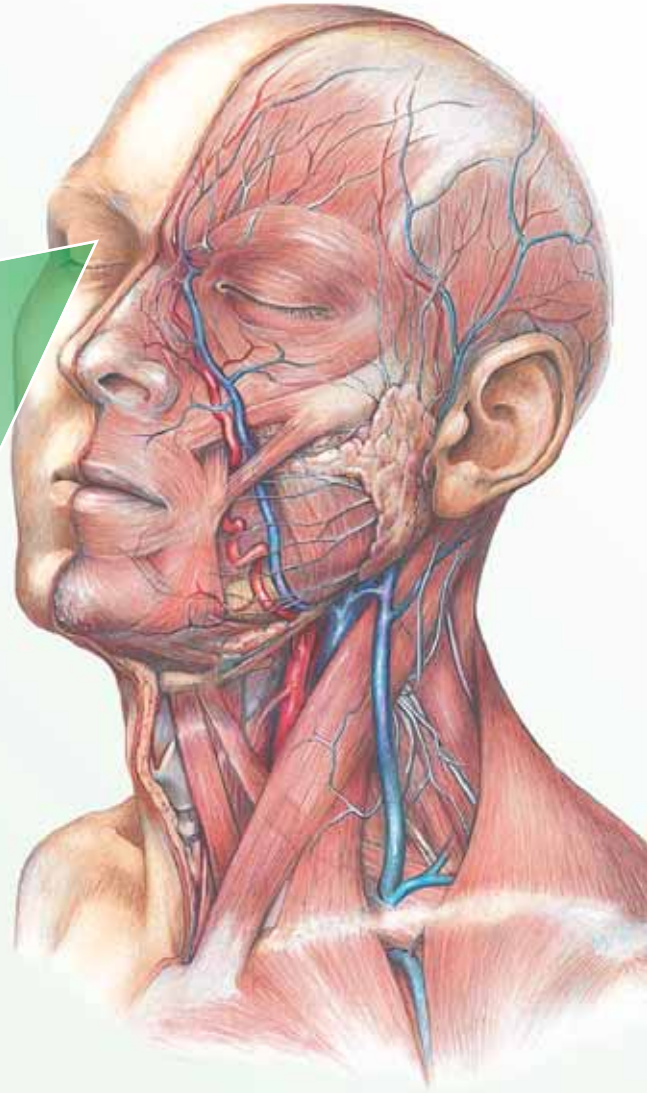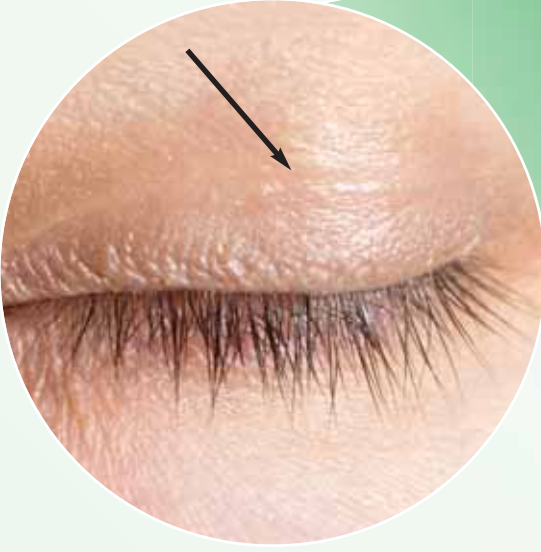‘ρΓηΔ’

Qimiriāt

Qimiriāt

Cils

# Eyelid



Δῤῥῥῥ ῥῥῥ

Ijiup Qulaa

Qablunaq/Pumngataa

Paupière



# Face



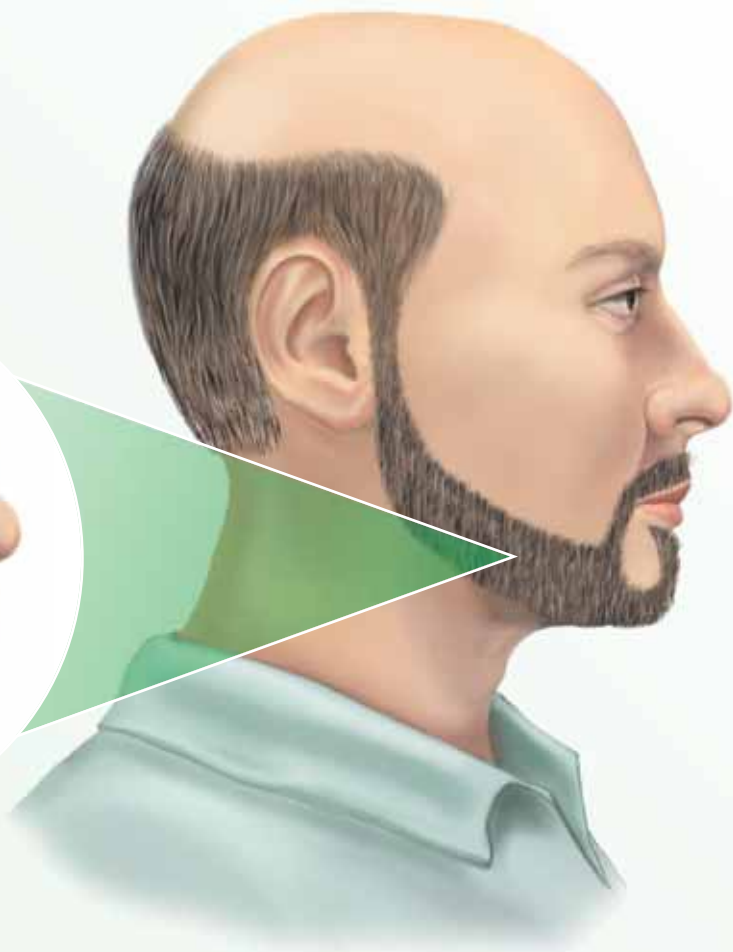ᐅᐱᑦᑲ

Kiinaq

Akuliak

Visage

## Facial Hair



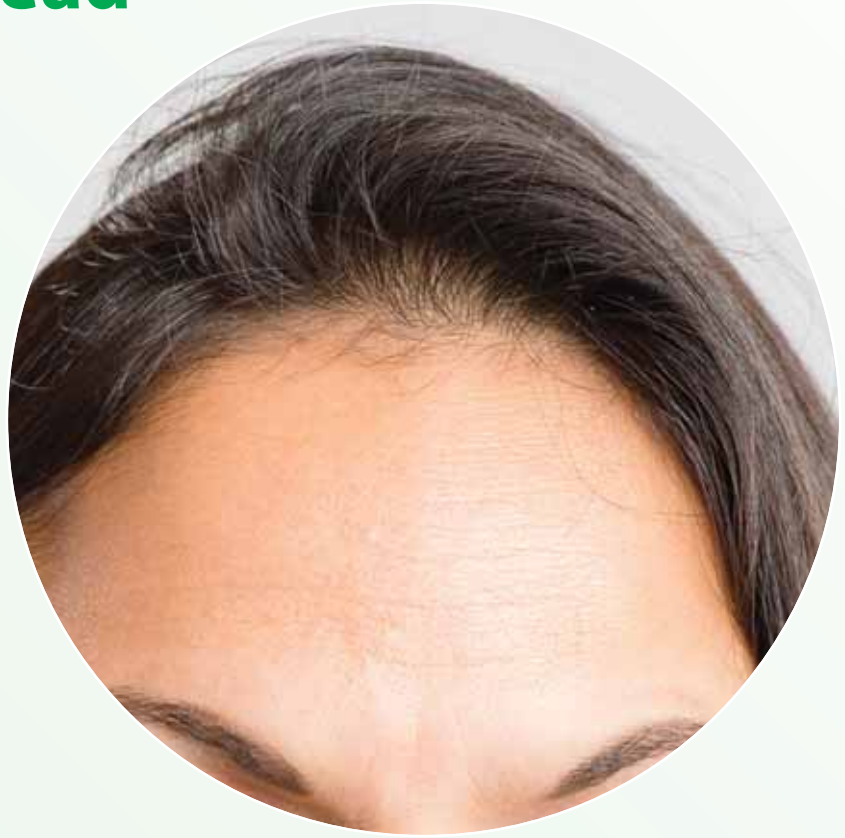
▷ГԳԵԳՃԵ

Umiqarvik

Umiqarniq

Zone pileuse du visage  
(moustache et barbe)

# Forehead



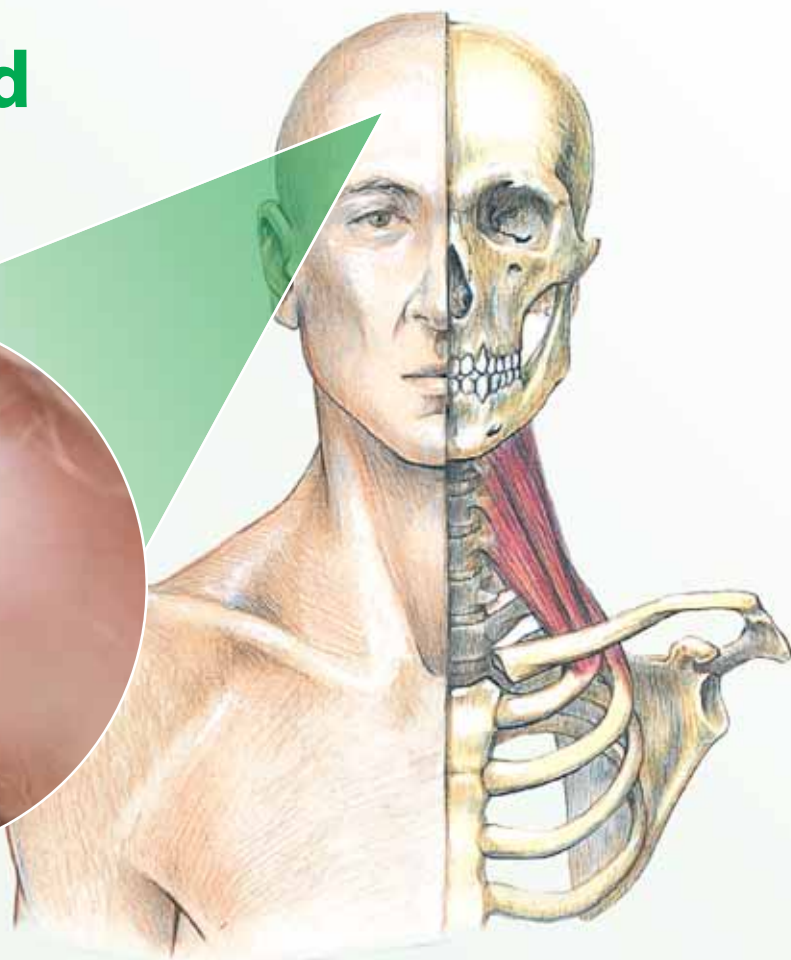
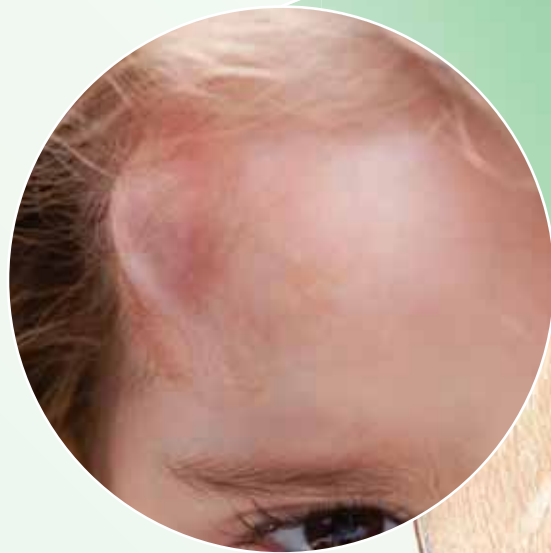ᑦᑲᑦᑲ

Qauq

Kiinaq

Front

# Forehead Bump



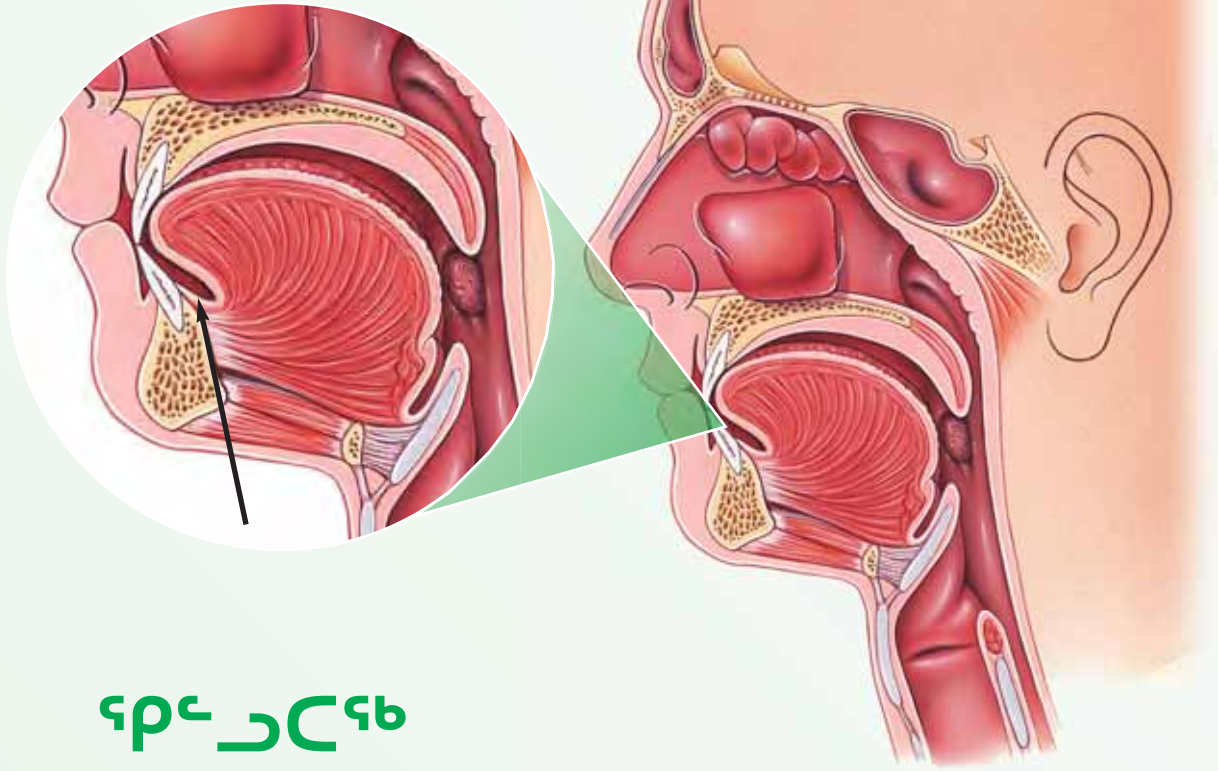
Δ ᄅᄃ ᄅᄃ

Iqsaq

Qauq

Bosse frontale

# Frenulum of the Tongue




ᑭᓯᓴᓐ ᓴᓴᓴᓐ

Qillutaq

Nuqarut

Frein de la langue

# Front Hair



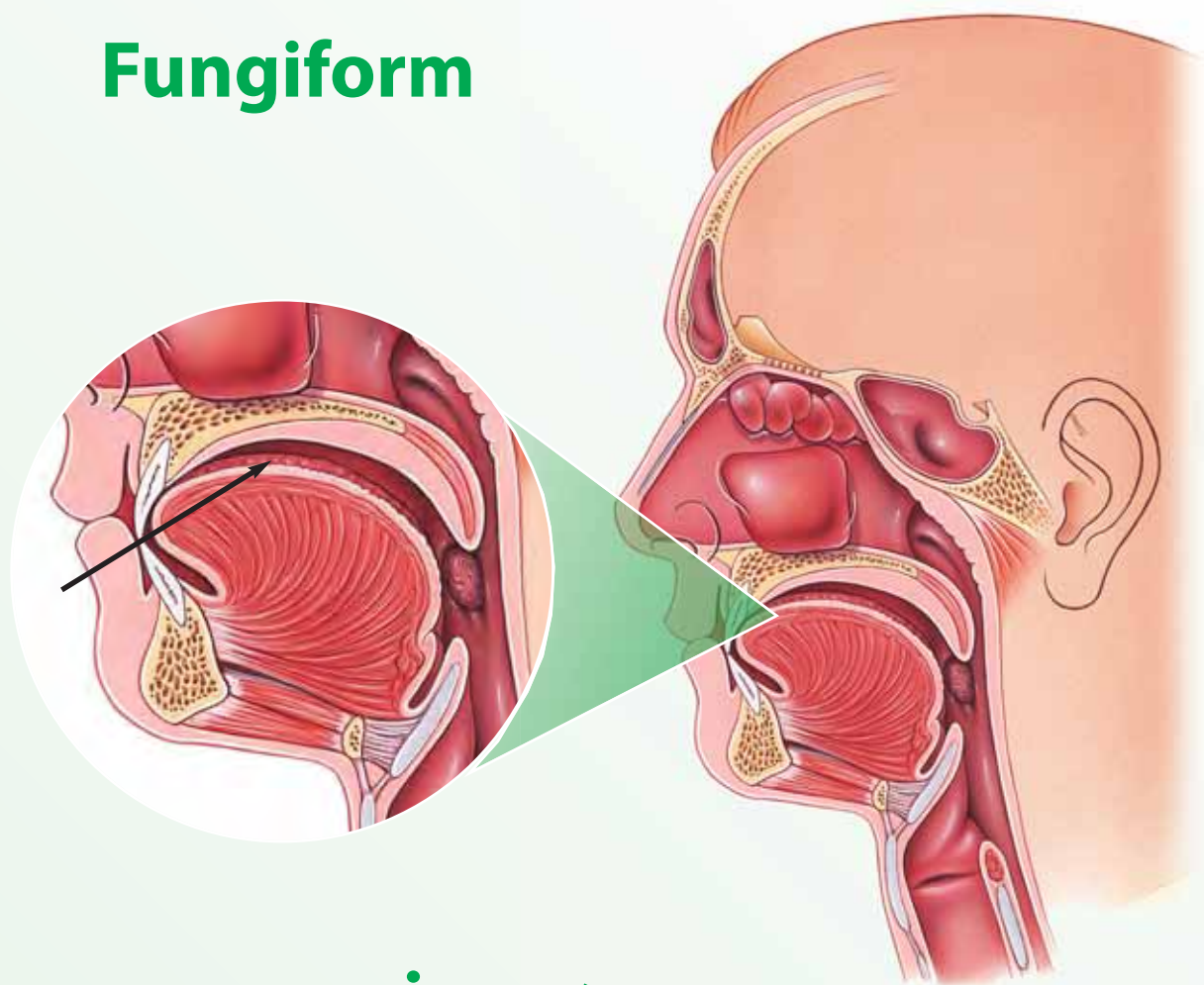
𐌸𐌹𐌳𐌹𐌿

Sivuit

Hivum Nuyat

Cheveux de devant

# Fungiform



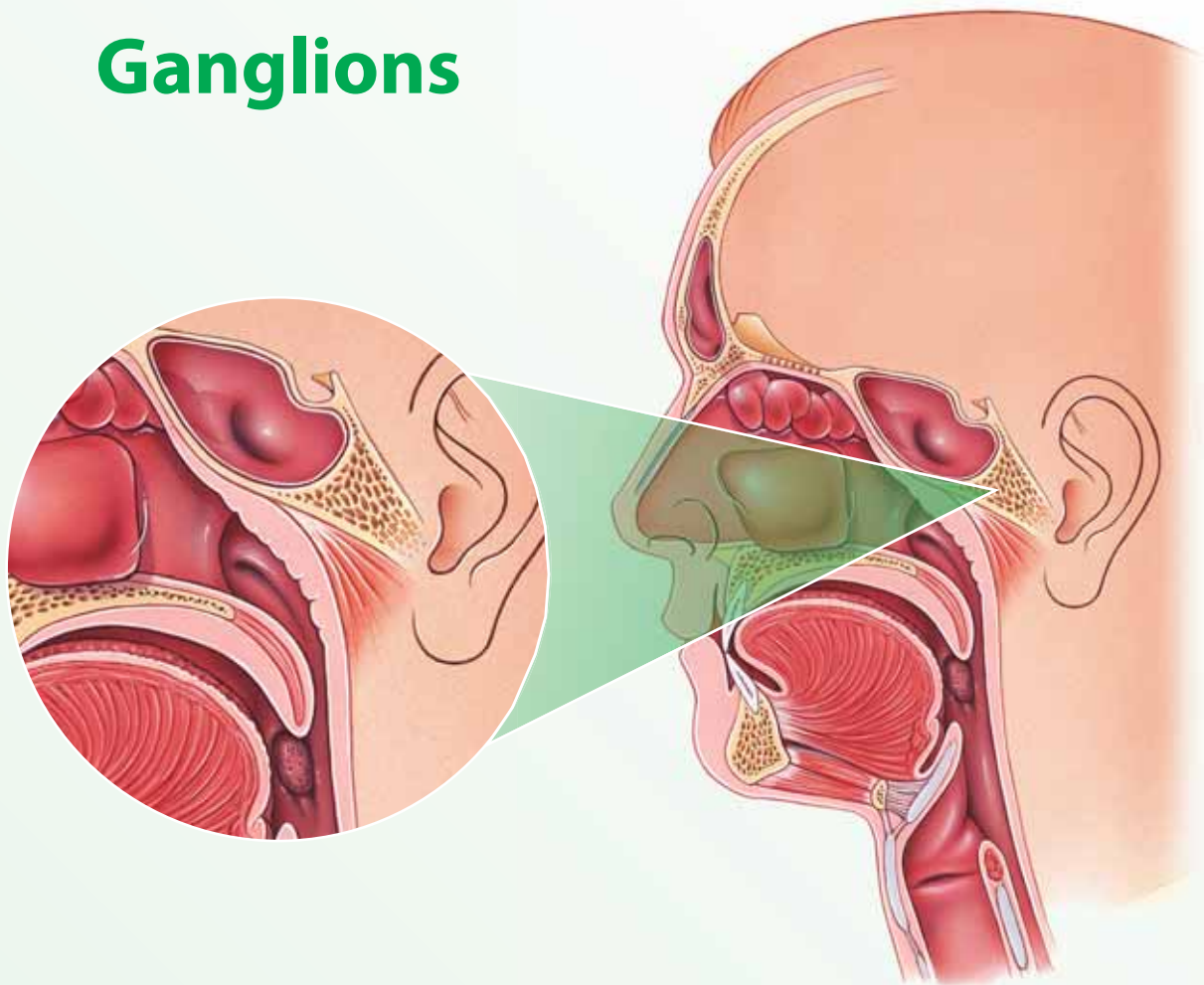
ᐃᑦᑲᐃᑦ ᑦᑲᑦᐱ/ᐱᑦᑲᐃᑦᑦ

Uqaup Qaanga/miqqungit

Nuvaliurvik

Papilles fongiformes

# Ganglions



ᑎᑭᑦᑲᑦᑲᑦ

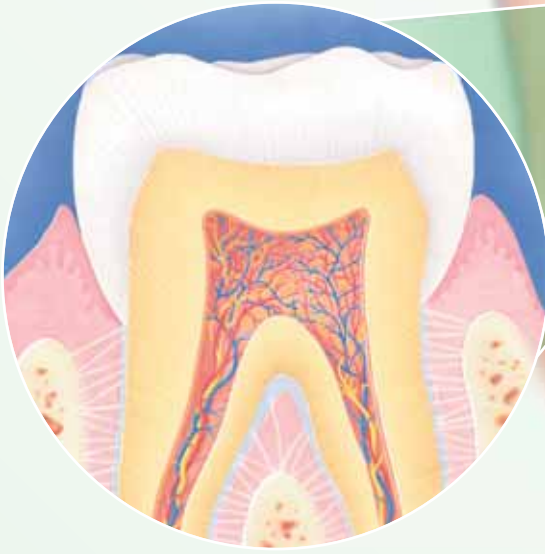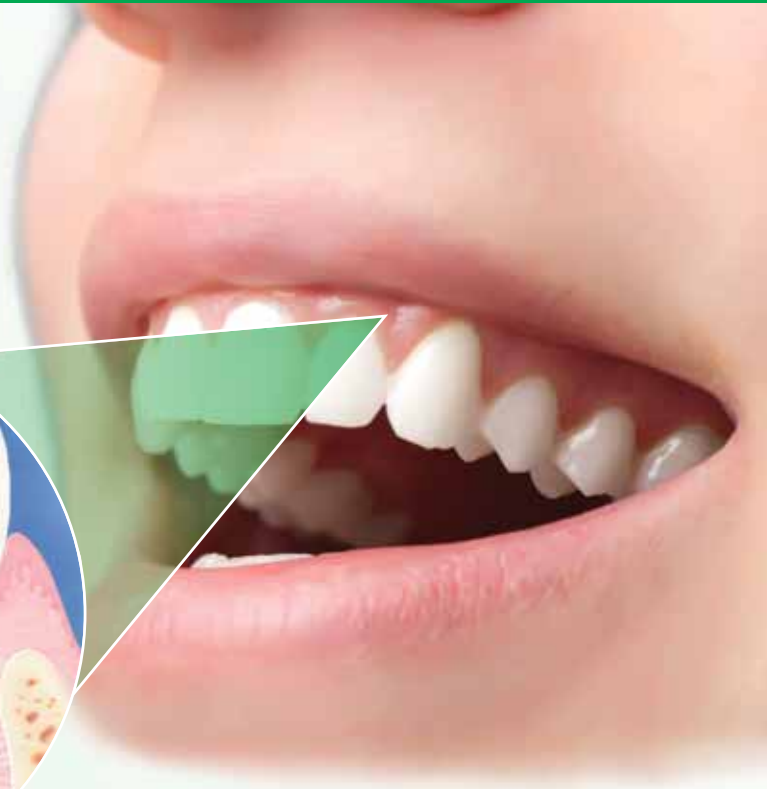Tisisaukkut

Immangniq

Ganglions



# Gum / Gingiva



Δᵇᵣᶜᵃᵇ

Ikkiaq

Kigutinilirvik

Gencive

# Hair



نواجق

Nujait

Nuyaq

Cheveux

## Hair at the Nape of Neck



ᑕᓄᓂᑦ ᓄᑦᑕᑦᑕᑦ

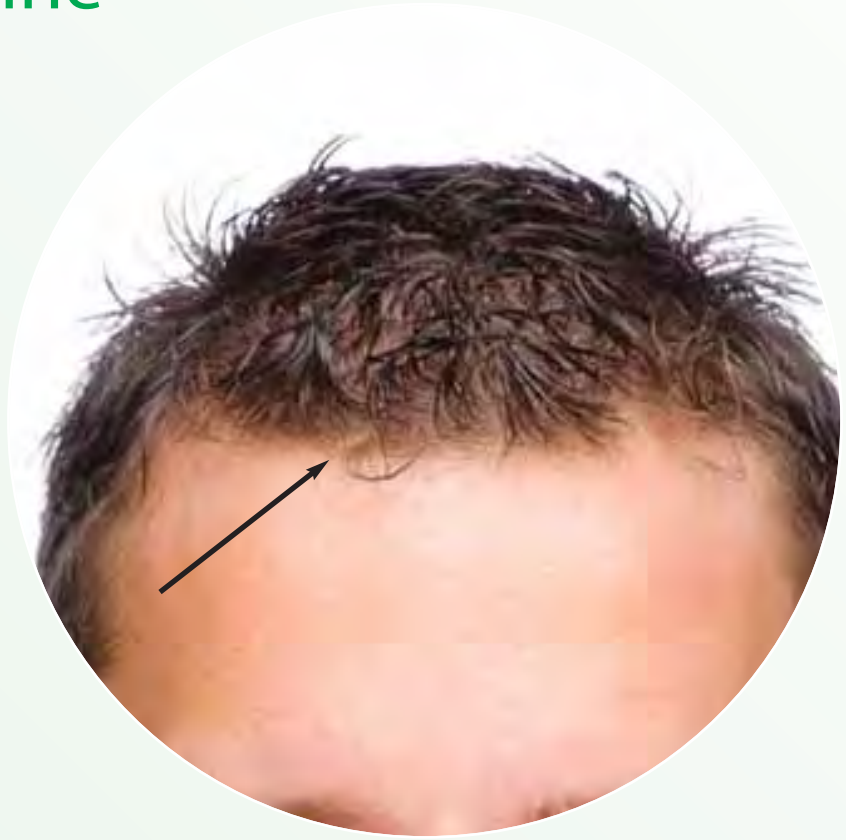
Tunusungmi Nujarusiit

Tunuhugutit

Cheveux sur la nuque



# Hair Line



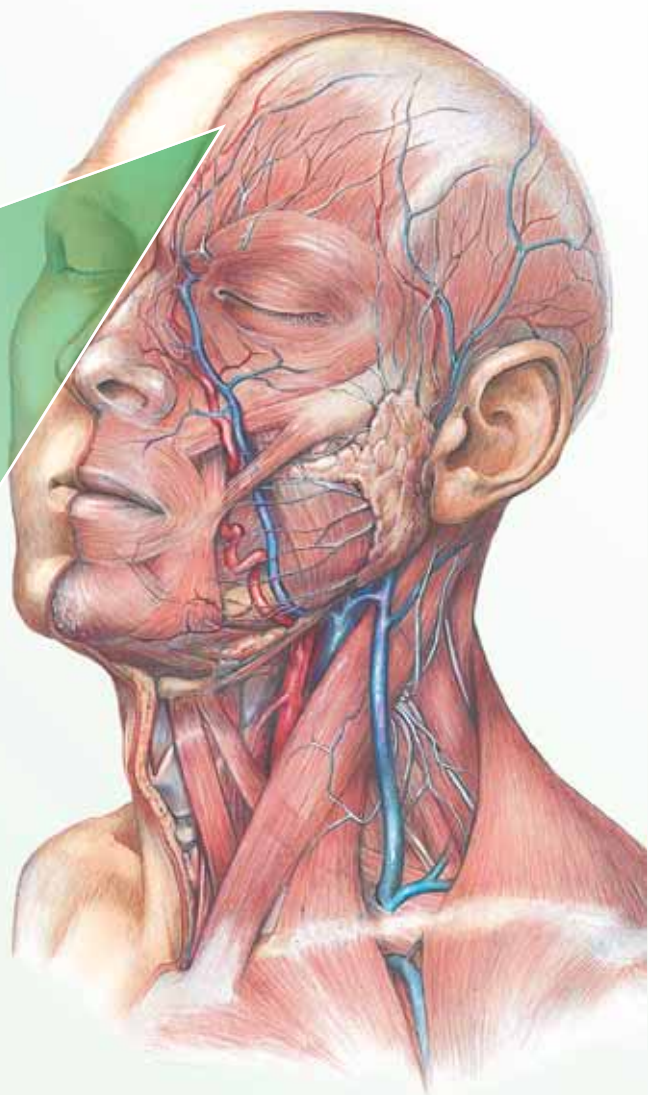
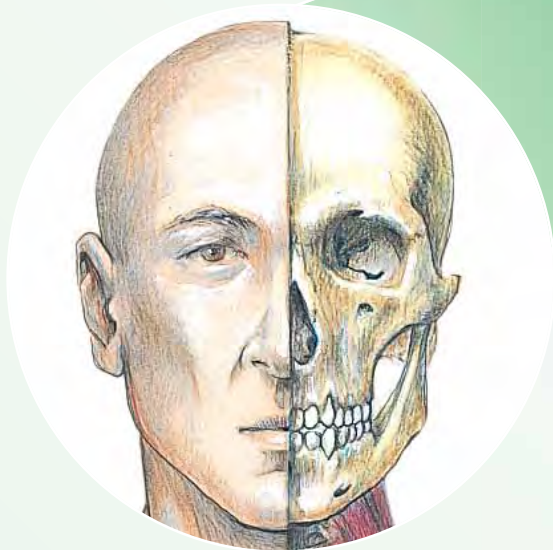
ᓄᓴᓴᓴᓴᓴᓴ

Nujarusiq

Nuyat Kiglinga

Raie des cheveux

# Head



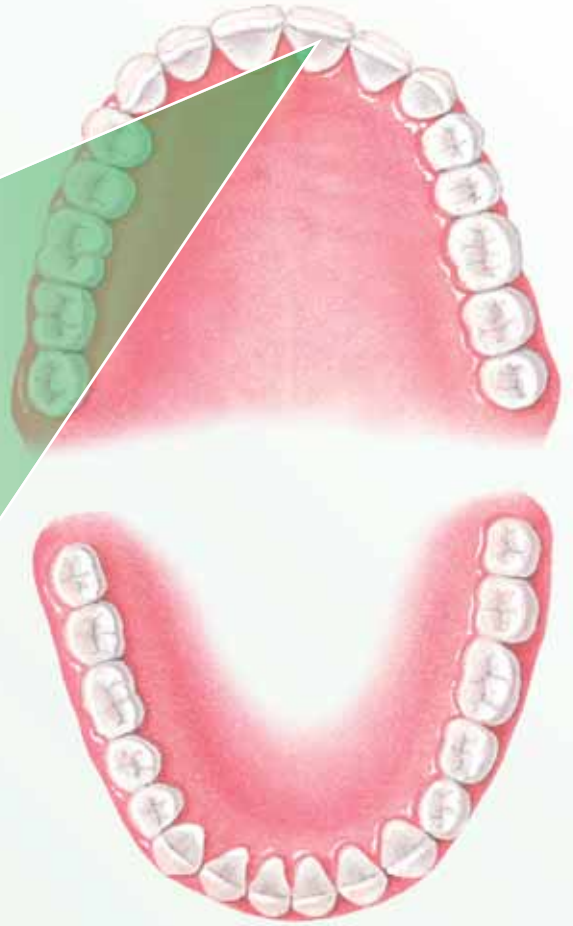ᓄᐱᓄᓄᓄ

Niaquq

Niaquq

Tête

# Incisor



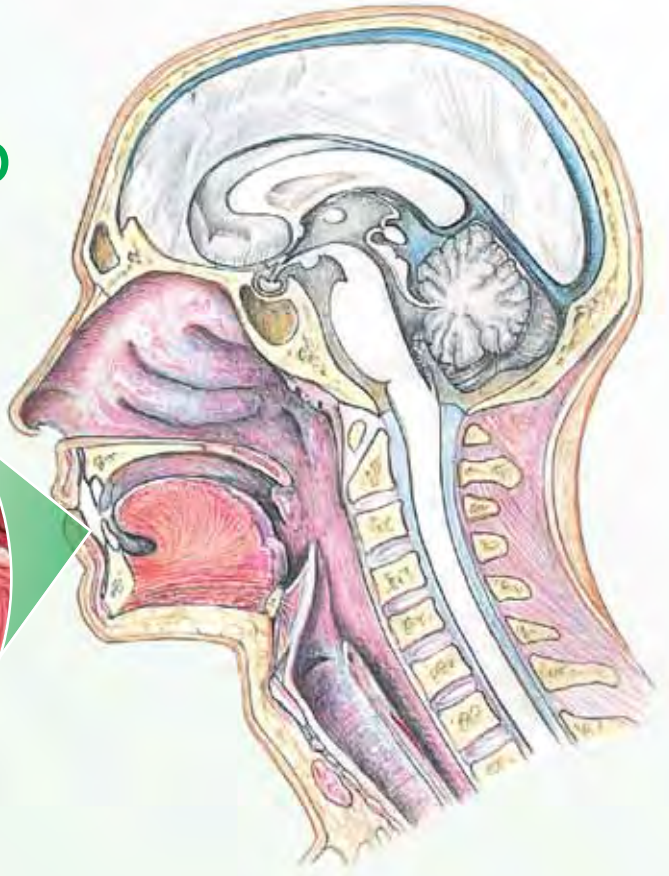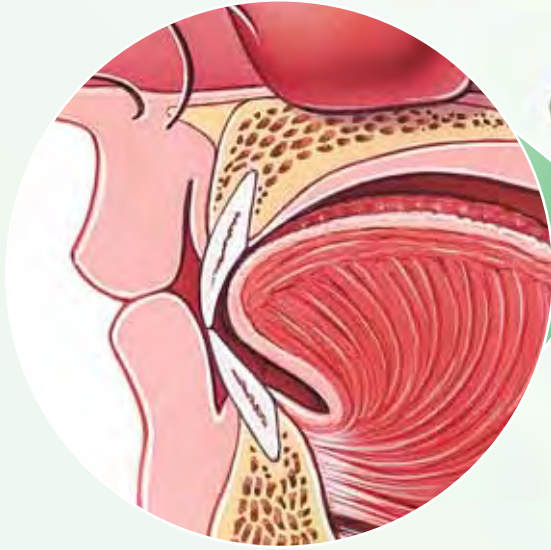
ᐱᑦᐱᑦᐱᑦ

Sivuat

Hivuaq

Incisive

# Inside of the Lower Lip



ᑭᑎᑭᑭᑭᑭᑭ

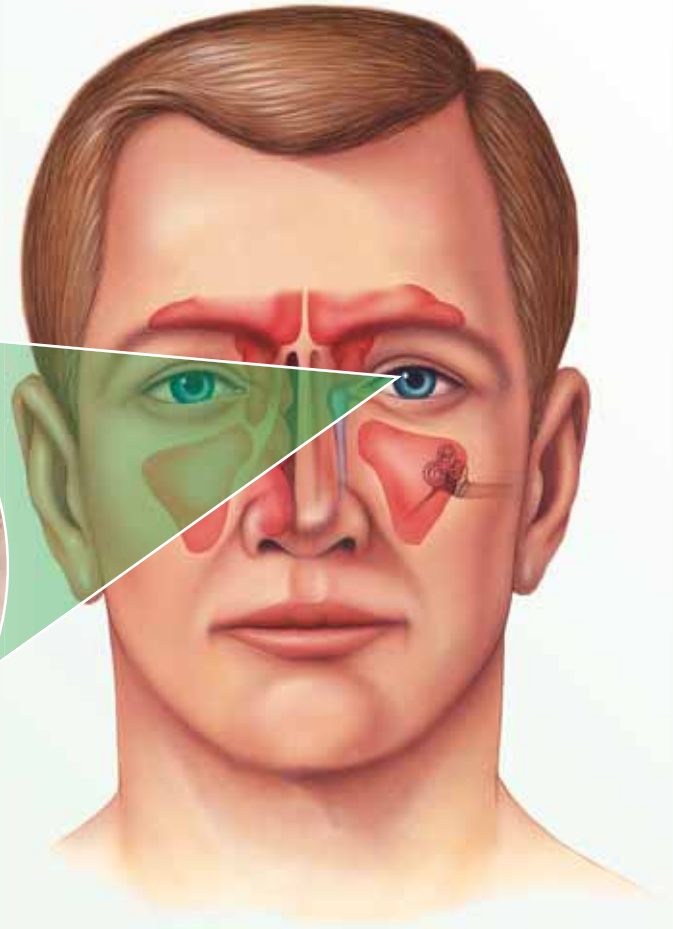
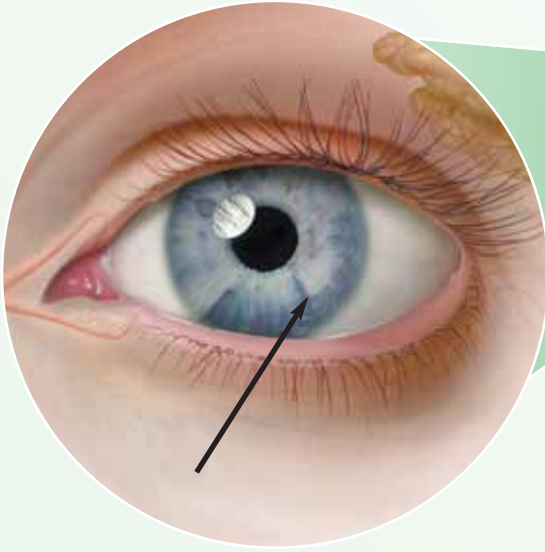
Qangasinaaq

Qaqhup Ilua

Intérieur de la lèvre  
inférieure



# Iris



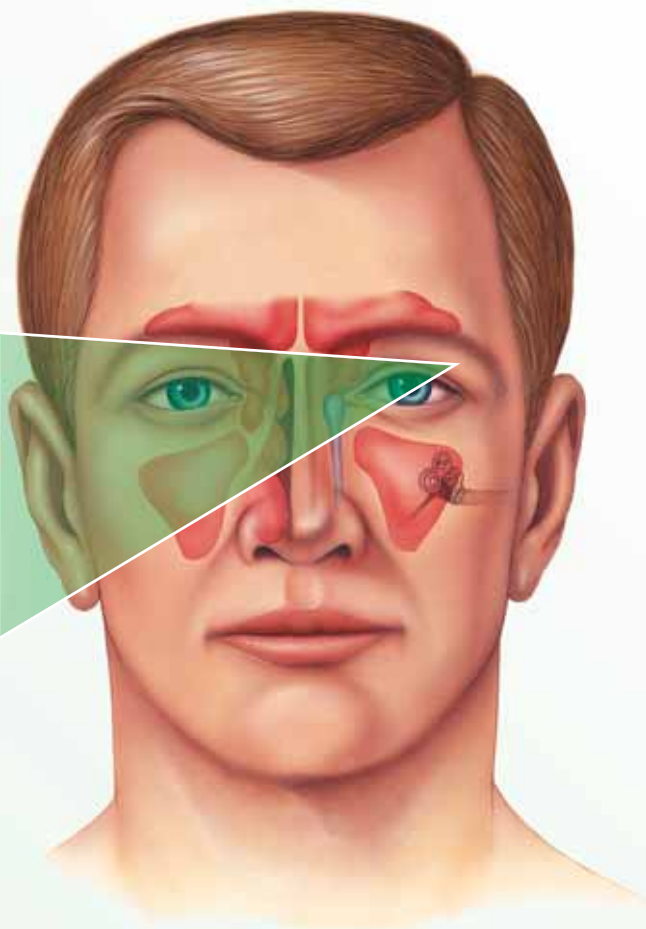
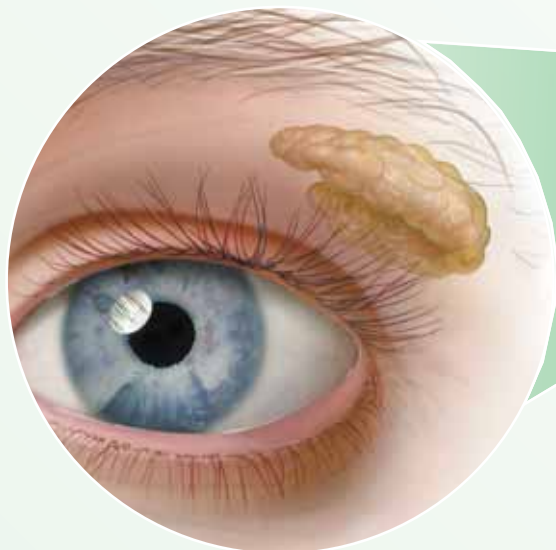Δῖῖῖ ῖῖῖῖῖῖῖῖ

Ijiup Qirnaangananinga

Tautuut

Iris

# Lacrymal Gland



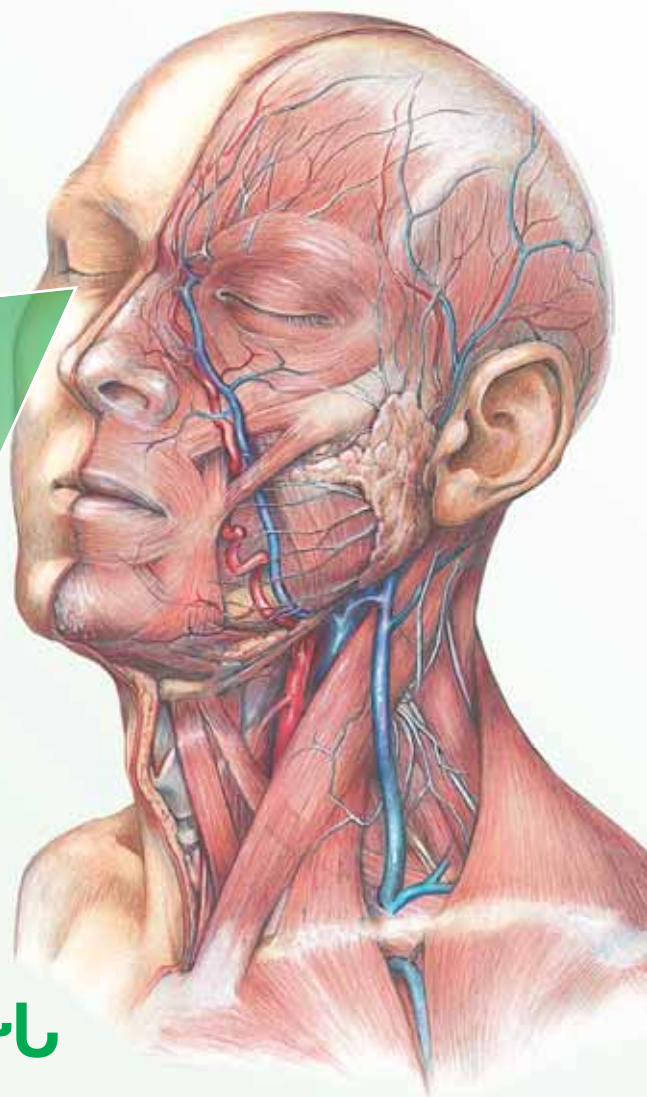
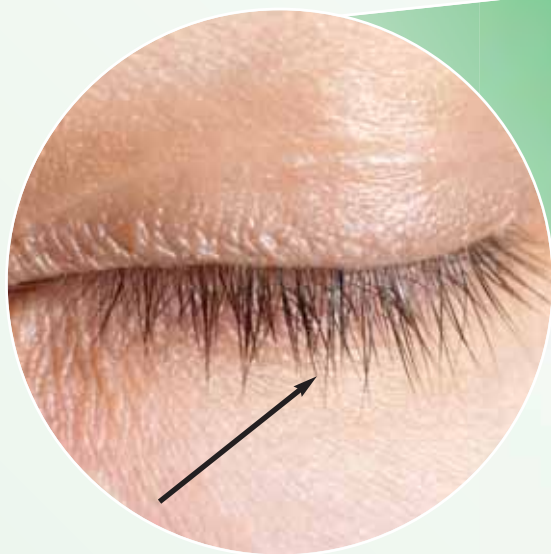ᑭᑭᑭᑭᑭᑭ

Quvviksaq

Qulvilhuq

Glande lacrymale

# Lower Eyelid



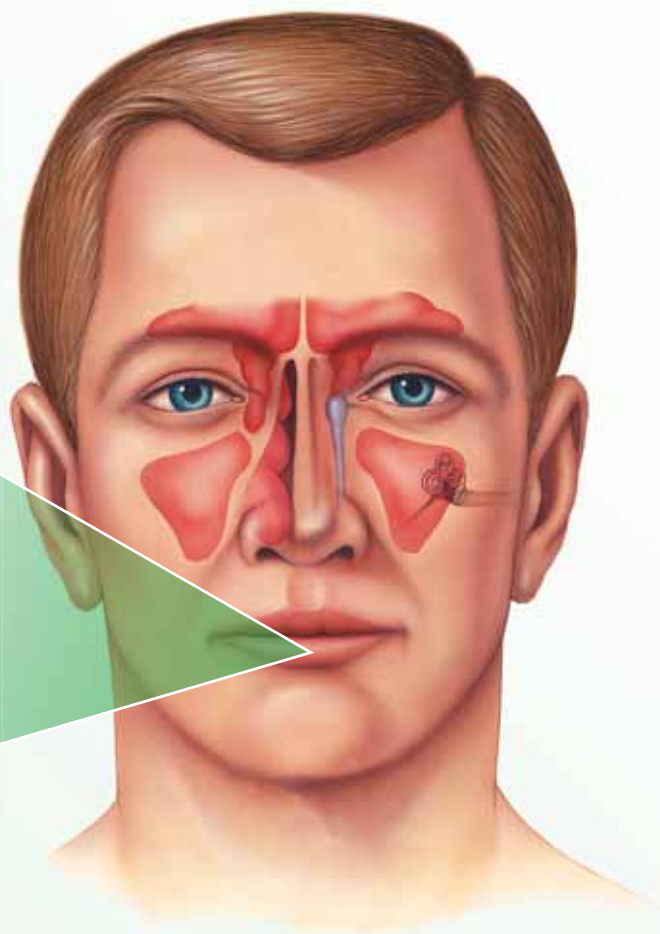
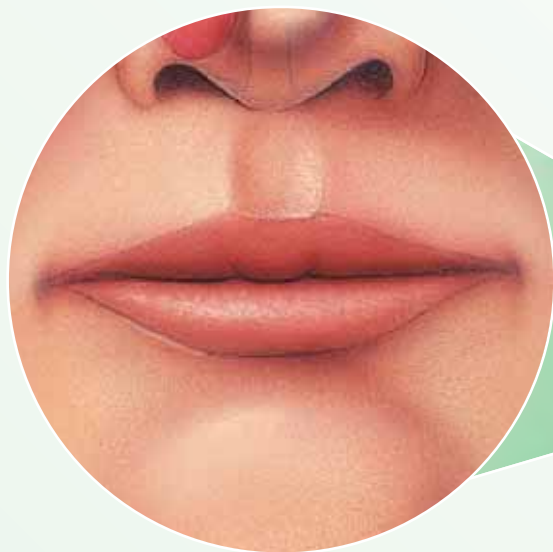
ΔΡΔ< ΔΝ<Ι<Ι

Ijiup Atingaanga

Qulvilhuq

Paupière inférieure

# Lower Lip



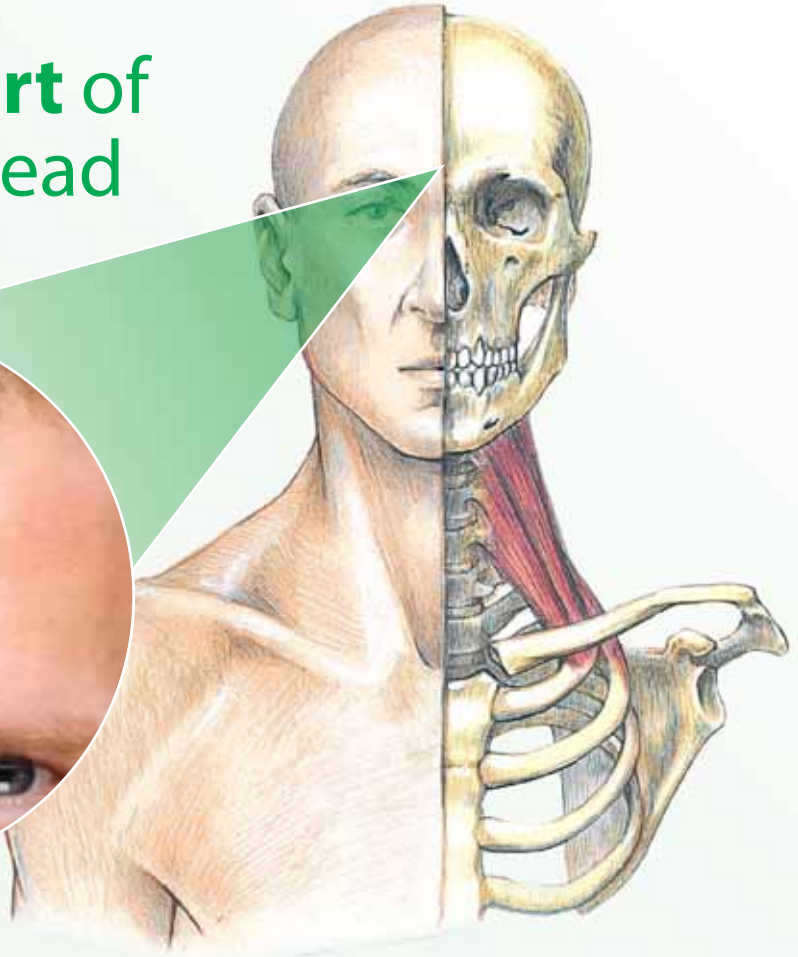
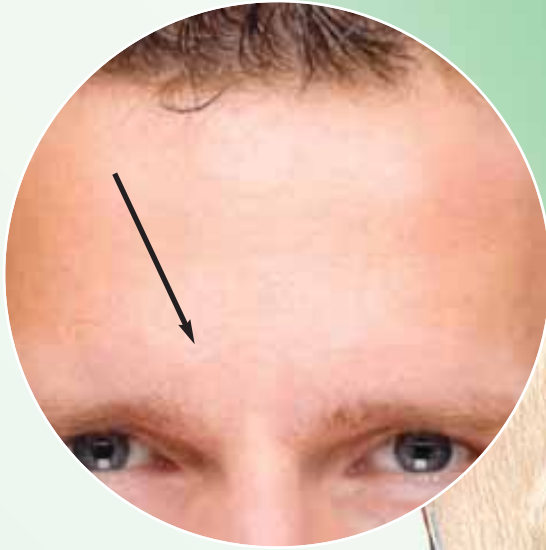᠒ᠪ᠒ᠪ ᠵ

Qaqtu

Qaqhuq

Lèvre supérieure / intérieur  
lèvre (inférieure)

# Lower Part of the Forehead



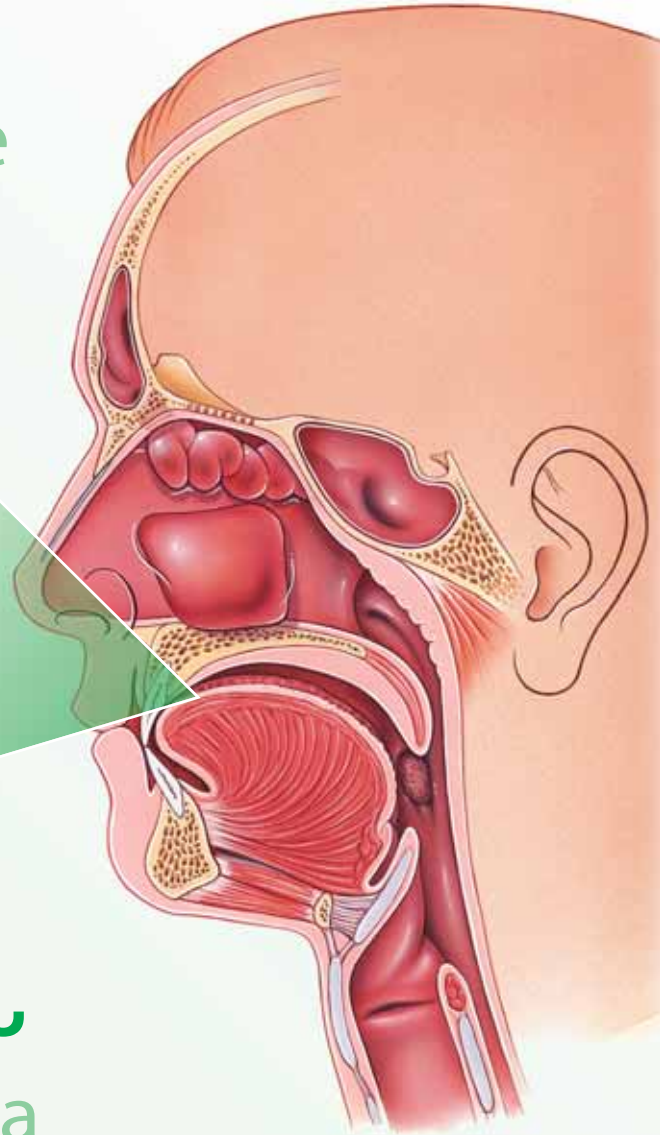
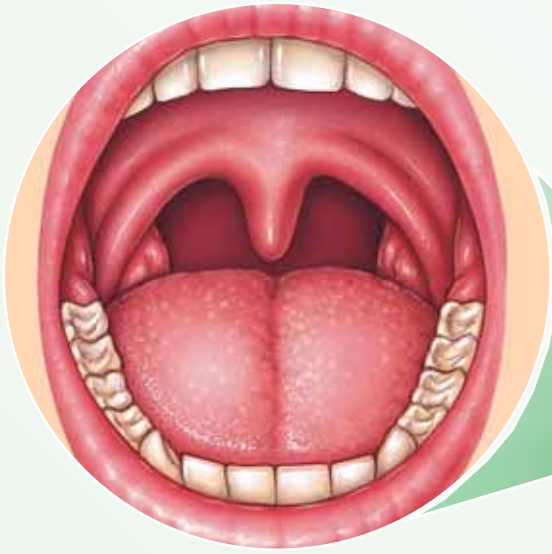ԳՐՏԵՂԳՆ

Qinnguq

Qin'nguq

Partie du bas du front

# Median Line of the Tongue



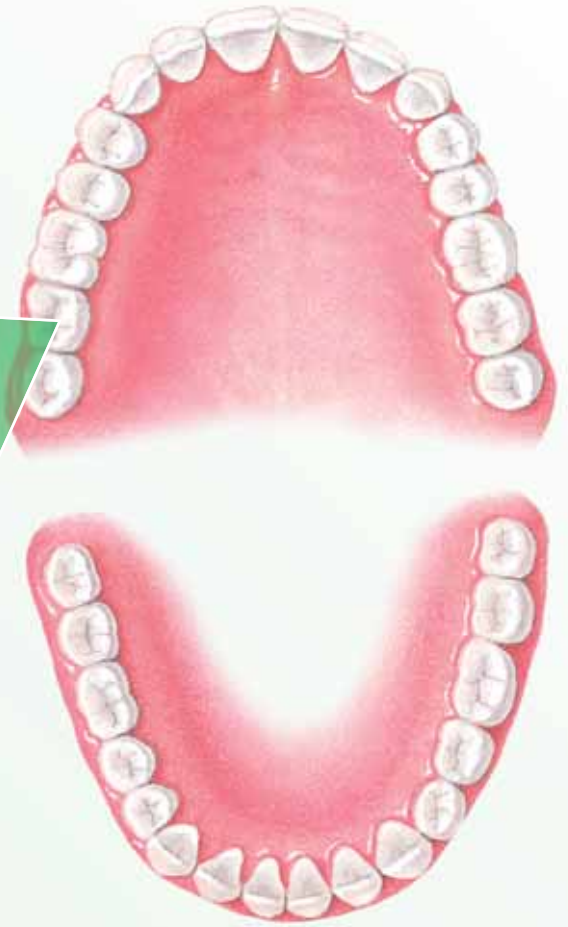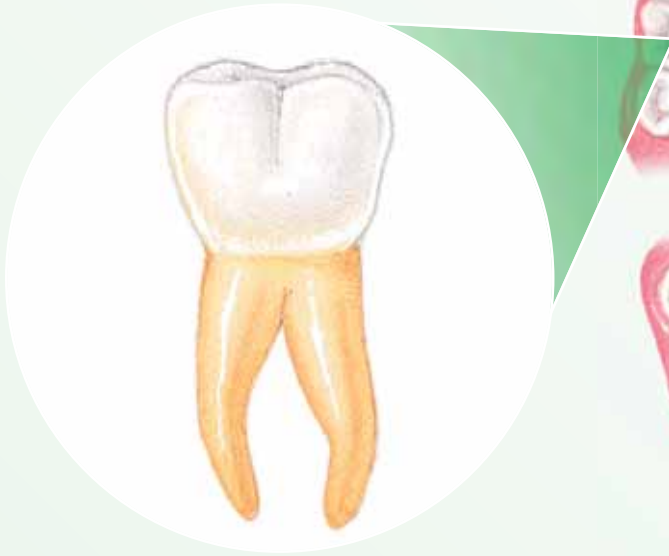▷ԳԵ▷Կ ԳՐՈՒՆ

Uqaup Qitinga

Uqqap Qitqa

Sillon médian de la langue

# Molar



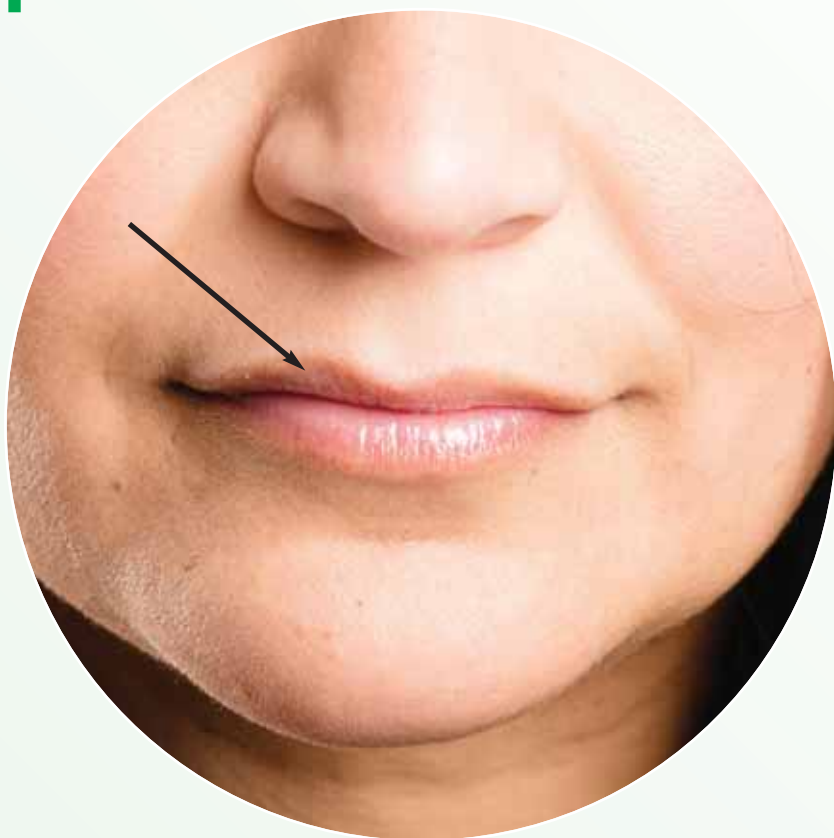Δ ๑๖ ๒ ๑๖ < ๖

Iqtiqqak

Iqhiqqak

Molaire

# Mouth



ጻብጻብ

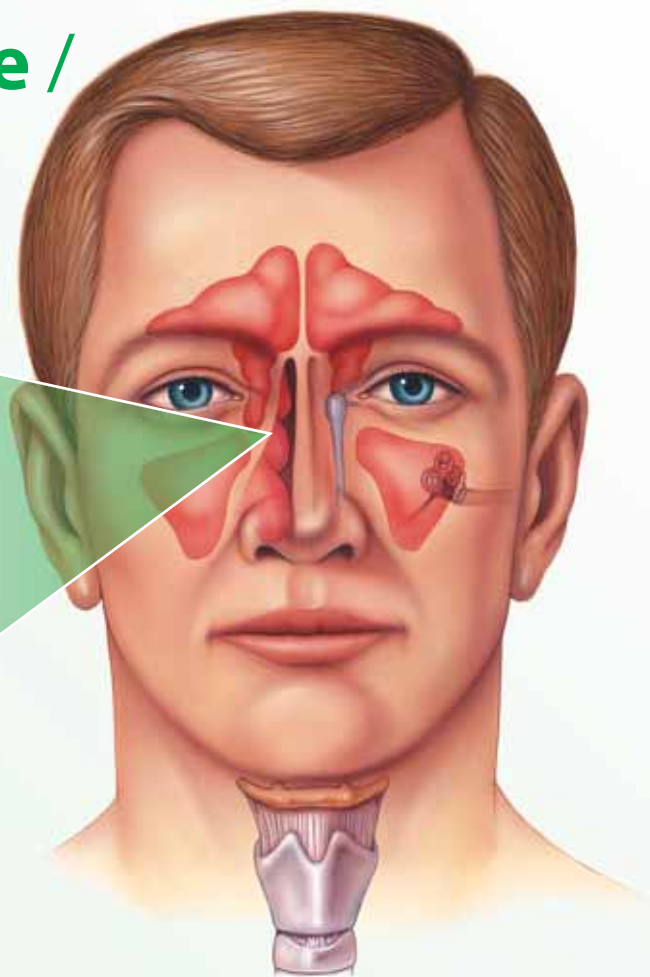
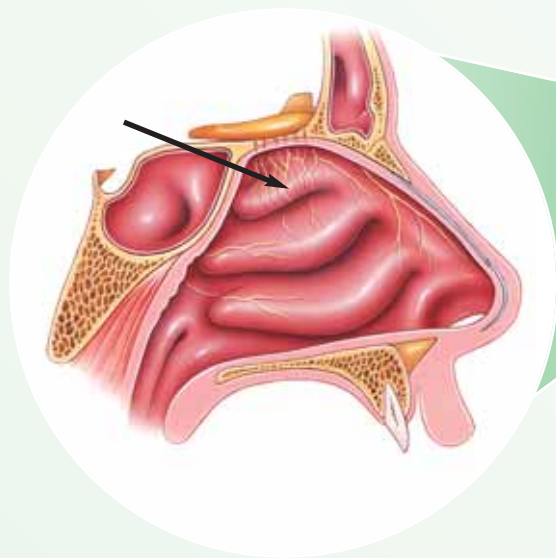
Qaniq

Qaniq

Bouche



# Nasal Conchae / Turbinate Bones



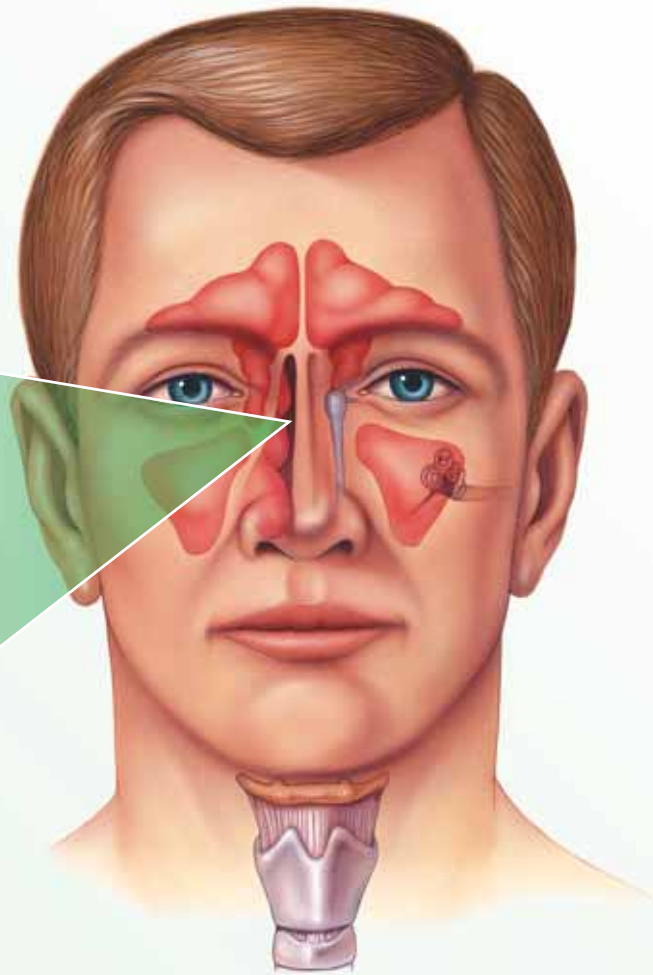
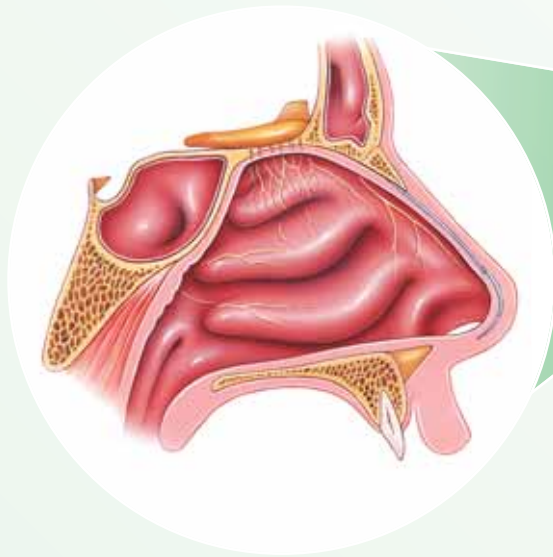
ΔJ↳Δ<sup>c</sup>

Imujait

Umiitaa

Cornets

# Nasal Fossa



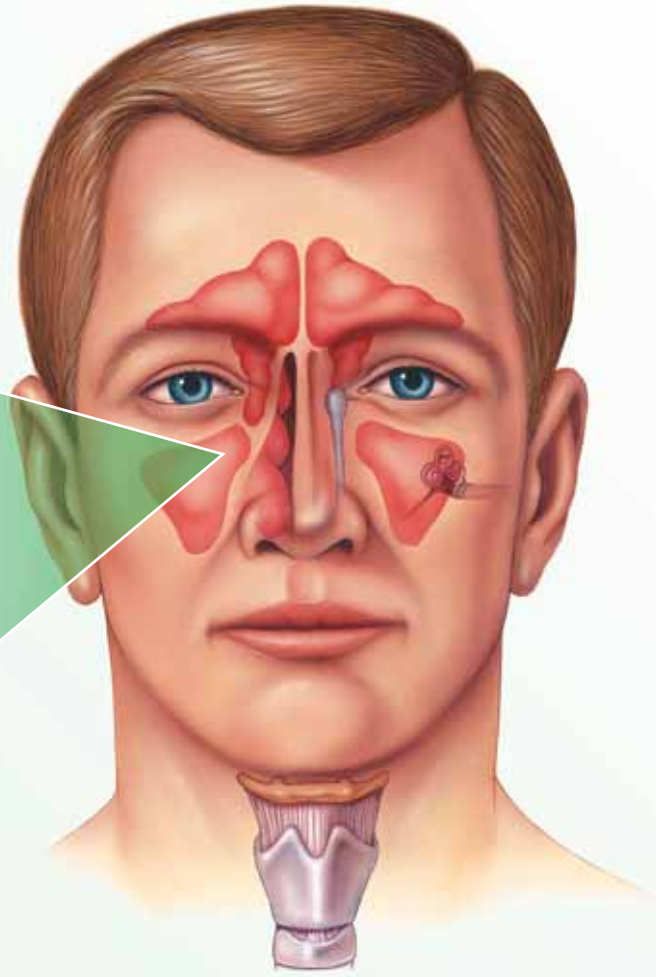
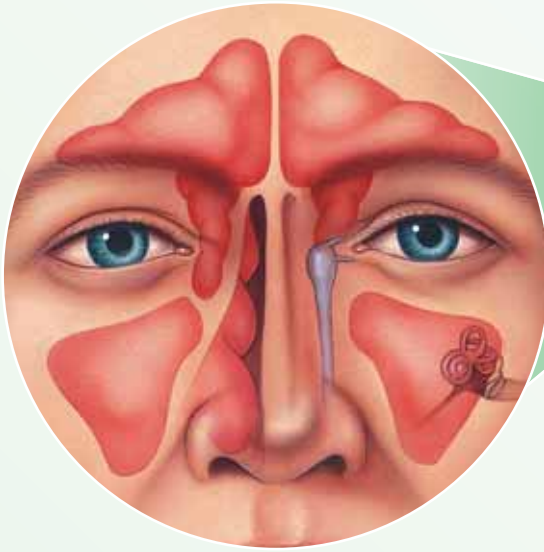
ΔΝῤῥῖσῤῥῖ

Itiqqirniq

Hurluk

Fosse nasale

# Nasal Sinus



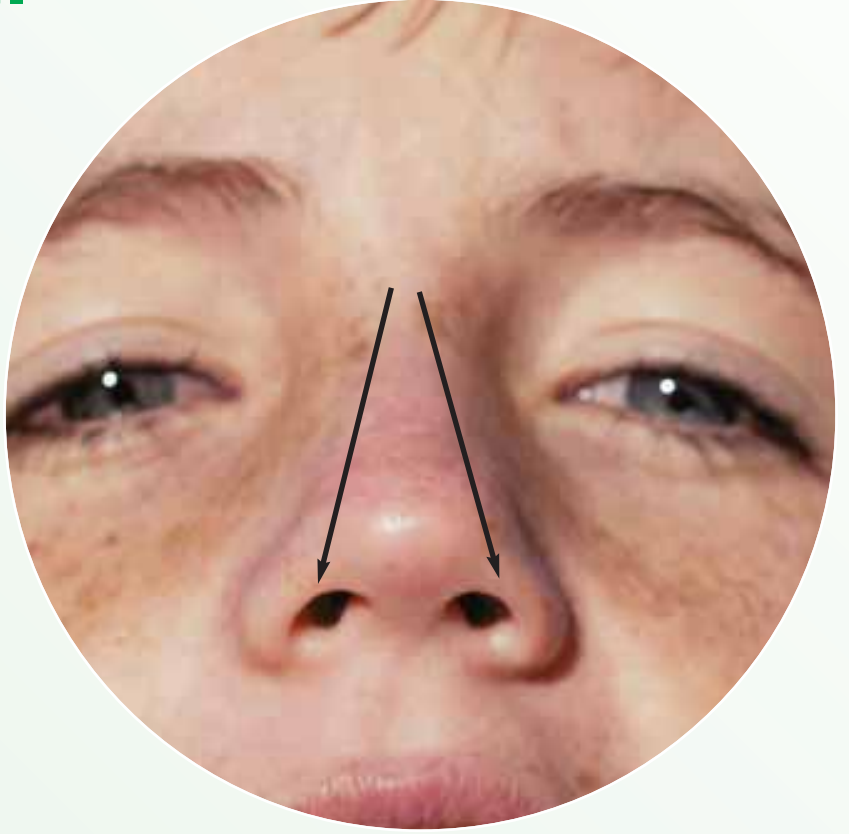
ΔΛΙΝΟ

immutit

Hurluup Qaqqulaanga

Sinus nasaux

# Nostril



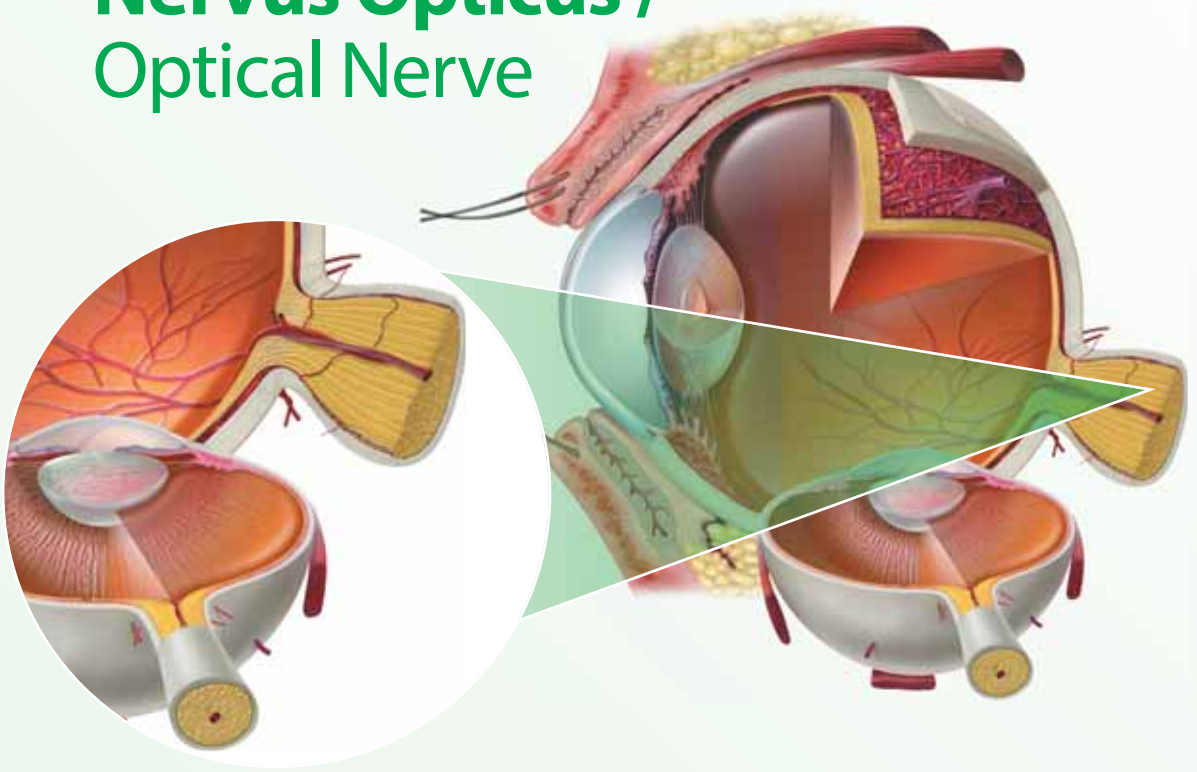
بؤرۈك

Surluk

Hurluk

Narine

# Nervus Opticus / Optical Nerve



Δῖῖῖ ΔΛῖῖῖ

Ijiup Ipiutanga

Iyip Attataa

Nerf optique

# Nose



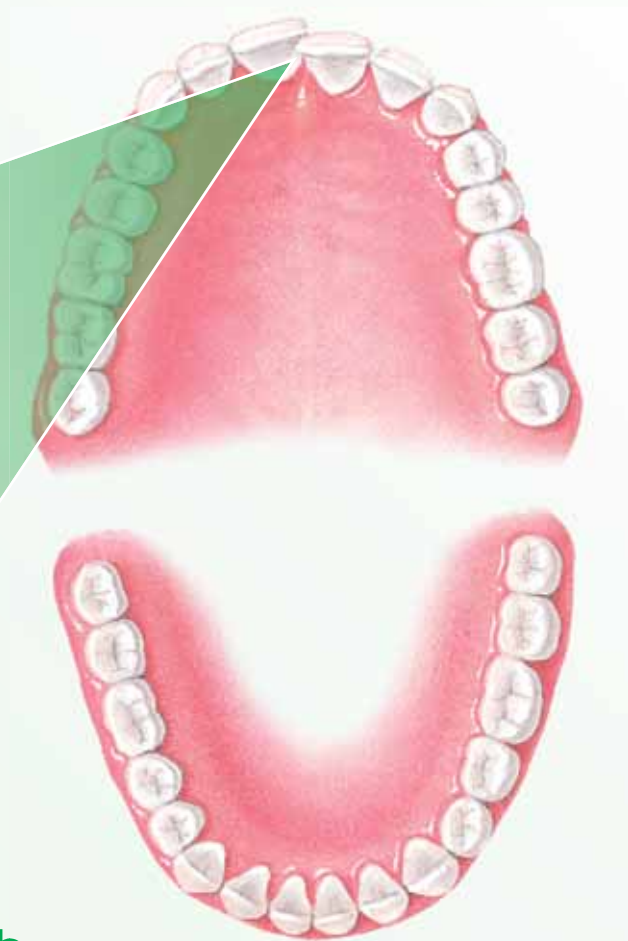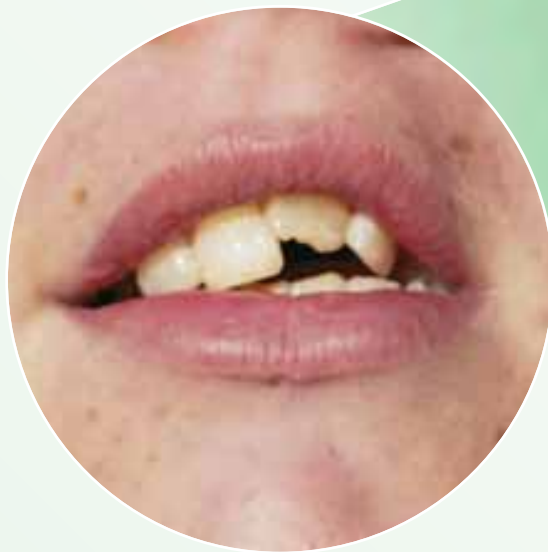
ᄒᄒᄒᄒᄒ

Qingaaq

Qingaaq

Nez

# Overlapping Teeth



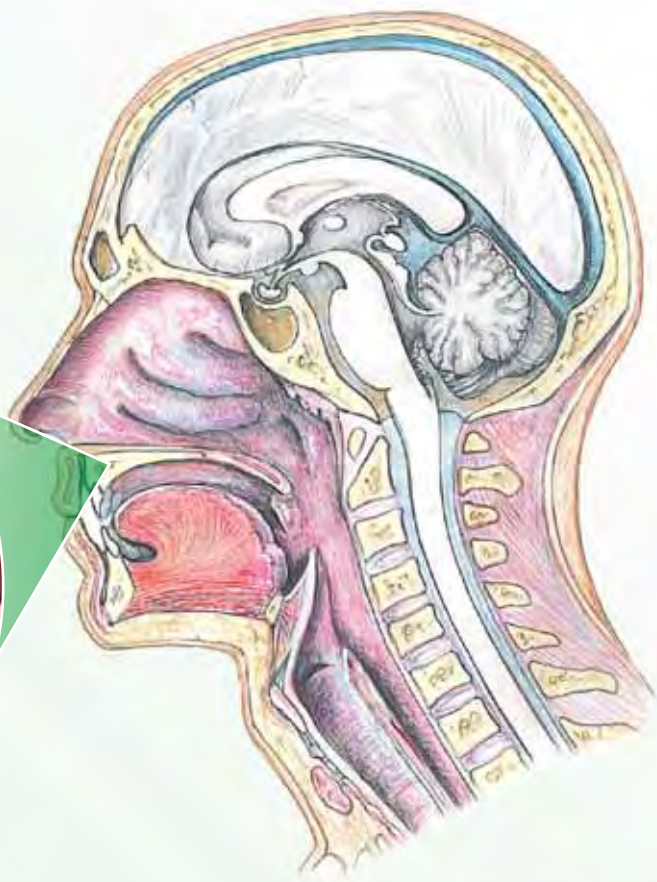
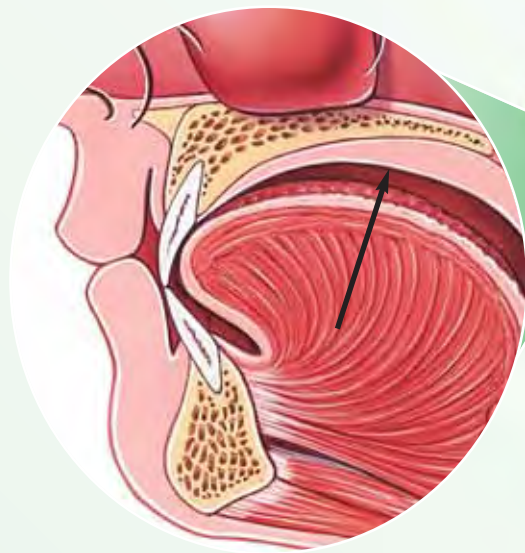
ᐃᐅᐅᐅᐅᐅᐅᐅᐅᐅ

Kigutippalaaqtuq

Kigutit Qaliriiktut

Dents qui se chevauchent

# Palate



قِرَاعُ

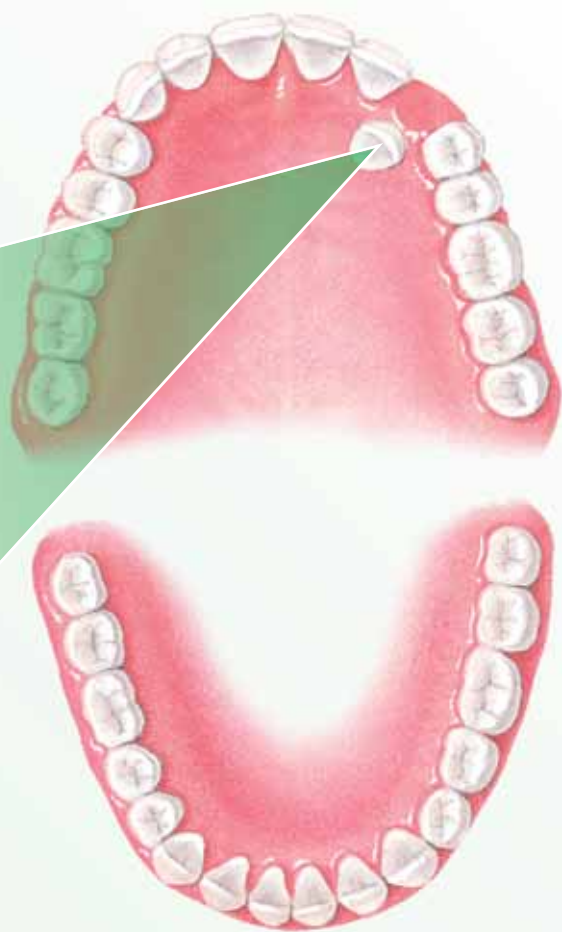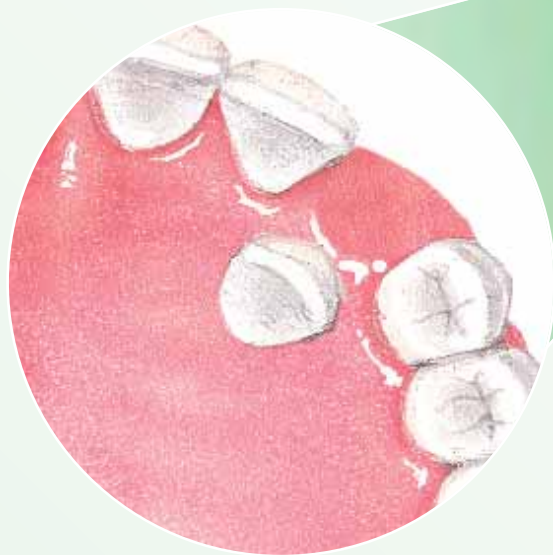
Qilak

Qilagaq

Palais



# Palate Tooth



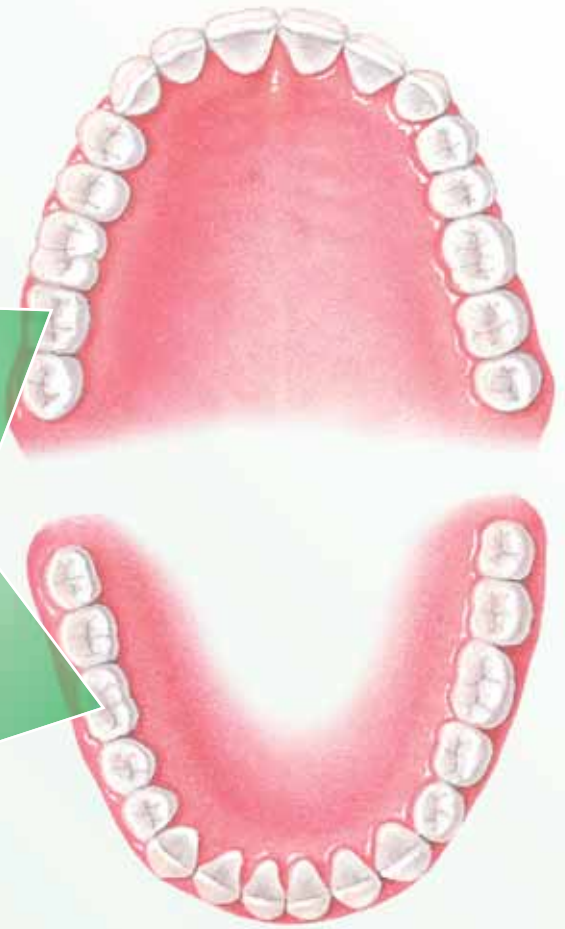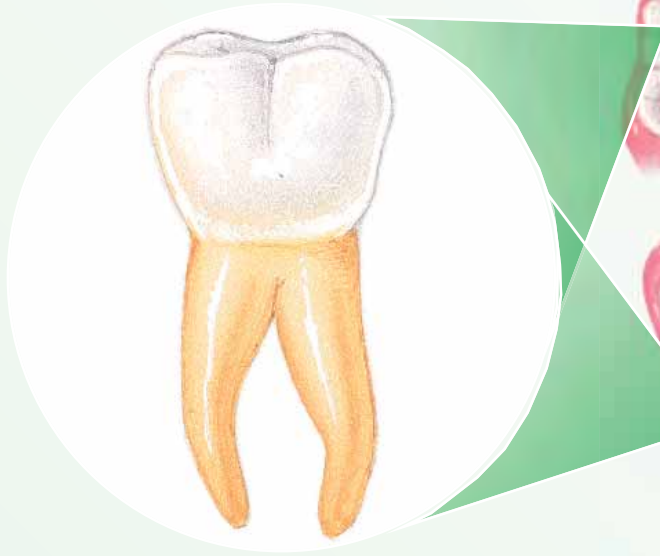ԳՐՃԿԼՈ

Qilummati

Qilangagut kigut nauyuq

Dent de sagesse

# Premolar



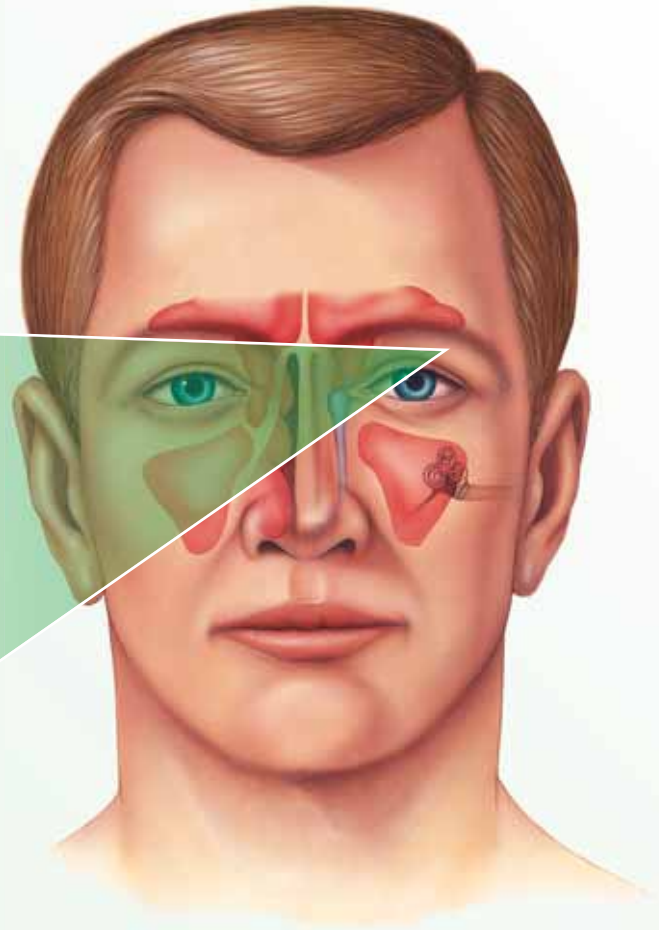
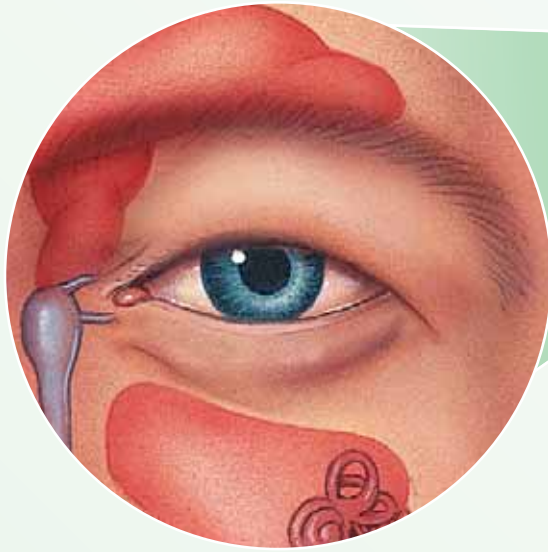
△ ㄉ ㄍ ㄌ ㄎ

Iqłiqpaq

Iqhiqpaup Tuglia

Prémolaire

# Puffy Eye



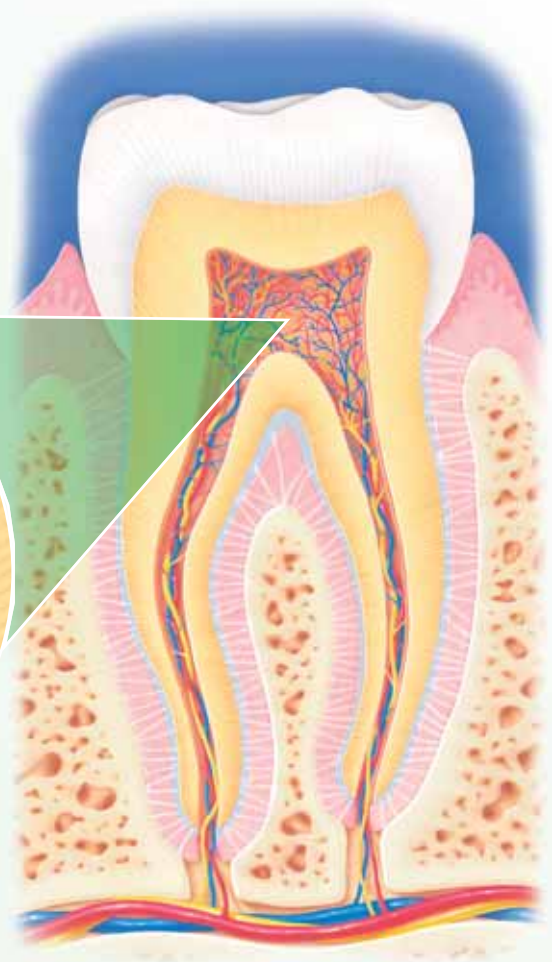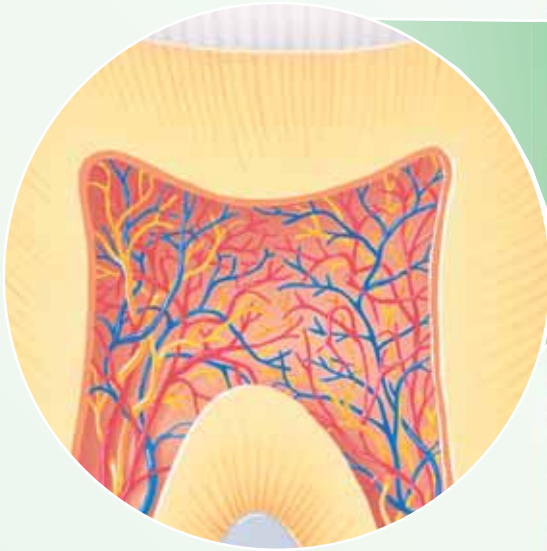
>↳↲↵↶

Pujjijuq

lik Puvipkaqtuk

Poche sous l'oeil

# Pulp



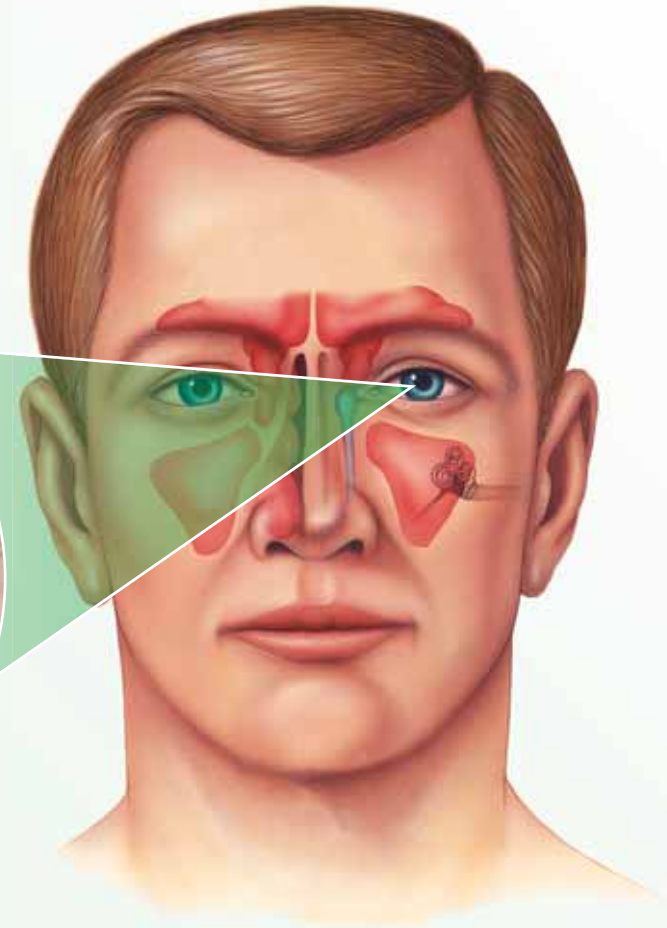
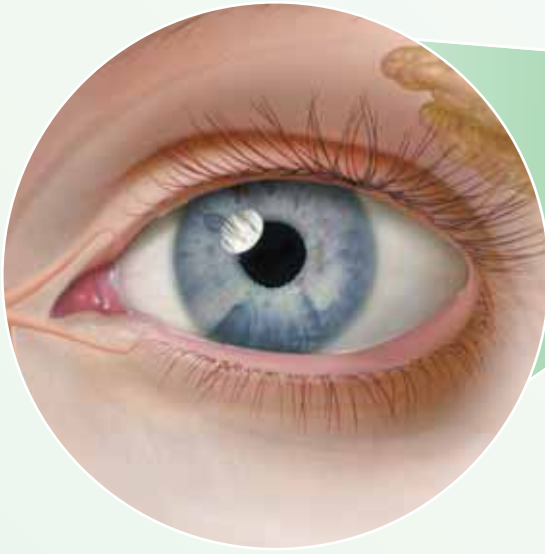
ᐱᑭᑦᑭᑦᑭᑦ ᐃᑦᐱᑦᑭᑦᑭᑦᑭᑦᑭᑦ

Kigutiup Ikpingniajjutinga

Kigutip Manngua

Pulpe

# Pupil



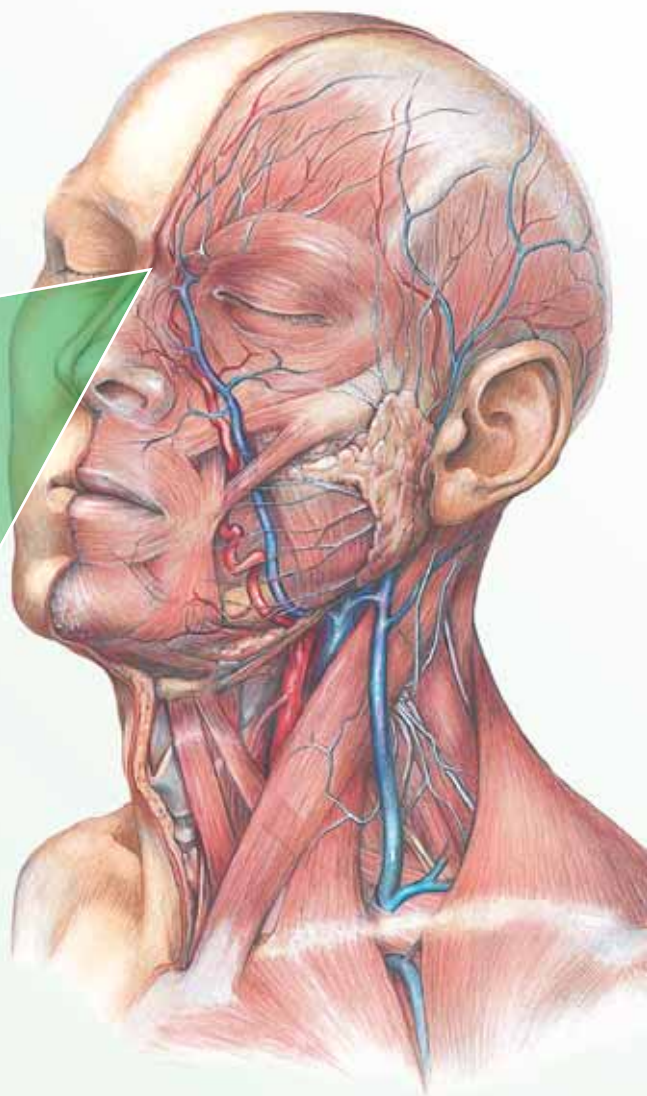
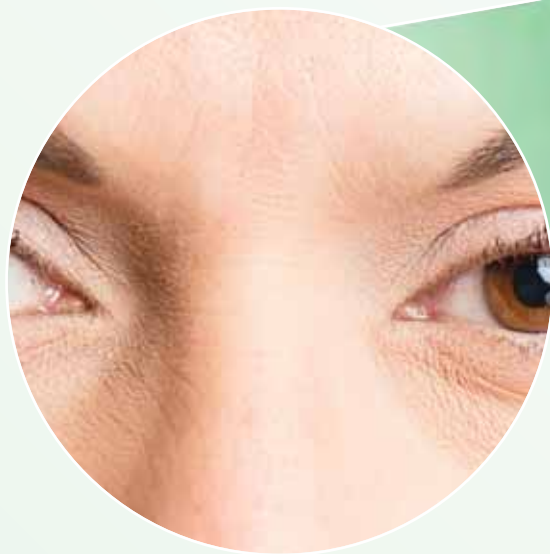ᑕᑦᑲᑦᑲᑦ

Takunnati

Takkuvik

Pupille

# Radix / Glabella / Columella



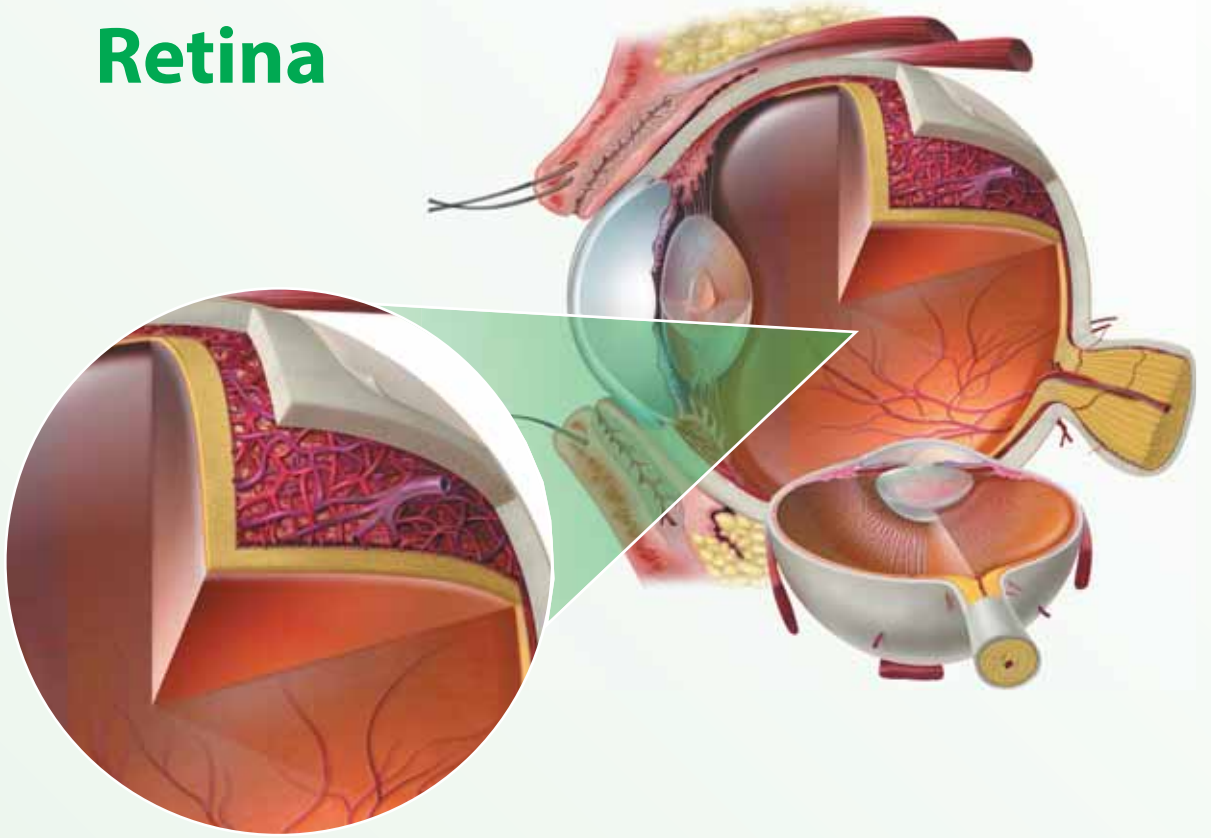
ᐱᑦᑦᑦᑦᑦᑦᑦᑦ

Akuliaq

Qin'nguq

Racine du nez glabelle,  
espace entre les narines

# Retina



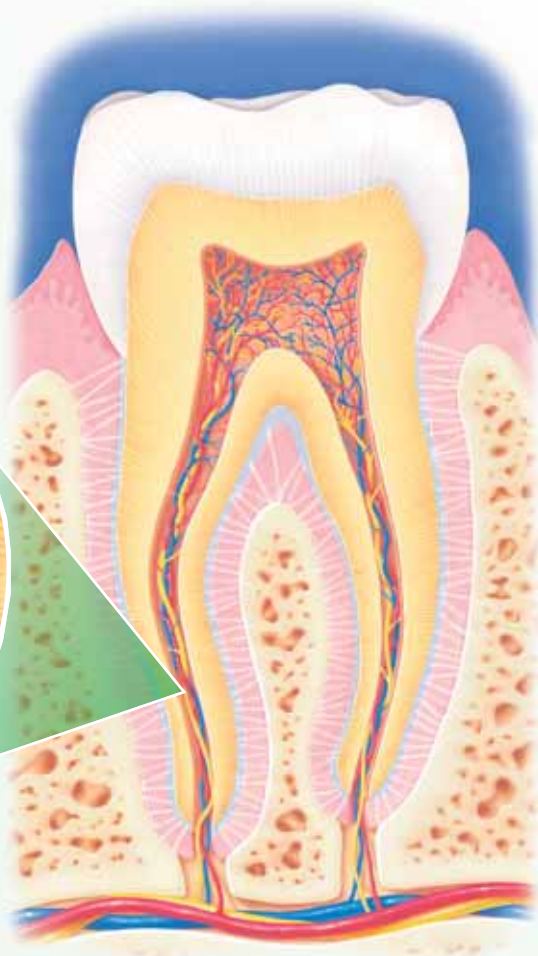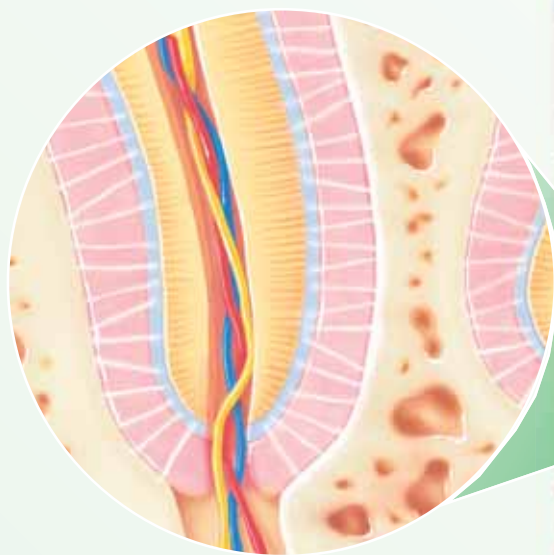
Δῖῑῑ Δῑῑῑῑῑῑῑ

Ijiup ilupaarutanga

Iyip Tautuutaa

Rétine

# Root



ᄇᄆᄇᄆᄆ

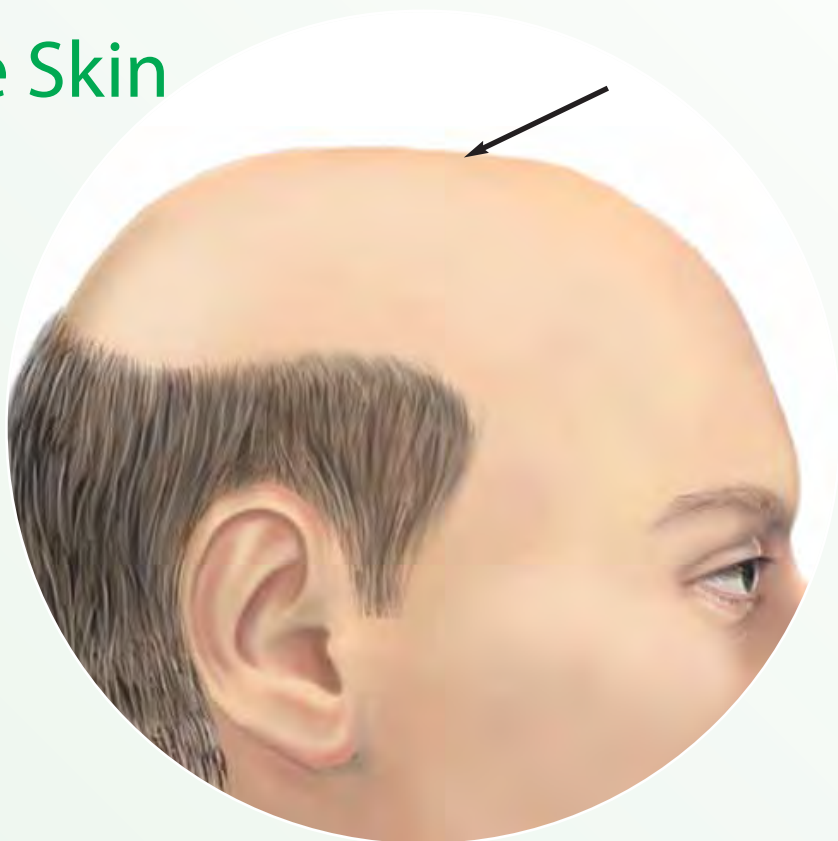
Mannguq

Manngua

Racine



## Scalp, Visible Skin



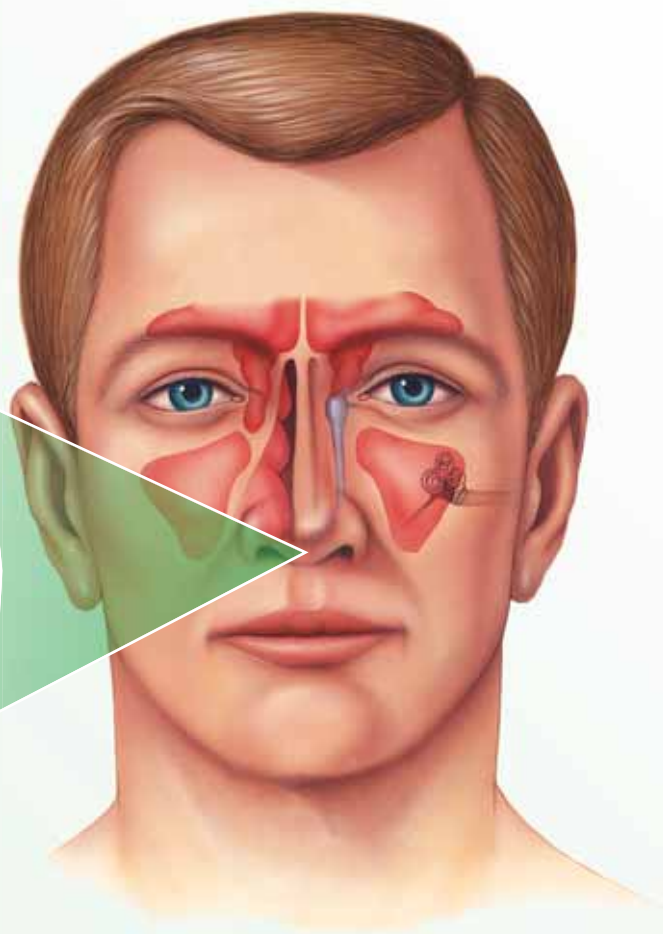
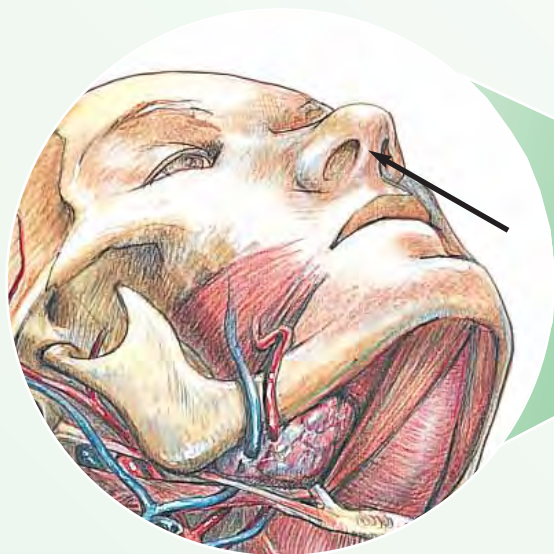
ᐅᐅᐱᐅ

Utuvik

Niaqqup Amia

Cuir chevelu, peau visible

# Septum



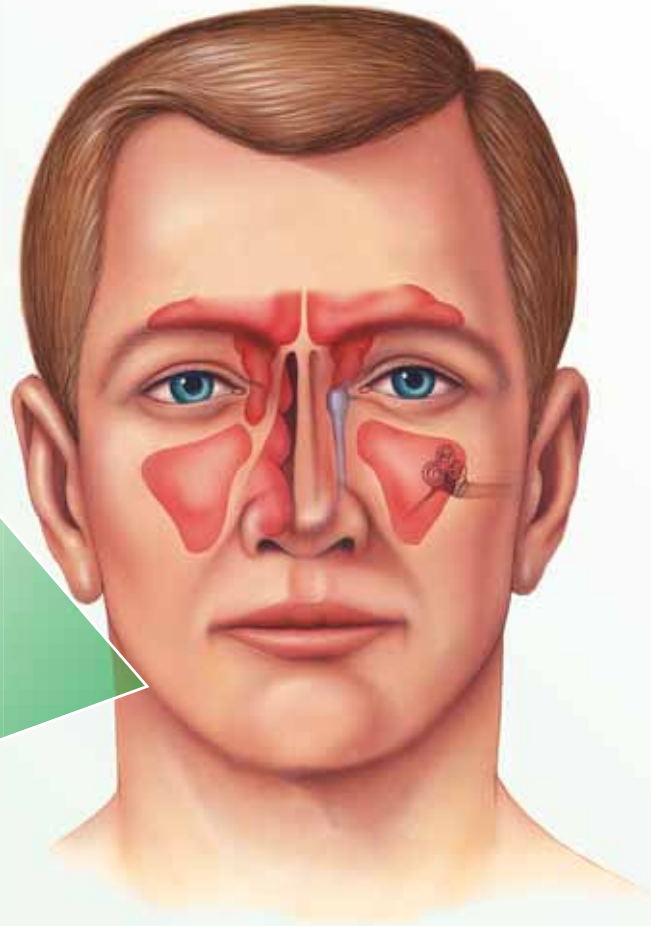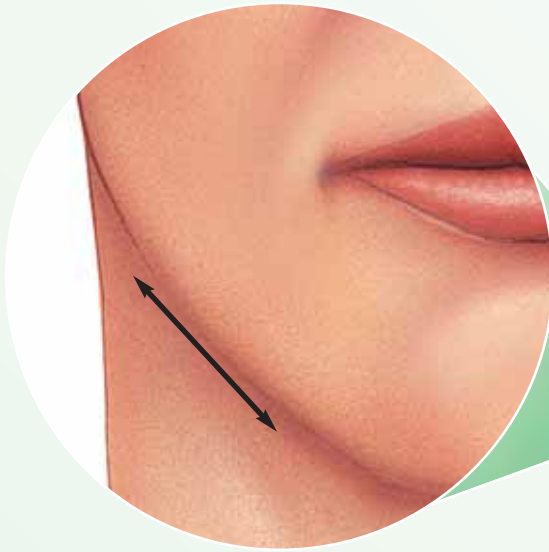
ᄇᄃᄆᄇᄇᄇ ᄇᄃᄆᄇᄇᄇ

Qingaup Nataqqunga

Qaqqulaaq

Espace entre les narines

# Side of the Jaw



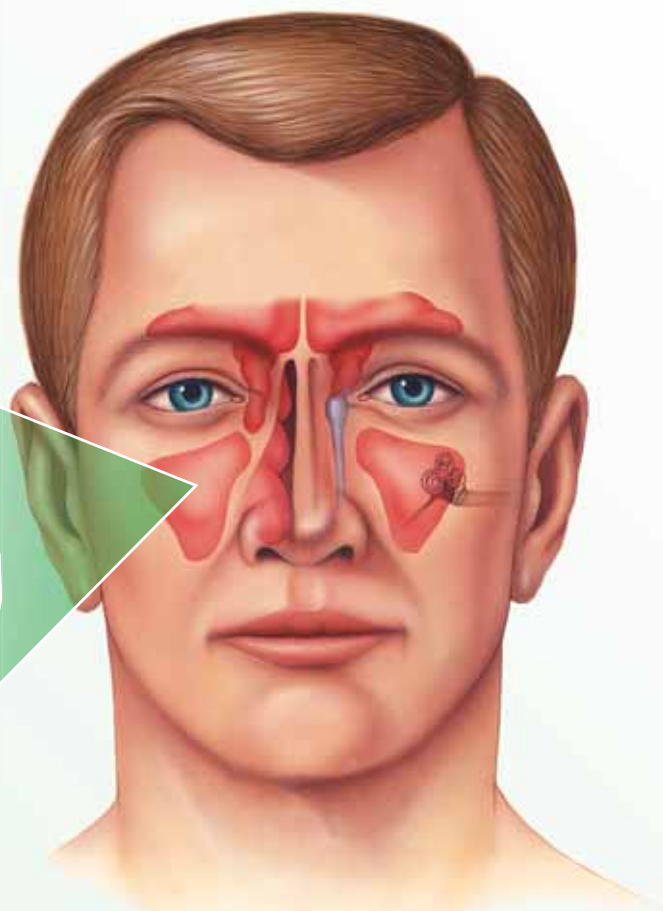
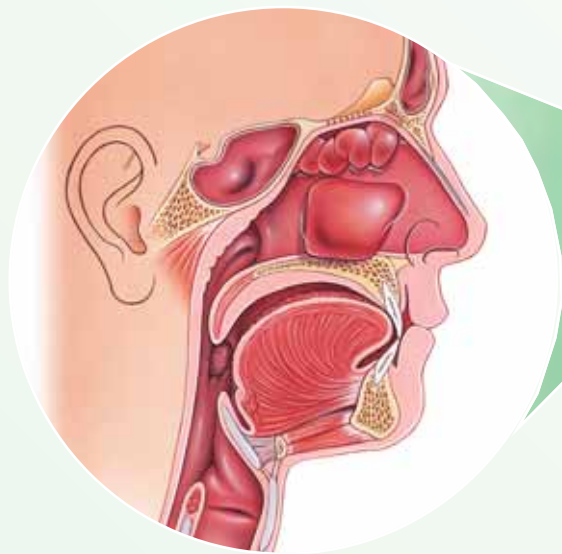ᐃᐅᑦᐅ

Tutaq

Agliruaq

Côté de la mâchoire

# Sinus



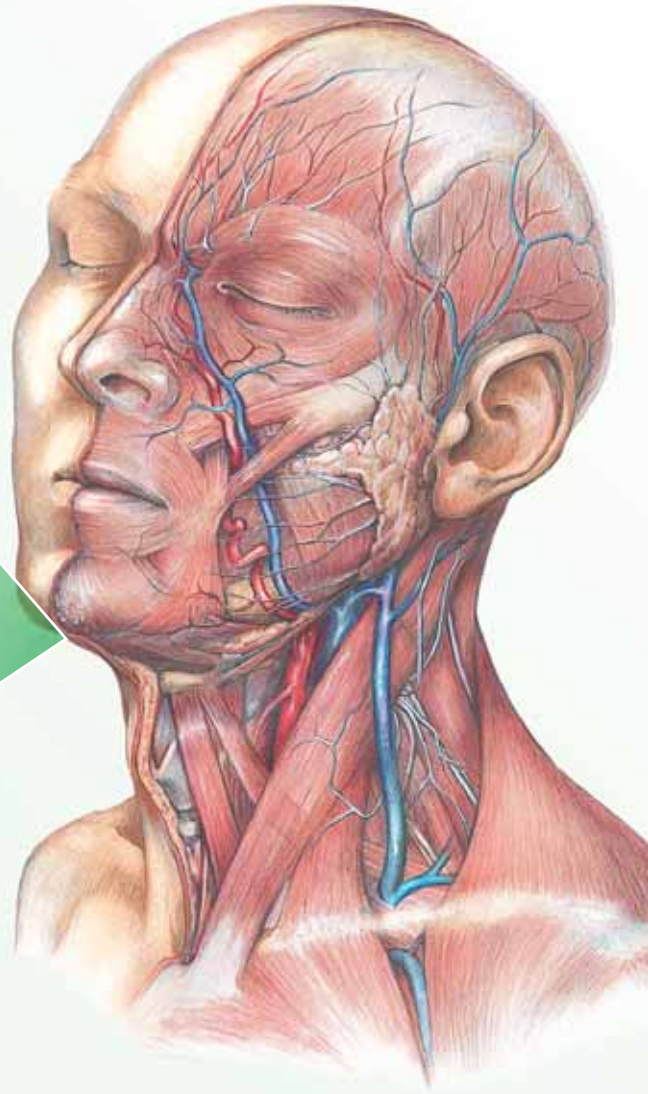
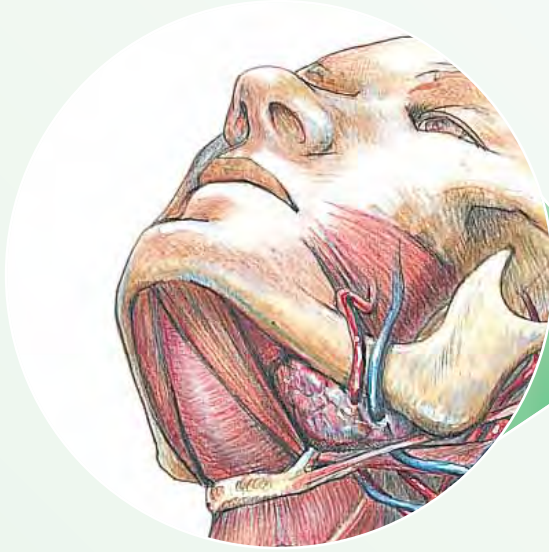
ΔΝῆρῆσῆ

Itiqqirniq

Hurlu

Sinus

# Submental Area



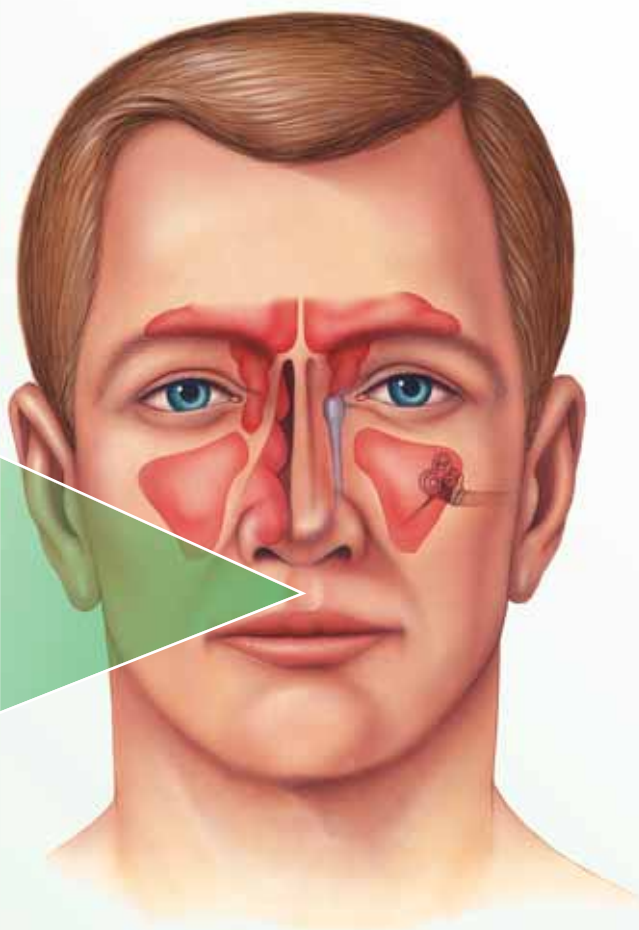
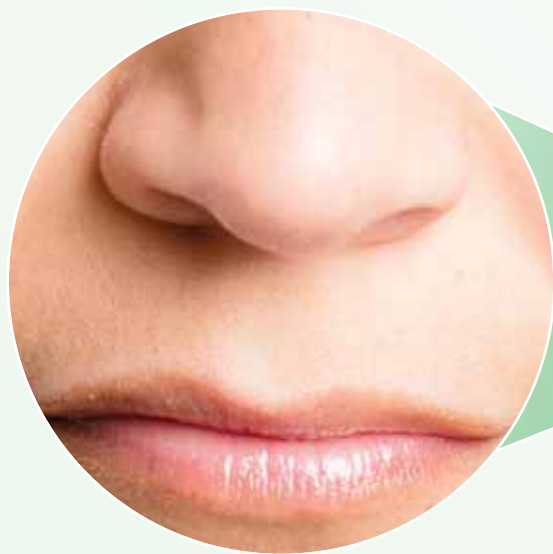ᠰᠤᠮᠤᠨᠲᠤ

Qakirluk

Qakilhuq

Région sous-mentale  
(espace entre menton et cou)

# Subnasal / Nasolabial Groove



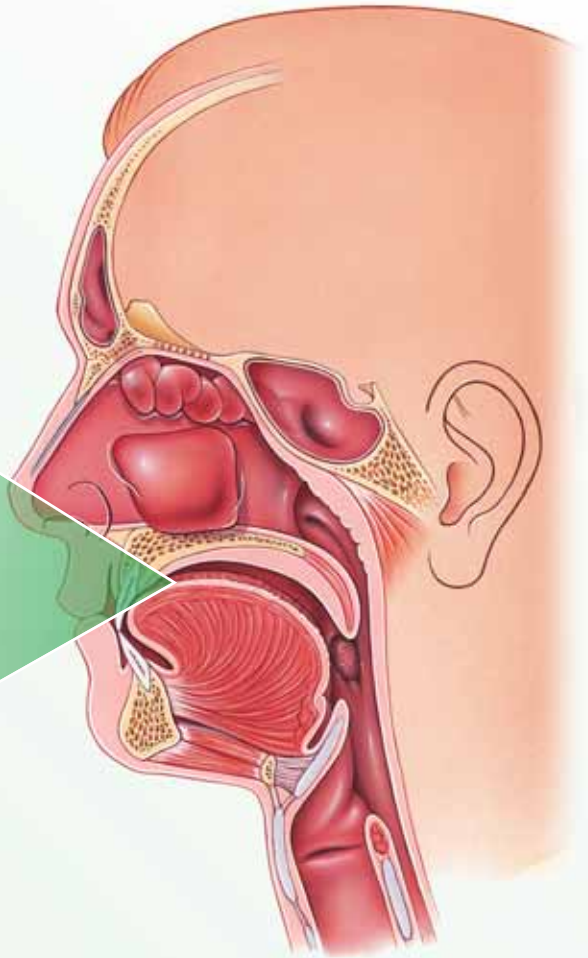
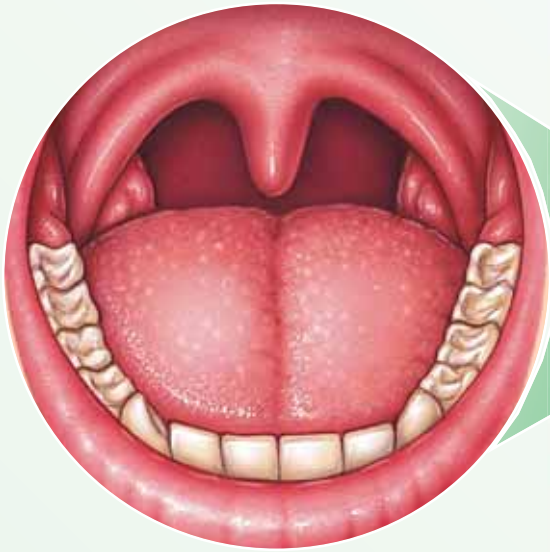Δ 𐌆𐌇𐌈𐌉

Iluqsaq

Kakkiviaq

Silon sub-nasal ou  
naso-labial

# Taste Buds



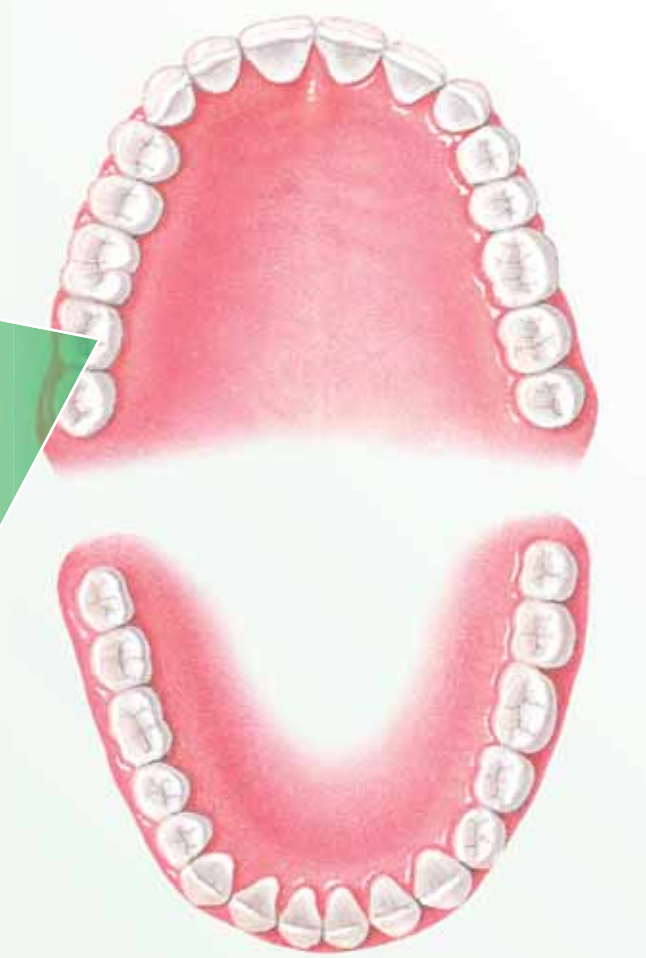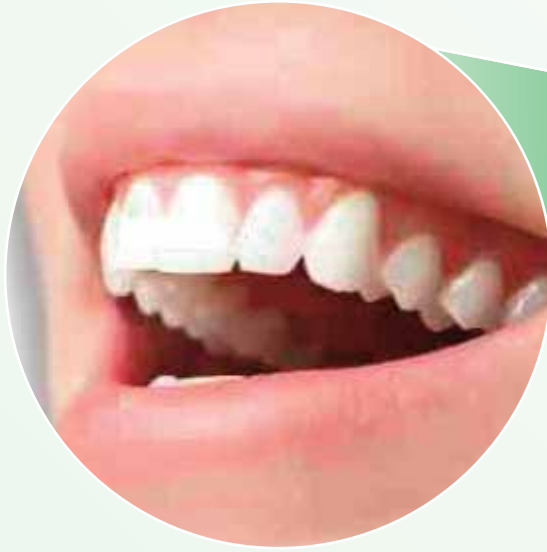ᐅᑦᑲᑲᑦᑦ ᑲᐃᐅᑦᑲᑦ

Uqakkut Naimajjutit

Niqinik Ilitaqhijutit

Papilles gustatives

# Teeth



ᐱᐭᐅᐅ

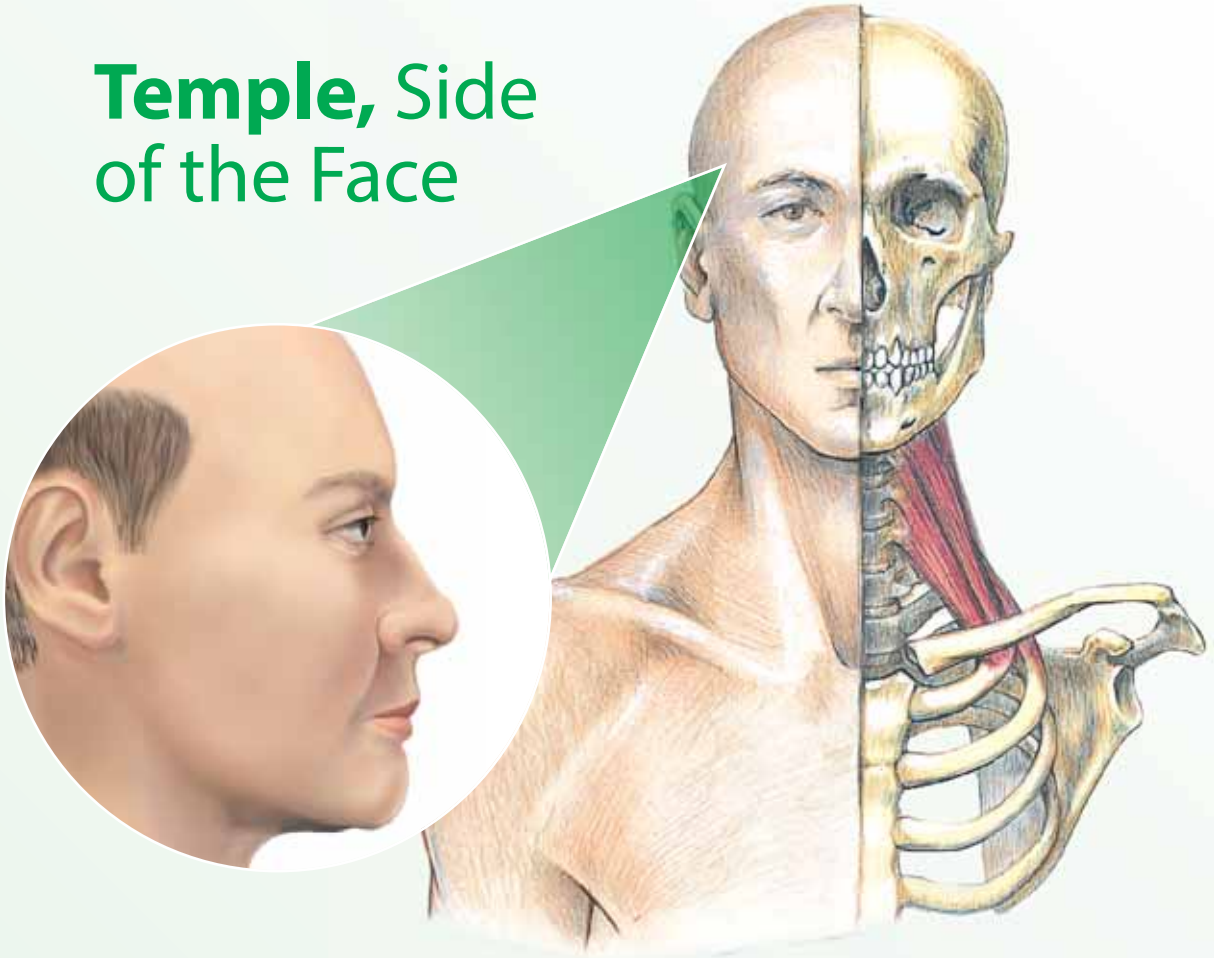
Kigutit

Kigutit

Dents



# Temple, Side of the Face



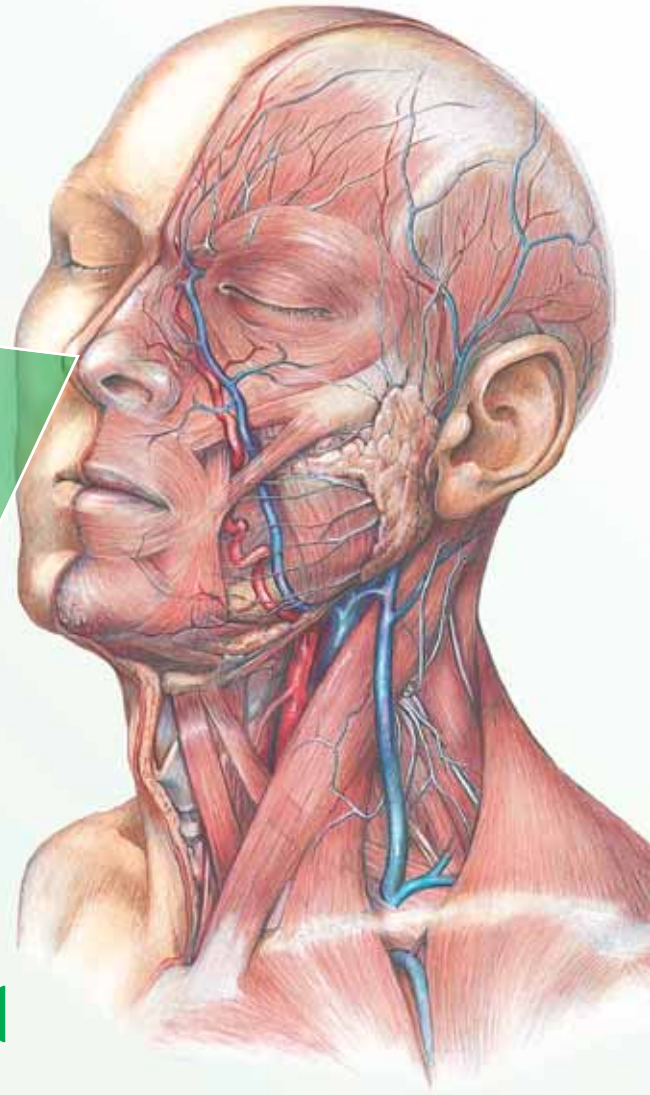
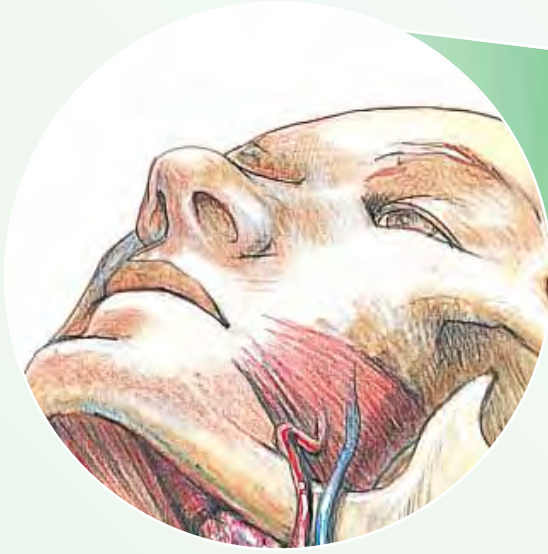Δ ᑭᑲ ᑭᑲ

Iqsaq

Tuuttiniq

Tempe, côté du visage

## Tip of the Nose



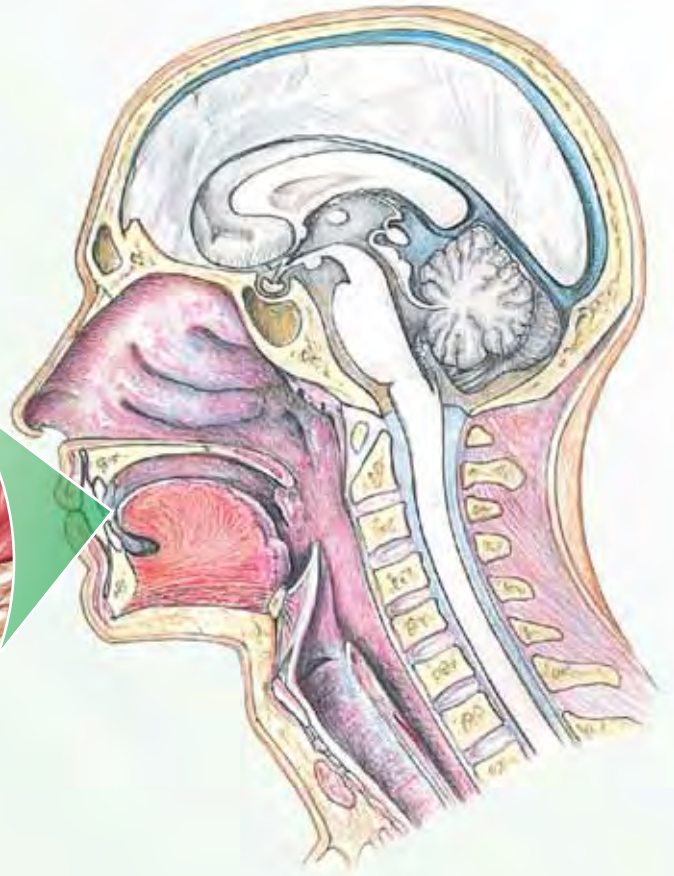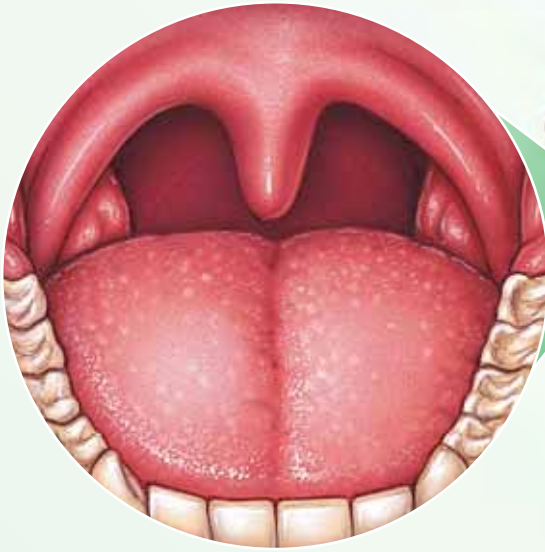
ᐱᕈᕐᕐᕐᕐᕐᕐ ᕐᕈᕐᕐᕐᕐᕐᕐ

Qingaup Nuvua

Qingaup Nuvua

Pointe du nez

# Tip of the Tongue



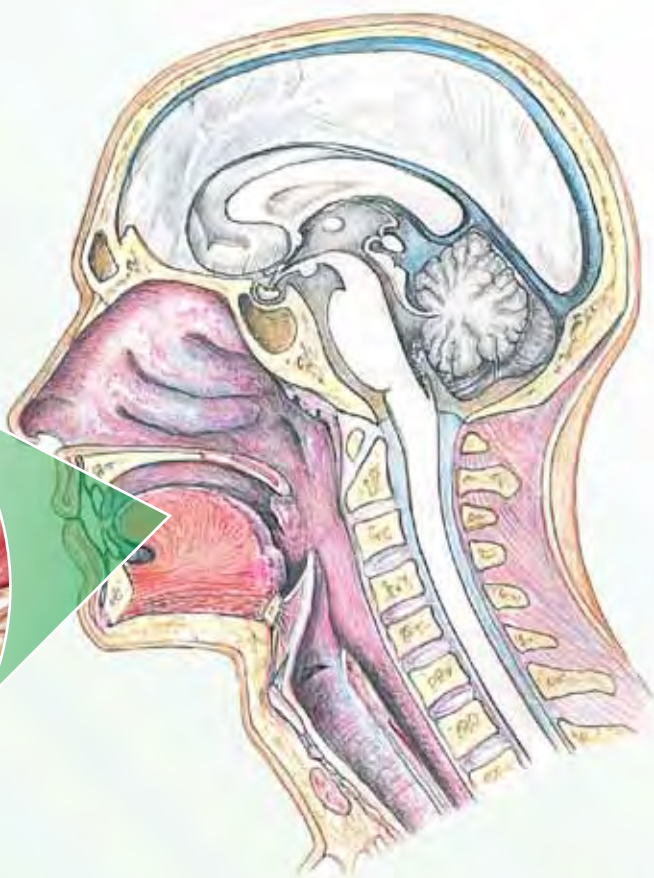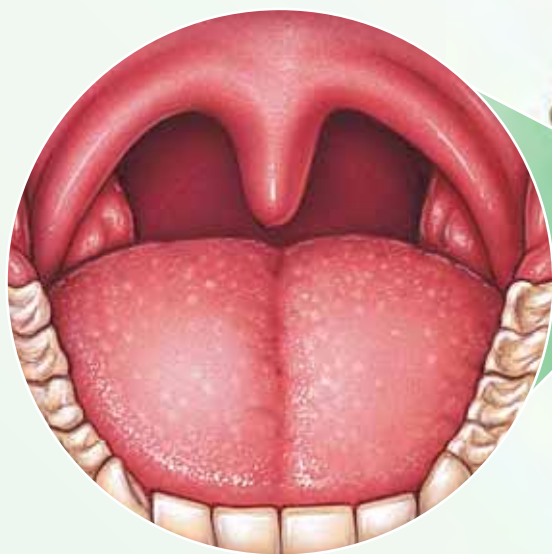
ᐅᑦᑲᐅᑦ ᐅᑦᑲᐅᑦ

Uqaup Nuvua

Uqqap Nuvua

Pointe de la langue

# Tongue



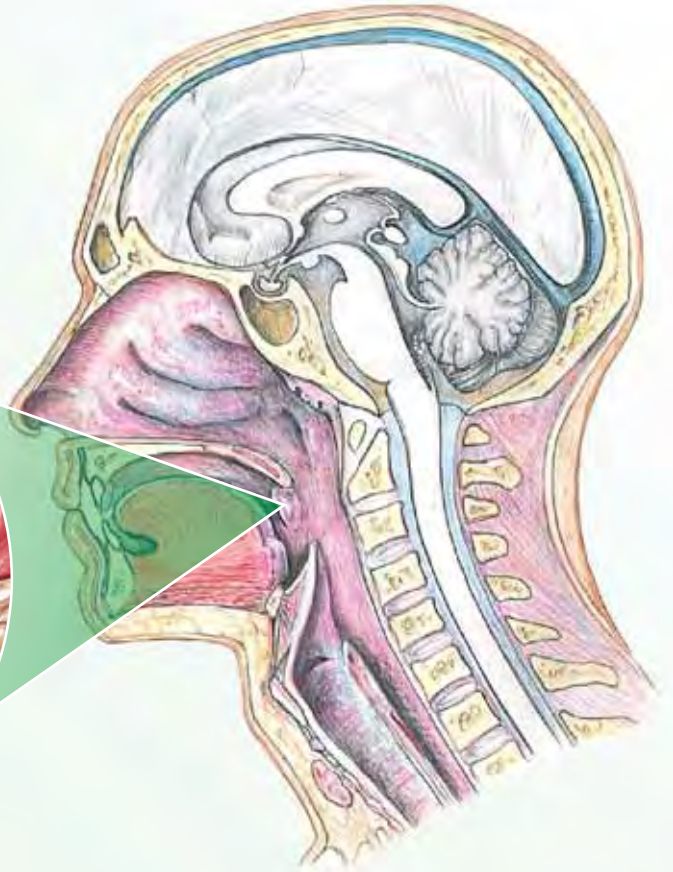
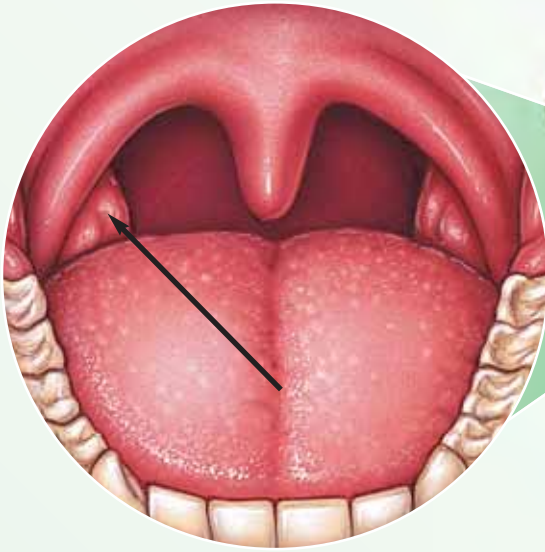
▷ ᄅᄅᄅ

Uqaq

Uqaq

Langue

# Tonsil



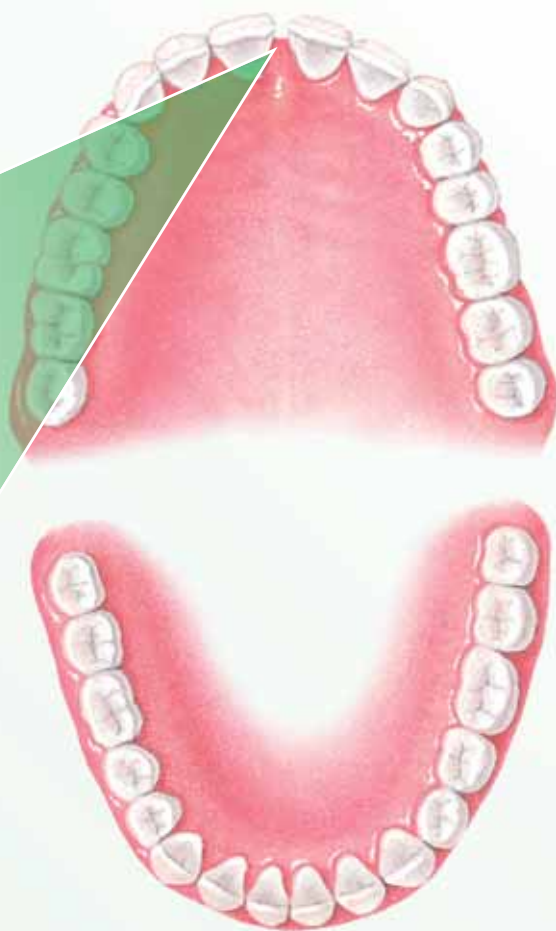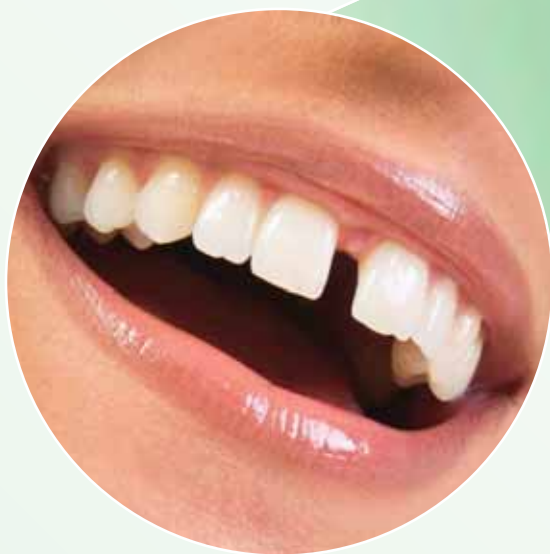ᄄᄁᄂᄃᄄᄅ

Qiliqsinaq

Qiniqhinaq

Amygdale

# Tooth Gap



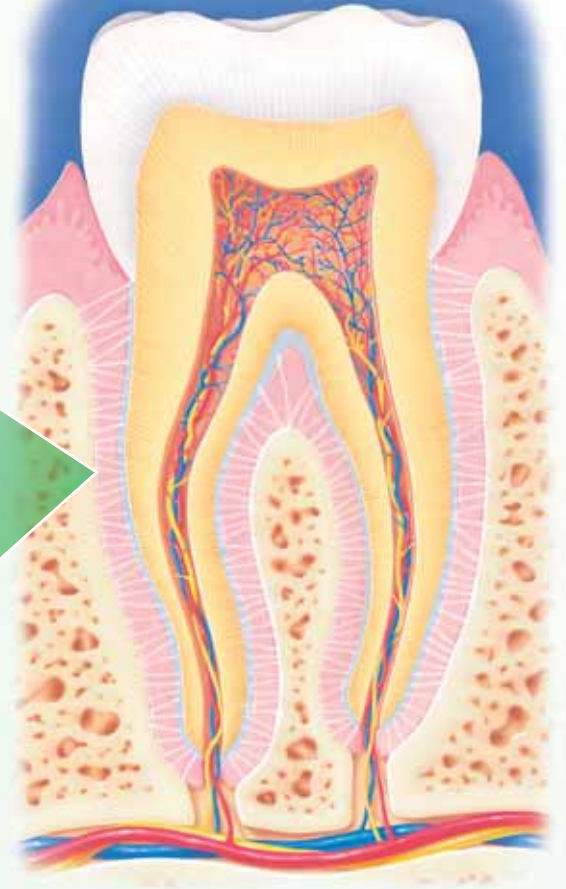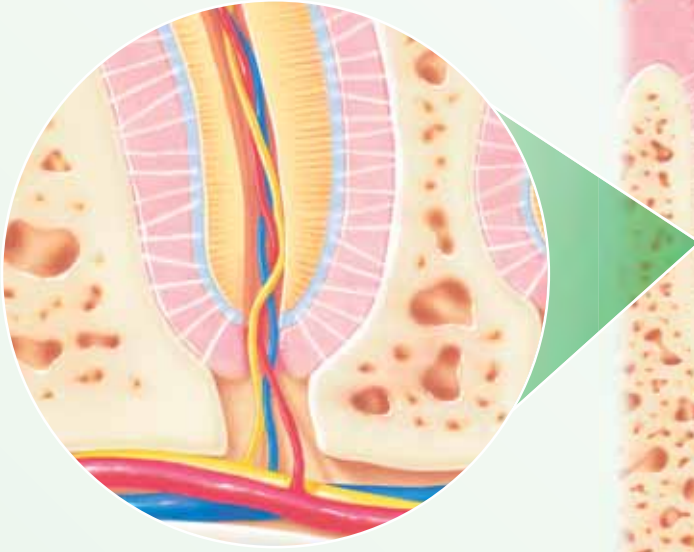
ᐅᐃᐅᐅᐅ

Kinngiq

Kigutip Akutturnia

Absence de dent,  
brèche-dent

# Tooth Socket



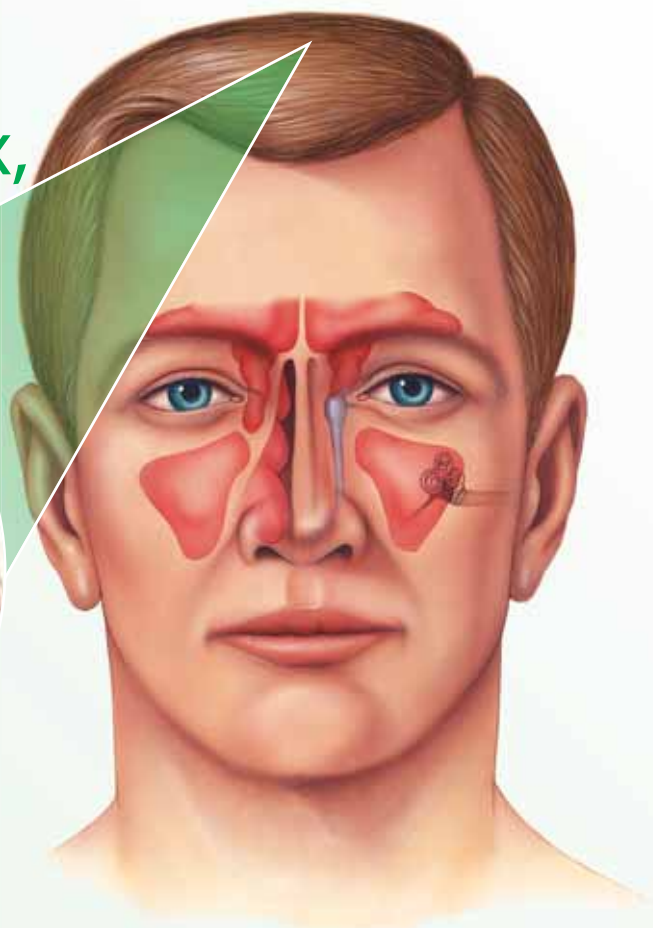ԲՅՈՒՆԳԱԾ

Kigutiqarvik

Kigutaiqhirvik

Alvéole dentaire

# Top of the Head / Vertex, Tuft of Hair



бъꞤꞤ

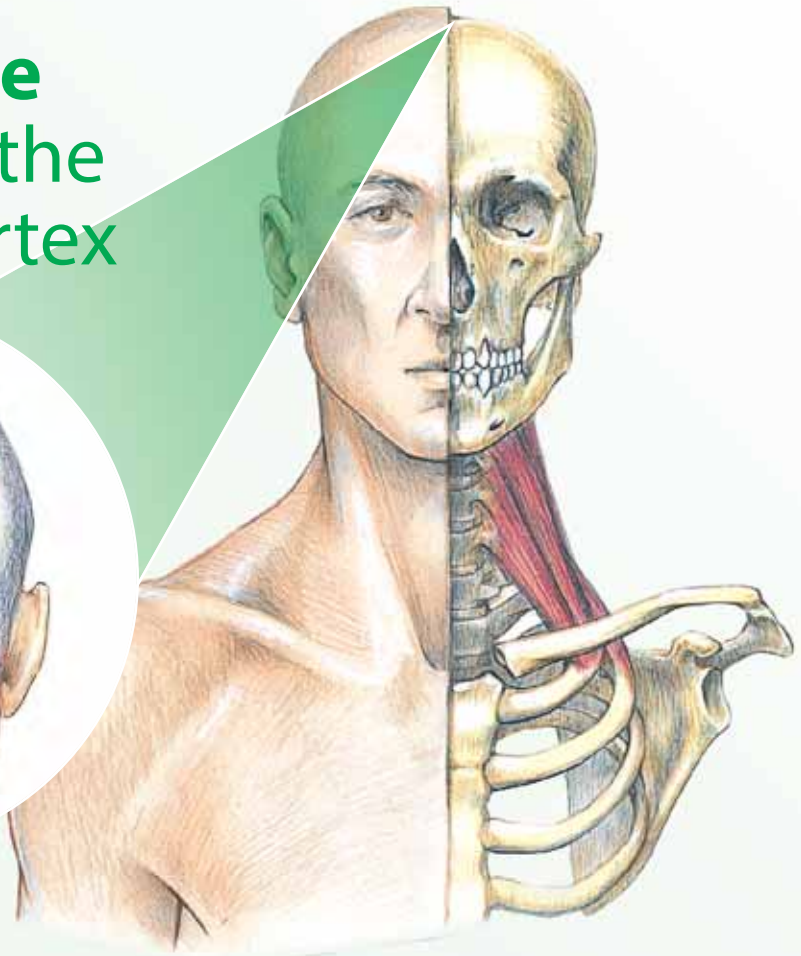
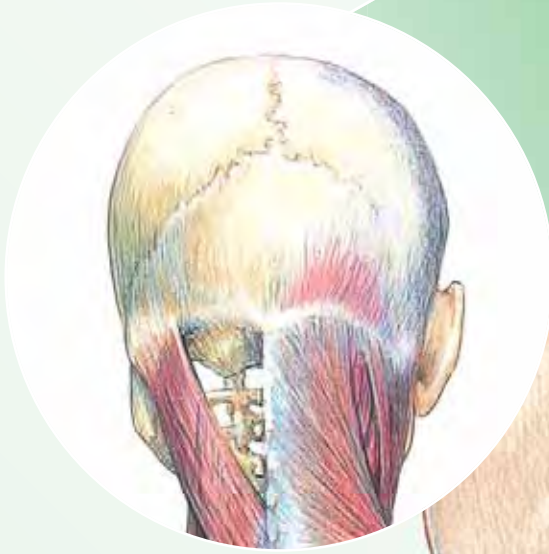Kajjiq

Kaavyiq

Sommet de la tête,  
épi de cheveux



# Top of the Head, of the Skull / Vertex



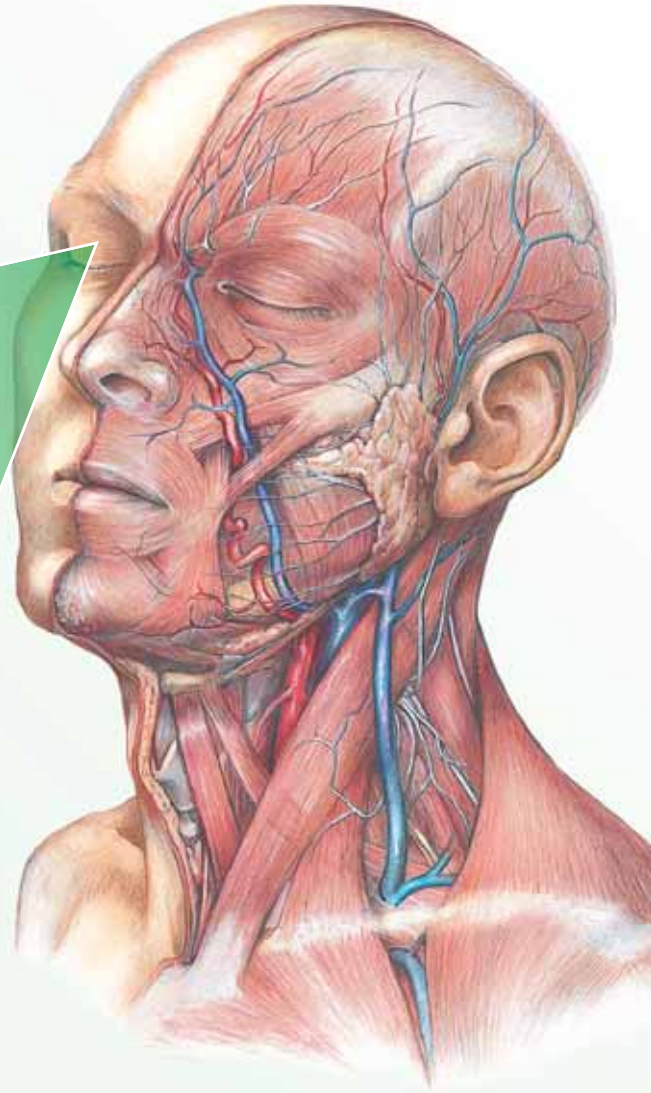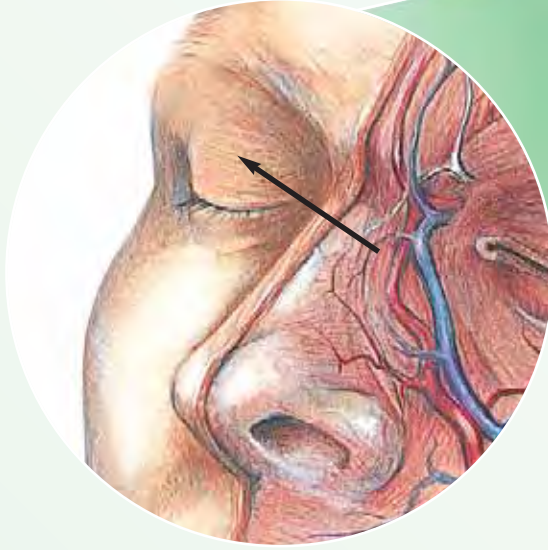ᐱᑲᑲᑦ

Makkaq

Hivu

Sommet de la tête,  
du crâne

# Upper Eyelid



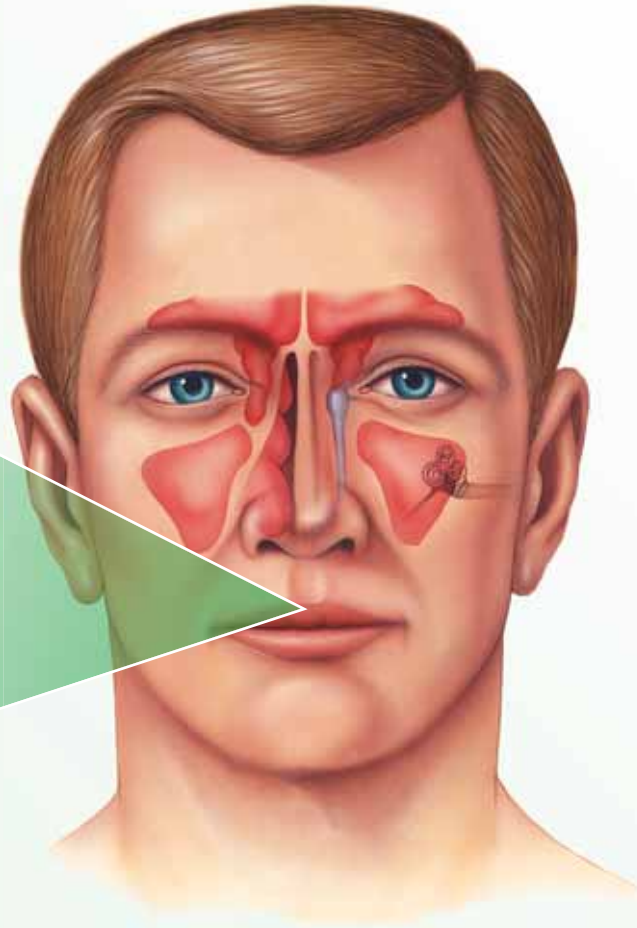
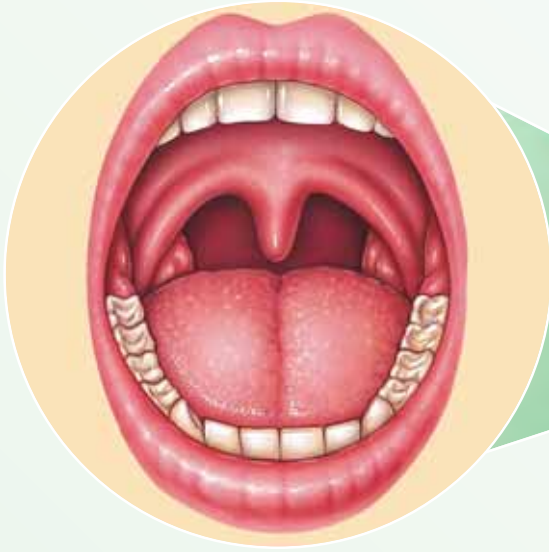ᲒᲗᲗᲗ

Punngati

Qablunak

Paupière supérieure

# Upper Lip / Inside of the Lower Lip



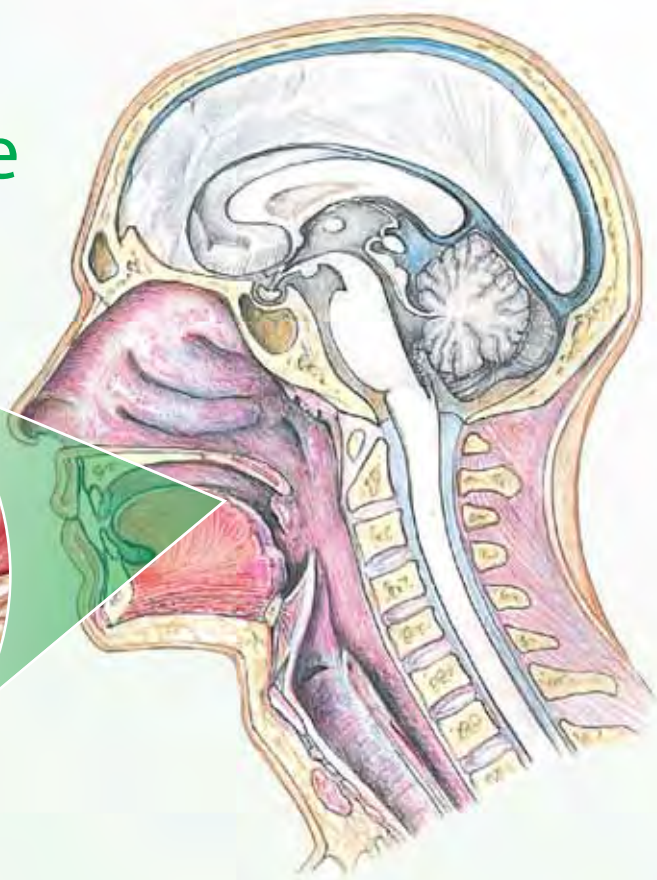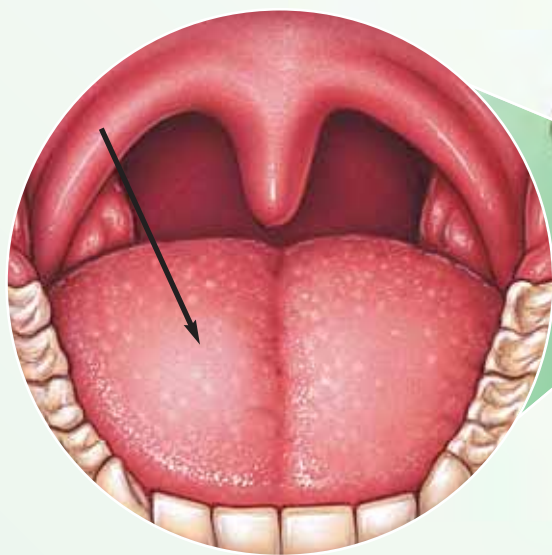
ᑭᑦᑲᑦᑲᑦᑲᑦᑲᑦ

Qarngasinaaq

Umilruq

Lèvre supérieure /  
intérieur de la lèvre  
inférieure

## Upper Side of the Tongue



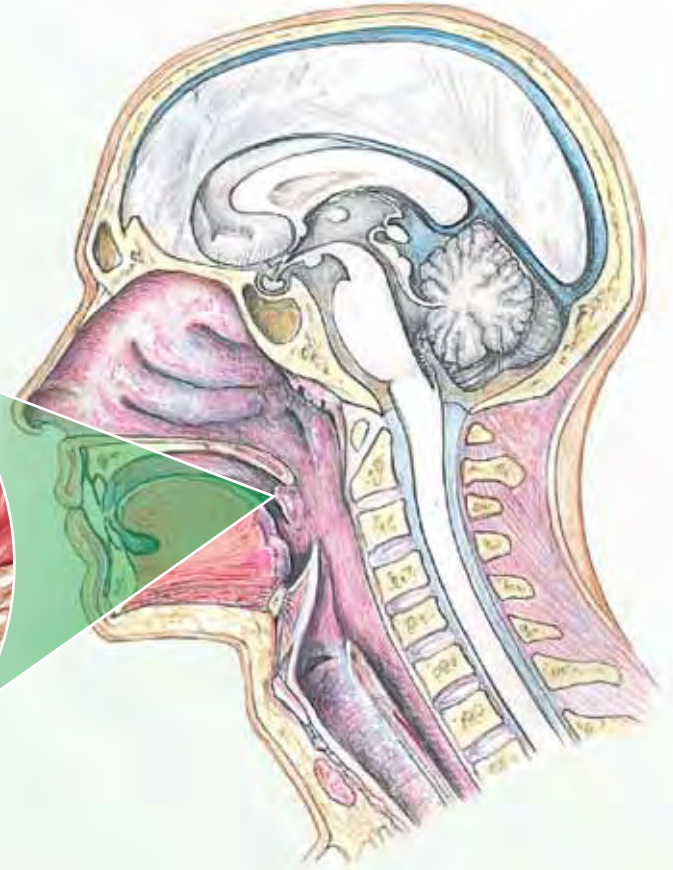
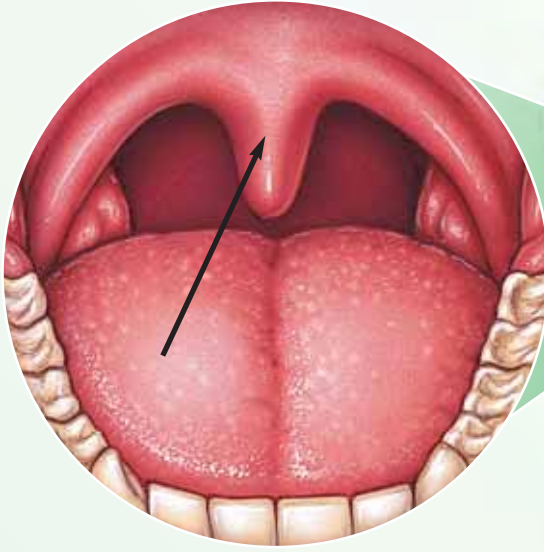
▷ᑦᑲ▷ᑦ ᑦᑲᑦᑲ

Uqaup Qaanga

Uqqap Qaanga

Face supérieure de la langue

# Uvula



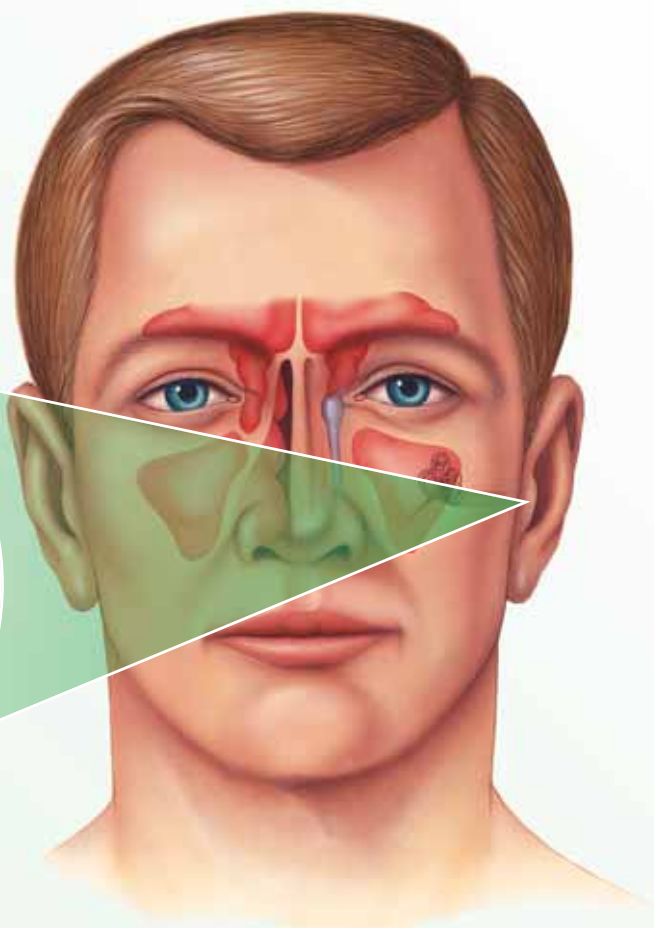
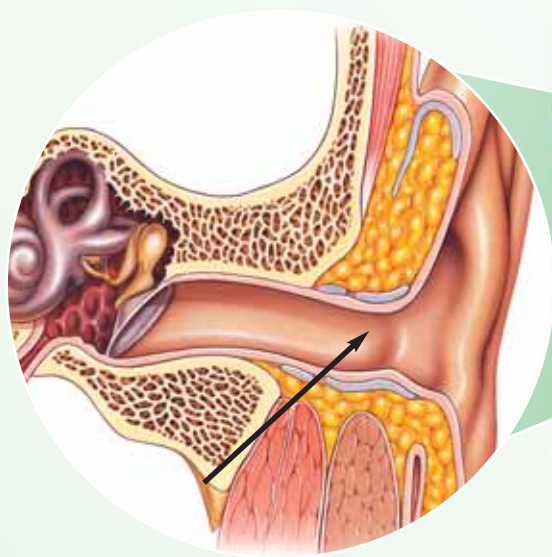
σῦλῶν

Niriliktaq

Niriliktaq

Luette

# Vestibule



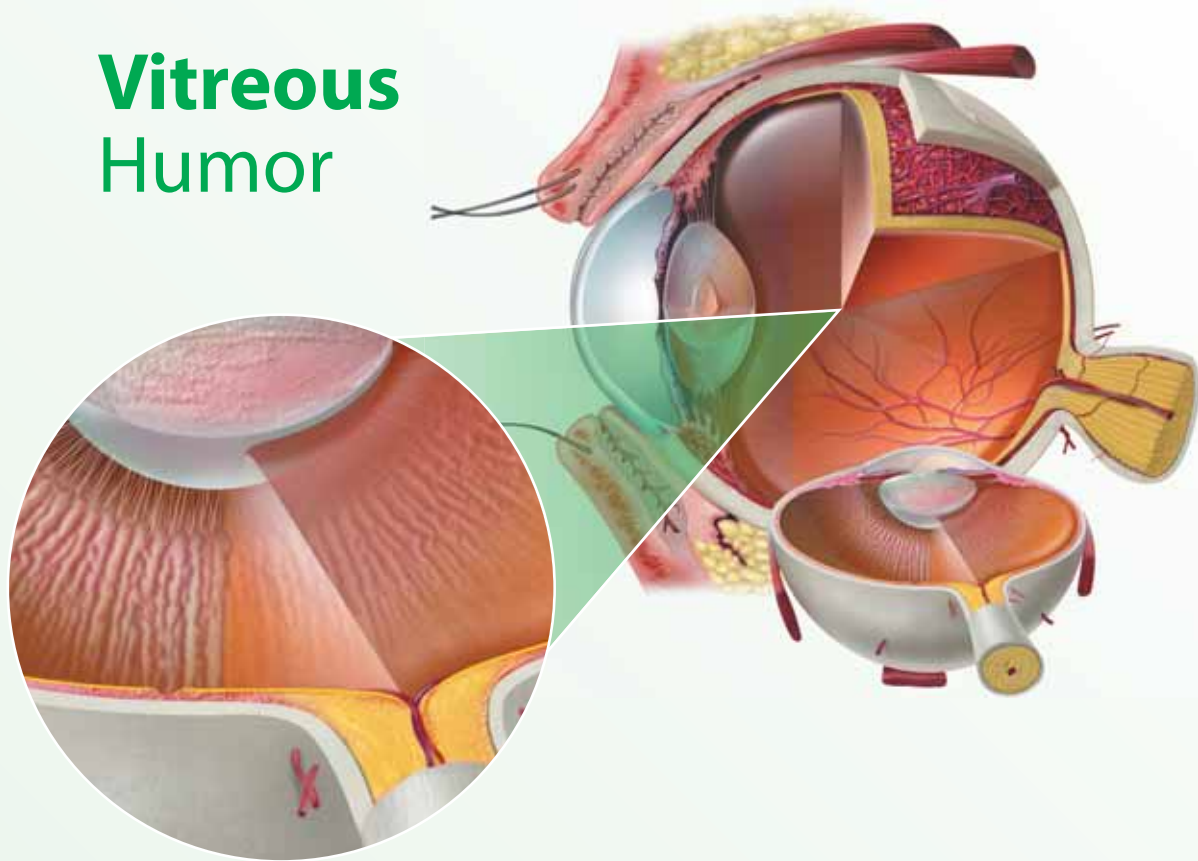
ᑯᑦᑲᑲᑲᑲᑲᑲ

Naliqqariigut

Hiutip Tuhaadjutaa

Vestibule

# Vitreous Humor



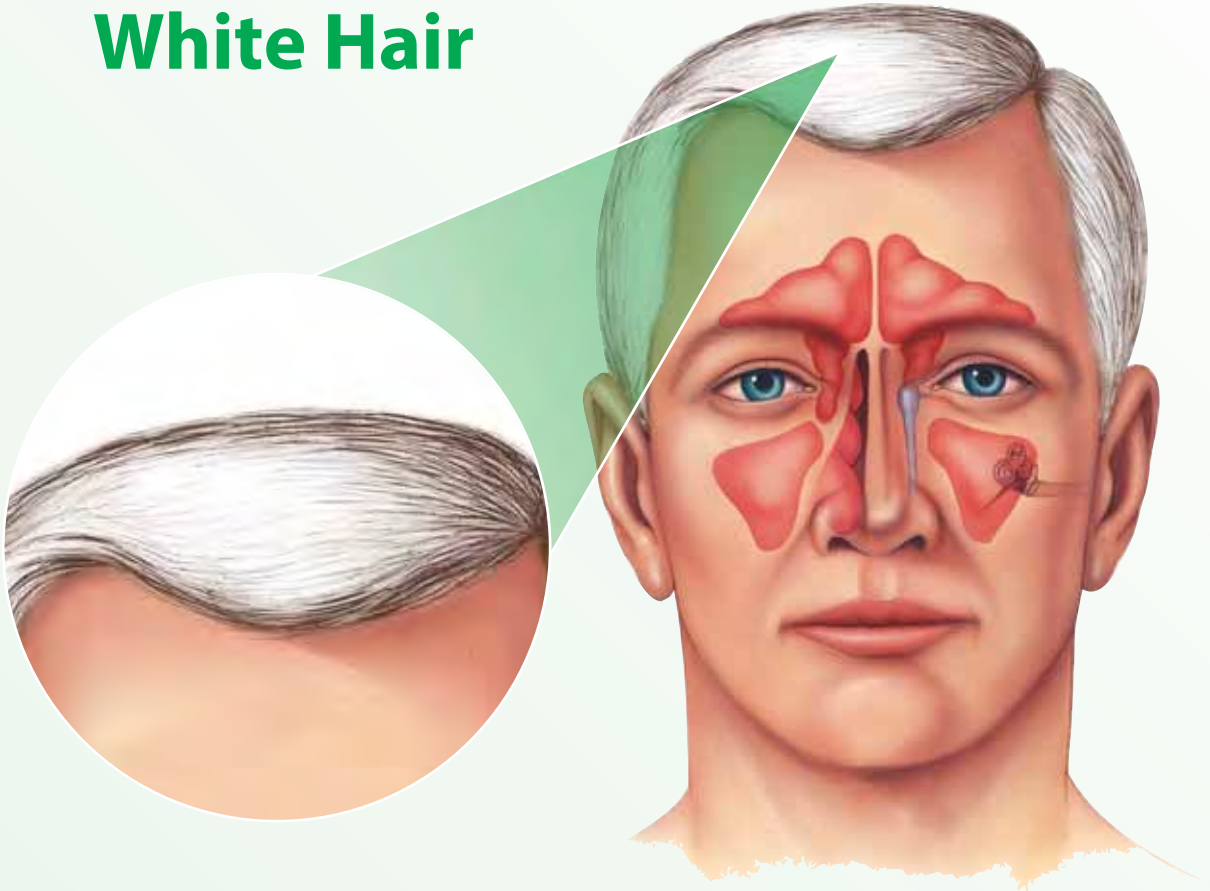ΔΡΔ< ΔL°J

Ijiup Imanga

Iyip Imaqutaa

Corps vitré

# White Hair



᠑ᠢᠢᠴ

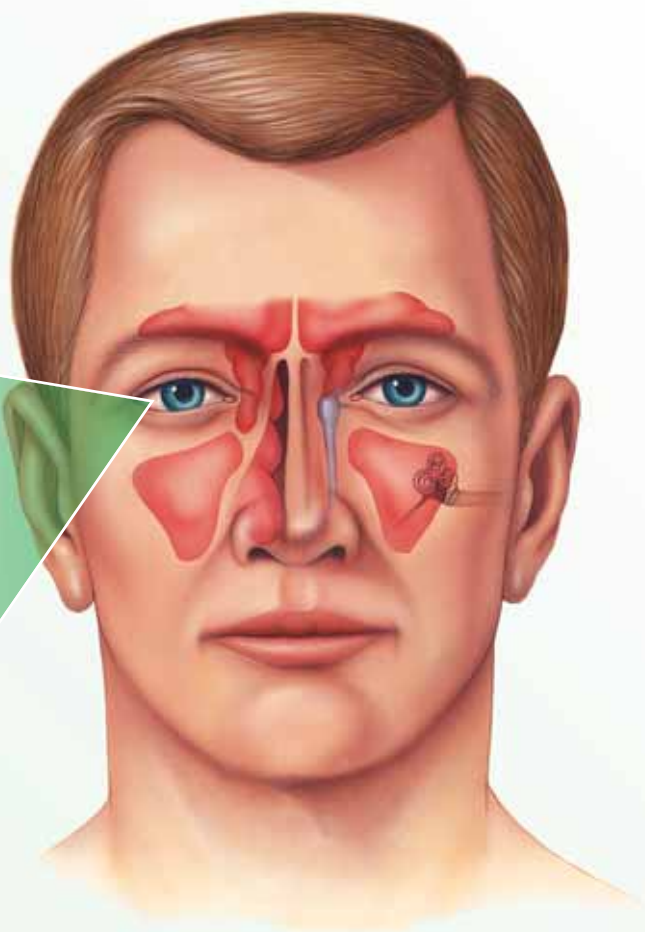
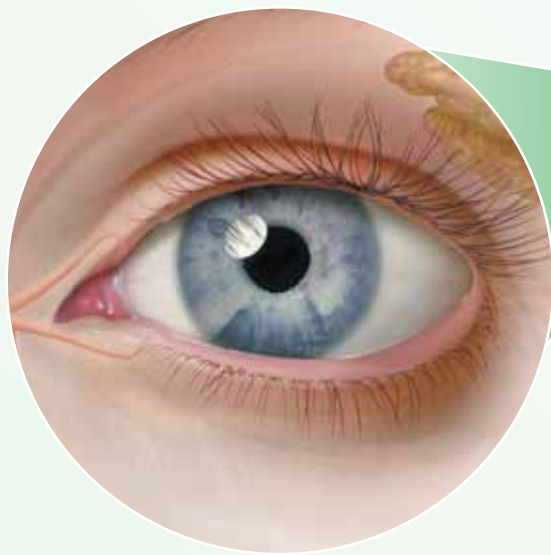
Qiiq

Qiiq

Cheveu blanc



# White of the Eye



ᑦᐃᐱᑦᑲᑦᑲ

Quviqsaq

Quviqhaq

Blanc de l'œil



# Muscles

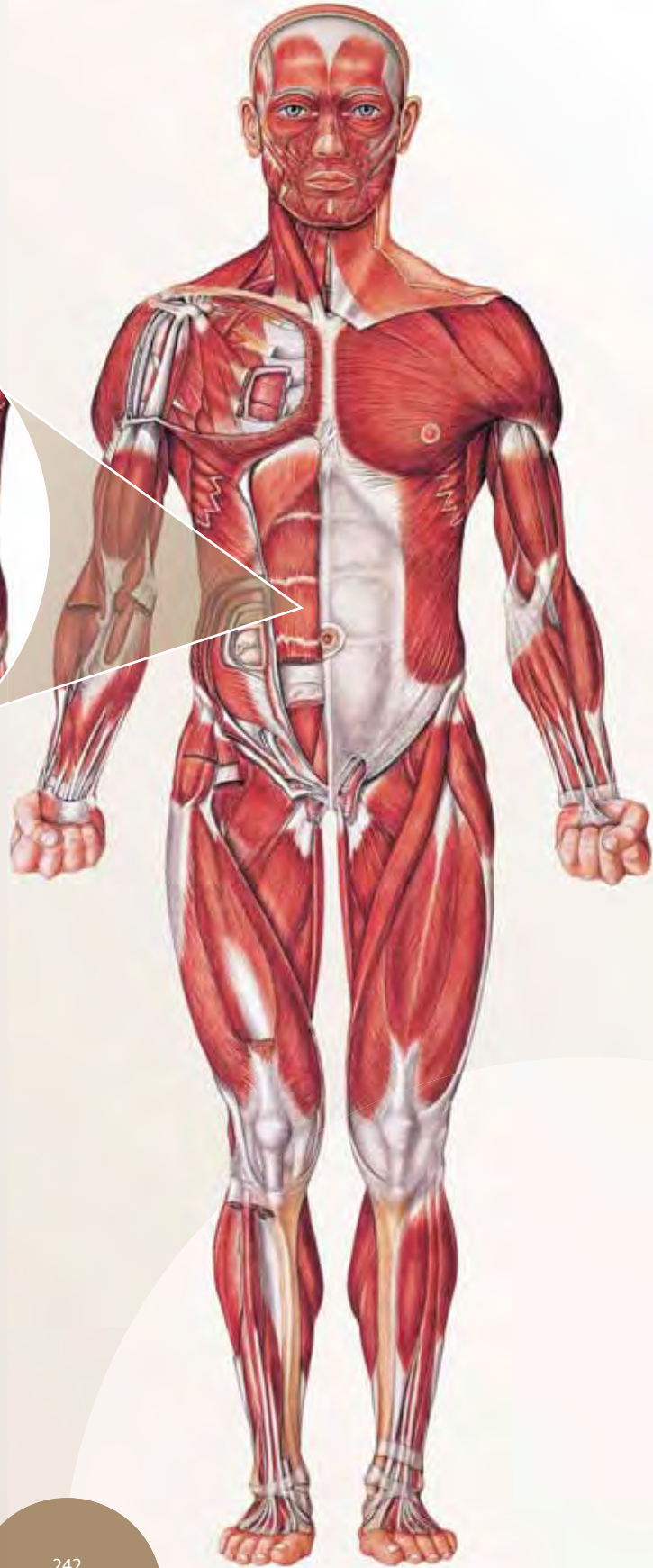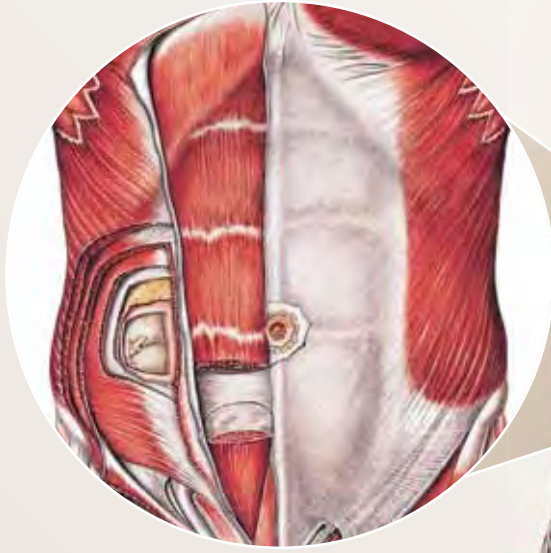
ᓃᓱᓴ

Nukiit

Nukik

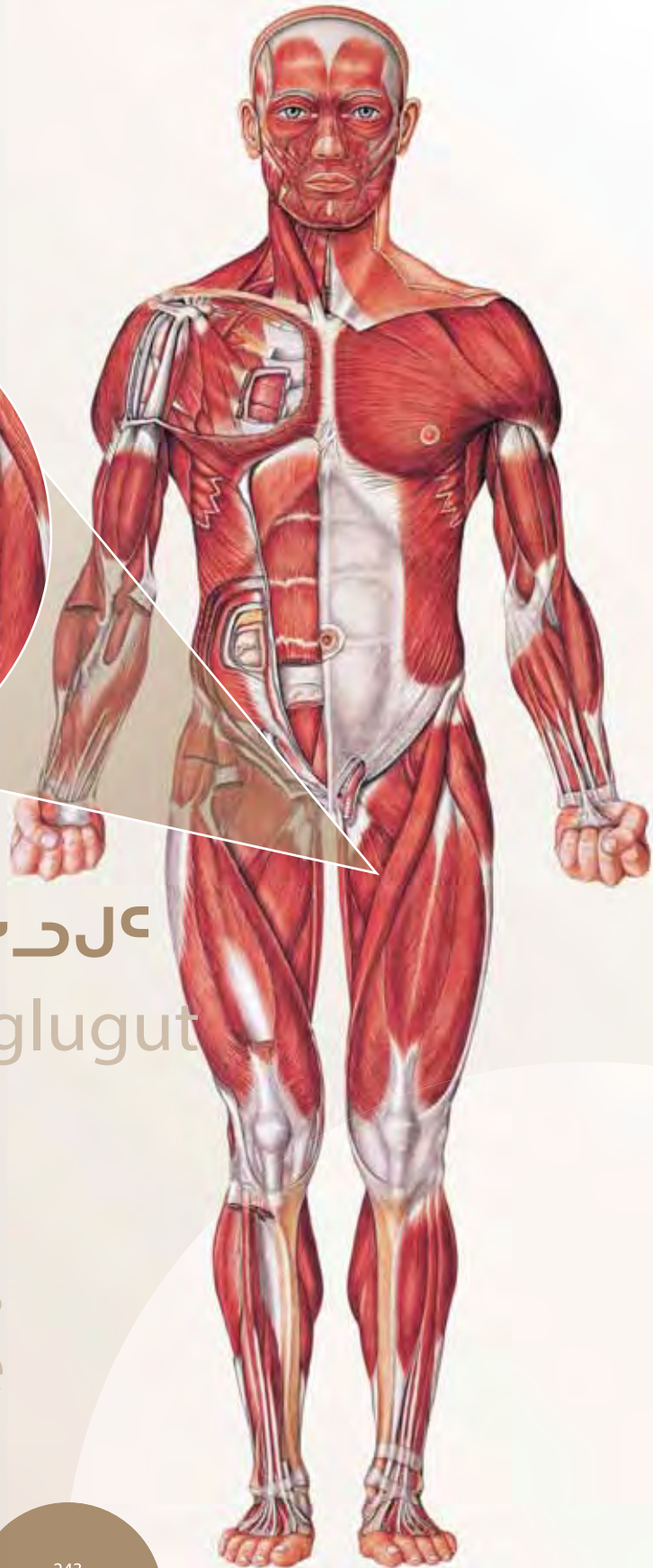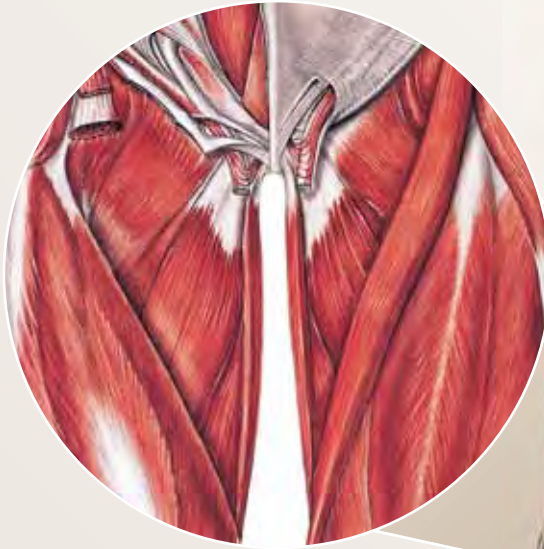
Muscles

# Abdominal Muscle



عكجذف  
Naarlugut  
Naarlugut  
Muscle  
abdominal

# Adductor Muscles of the Thigh

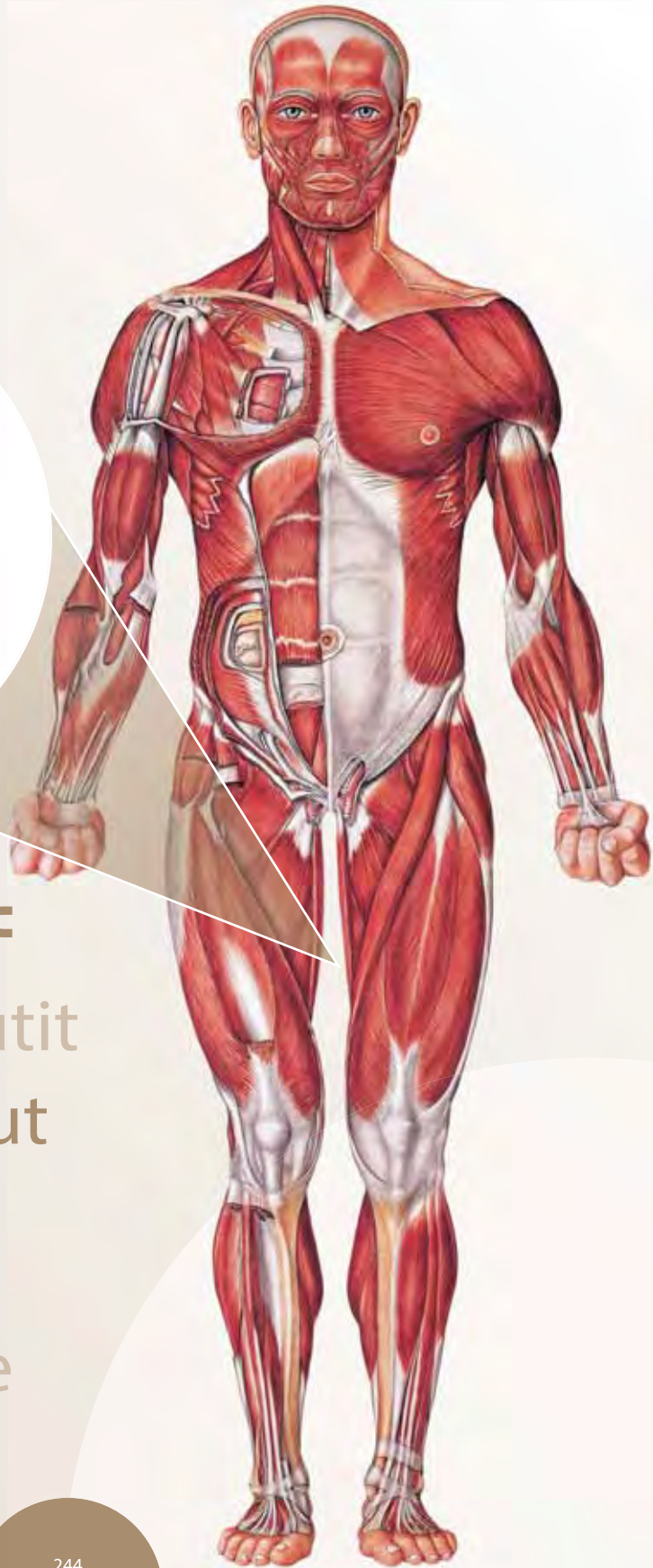
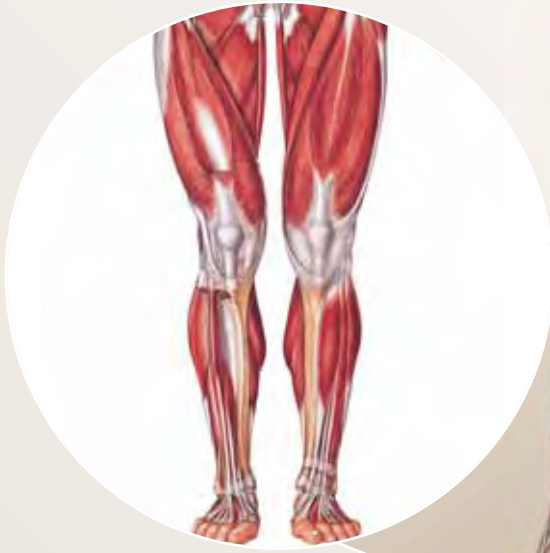
ᑎᑦᑎᑦ ᑎᑦᑎᑦ ᑎᑦᑎᑦ  
Nukik Ilutaglugut

Ilutak

Muscles  
adducteurs  
de la cuisse

# Anterior Muscles of the Leg



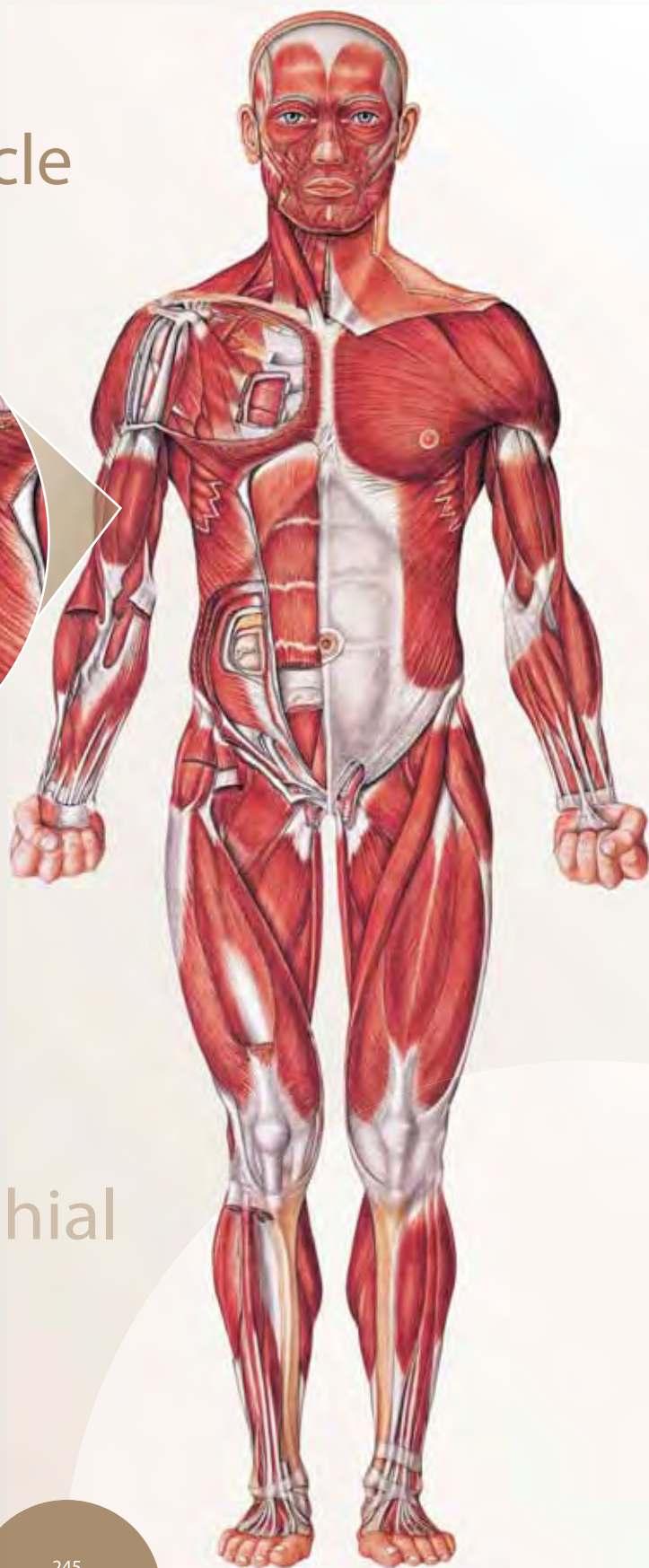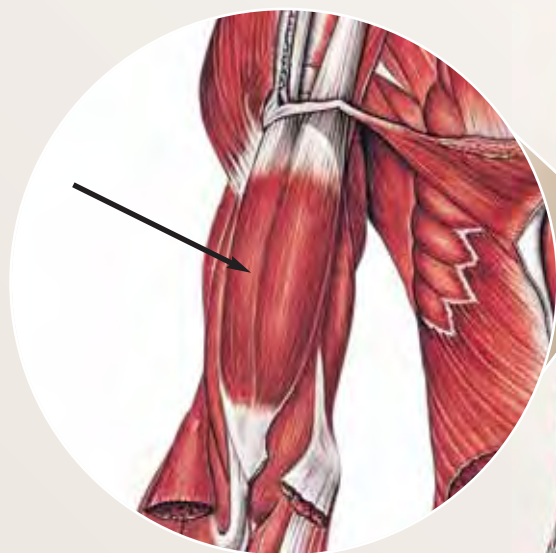
ᐱᐅᑦᑦᑦᑦᑦᑦᑦ

Sivurarlugutit

Hivurarlugut

Muscles  
antérieurs  
de la jambe

# Biceps Brachii Muscle



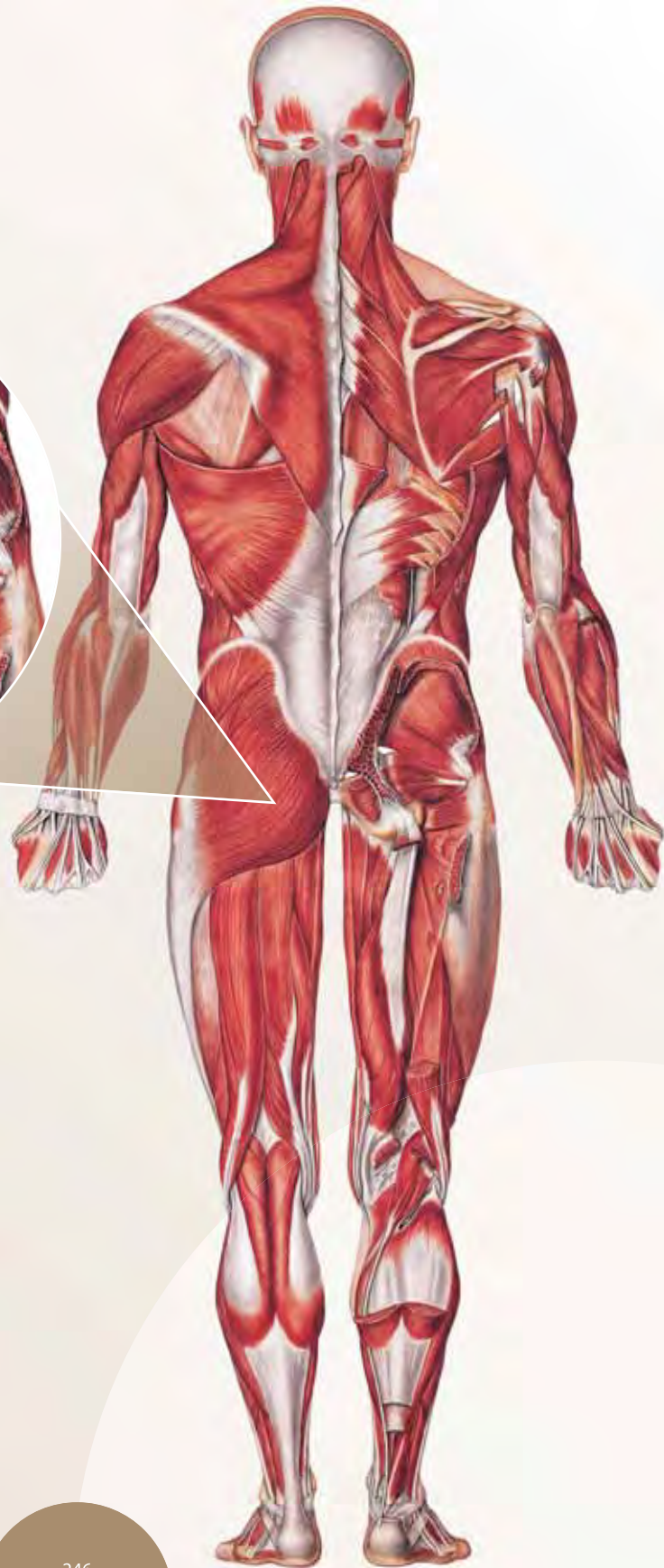
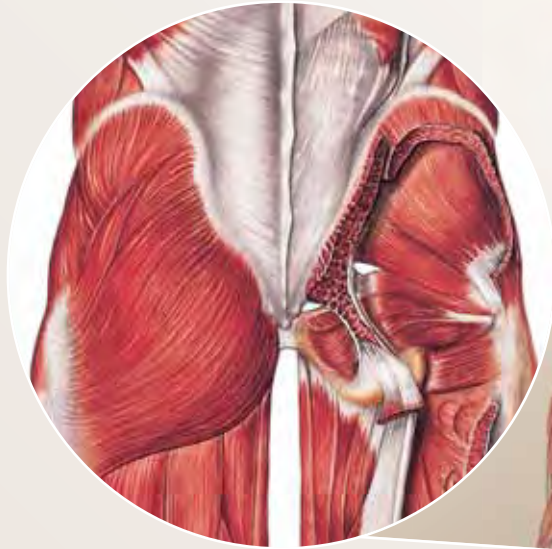
ᑲᑦᑦᑦᑦᑦᑦ

Kattuaq

Kattuaq

Biceps brachial

# Buttocks



▷ᐃᐅᐅᐅ

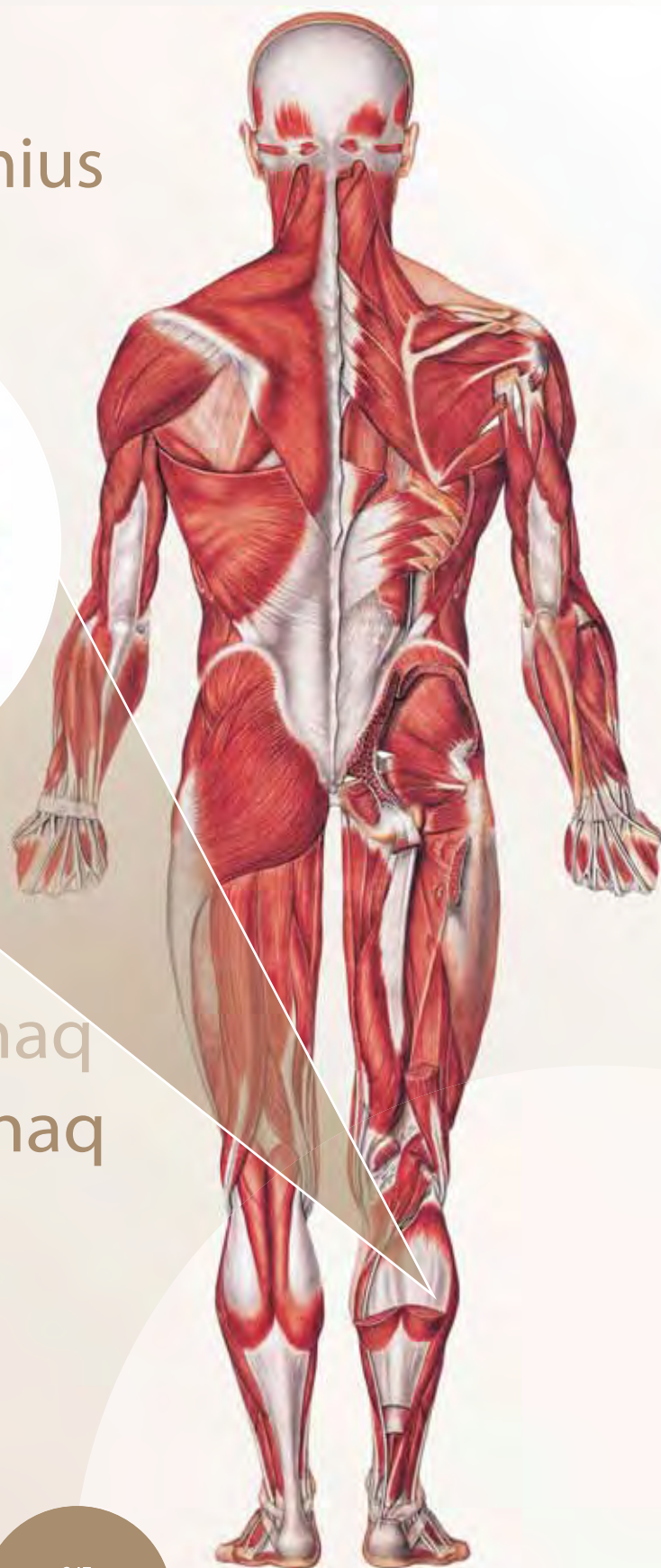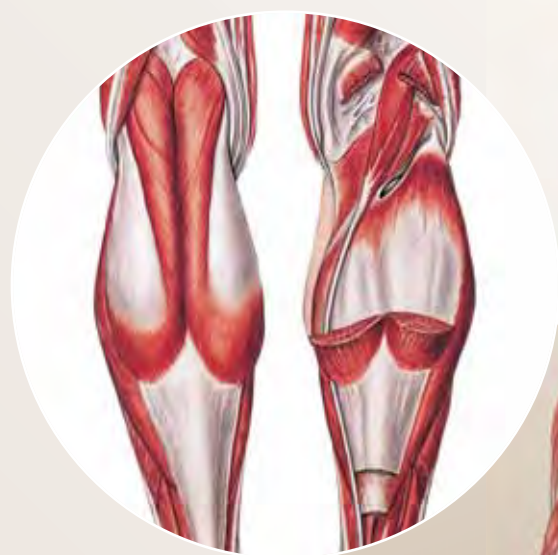Ukpatiik

Ukpatik

Fesses



# Calf / Gastrocnemius Muscle



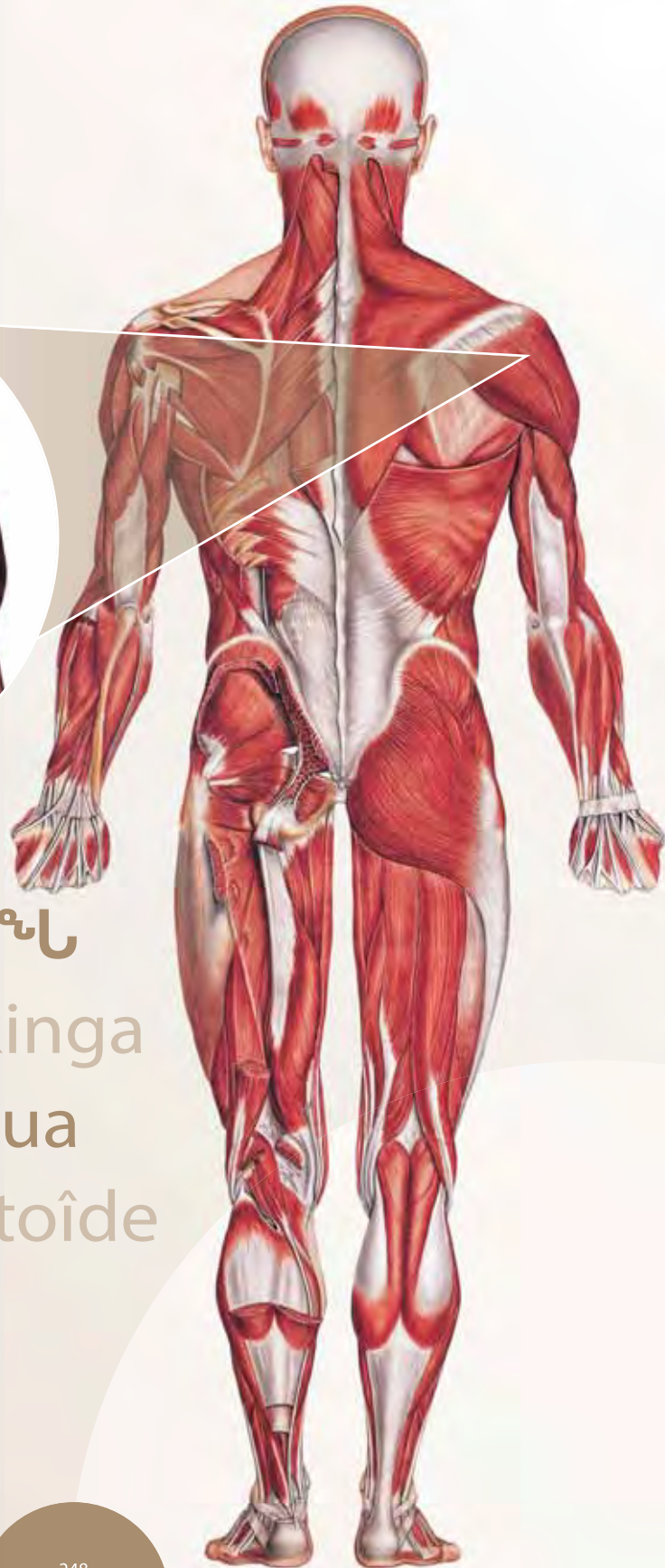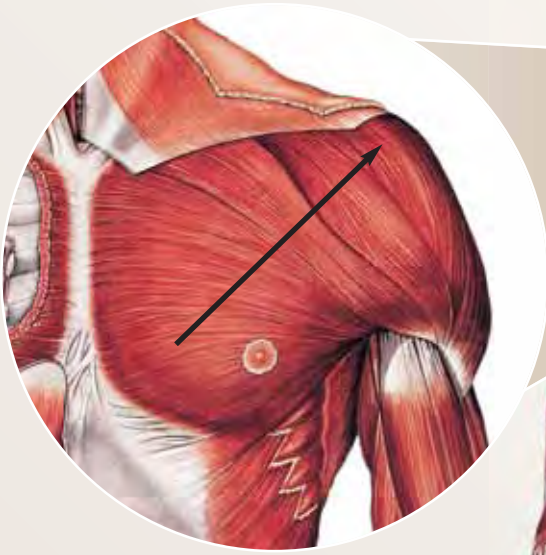
ᄒᄒᄒᄒᄒᄒ

Nakasungnaq

Nakahungnaq

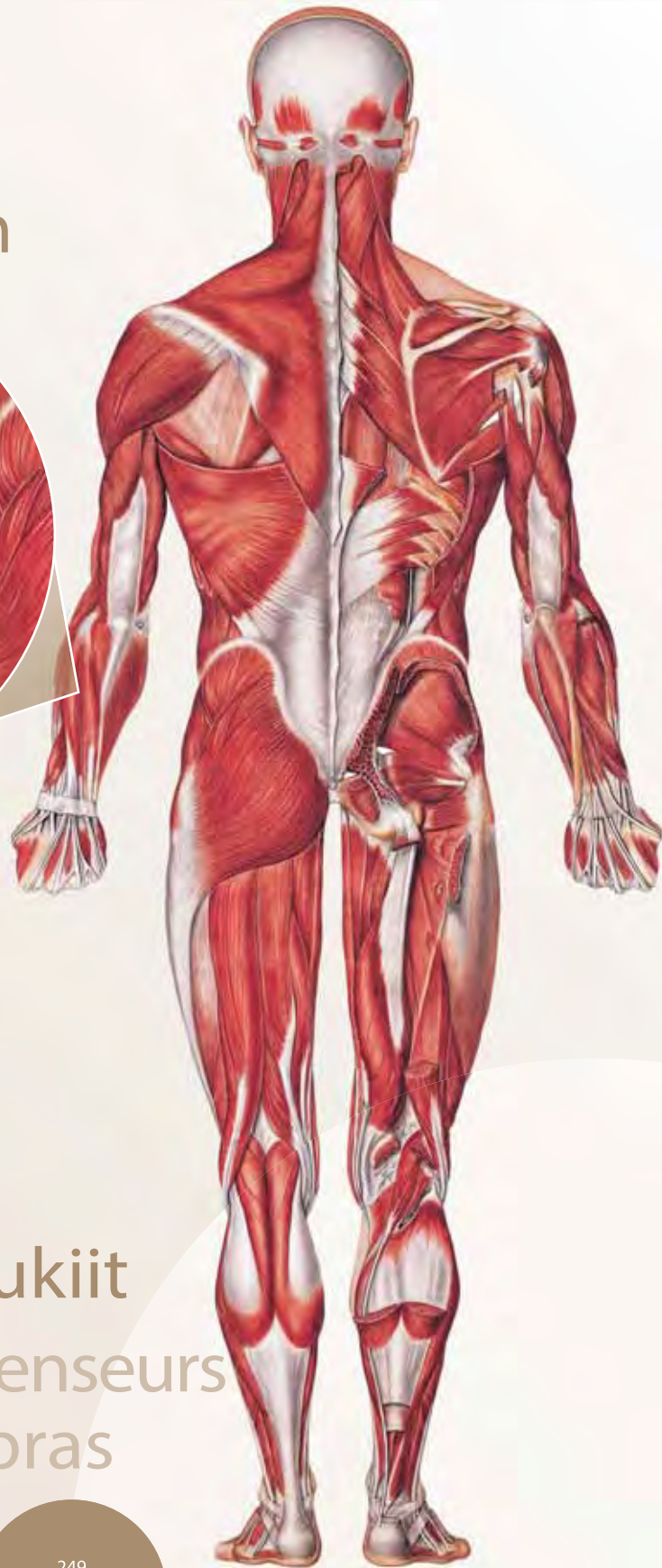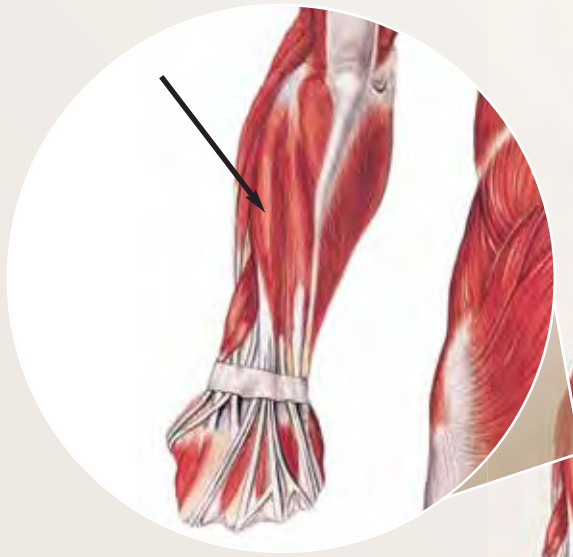
Mollet

# Deltoid Muscle



ՎնՎ՛ ԵՐ՞Ն  
Aariap Nukinga  
Tuigup Ivalua  
Muscle deltoïde

# Extensor Muscles of the Forearm



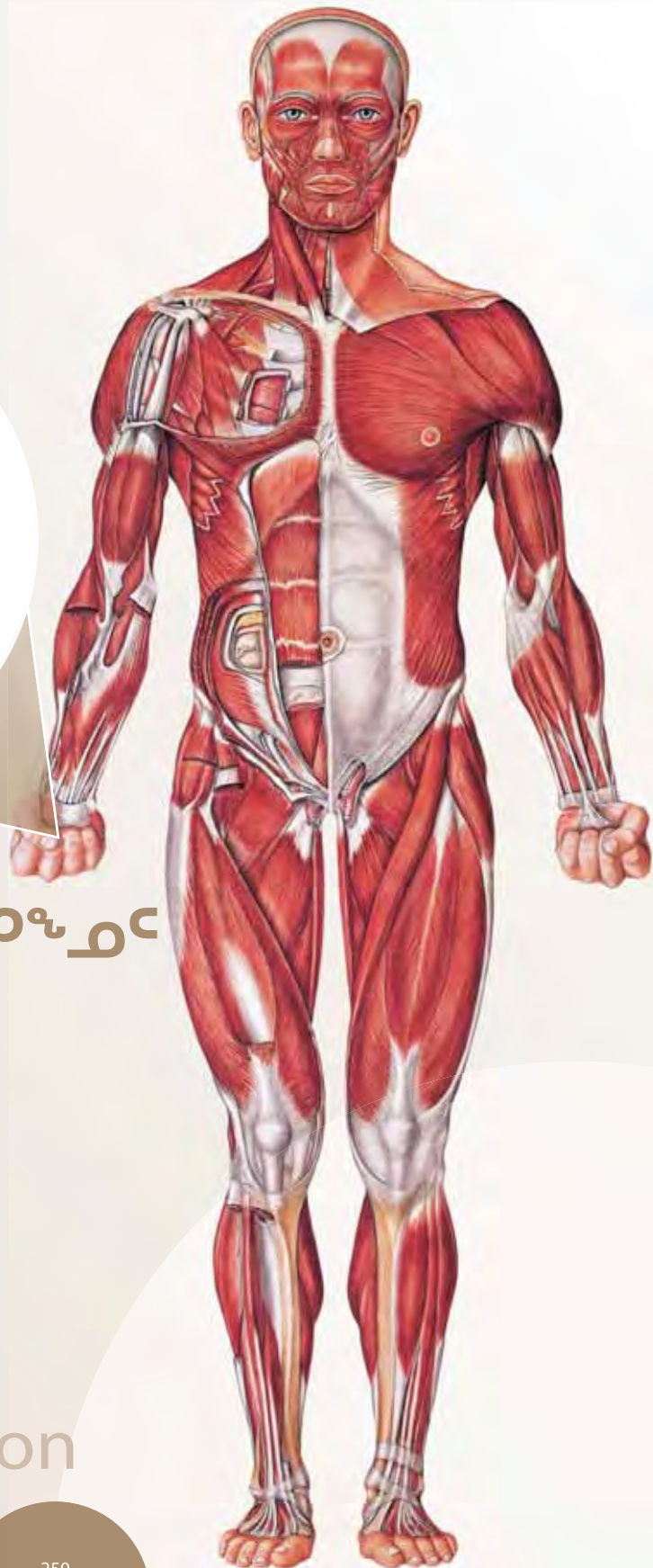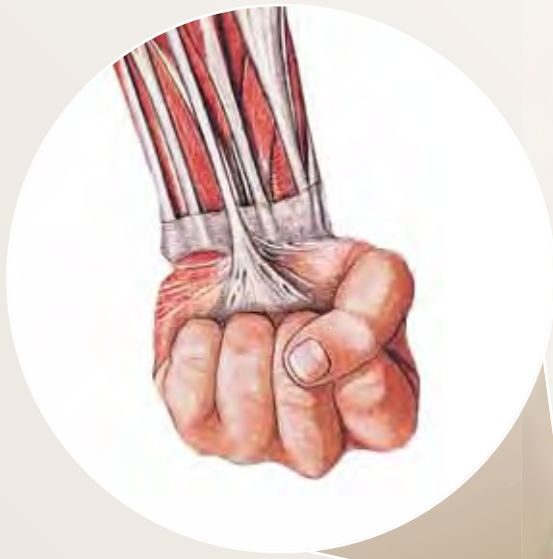ᐱᓐᓐᓐᓐᓐᓐ  
ᓐᓐᓐᓐᓐᓐ

Aggautiup  
Nukingit

Algautip Nukiit

Muscles extenseurs  
de l'avant-bras

# Flexion/s

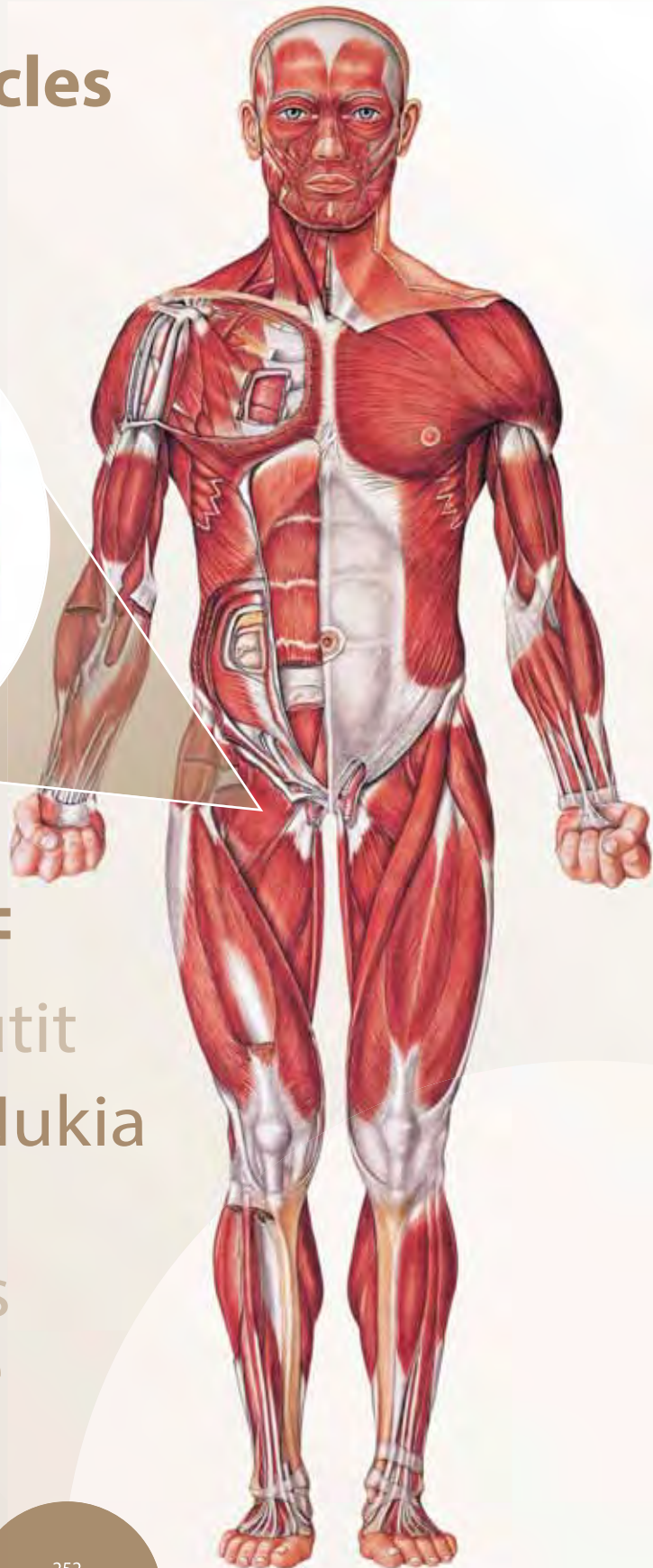
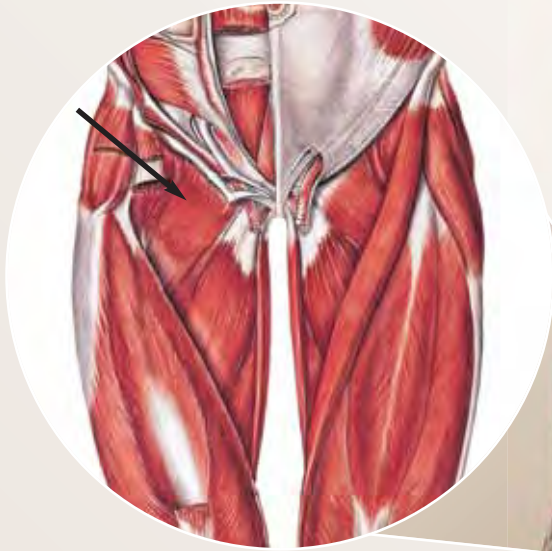
በገርጊና ምዕድር  
ልዩዎችና ማህሪ

Timlimaaq  
nukingnut  
iqijarninga  
Iqimmirutit  
Pli du menton



# Flexor Muscles of the Thigh



ᐱᐅᐅᐅᐅᐅᐅᐅᐅ

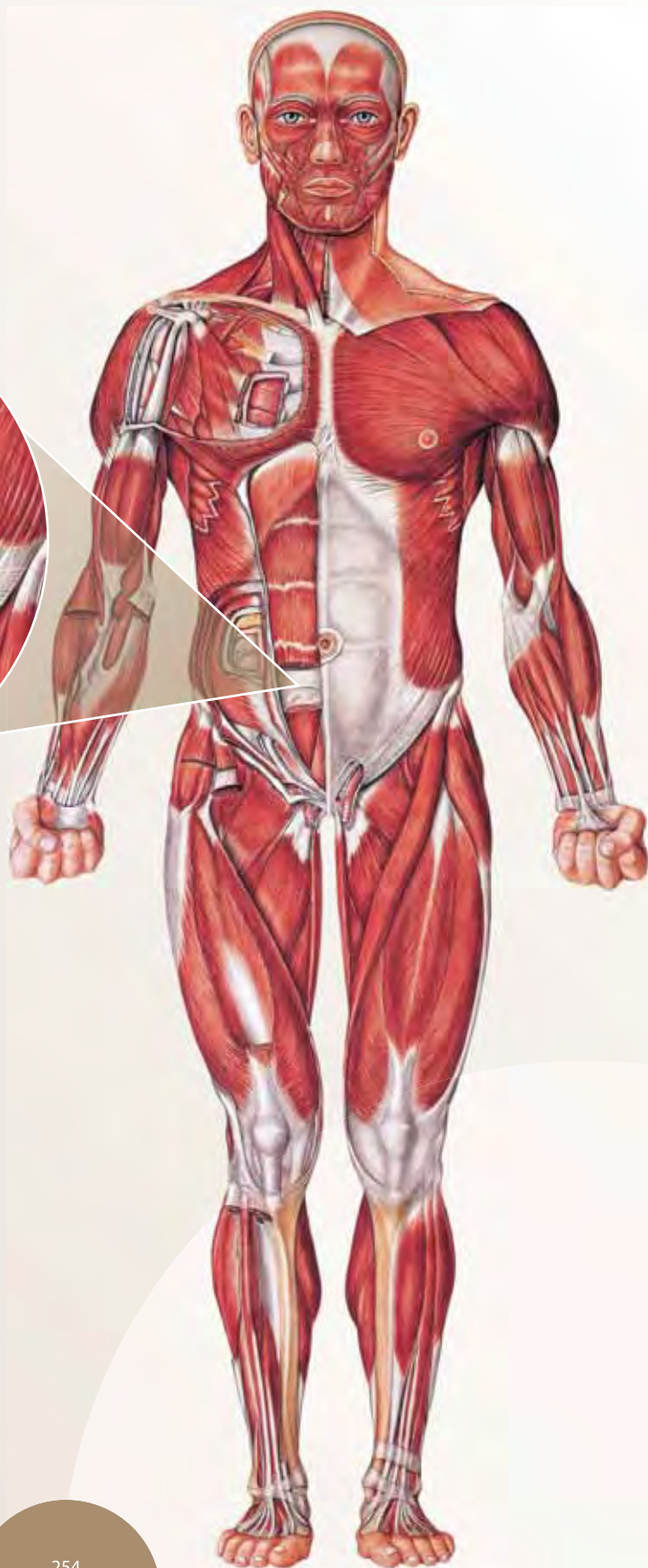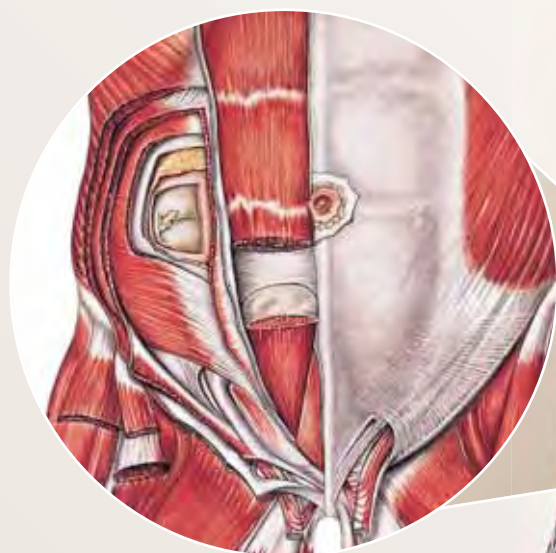Sivurarlugutit

Taqtunap Nukia

Muscles  
fléchisseurs  
de la cuisse



# Hernia



ԳՆՈՆ

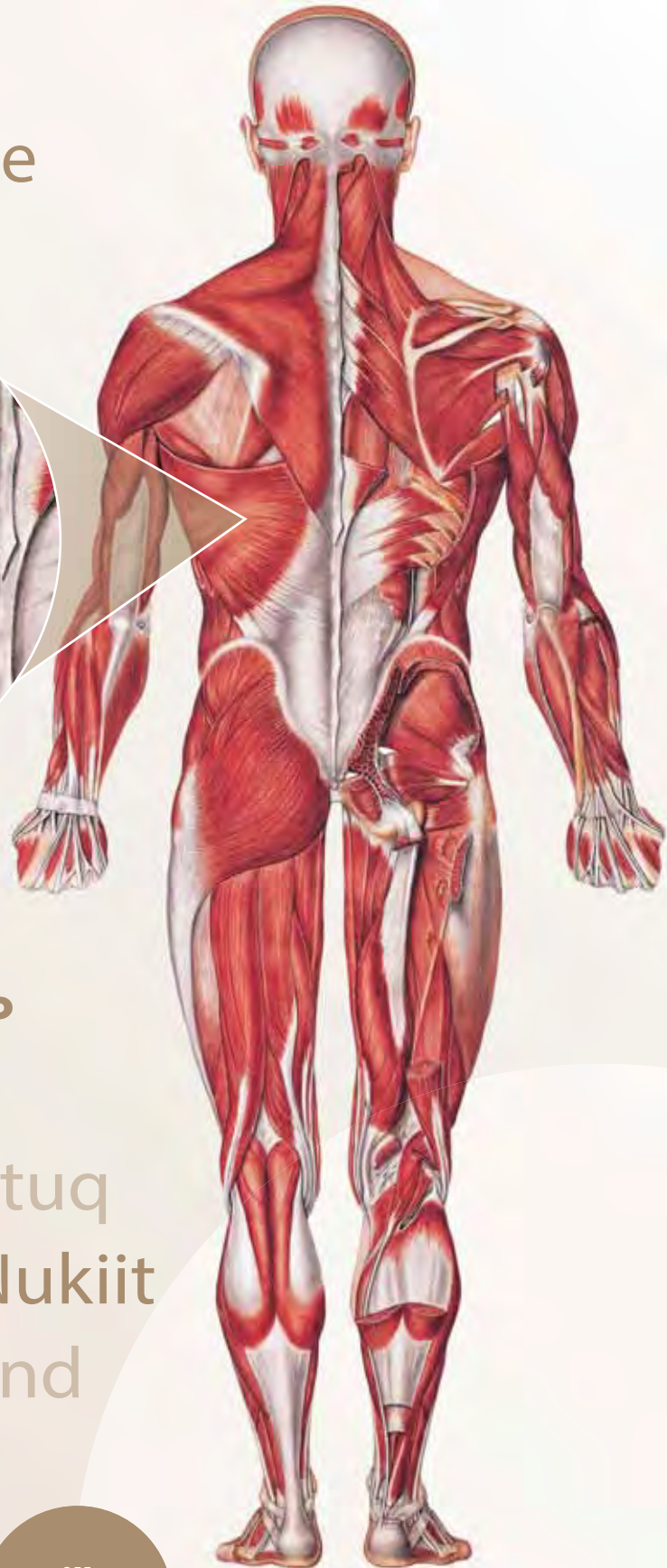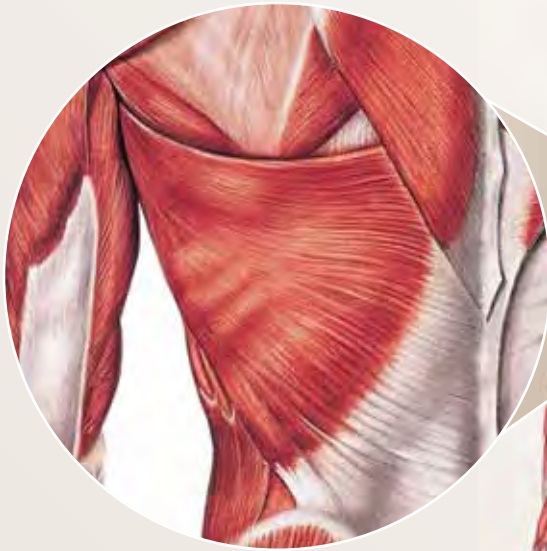
Qatik

Aniniq

Hernie



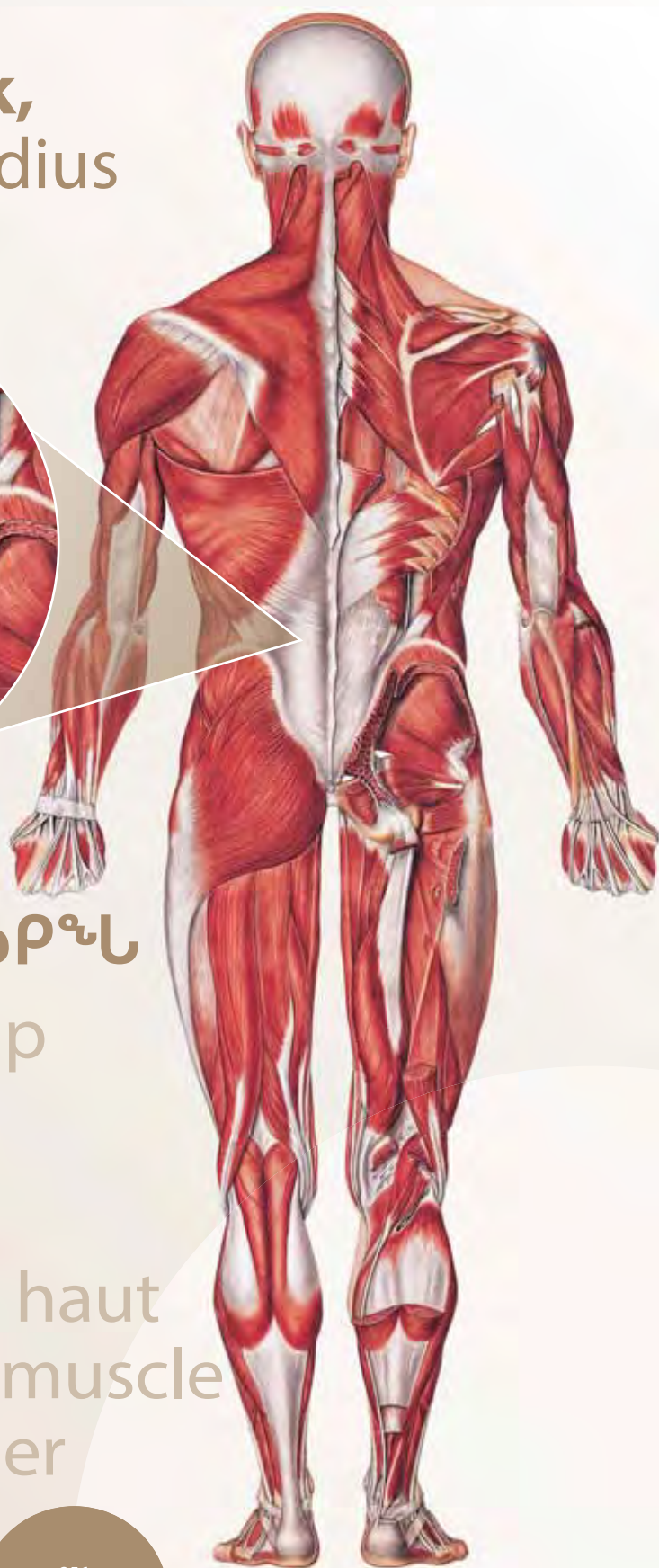
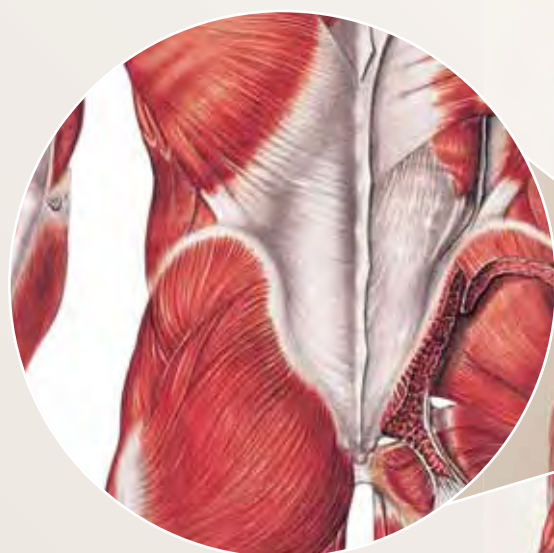
# Latissimus Dorsi Muscle



ᓄᓯᓴ  
ᓴᓂᓴᓴᓴᓴᓴᓴᓴᓴ

Nukik  
Sanirarmiittuq  
Haniraup Nukiit  
Muscle grand  
dorsal

# Lower Back, Gluteus Medius Muscle



ԺԿՈ՞ՆՆՅ՝ ՄԲ՞ՆԼ

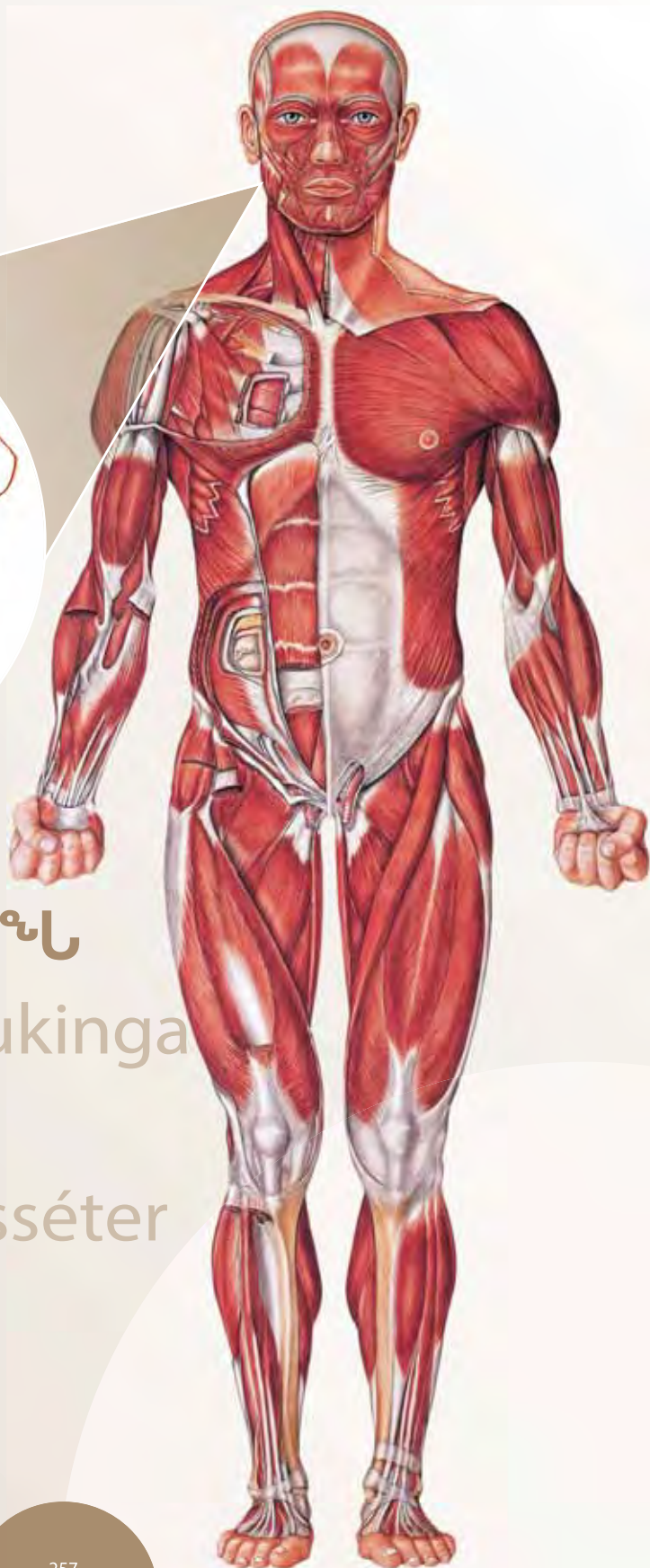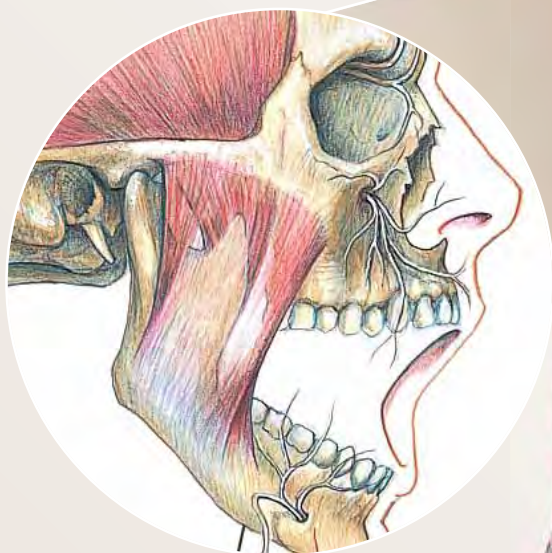Kuuttinnaap

Nukinga

Kuuttiniq

Bas du dos, haut  
de la fesse, muscle  
moyenfessier

# Masseter Muscle



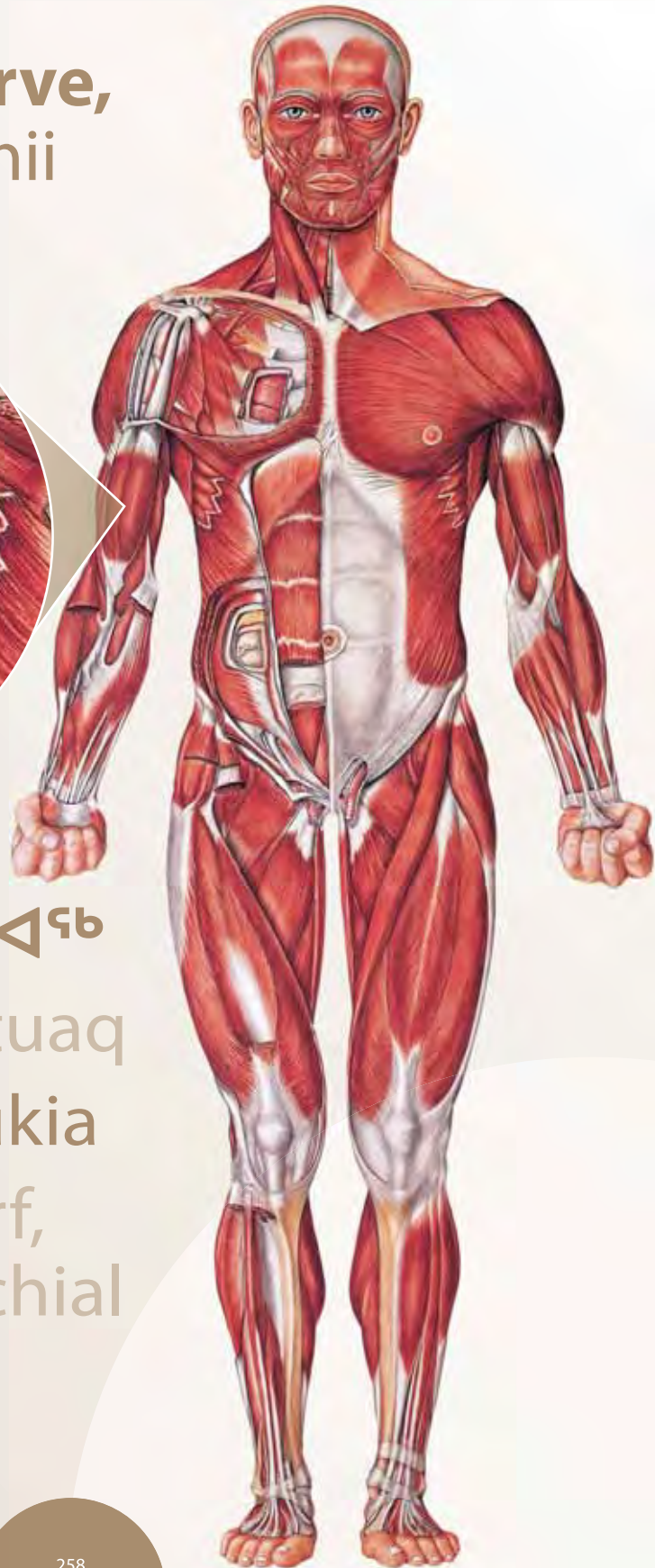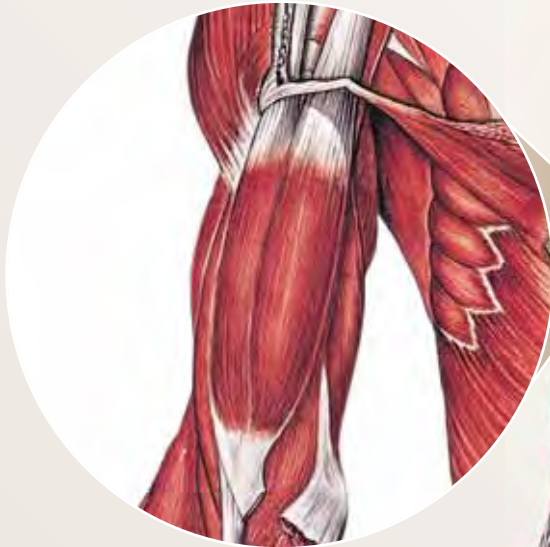ᐱᓕᓕᓂᓂ ᓄᓂᓂᓂ

Agli ruup Nukinga

Tuttak

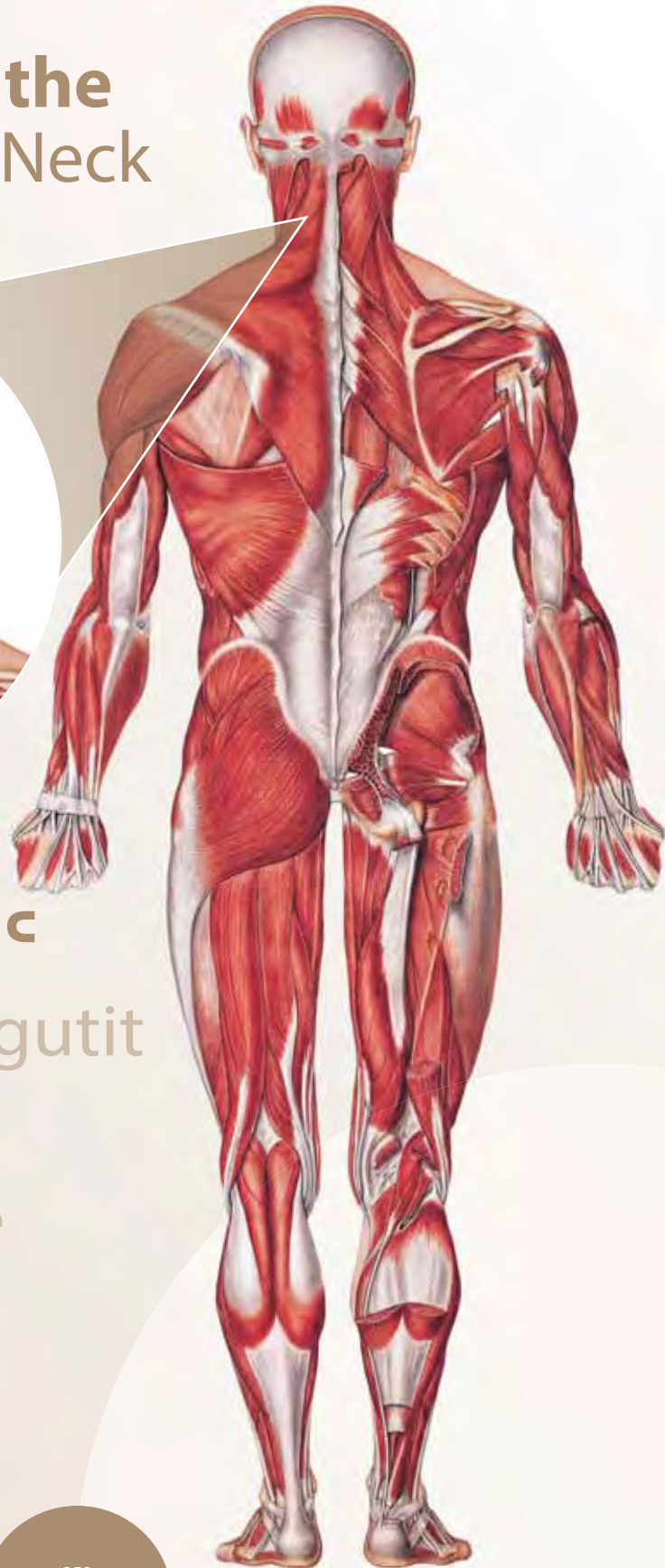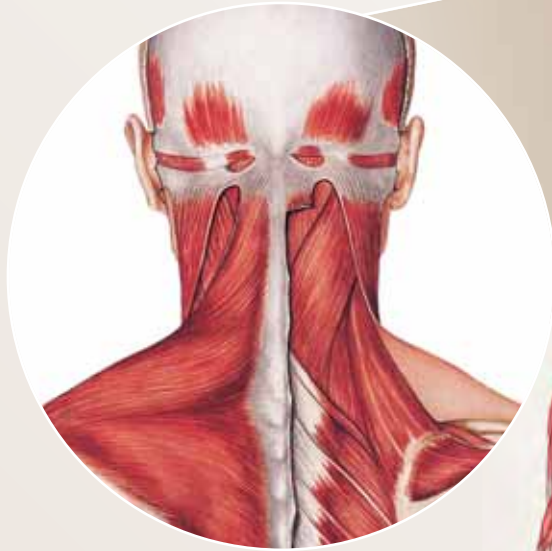Muscle masséter

# Muscle, Nerve, Biceps Brachii Muscle



ᑕᑕᑦᑏ ᑲᑕᑕᑕᑕᑕᑕ<sup>ᑕᑕ</sup>  
Talirmi Kattuaq  
Kattaup Nukia  
Muscle, nerf,  
biceps brachial

# Muscles of the Back of the Neck



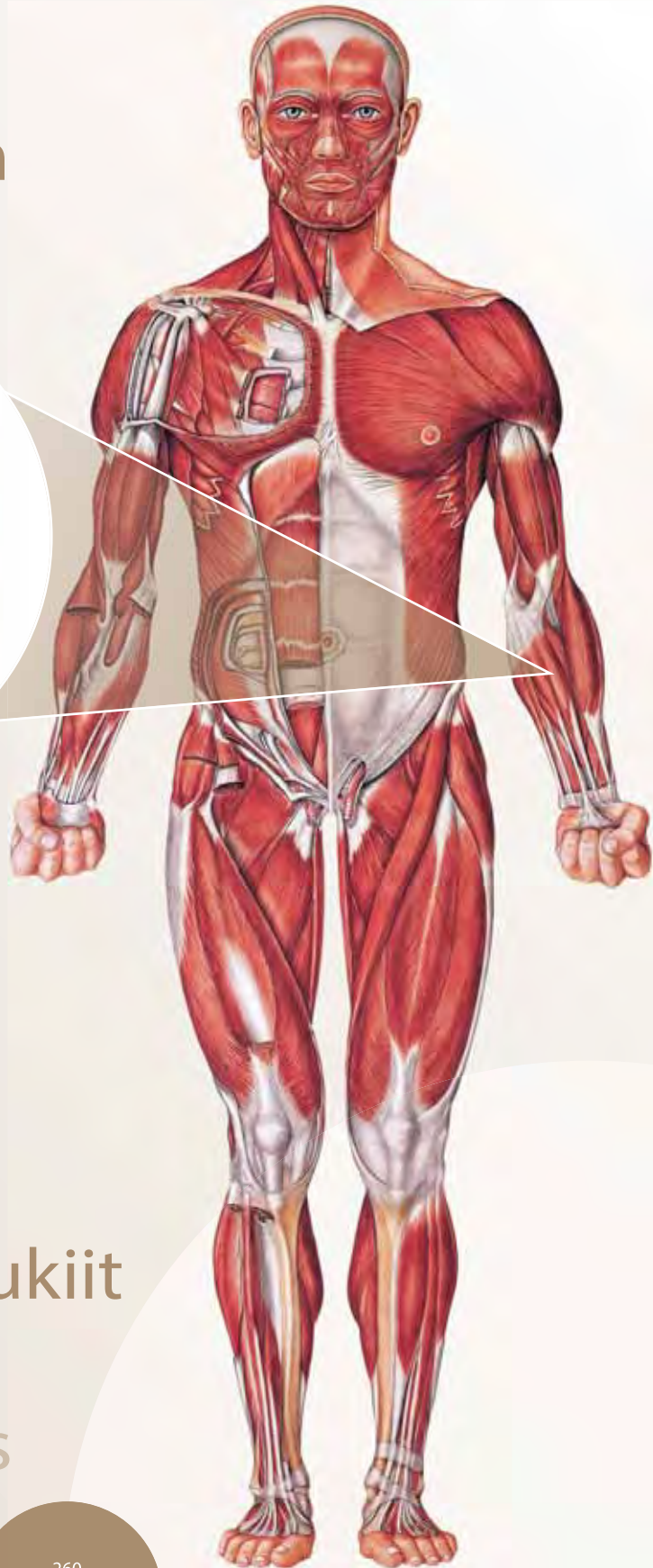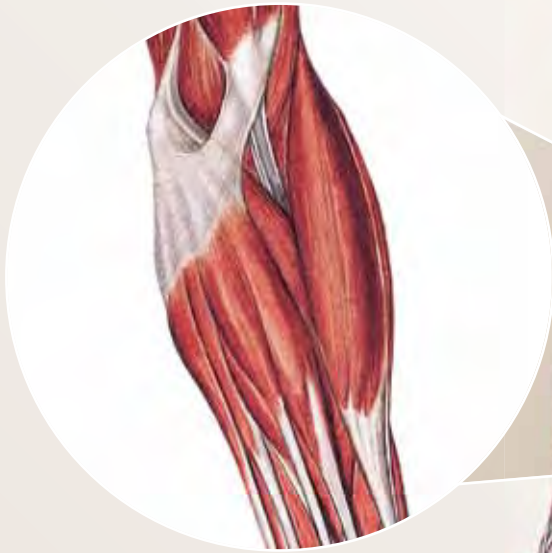תנוסוגלוגוטי

Tunusuglugutit

Aarlugut

Muscles de  
la nuque

# Muscles of the Forearm



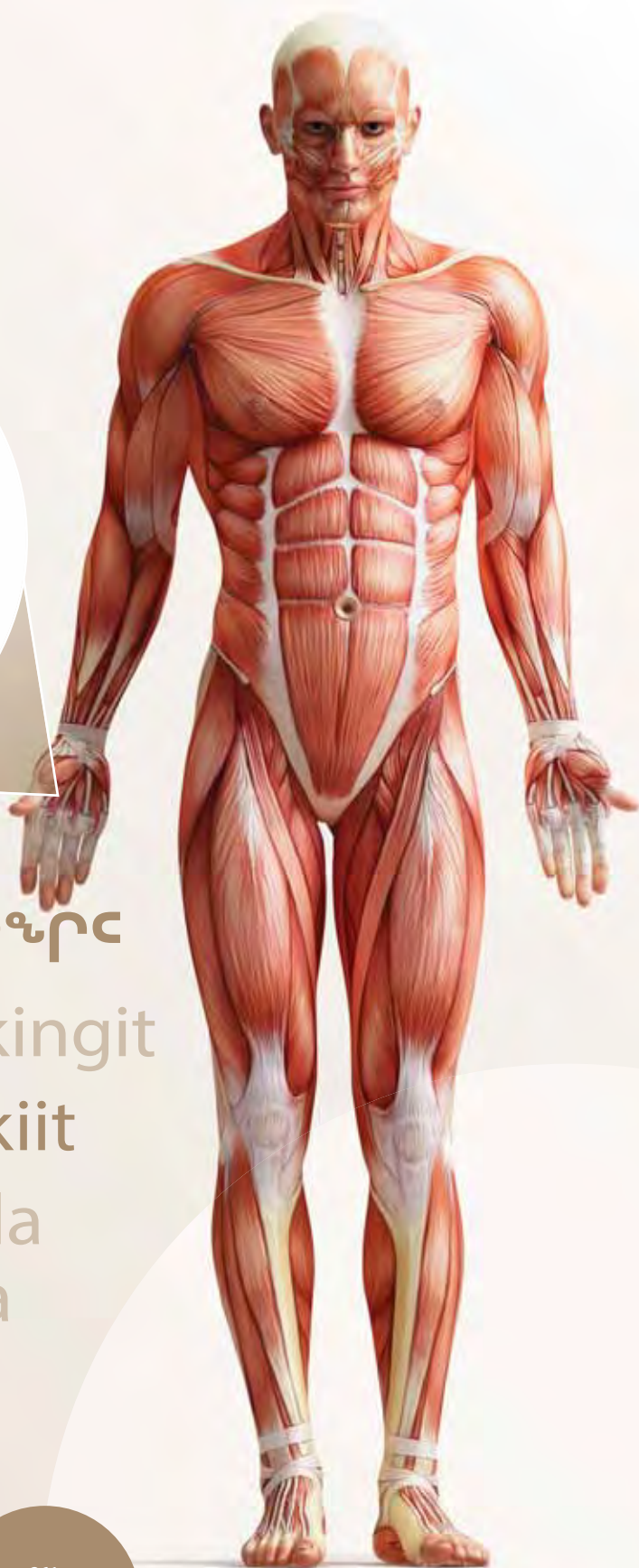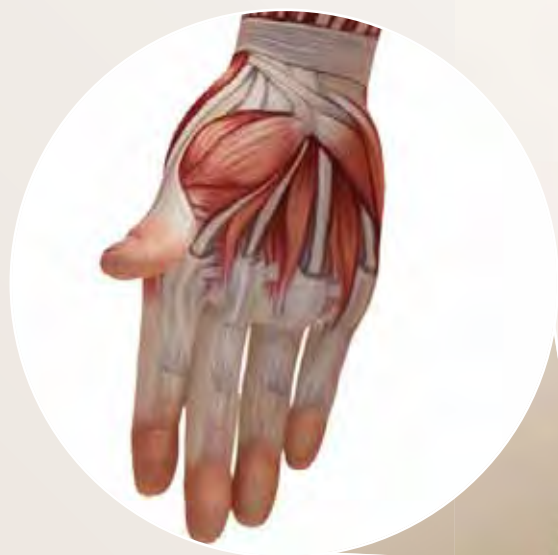ᐱᓕᓕᐱᓐᓂᐱᓐ  
ᐱᓕᓕᐱᓐᓂᐱᓐ

Aggautiup  
Nukingit

Tayarnip Nukiit

Muscles de  
l'avant-bras

# Muscles of the Palm



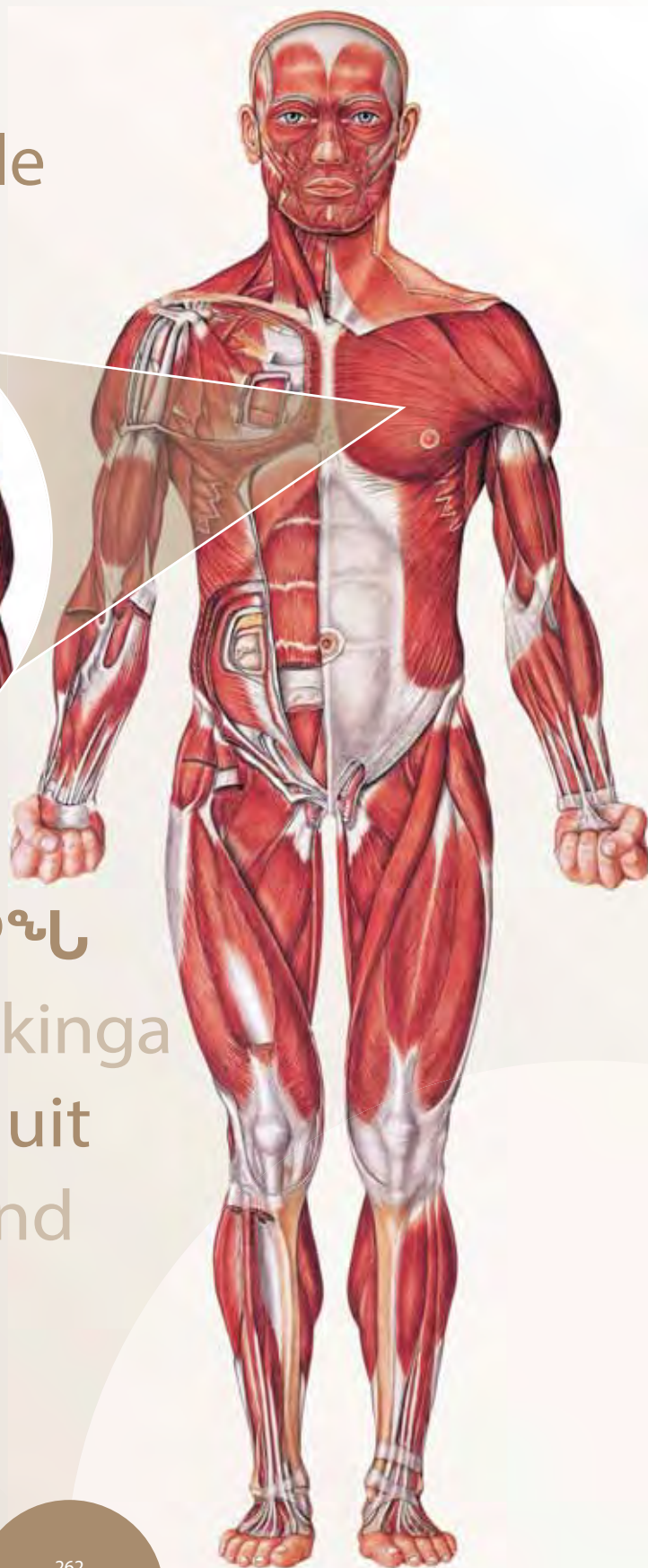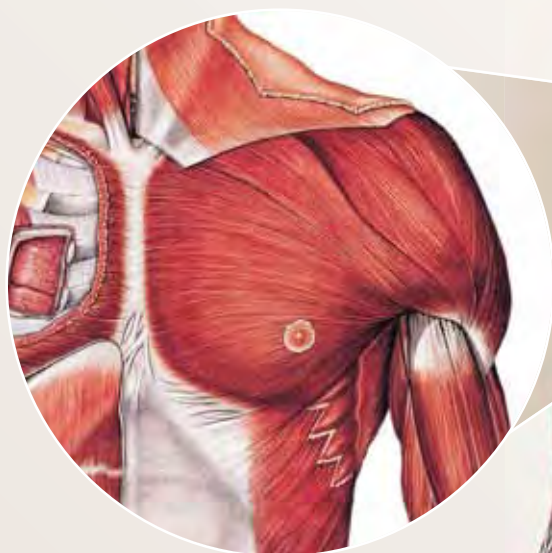
ΔΟΛΔ< ρρ<ρ<

Itimaup Nukingit

Itimaup Nukiit

Muscles de la  
paume de la  
main

# Pectoralis Major Muscle



ԿՆՆԱԾՅ՝ ԵՐՆՆ

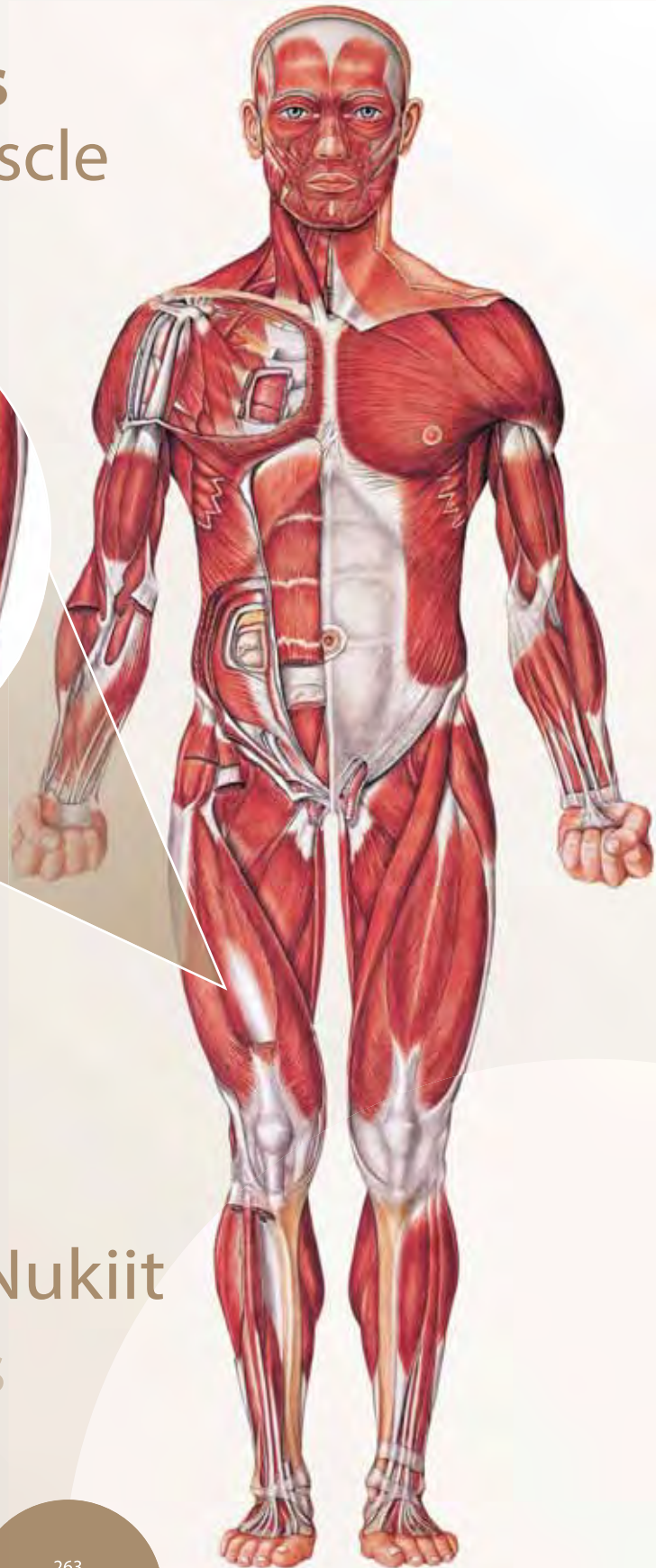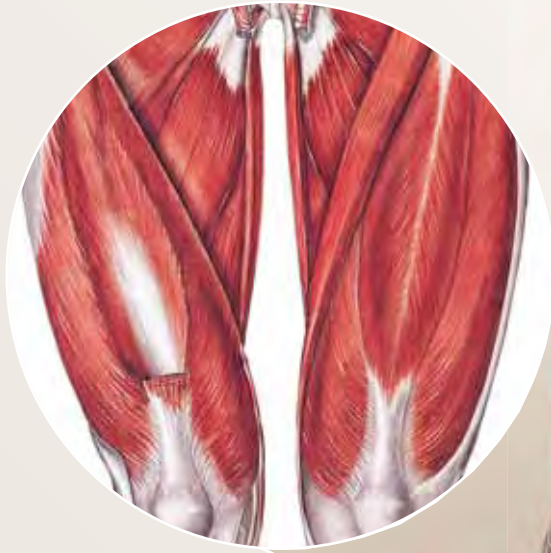Sagviup Nukinga

Hatqap Ivaluit

Muscle grand  
pectoral



# Quadriceps Femoris Muscle

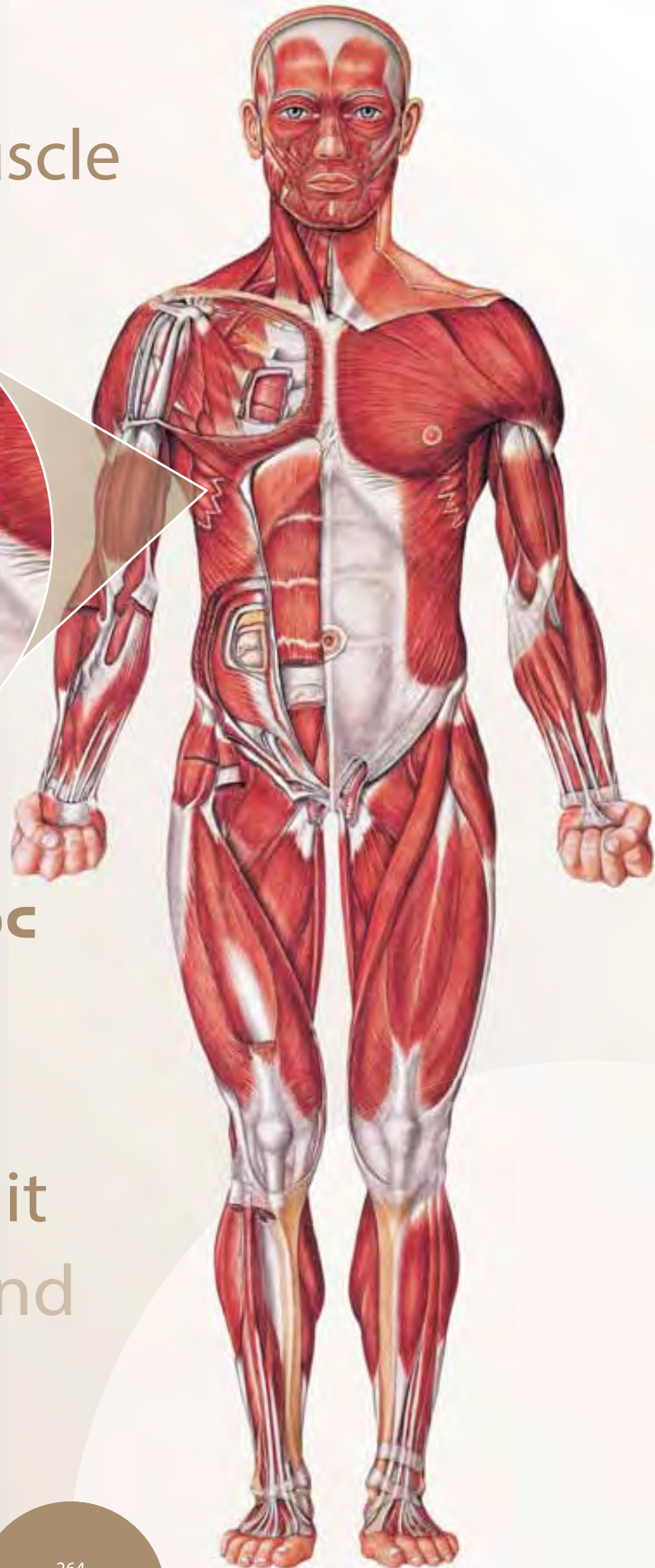
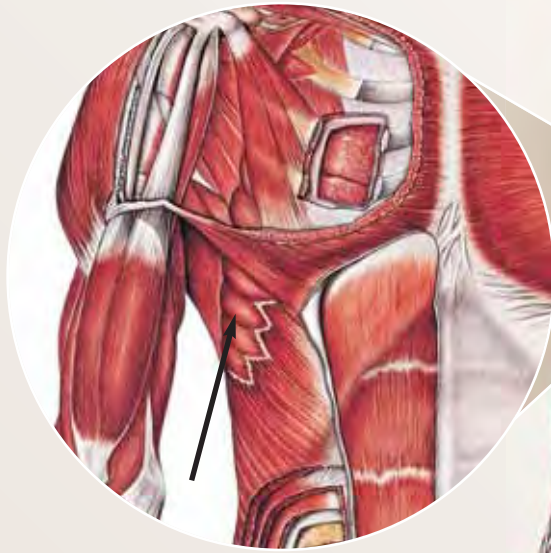
ᐱᐱᐱᐱᐱᐱᐱᐱ  
ᐱᐱᐱᐱᐱᐱᐱᐱ

Qukturaup  
Nukingit

Hivuqqap Nukiit  
Quadriceps  
fémoral

# Serratus Anterior Muscle

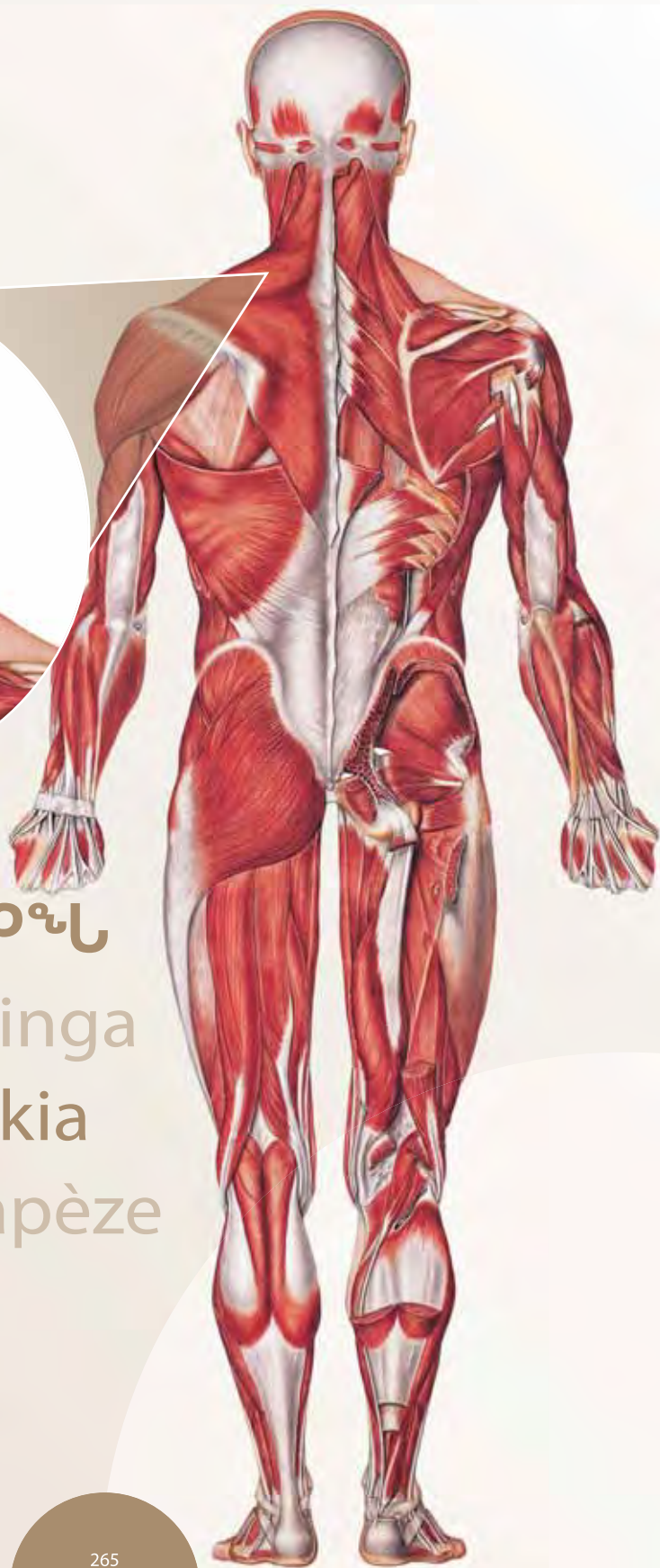
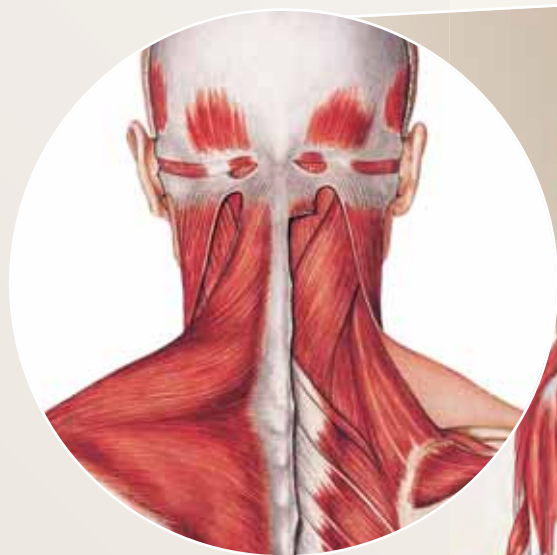
ካሪሳሪ ስታር

Sanirarmi  
Nukiit

Uniup Nukiit  
Muscle grand  
dentelé

# Trapezius Muscle



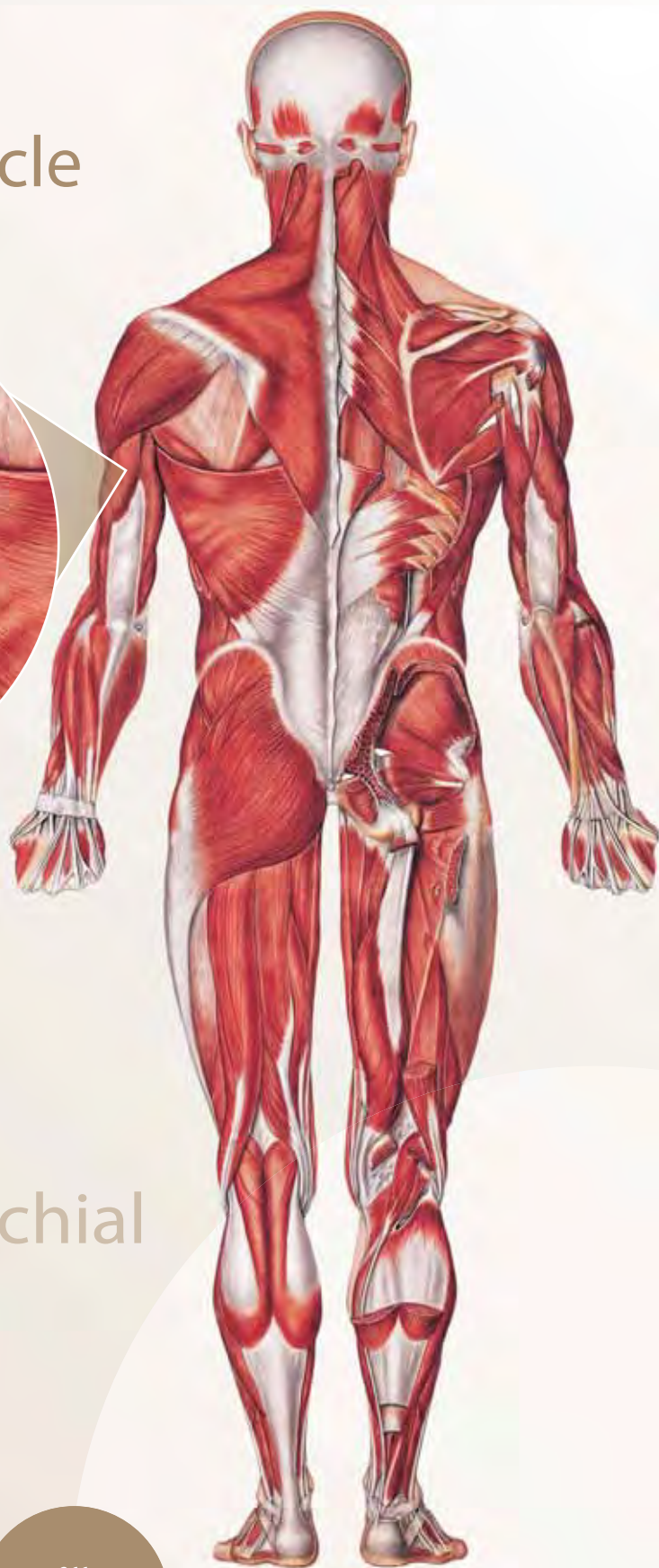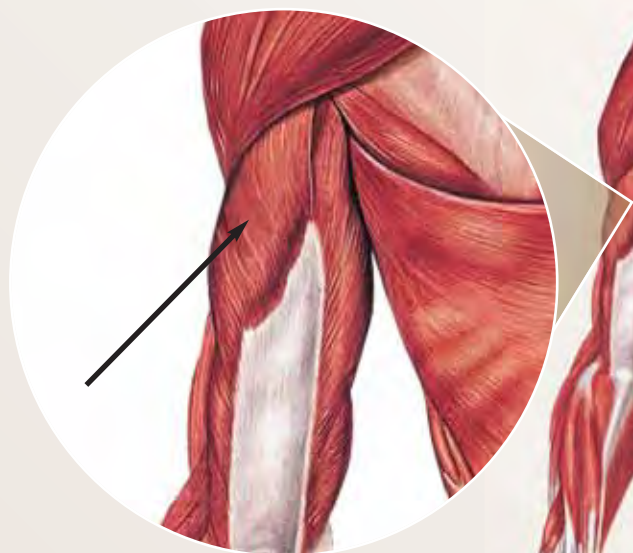
ՎնՎ՛ ԵՐ՞Ն

Ariap Nukinga

Aariap Nukia

Muscle trapèze

# Triceps Brachii Muscle



ᠪᠴᠳᠠᠭᠪ

Kattuaq

Kattuaq

Triceps brachial

# Organs/Digestive/ Brain

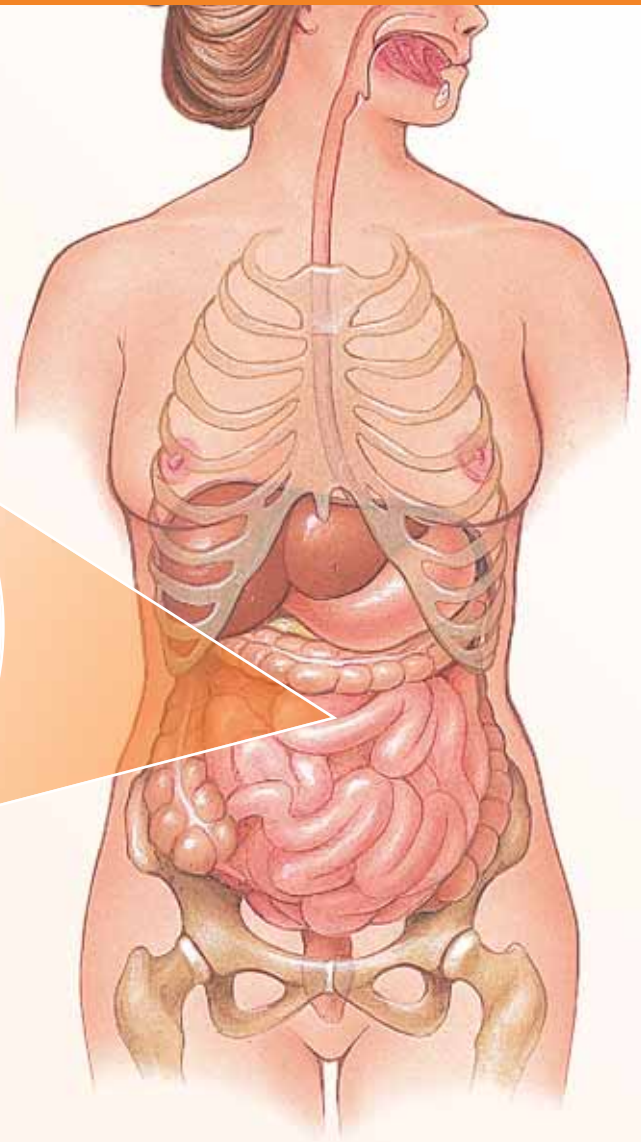
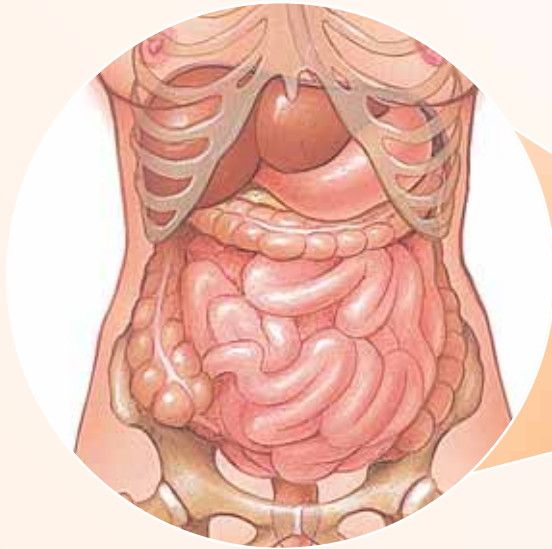
Δ<sup>ε</sup>ε<sup>δ</sup> / σ<sup>ρ</sup>λ<sup>ε</sup>π<sup>ο</sup>σ<sup>β</sup>  
◄<sup>δ</sup>π<sup>ρ</sup>λ<sup>ε</sup>π<sup>ο</sup> / ε<sup>β</sup>ρ<sup>λ</sup>η<sup>ε</sup>β

Irraviit/Nirijattinnik  
Aviktirijjuti/Qarisaq

Iluliit/Niqinik iihivia/Qaritaq

Organes / Appareil  
digestif / Cerveau

# Abdominal Cavity



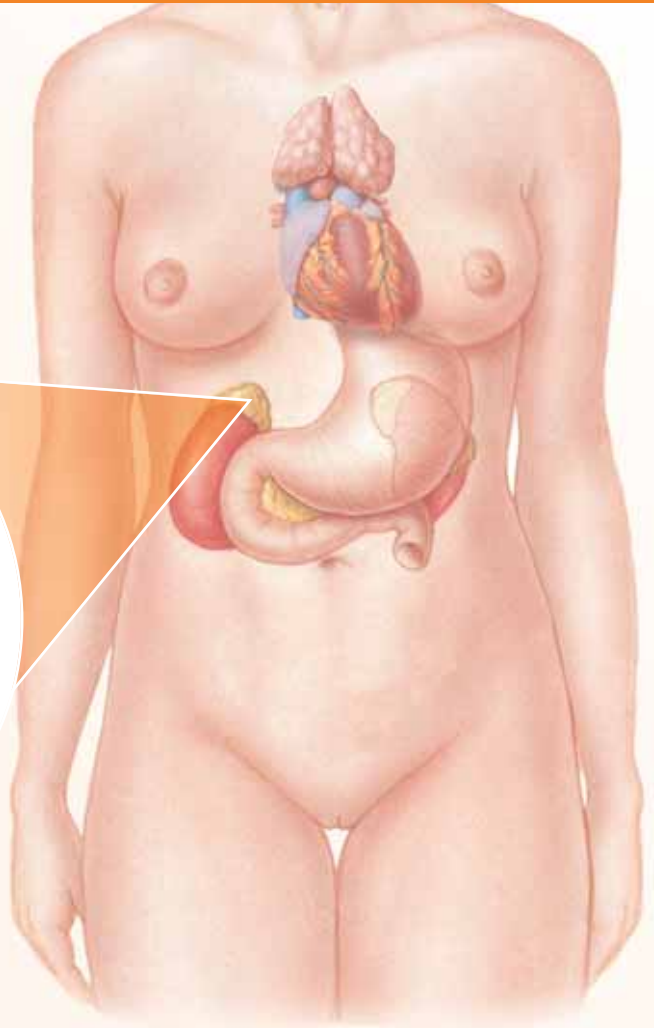
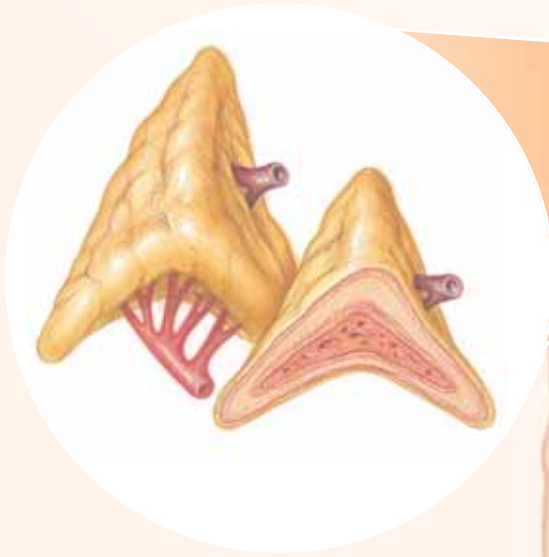ᐅᑦᑲ

Naaq

Kanivaut

Cavité abdominale

# Adrenal Gland



ᑕᑦᑲᑕᑭᑏᑦ

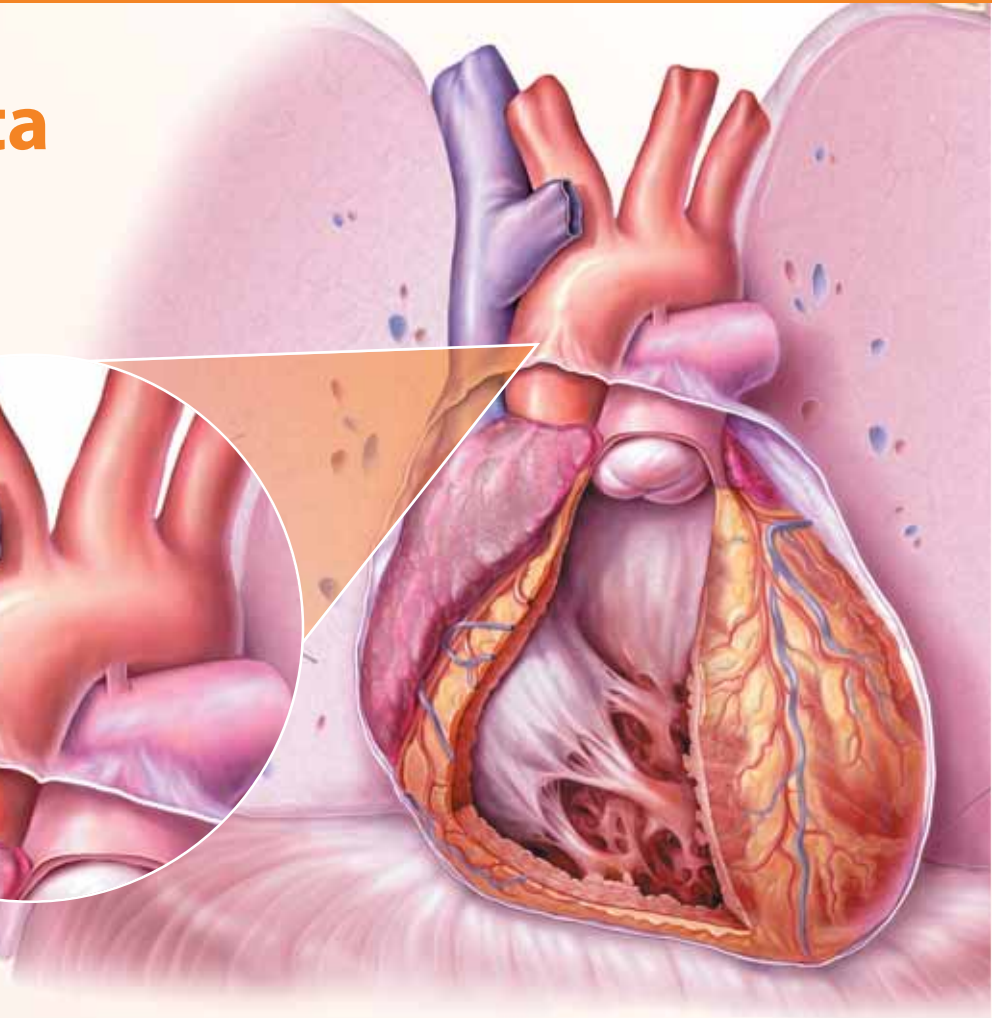
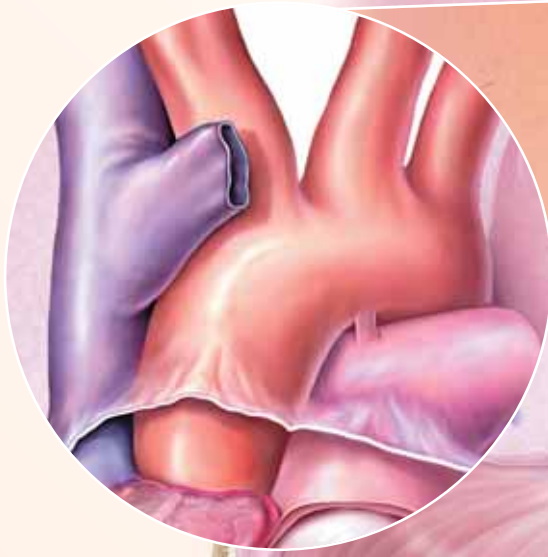
Taqturutiik

Taqtuuk Qulaaniittuk

Qiniqhinaik

Glande surrénale

# Aorta



ᑭᑦᑲᑦ ᑭᑦᑲᑦ ᑭᑦᑲᑦ

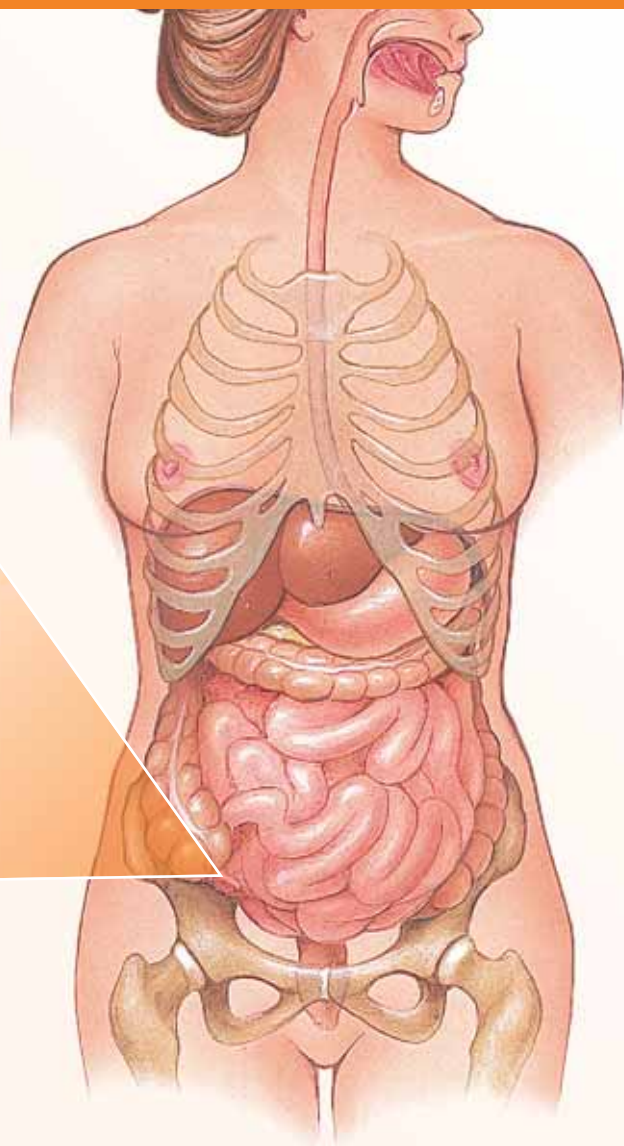
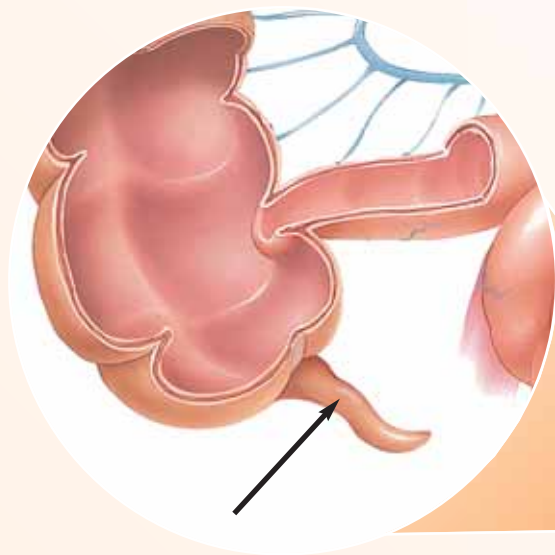
Qalluviaq

Qaalluviaq

Aorte



# Appendix



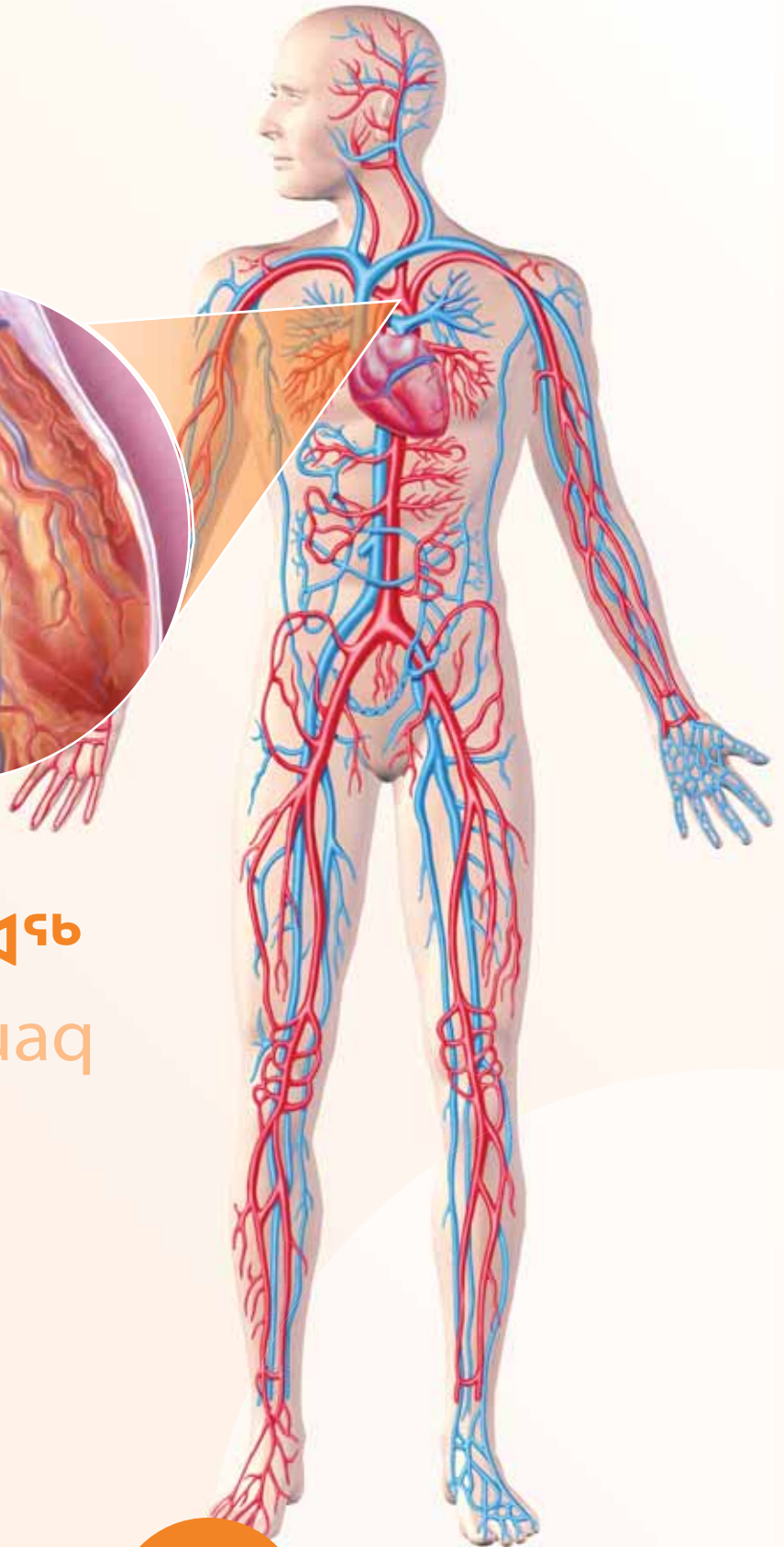
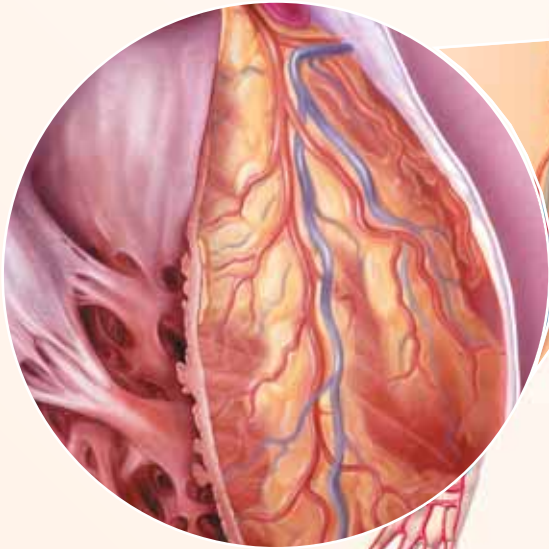
ᑭᕿᐱᕐᑭ

Qipingu

Ilulliut

Appendice

# Artery



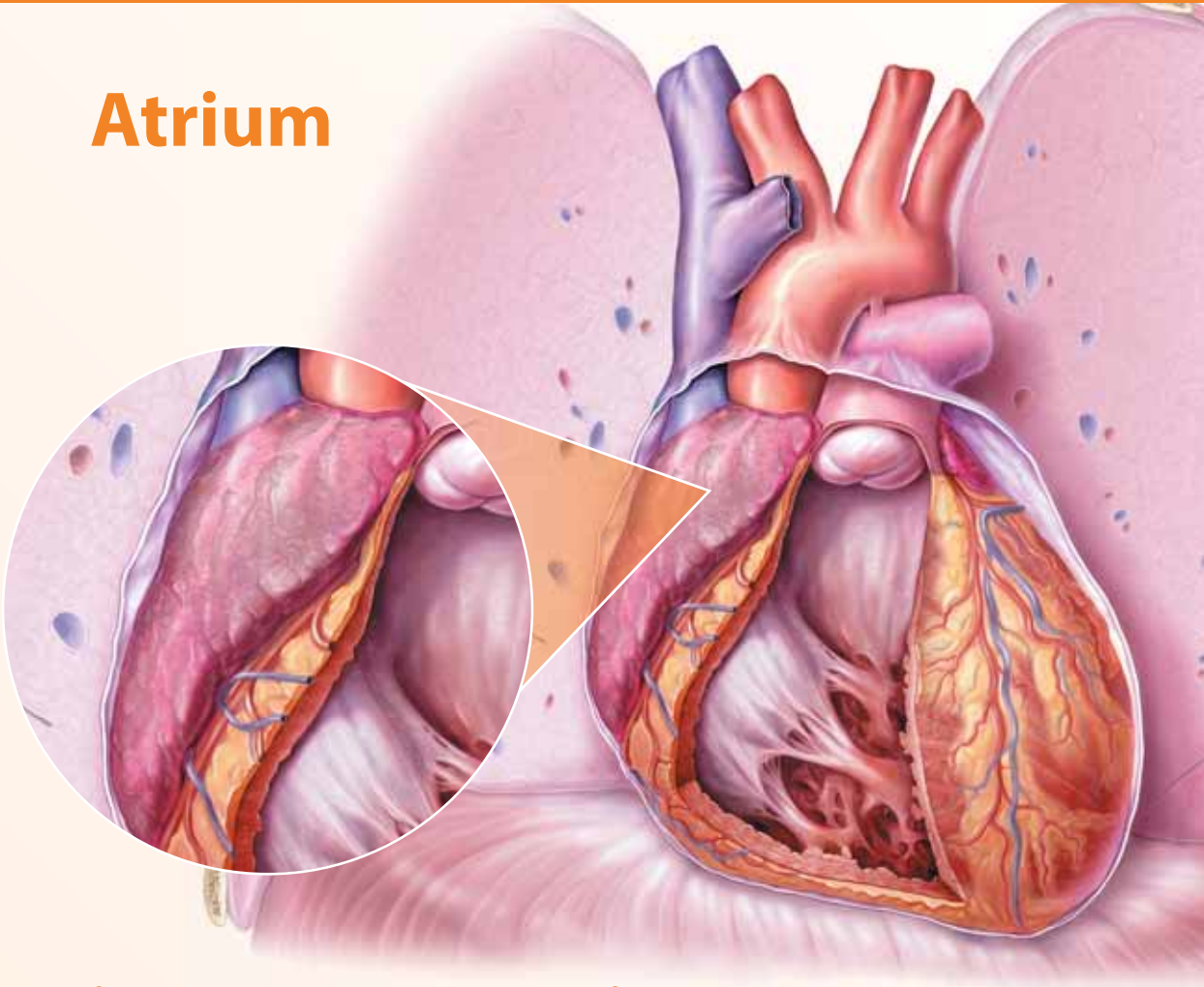
ᑕᑦᑲᑦᑲᑦᑲᑦᑲᑦ

Taqarjuaq

Taqait

Artère

# Atrium



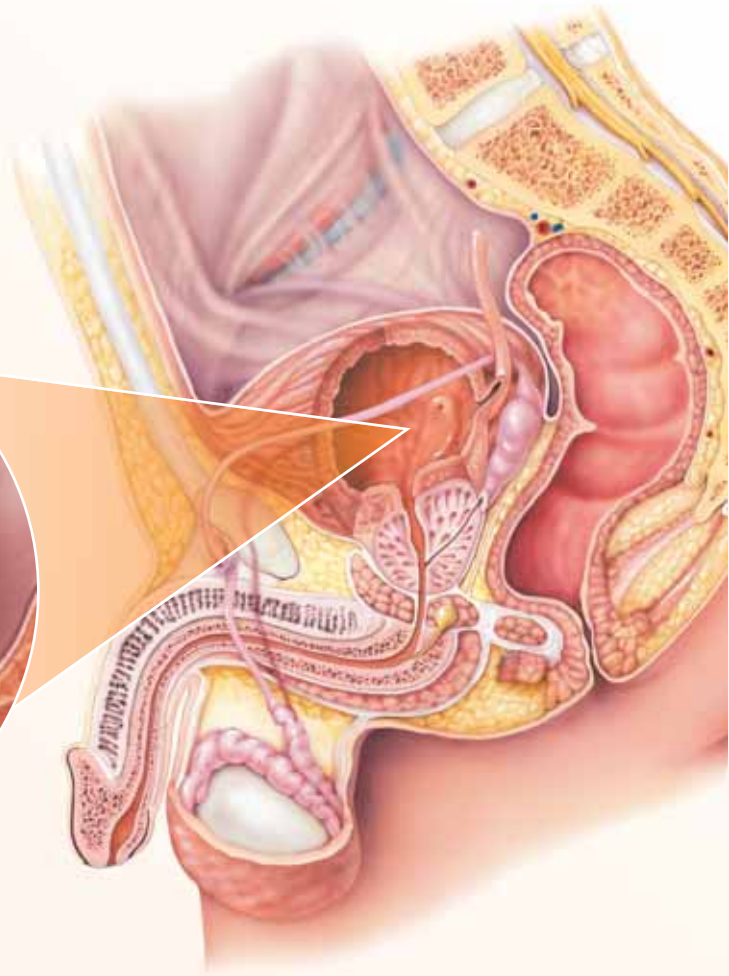
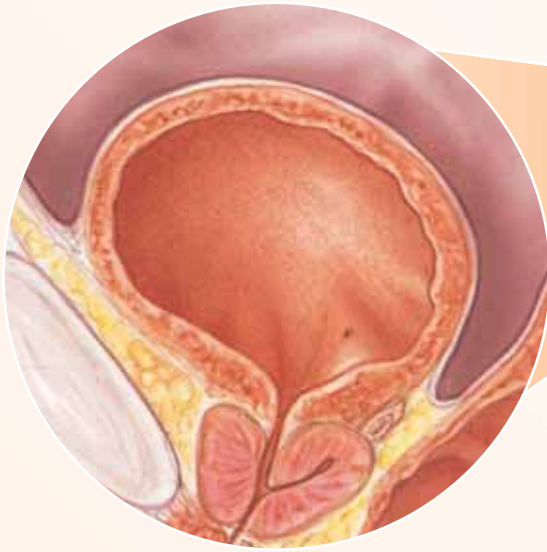ᐃᑦᑲᑲᑦ ᑲᑲᑲᑲᑲ

Uummatiup Qulingaanga

Uummatip Qaludjutaa

Oreillette

# Bladder



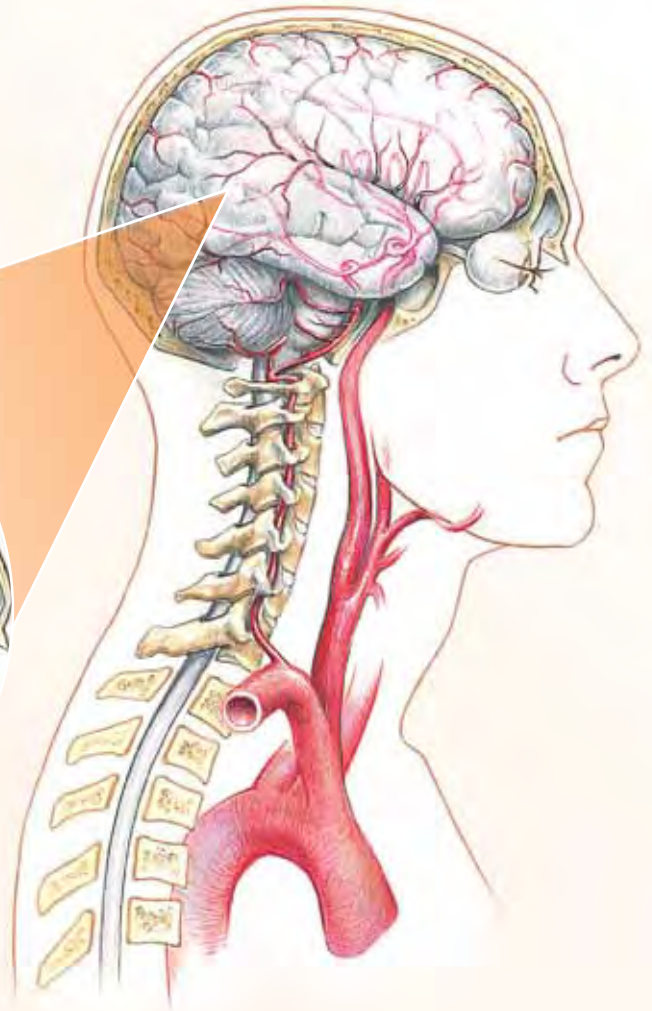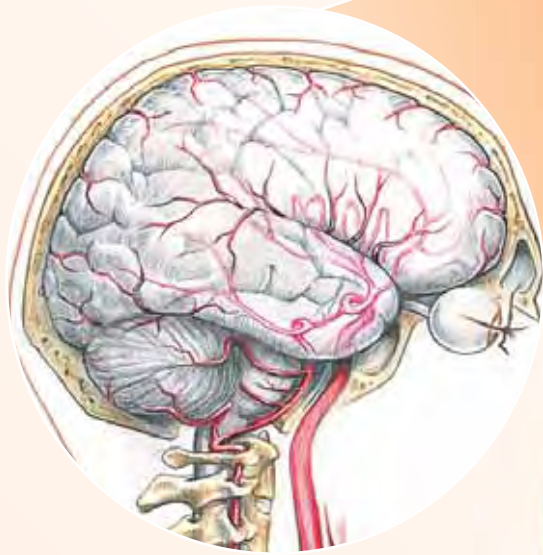ጫሪጫ

Nakasuk

Nakahuk

Vessie

# Brain



ԳԵՂԻԳԵ

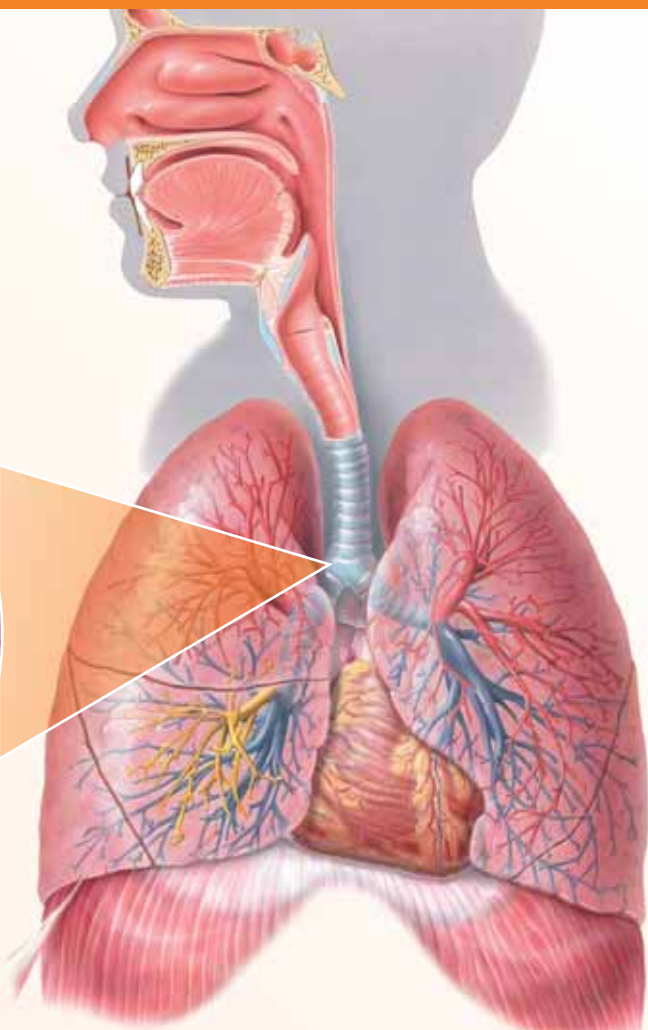
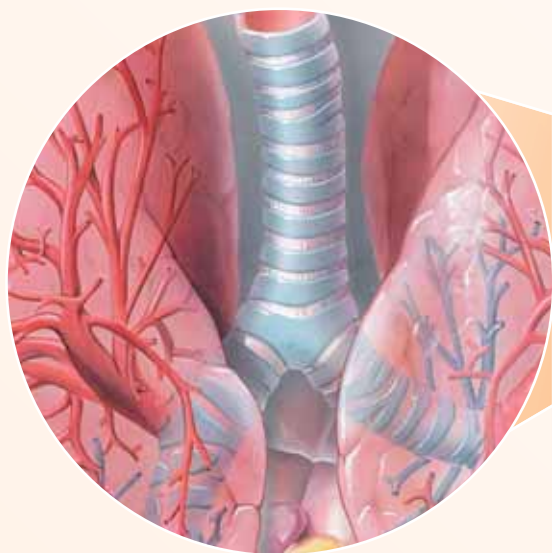Qarisaq

Qaritaq

Cerveau



# Bronchi



ᐅᑦᑲᑦᑭᑦ ᐅᑦᑲᑦᑭᑦ ᐅᑦᑲᑦᑭᑦ

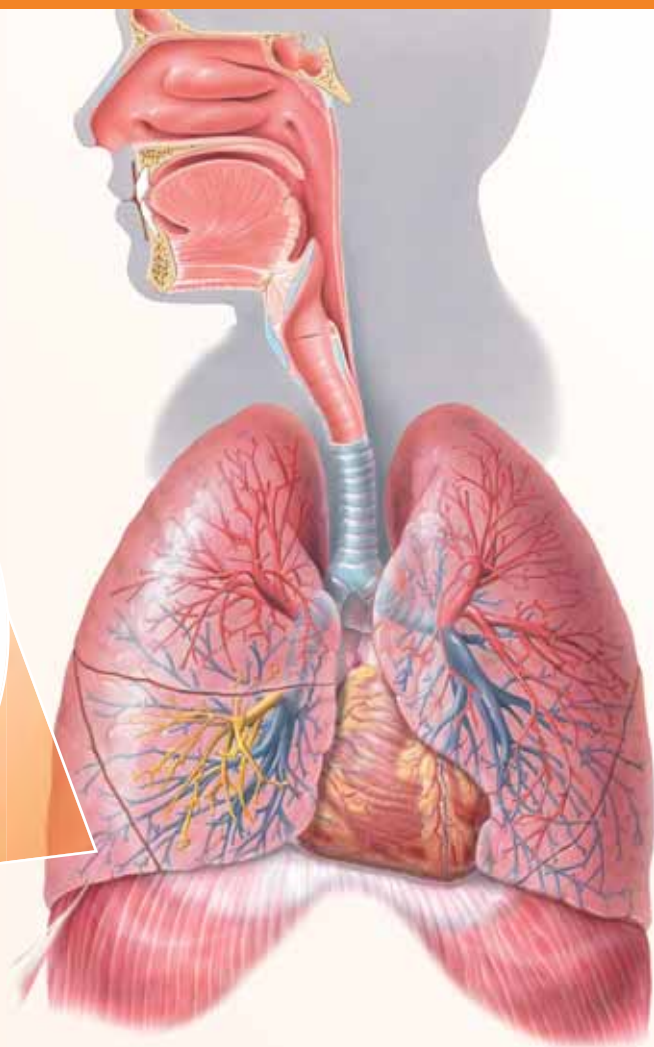
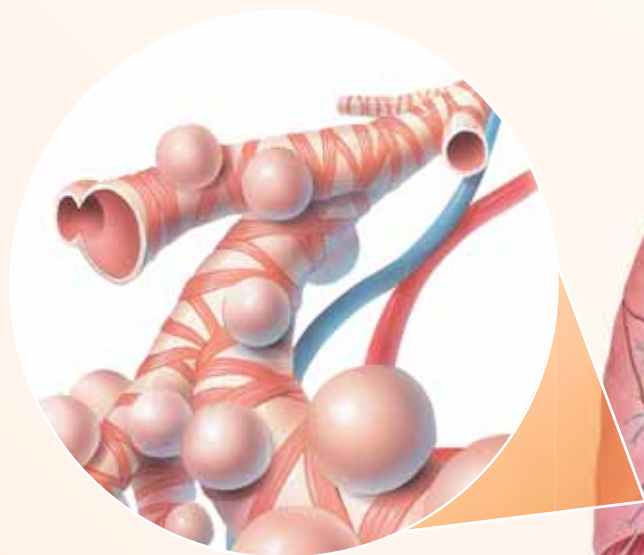
Tuqtuup

Puvangmuanganinga

Puvaup Huvyuit

Bronches

# Bronchioles



ᓄᐱᑦᓃᐅᐅᐅᐅᐅ

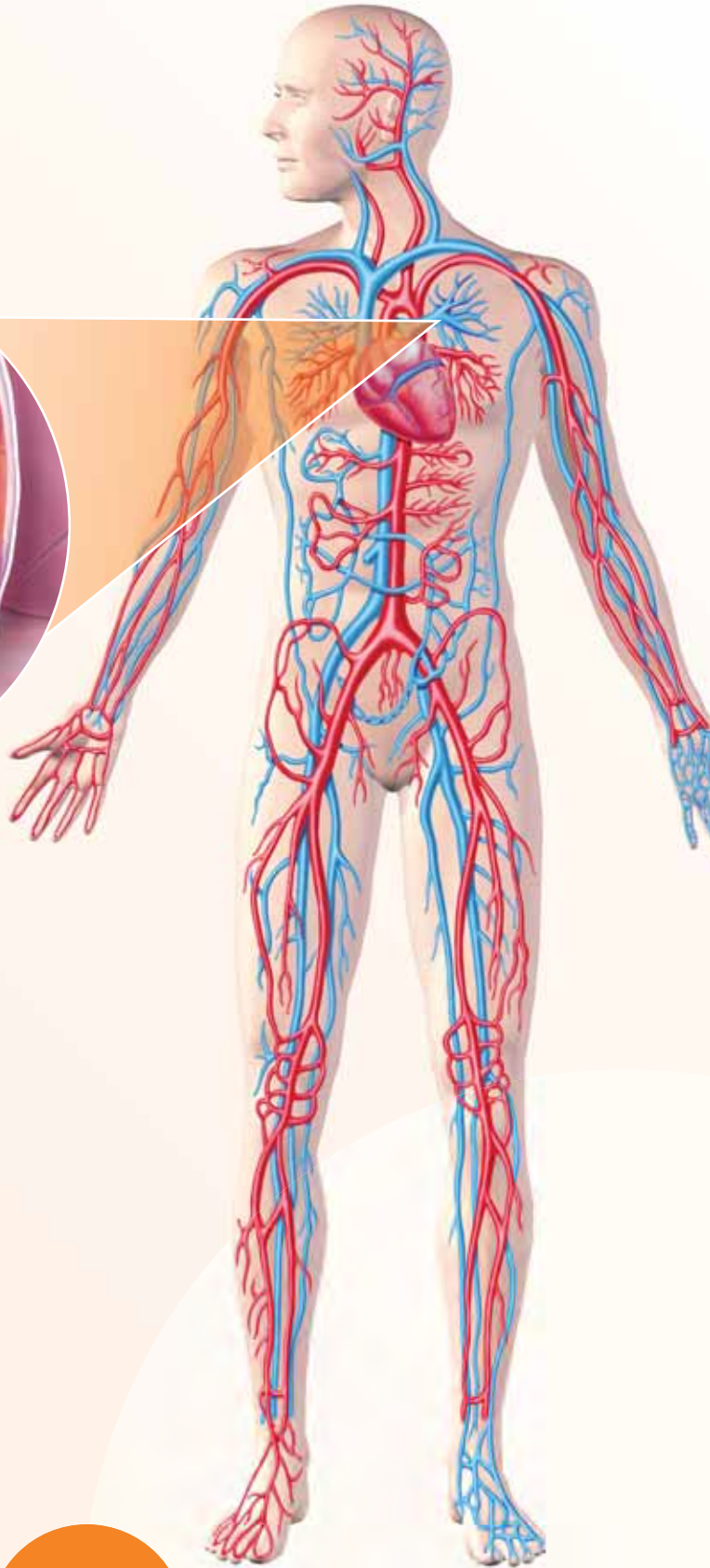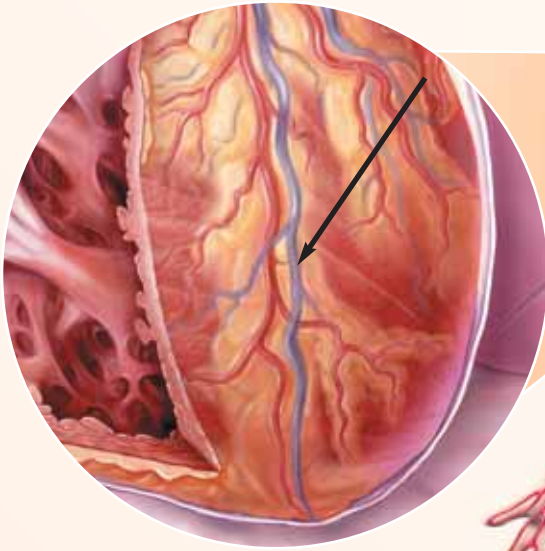
Nuviqłuit

Huvyuit

Bronchioles



# Capillary



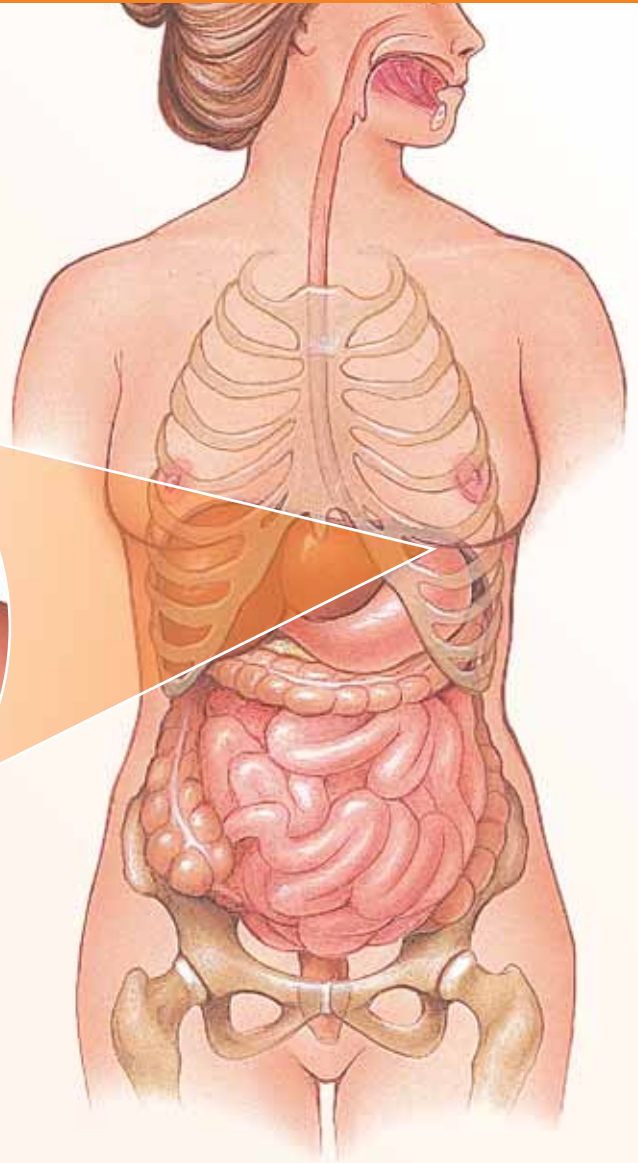
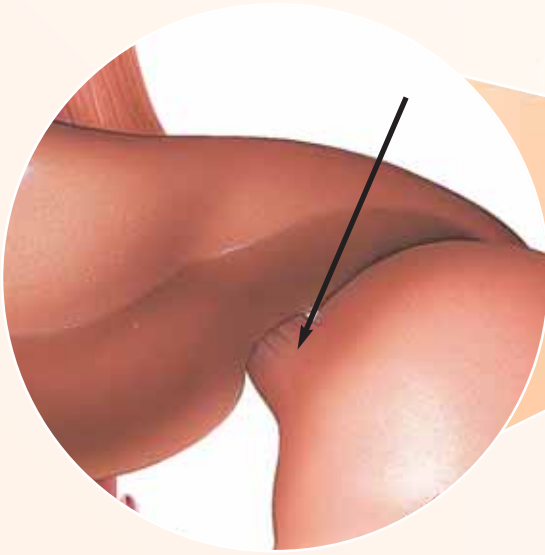
ᑕᑦᑲᑦᑭᑦᑲᑦ

Taqarusiq

Taqannuit

Capillaire

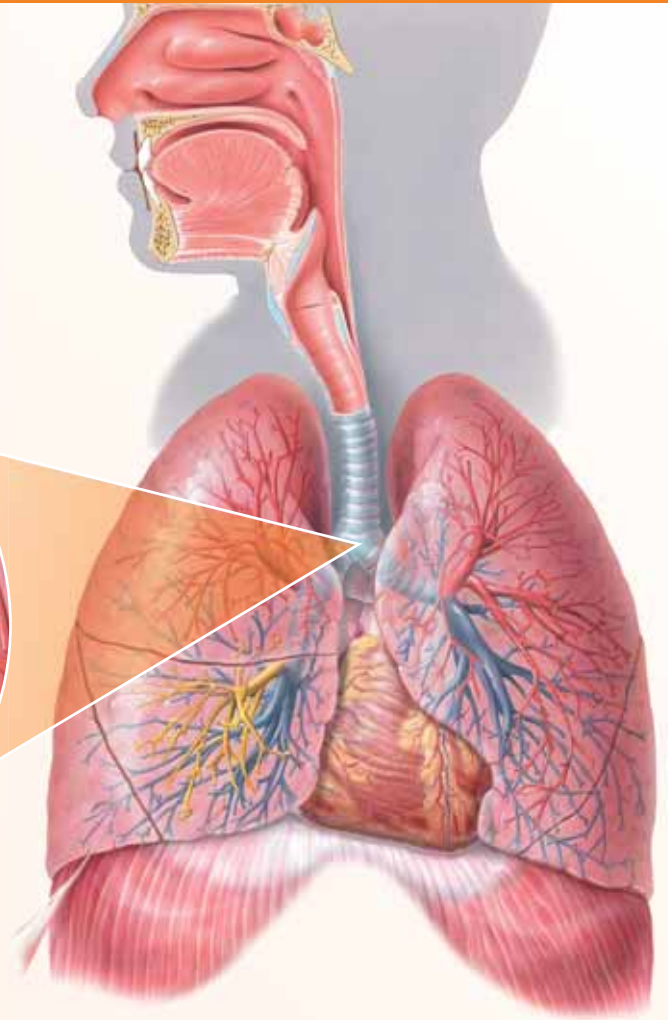
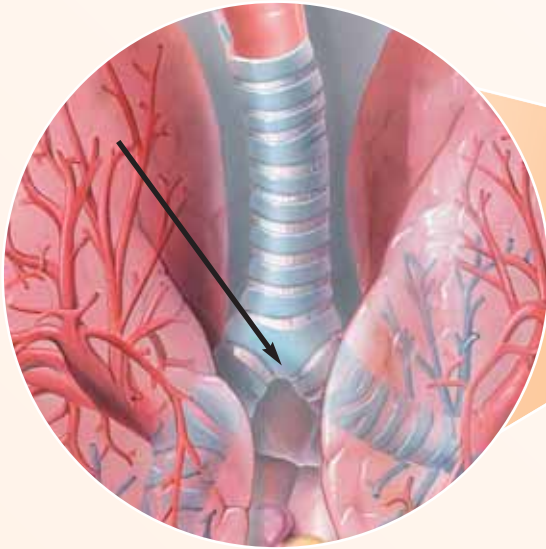
# Cardia Esophageal Junction



ᐱᑦᐱᑦᐱᑦᐱᑦ  
ᑦᐱᑦᐱᑦᐱᑦᐱᑦ

Aqiaruup Quuqqanga  
Aqiaruup Pivviuyaa  
Cardia

# Carina / Bifurcation of Trachea



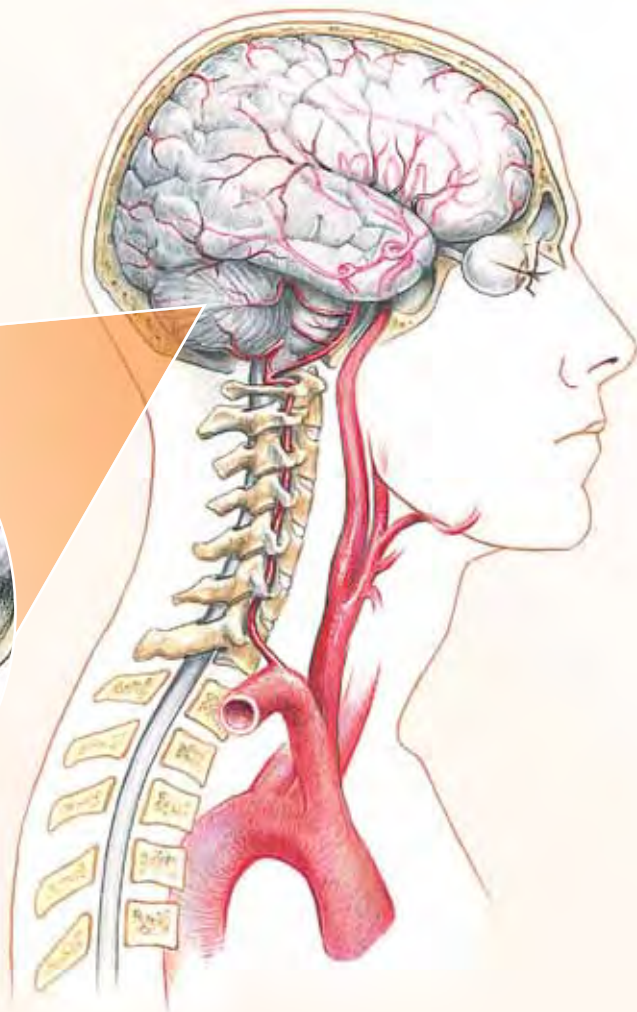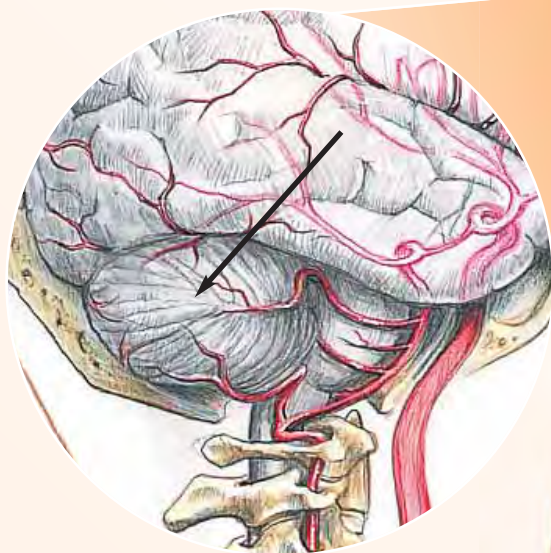
ܕܩܒܐܢܐ

Tuqłuk

Tuqhuk

Éperon trachéal

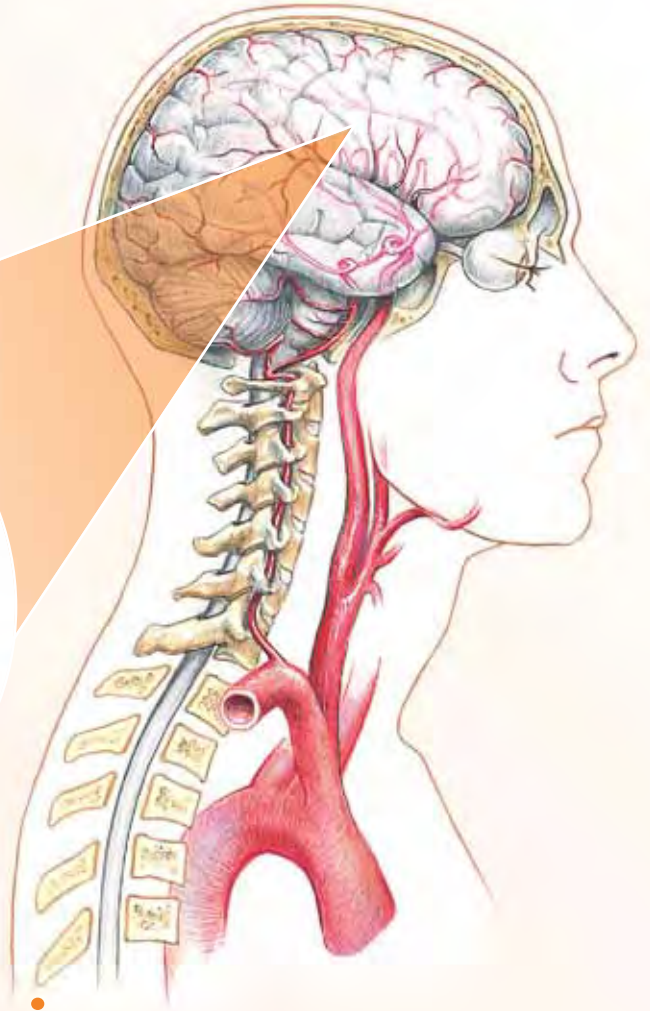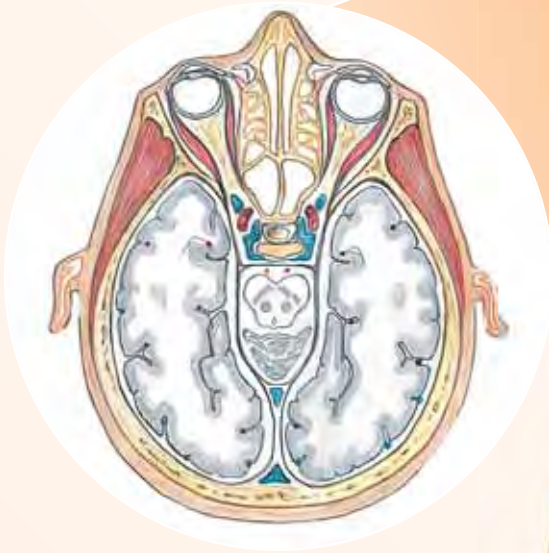
# Cerebellum



▷◁↳°∪Δ↵▷◁◡

Upalungaijaut  
Ihumaliurvik  
Cervelet

# Cerebral Hemispheres



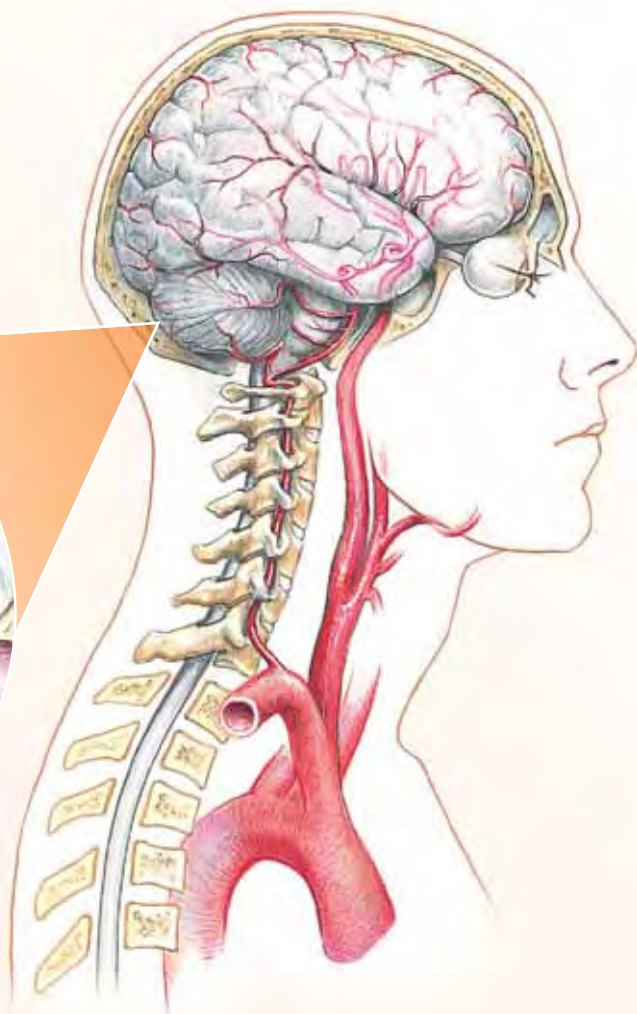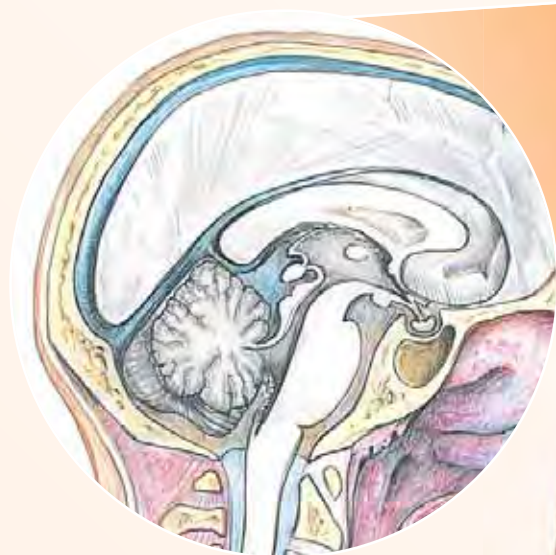ᑭᓂᓴᓂ ᐃᓂᐱᓂ

Qarisaak iglugiik

Qarittak Iglugiik

Hémisphères cérébraux

# Cerebral Meninges



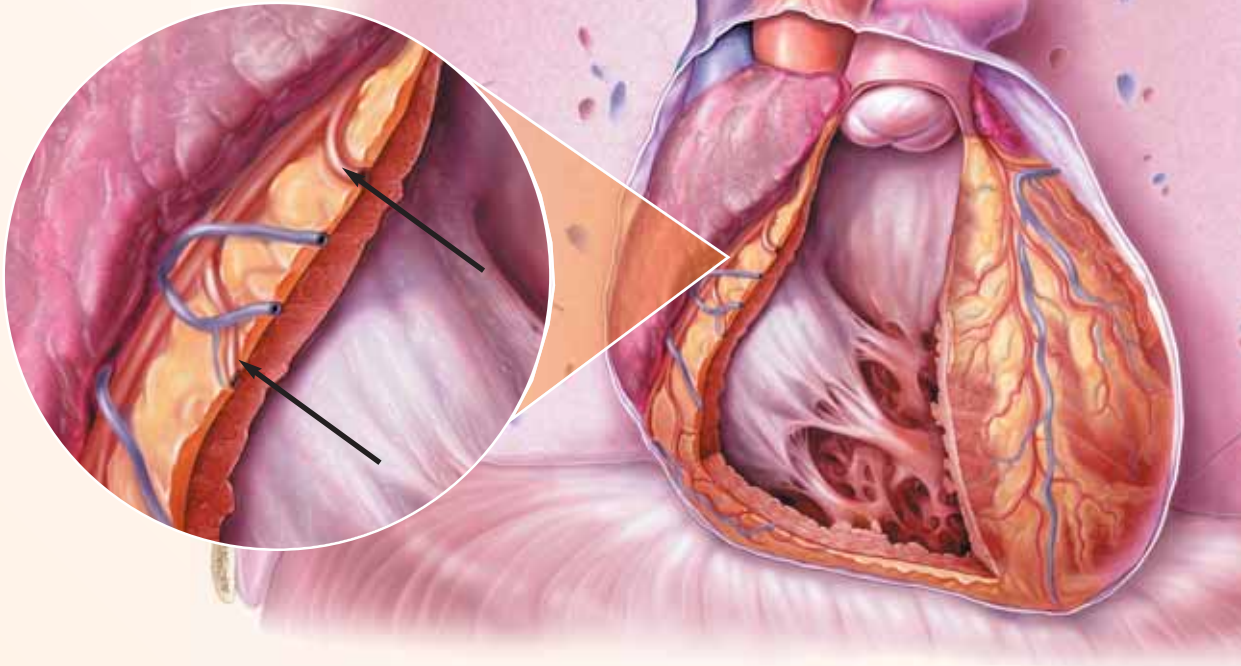
ፍጠራ ነገር ጎረቤ

Qarisaup Puunga

Qarittap Kapihianga

Méninges cérébrales

# Coronary Vessels



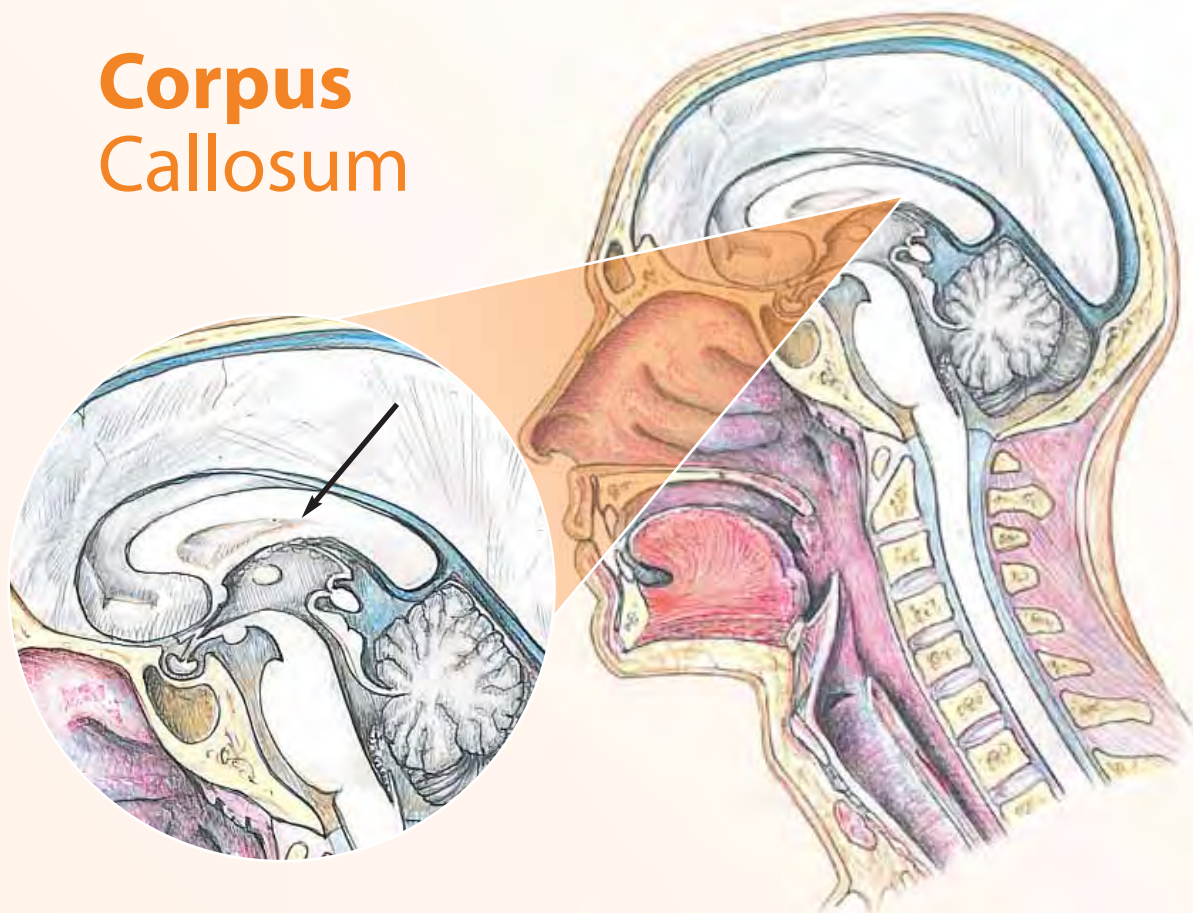
ᐃᐭᐭᐭᐭᐭᐭᐭ ᐭᐭᐭᐭᐭᐭᐭ ᐭᐭᐭᐭᐭᐭᐭᐭᐭᐭ

Uummatiup Qaangani Taqait

Uummatip Taqait

Vaisseaux coronaires

# Corpus Callosum



ԳԵՂԿՂԸ ԵՈՐՏԻՅ

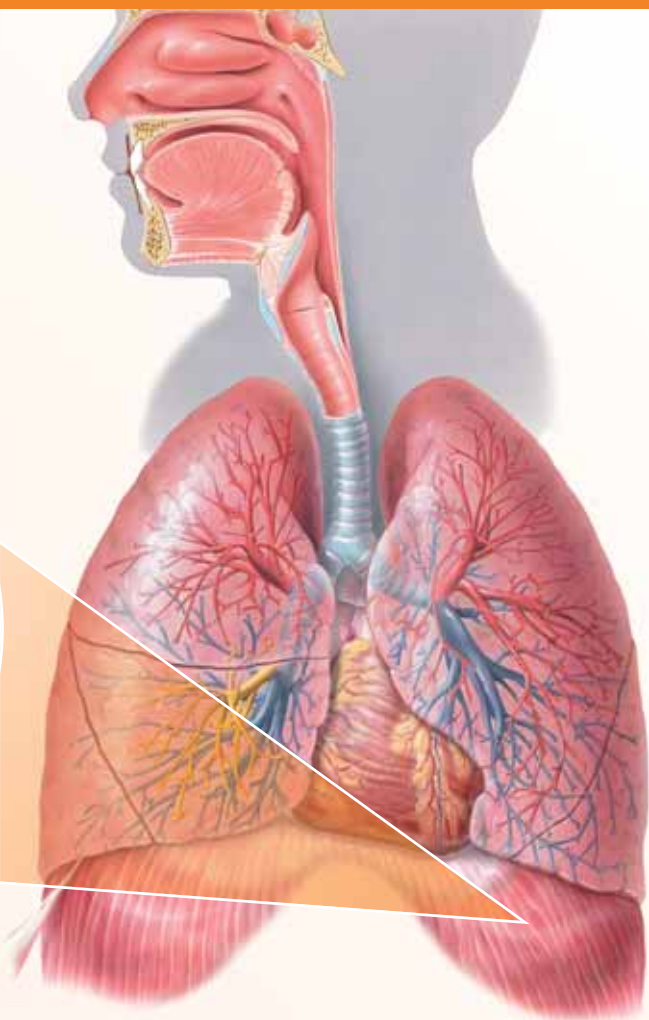
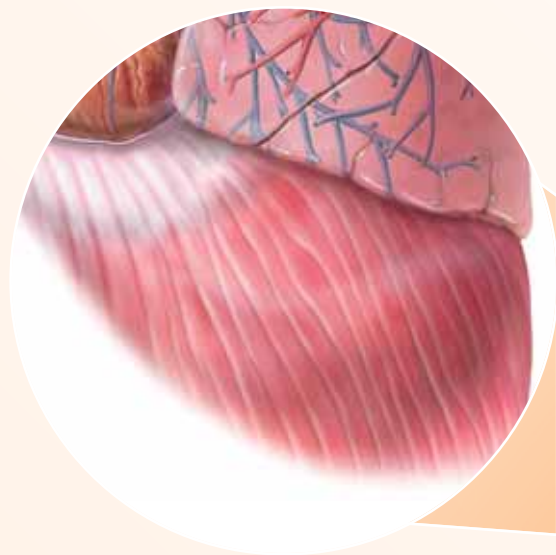
Qarisarmut Katinniq

Qarittap Akilvirutaa

Corps calleux



# Diaphragm



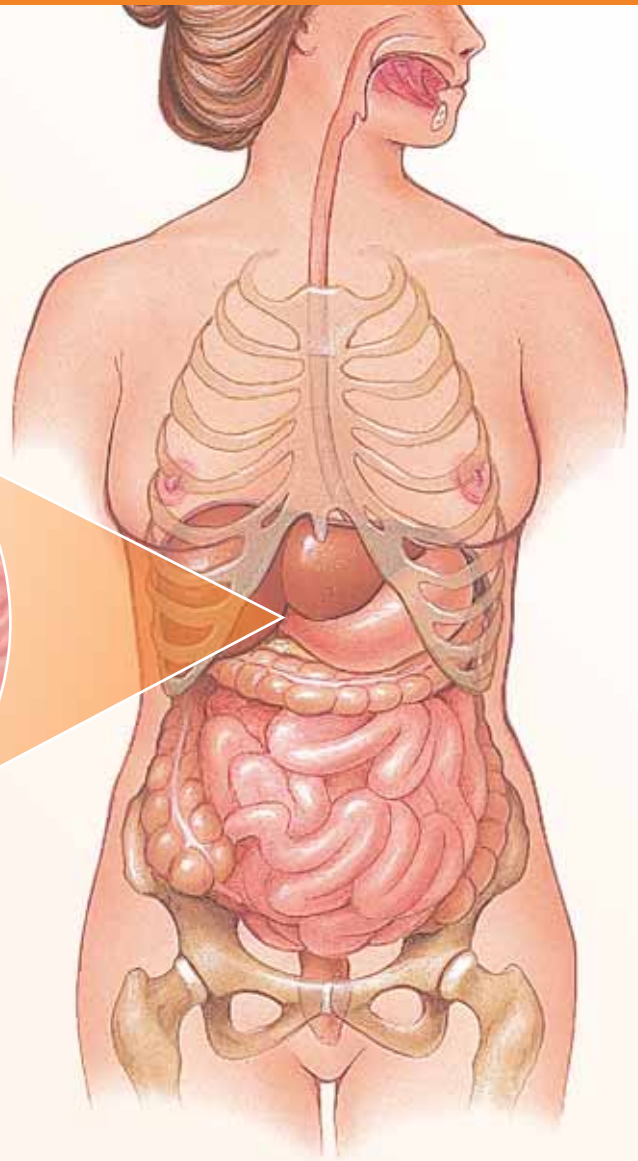
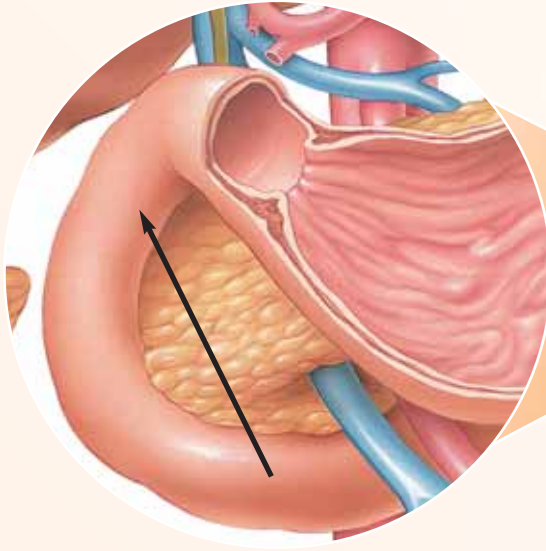
बसुद

Kanivaut

Kanivaut

Diaphragme

# Duodenum



ᑦᑭᑭᑦᑭᑦᑭᑦ

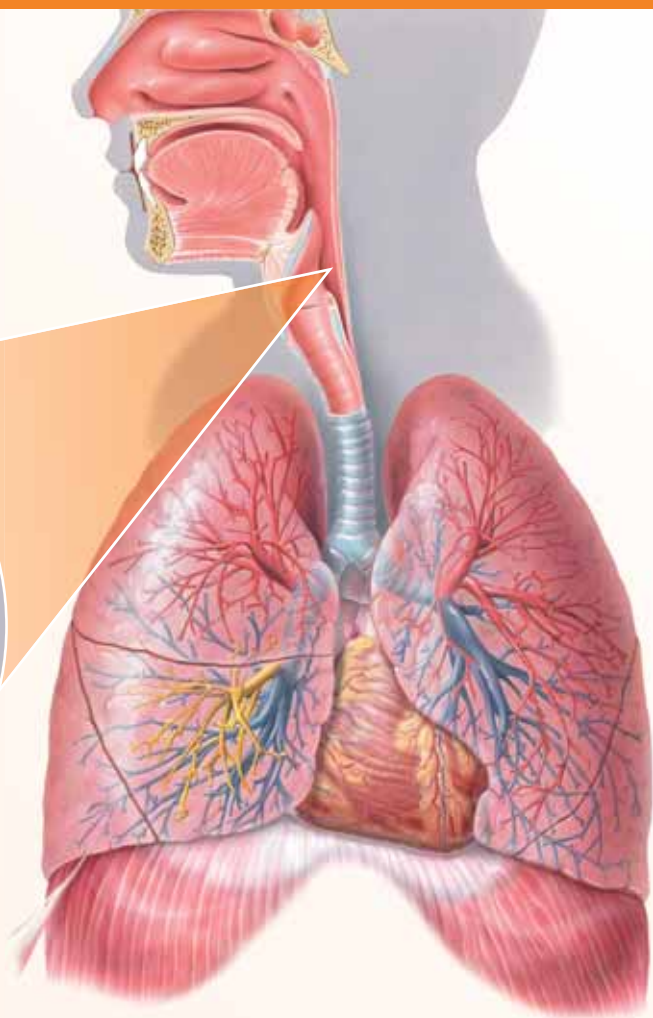
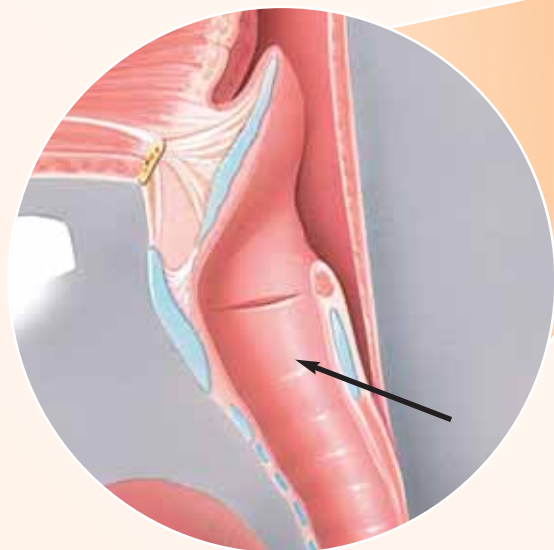
Quukinniq

Quukilruq

Duodénium



# Esophagus



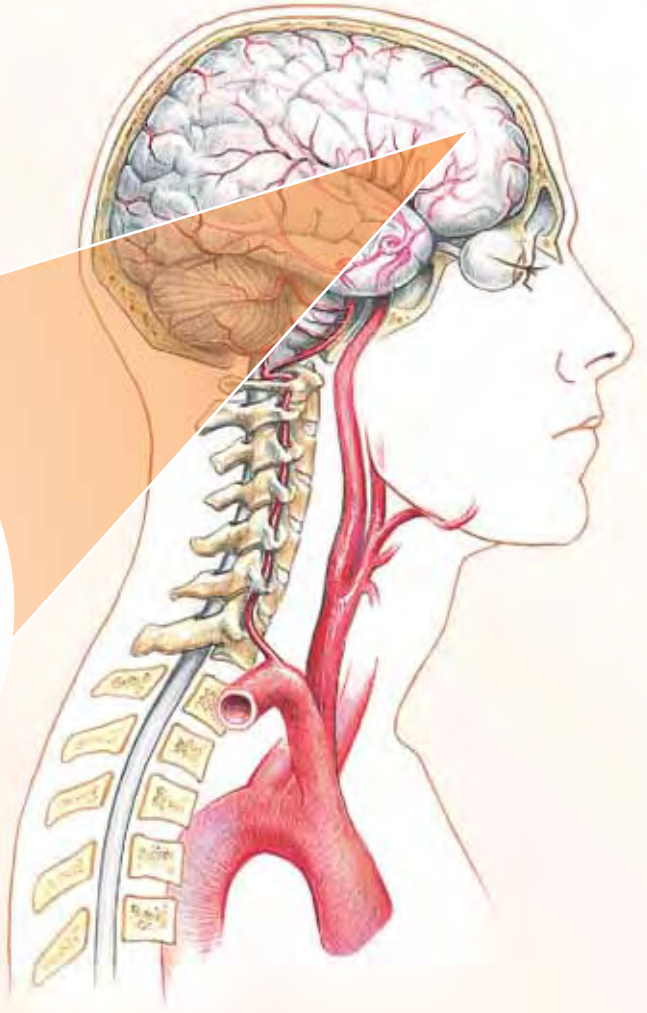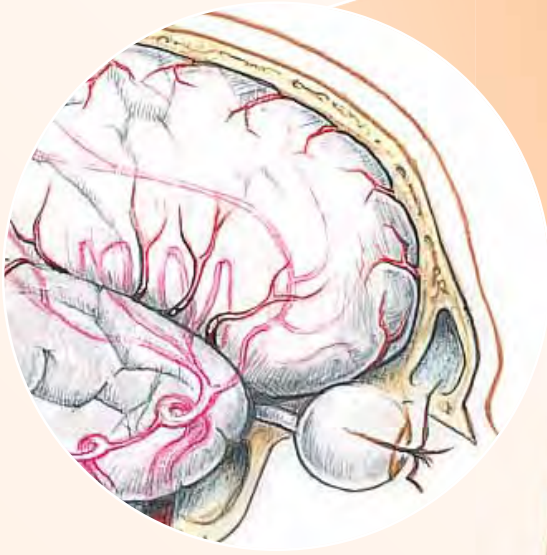ᐃᓴᓯᐃᑦᑲ

Iggiaq

Tuqhuk

Esophage

# Frontal Lobe



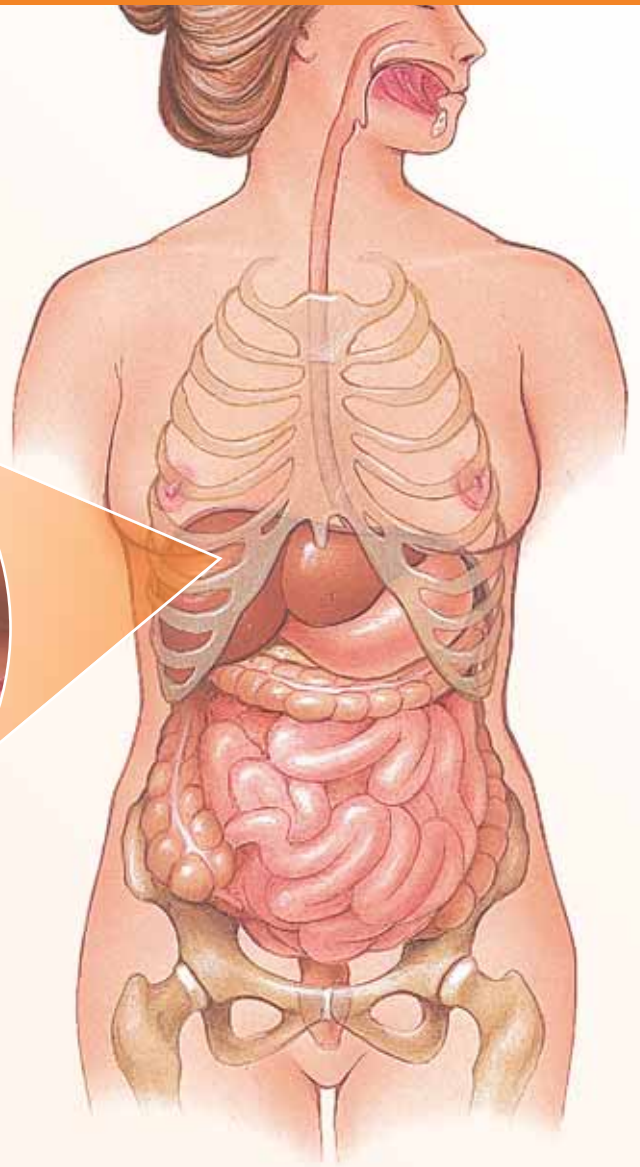
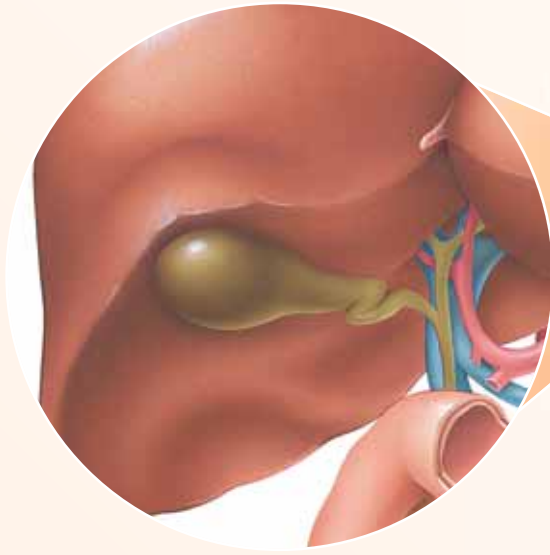
ΔʀԼ ԵԿ ԳԵԴ ԳՃ Ե

Isumaksaqsuurvik

Hivun'nga Qaritaup

Lobe frontal

# Gall Bladder



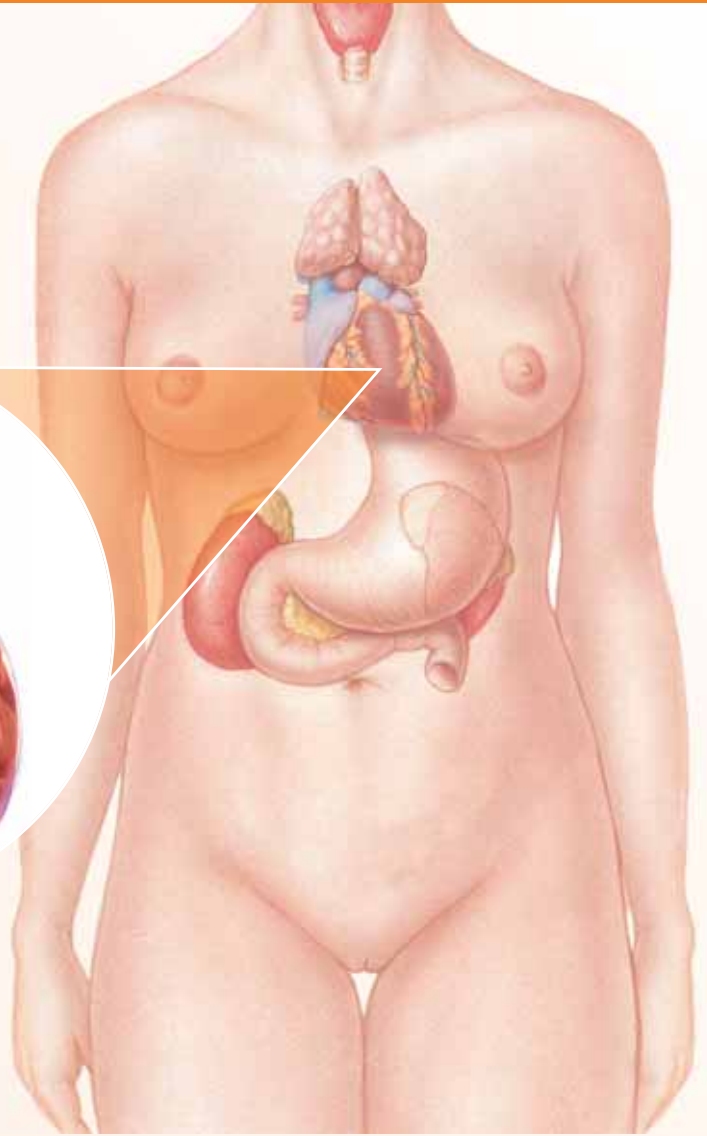
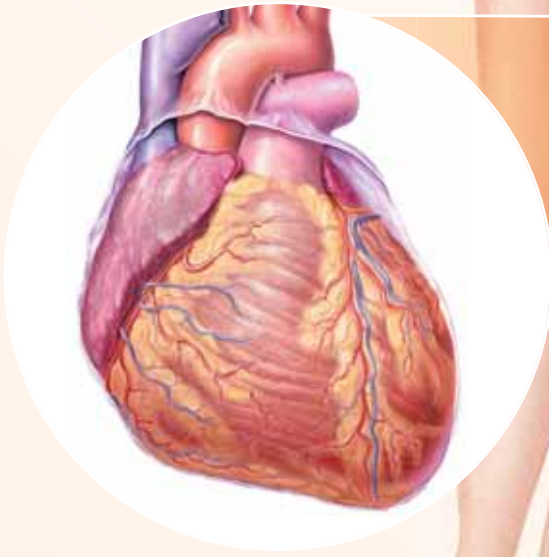
سۇنغاق

Sungaq

Hungaqarvik

Vésicule biliaire

# Heart



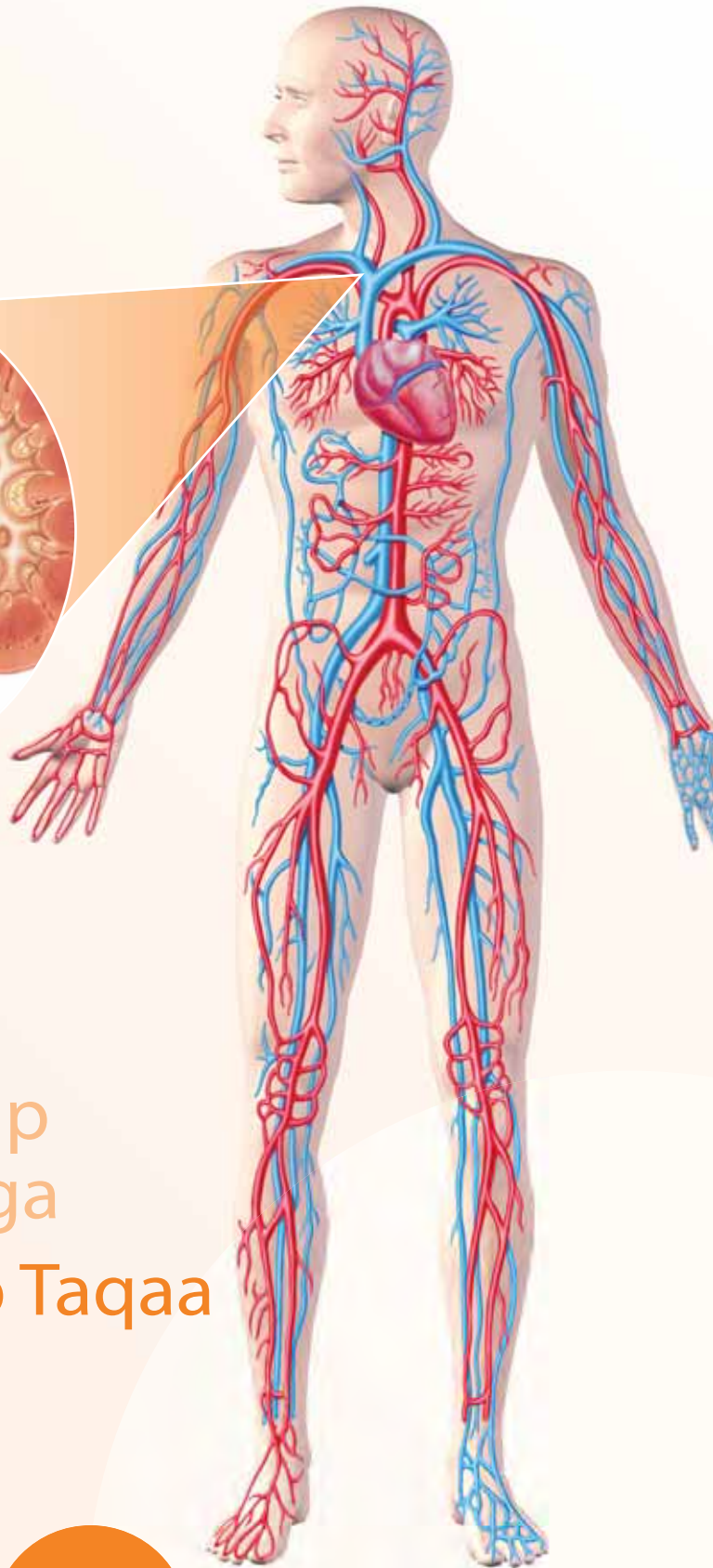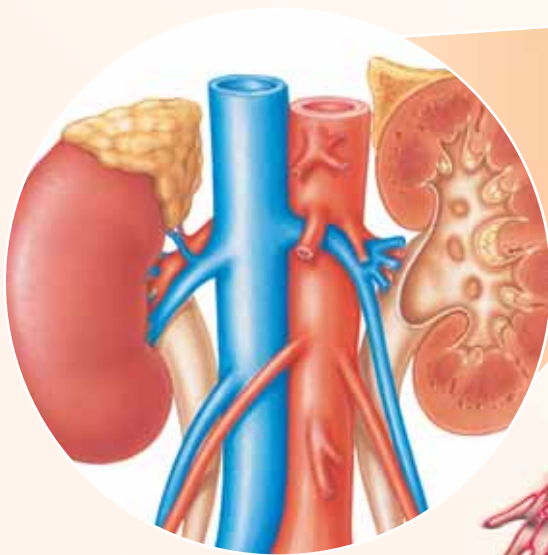
ᐃᐸᐸᐸ

Uummati

Uummat

Cœur

# Inferior Vena Cava



ᐃᐸᐸᐸᐸᐸ

ᐸᐸᐸᐸᐸᐸᐸ

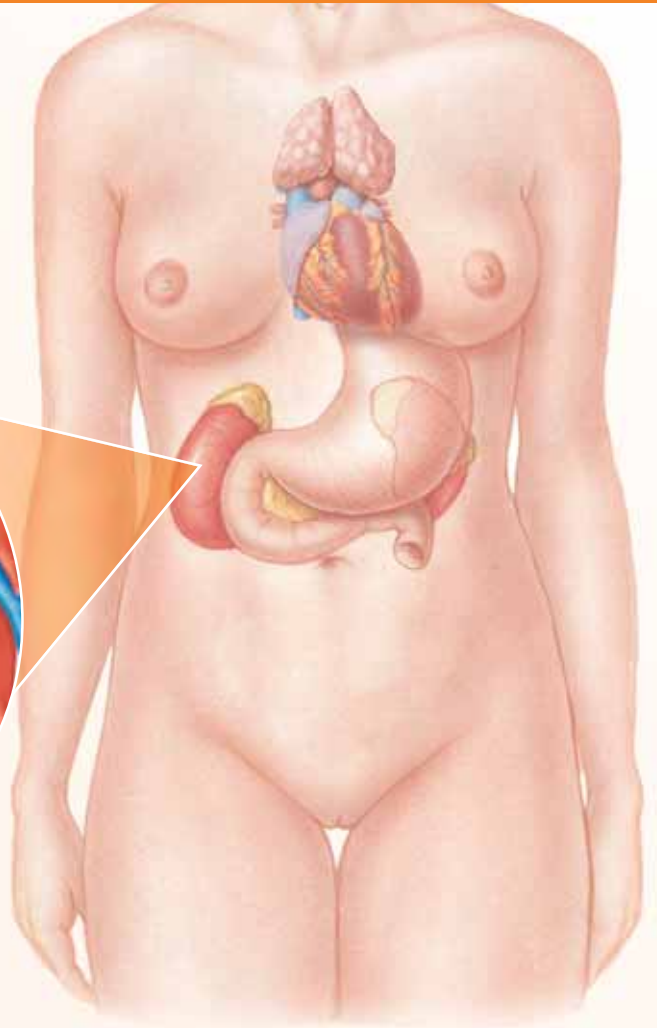
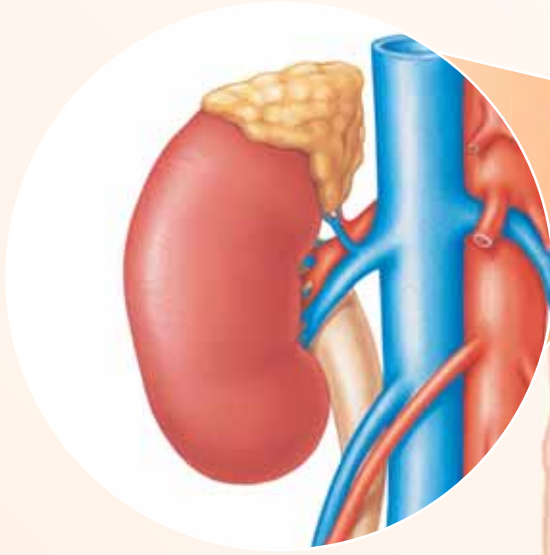
Uummatiup  
Taqarjuanga

Uummatip Taqaa

Veine cave  
inférieure



# Kidney



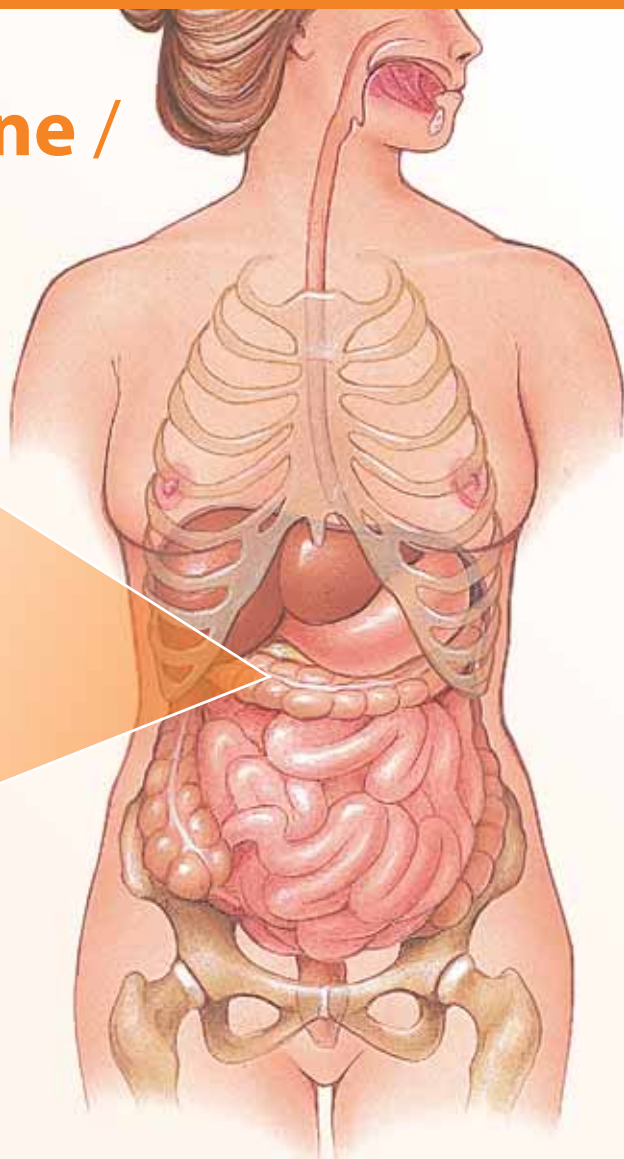
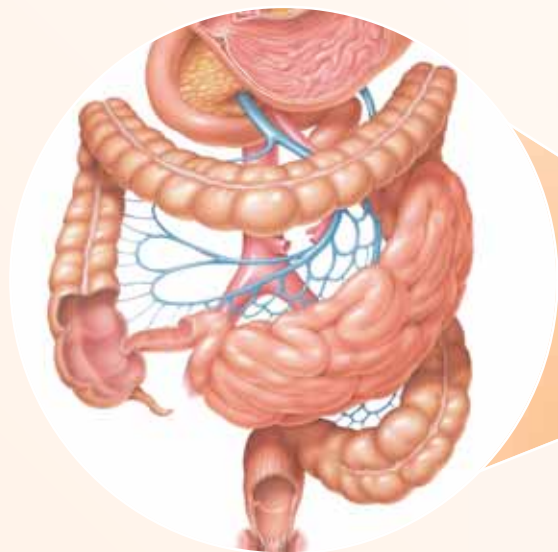
﴿ ٢٩٦ ﴾

Taqtu

Taqtu

Rein

# Large Intestine / Colon



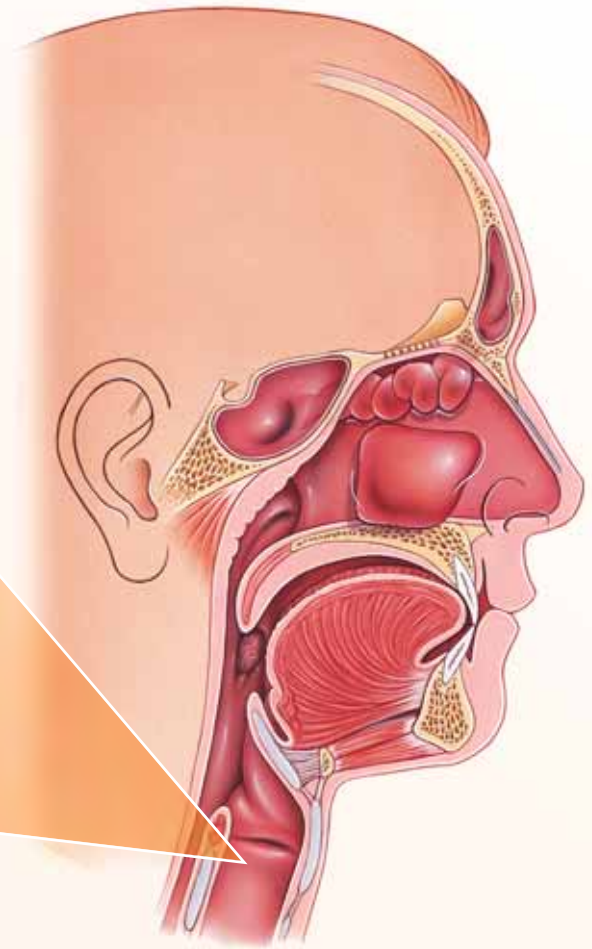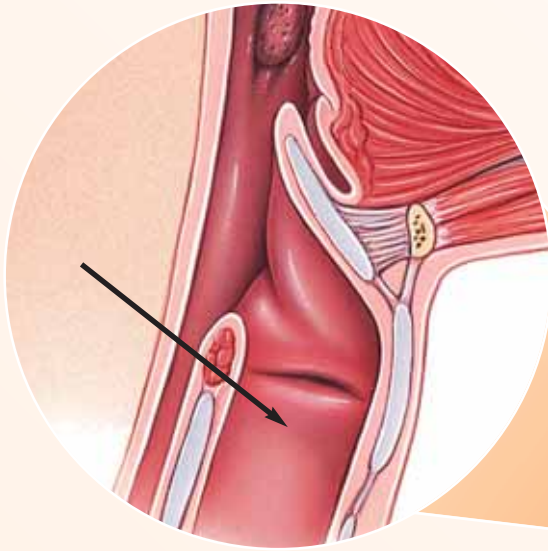
ᐱᐅᐅᐅᐅᐅ

Anavauti

Ingaluat/Iqhuq

Gros intestin, colon

# Larynx / Voice Box



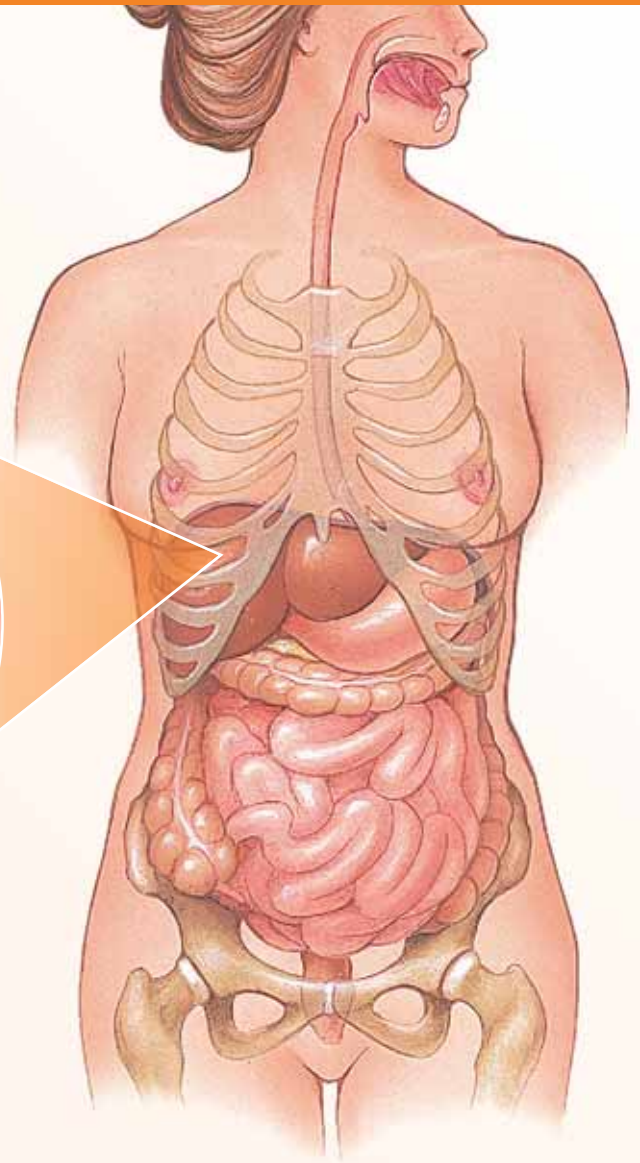
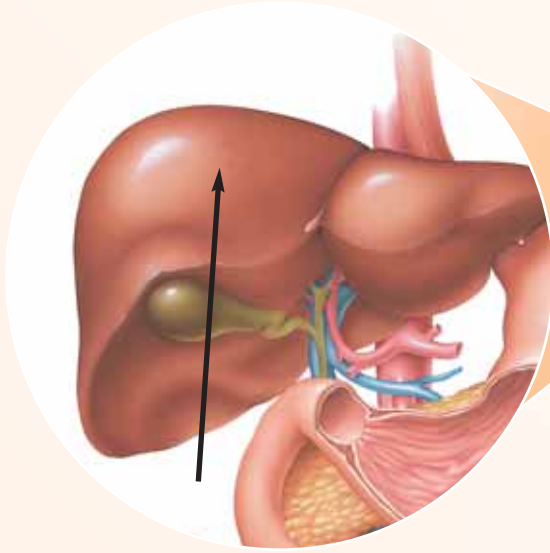
ᐅᑦᑲᑦᑲᑦ

Tuqqujaak

Nivyaarvik

Larynx

# Liver



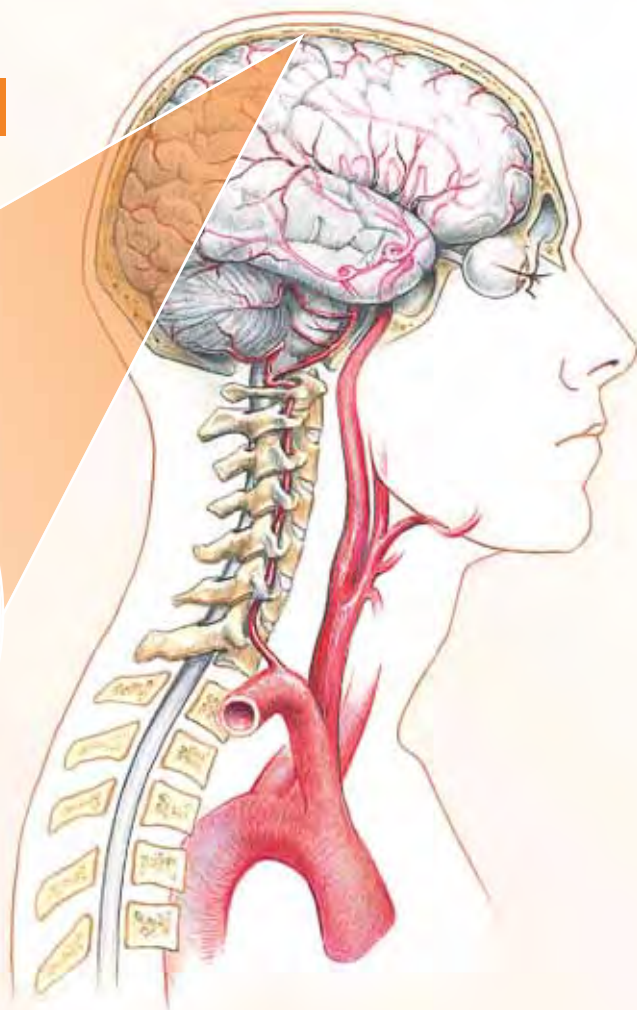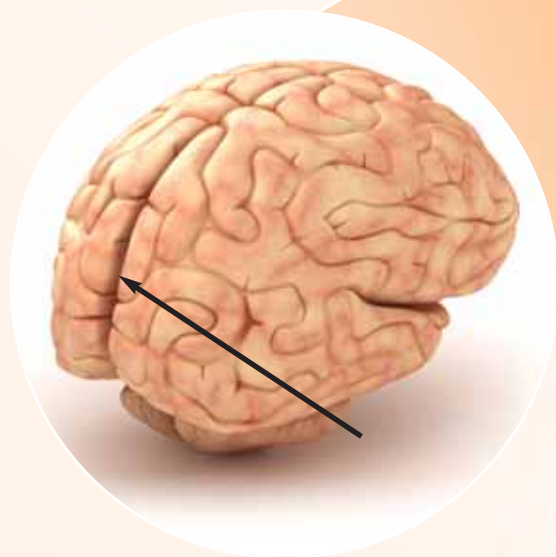ՈՒՅԽ

Tinguk

Tinguk

Foie

# Longitudinal Cerebral Fissure



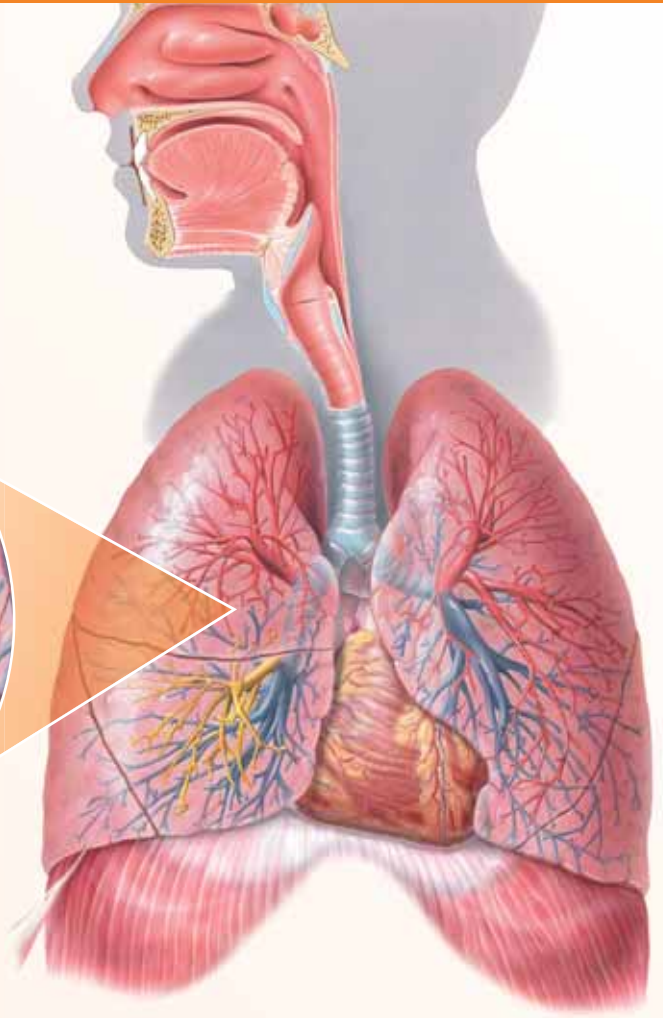
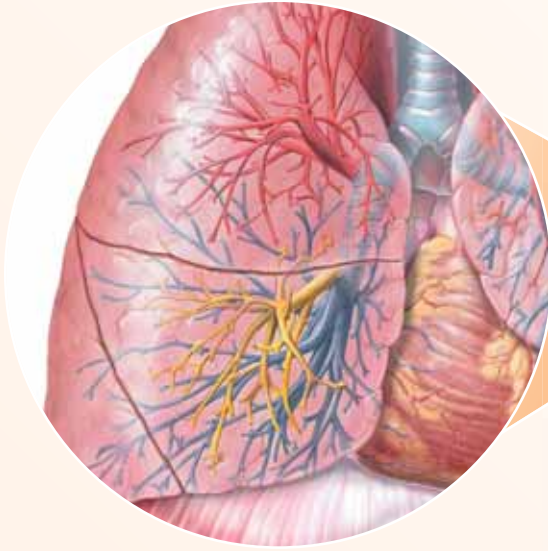
Λ ς σ ς β

Pirniq

Akulvirutaa

Scissure inter-hémisphérique

# Lung



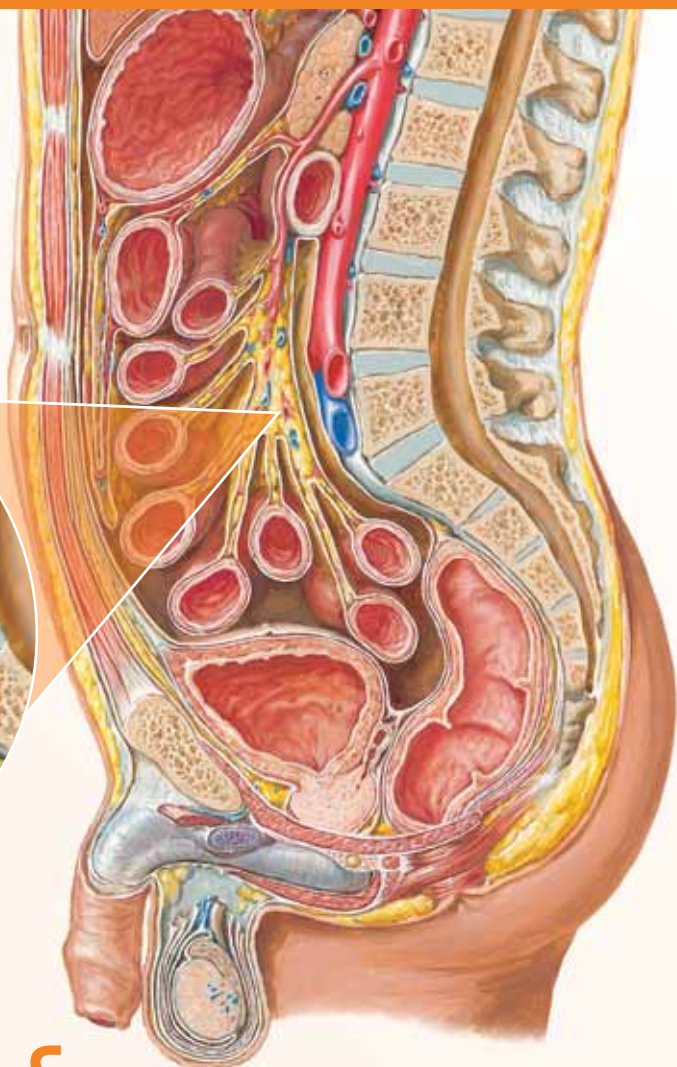
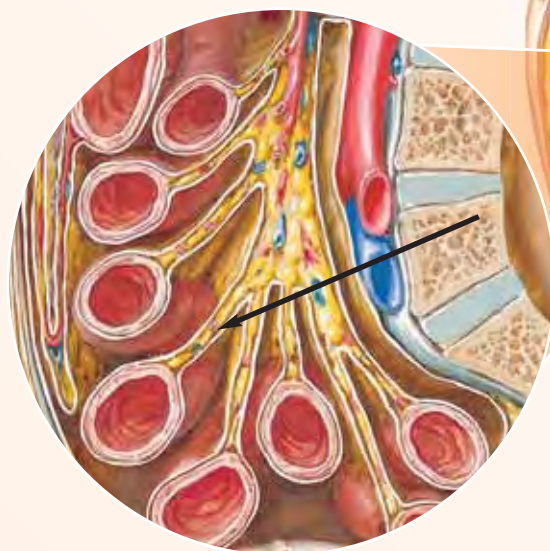
> ୧୦୬

Puvak

Puvak

Poumon

# Mesentery



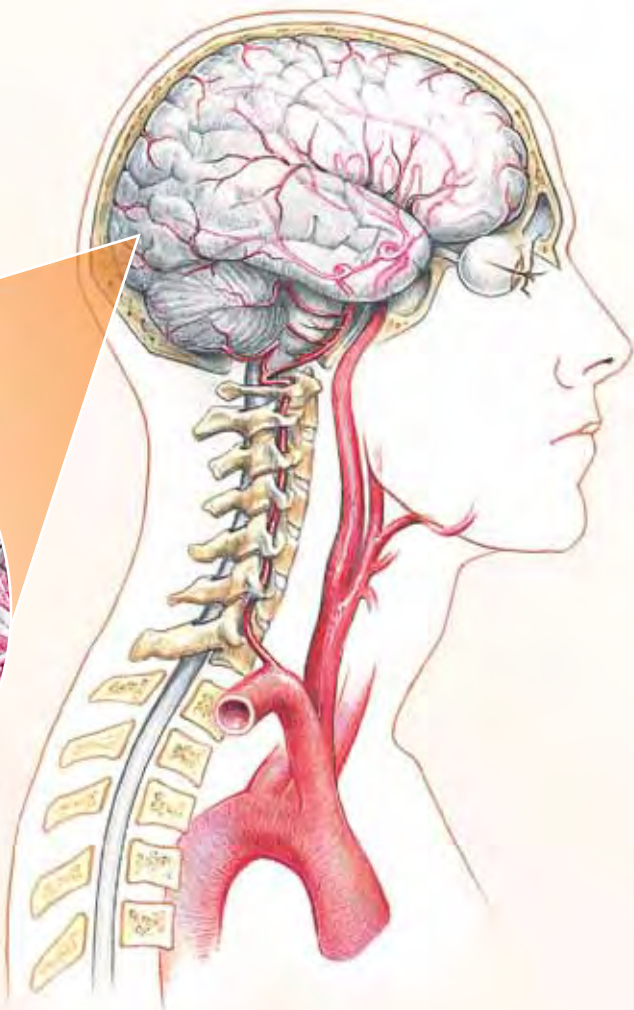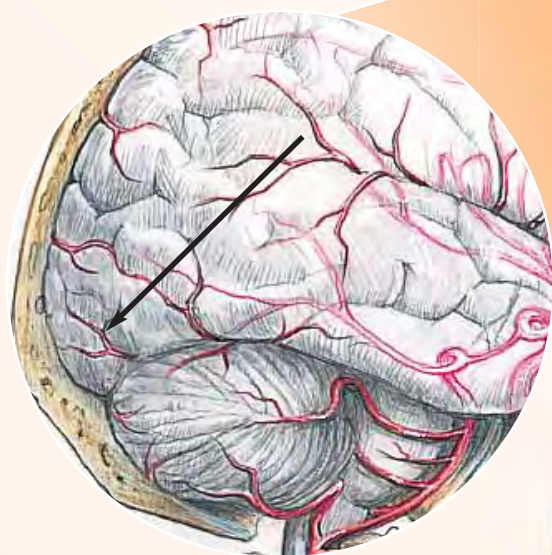
Δῆλῶς ἔστιν

Irraviit Puungat

Kikhaut

Mésentère

# Occipital Lobe



ԳԵՆԸԿՏՆԵՆ ԳՐԲԺԺՆԵՆ

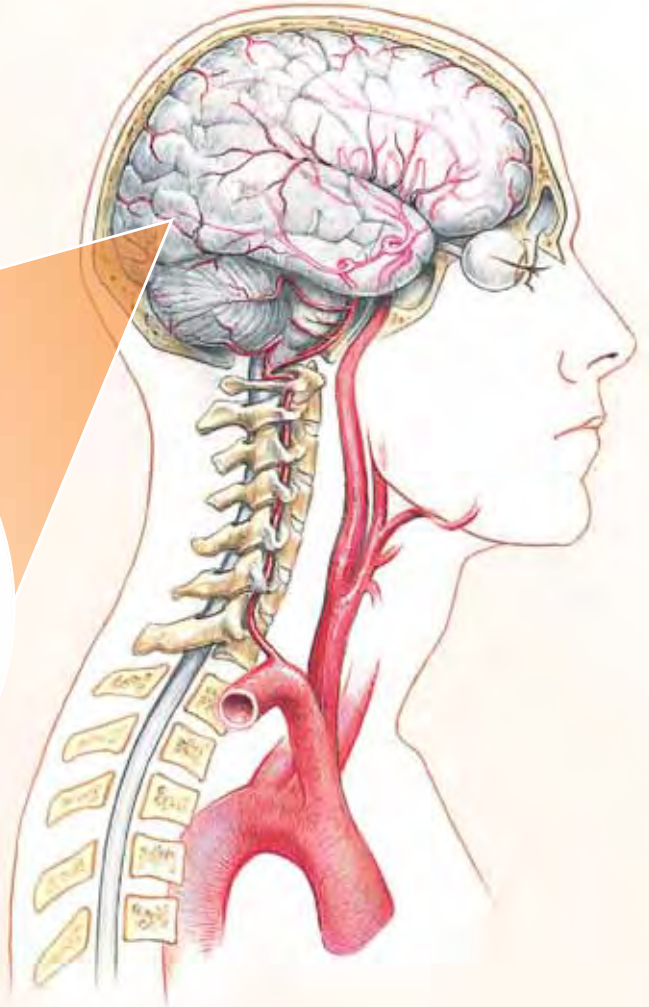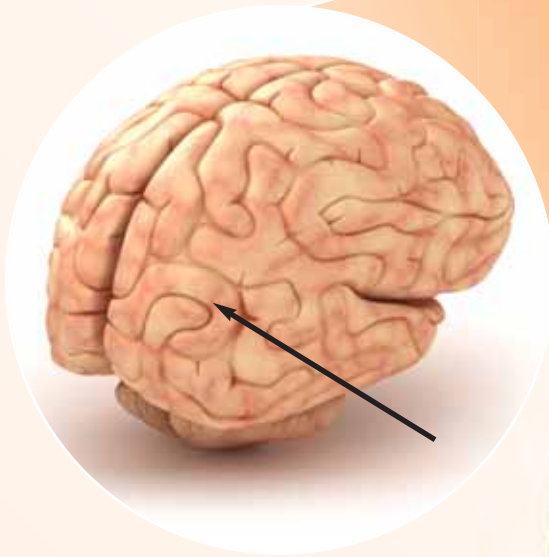Qarisaup Aginninga

Qupqarvik

Lobe occipital



# Parietal Lobe



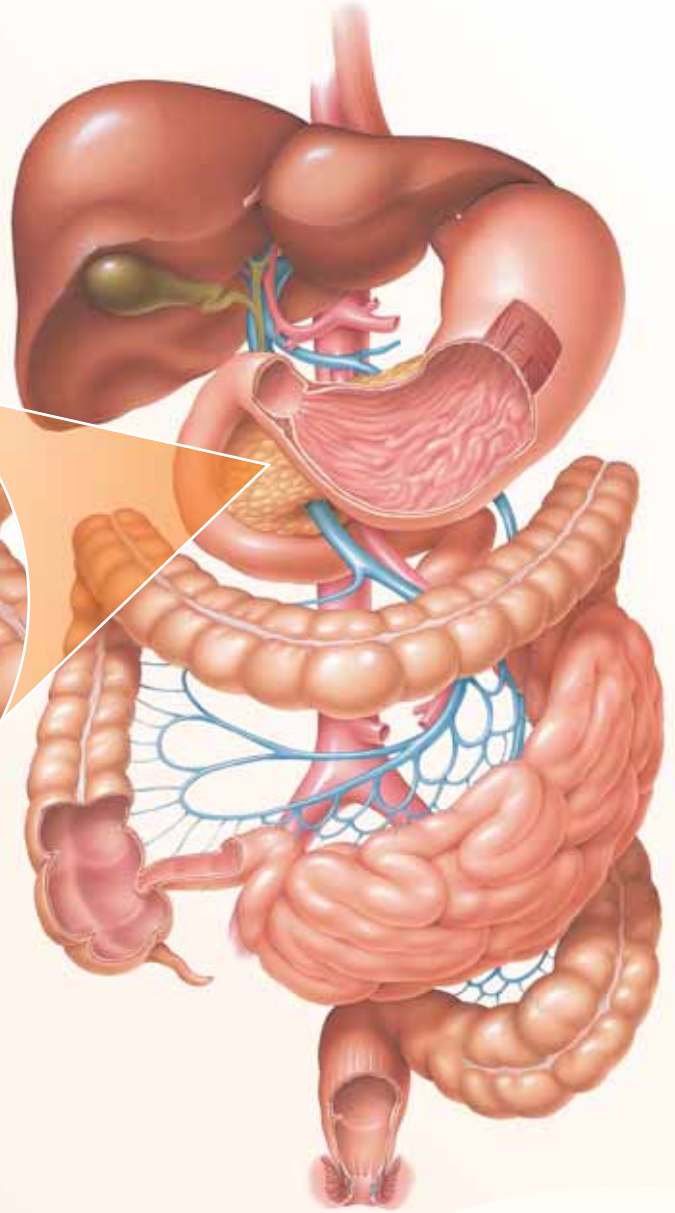
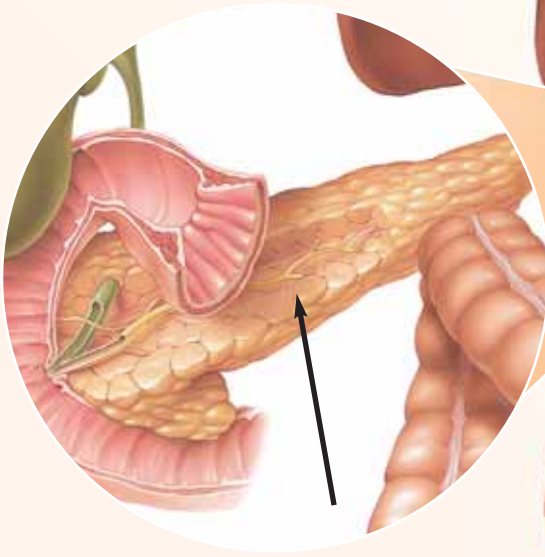>ΔJñ<sup>b</sup>d<sup>c</sup> Δ<sup>9</sup>b<sup>b</sup>▷L<sup>3</sup>↵<sup>c</sup>

Puiguriikkut Iqqaumajjut

Qitqa Qaritaup

Lobe pariétal

# Pancreas



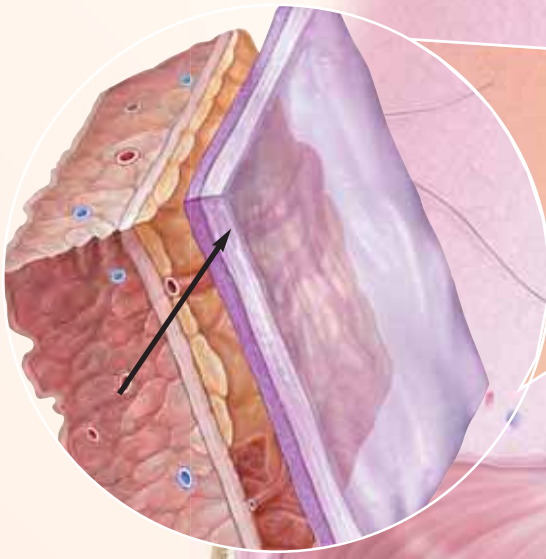
ᐱᐱᐱᐱᐱᐱᐱᐱ

Qiksalikaaq

Nigvik

Pancreás

# Pericardium



б6АPԳԵ

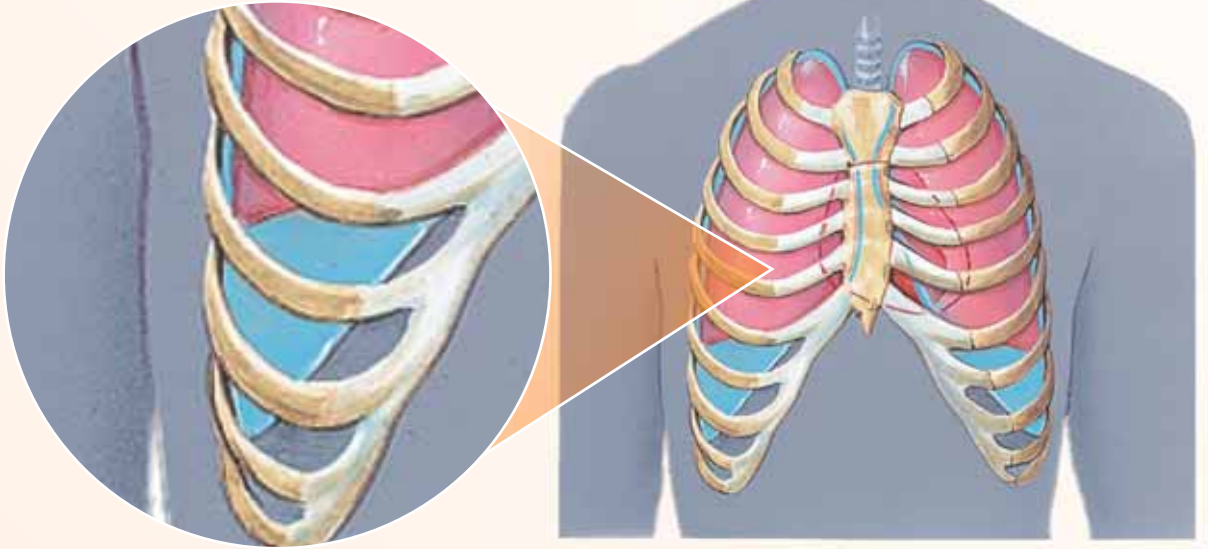
Kavisiq

Kapihiaq

Péricarde



# Pleura



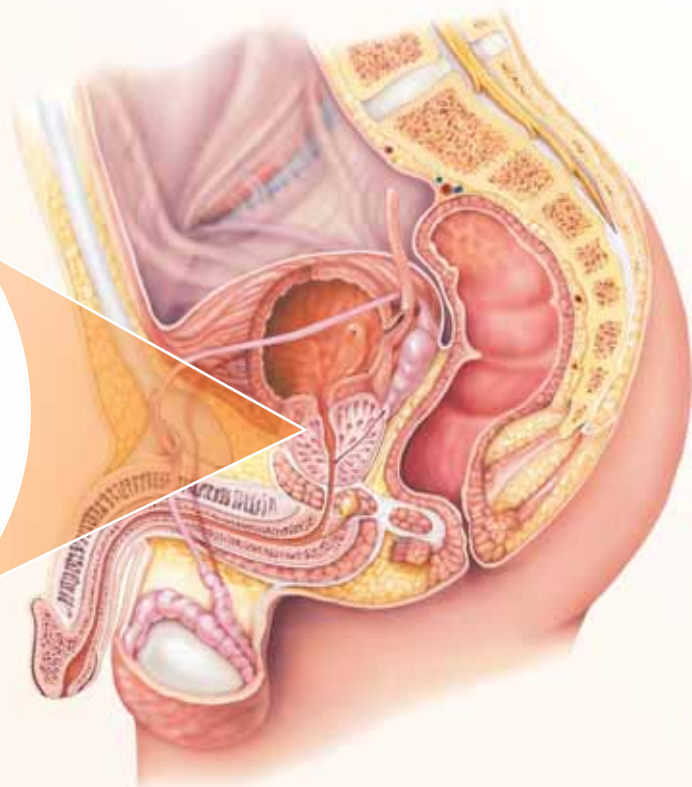
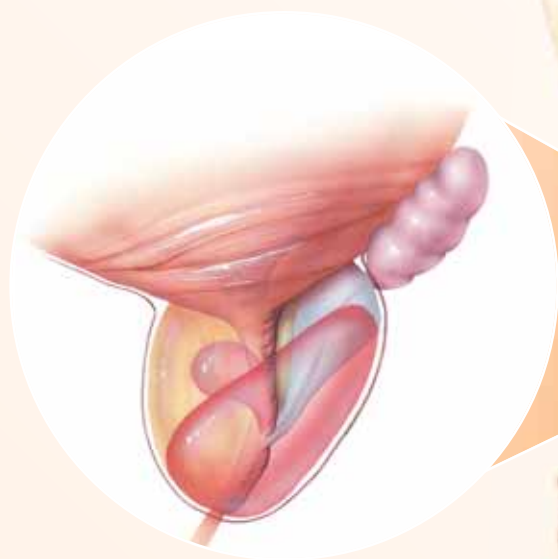
ᐱᐅᐅᐅᐅ ᐱᐅᐅᐅᐅ

Puvaup Qaapaanga

Maminguyaq

Plèvre

# Prostate



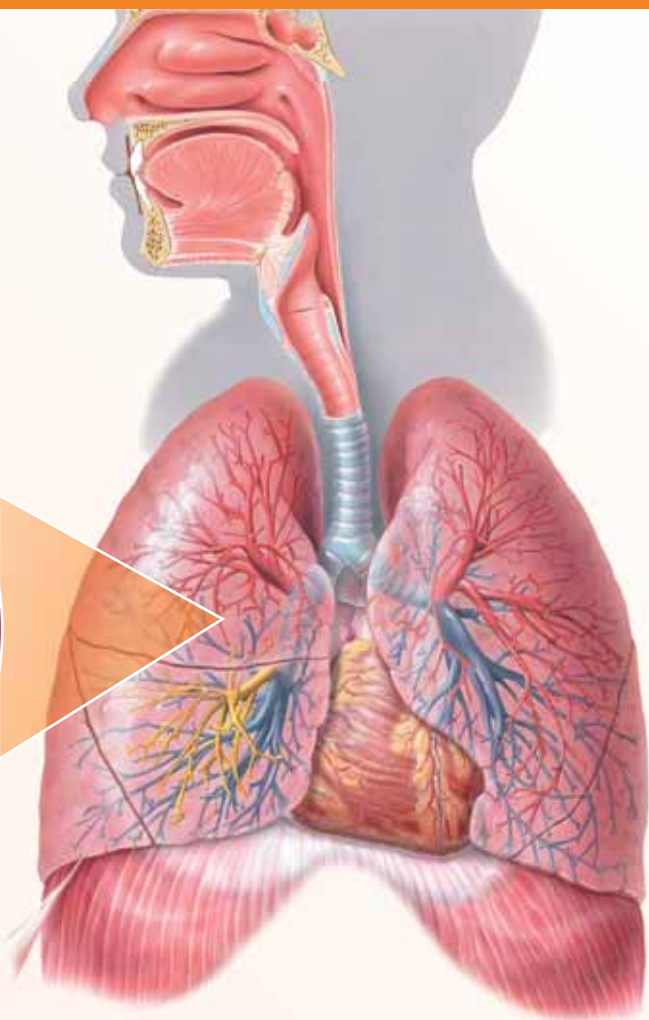
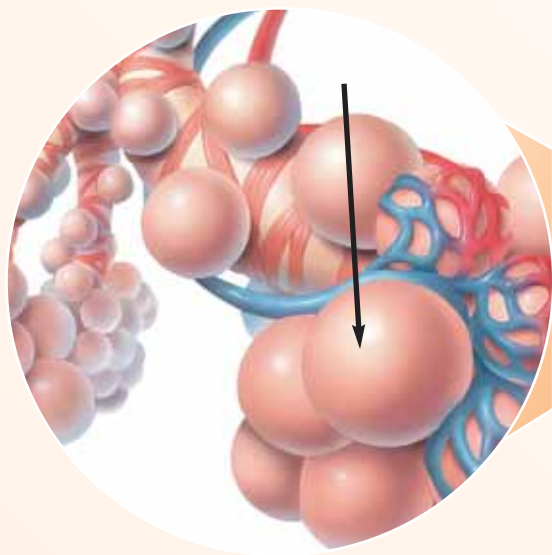
ᑭᓄᓄᓄᓄᓄᓄ

Sungiliq

Nunudjut

Prostate

# Pulmonary Alveolus



ᓄᓴᑦᓄᑦᑦᑦᑦ

Nuviqłuit

Anniqhaaktarniup

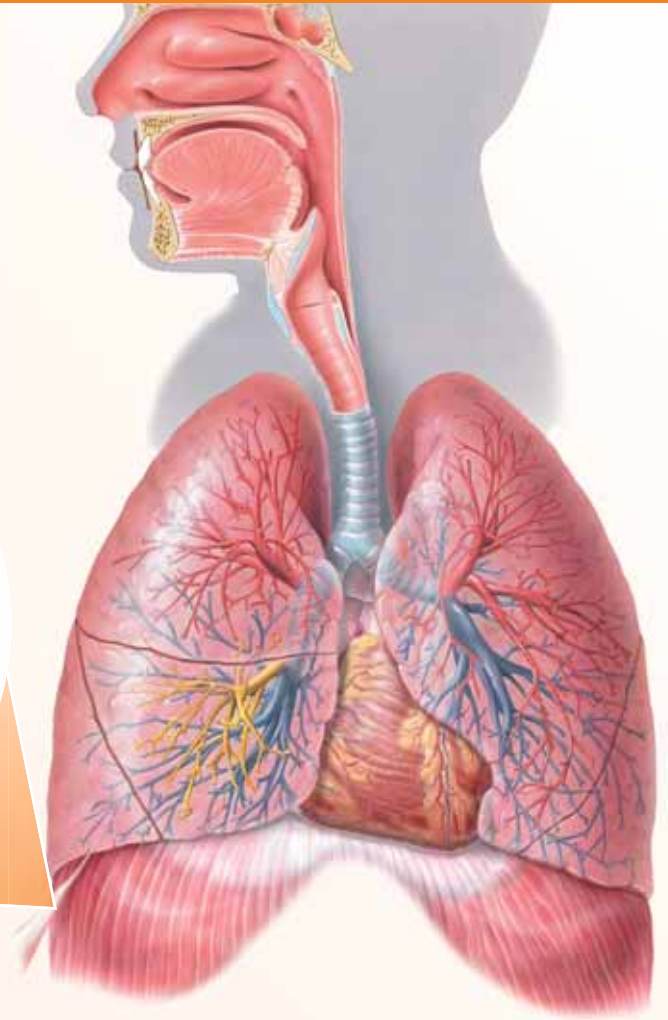
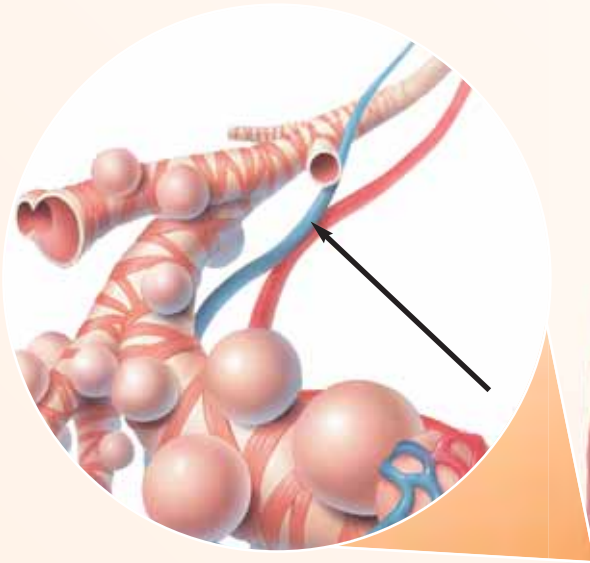
Halummaqhitait

Alvéole pulmonaire





# Pulmonary Vein



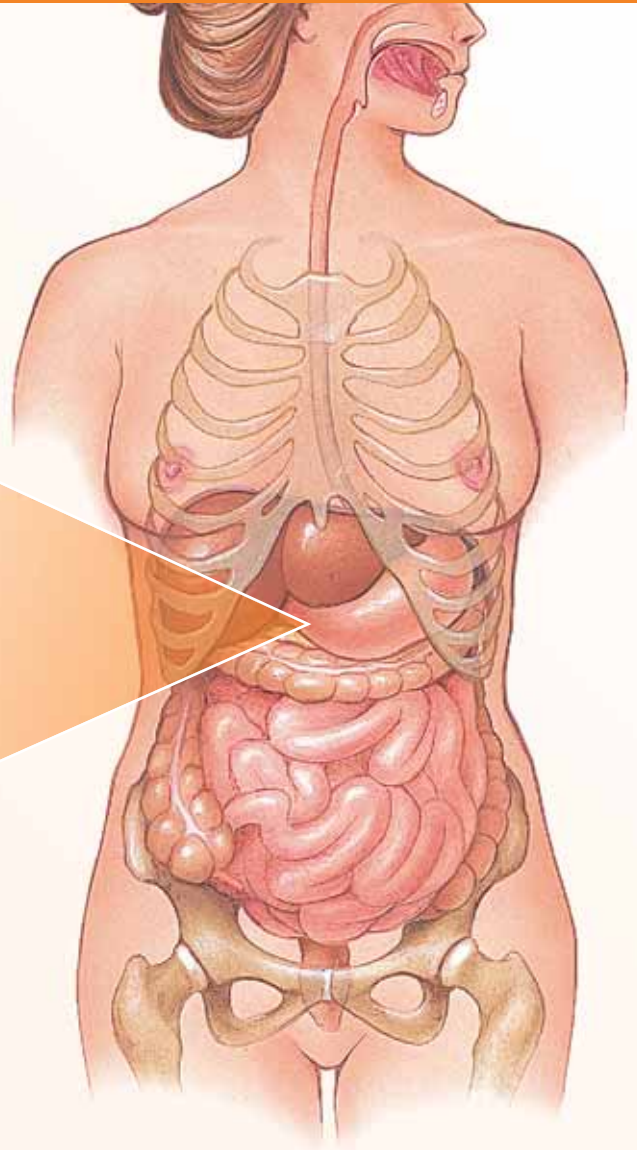
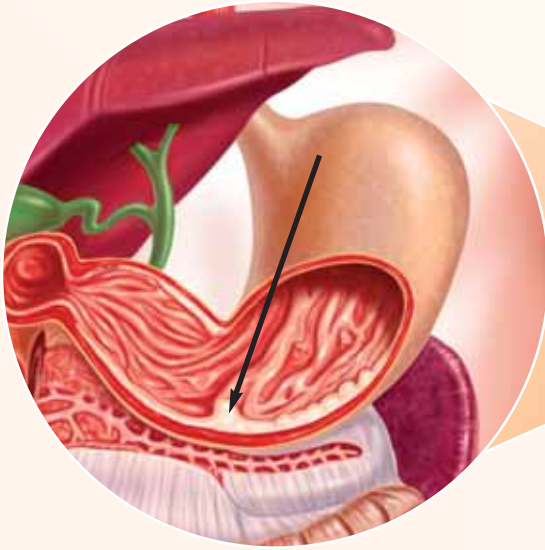ጎጂጎጎጎጎ ርፍጎጎጎ

Puvaup Taqanga

Puvaup Taqaa

Veine pulmonaire

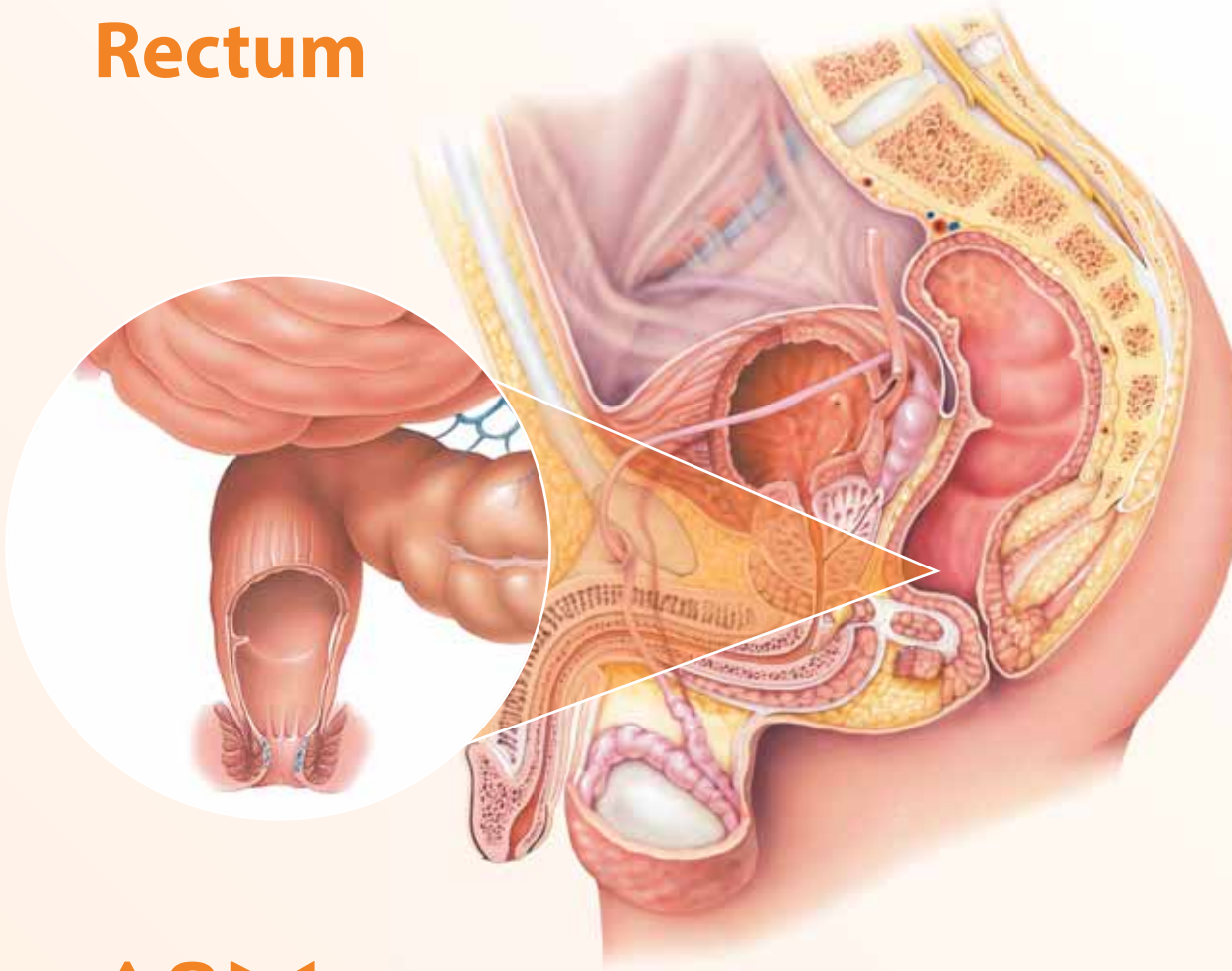
# Pylorus



ᐃᑦᓱᐃᓱᑦᓴᑦ  
ᐃᑦᓱᑦᑦᑦᑦᑦᑦ

Aqiarurmiit Aqiglisarvia  
Natiqhinak  
Pylore

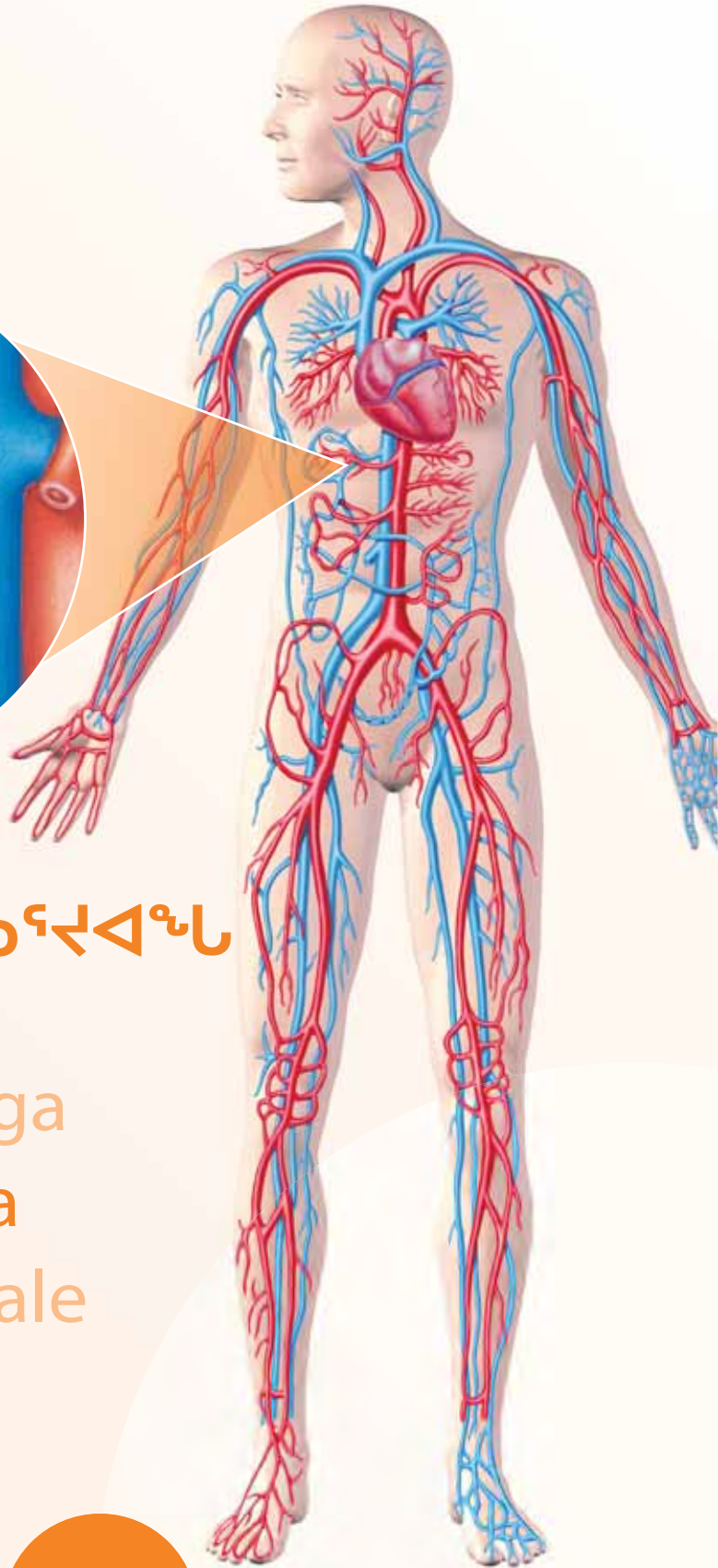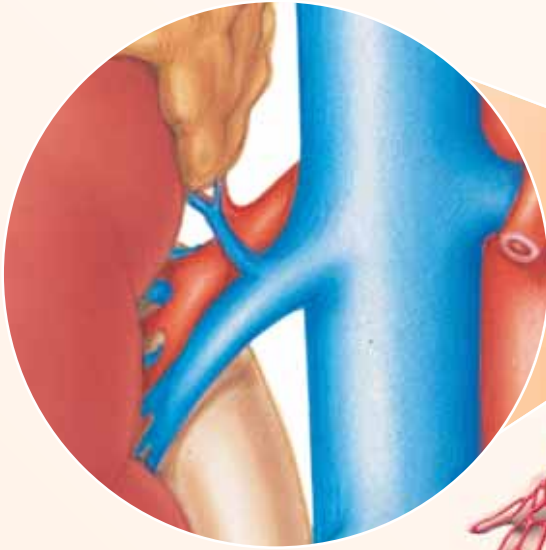
# Rectum



ΔΝΔ<  
Δ&ΓΔÇ

Itiup Ungiutaa  
Iqhuup Kiglinga  
Rectum

# Renal Artery



ᑕᑦᑲᑕᑦ ᑕᑦᑲᑦᑲᑦᑲᑦᑲᑦ

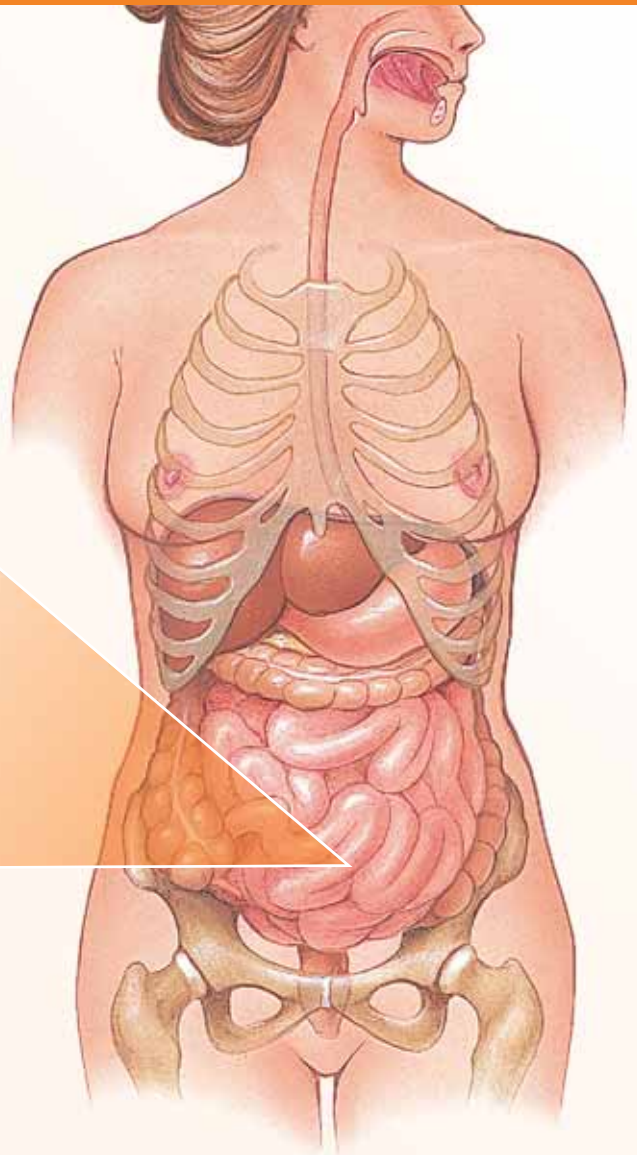
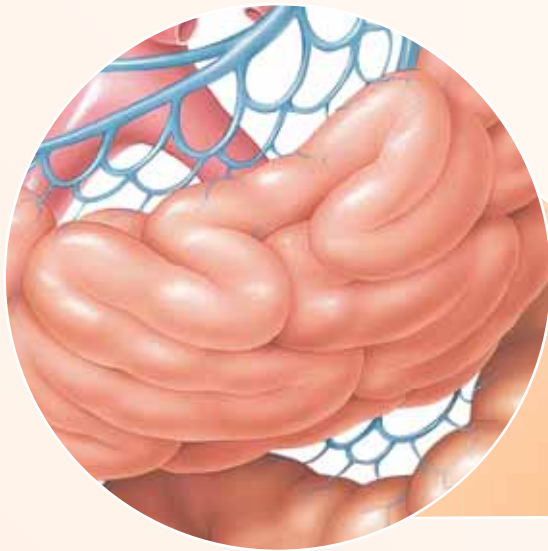
Taqtuup

Taqarjuanga

Taqaqarvia

Artère rénale

# Small Intestine



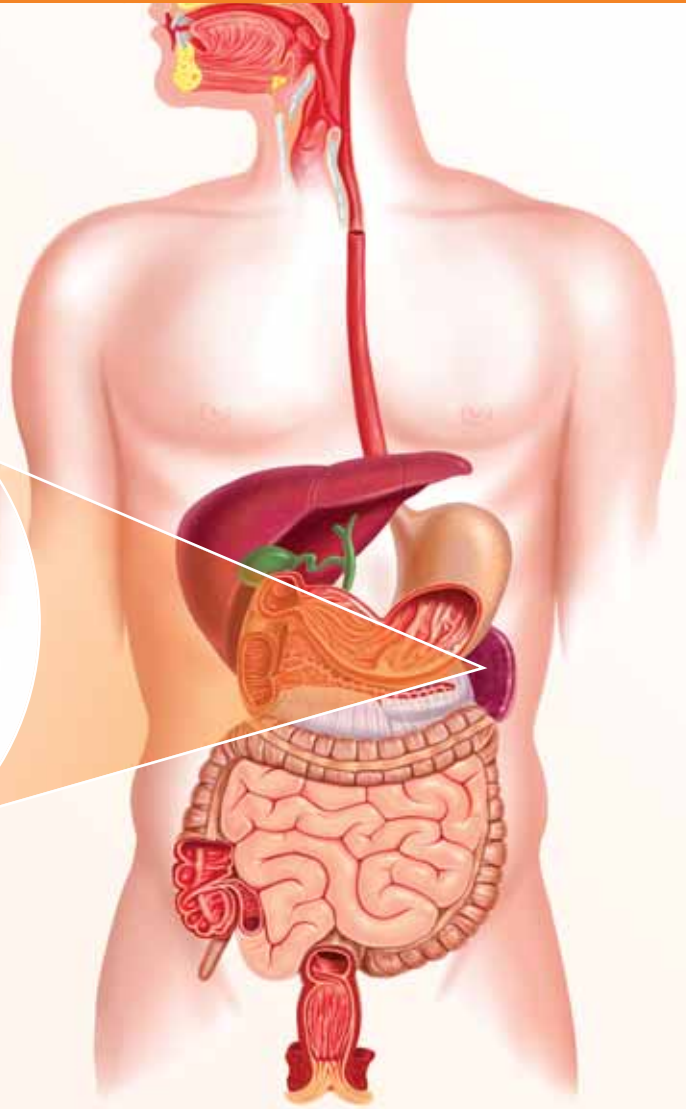
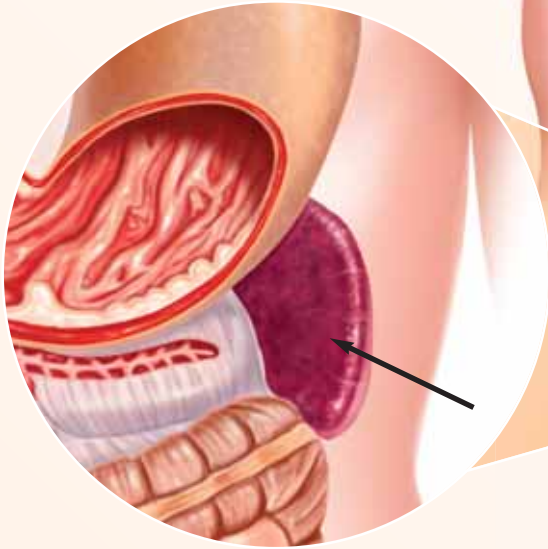
ᐃᓄᓂᐱᓂᓂ

Inaluat

Ingaluaq

Intestin grêle

# Spleen



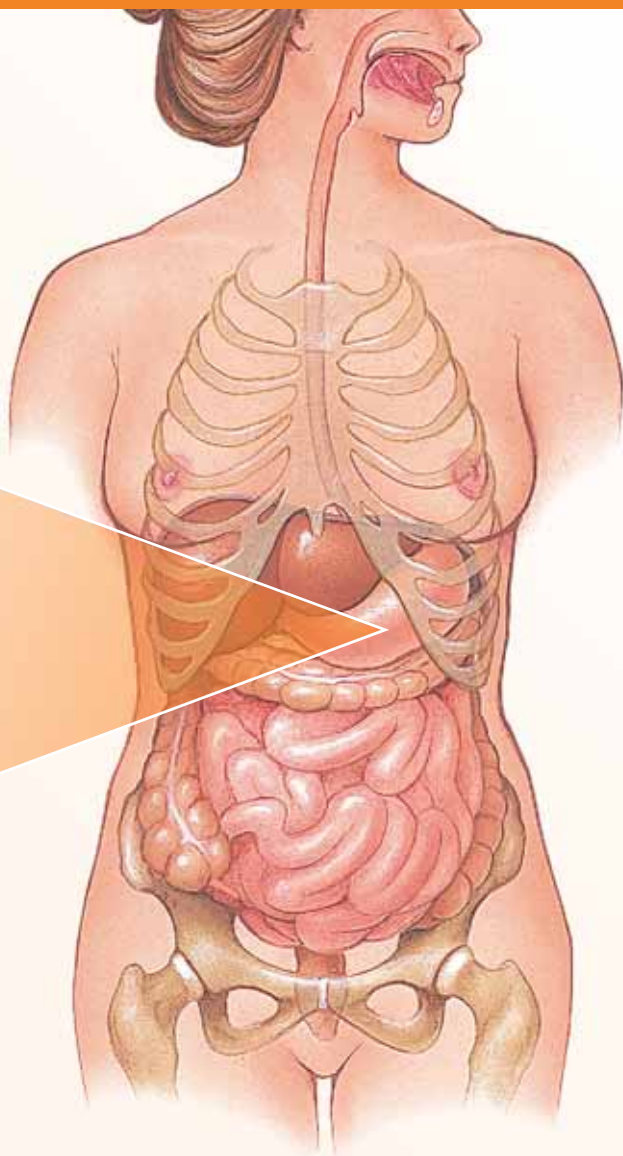
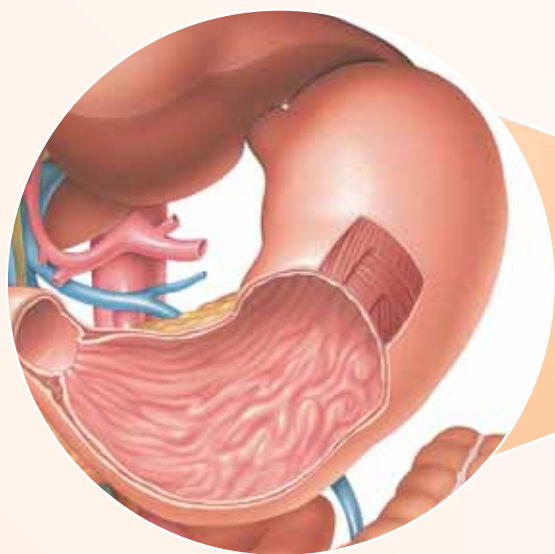
LC५

Matsa

Maffa

Rate

# Stomach



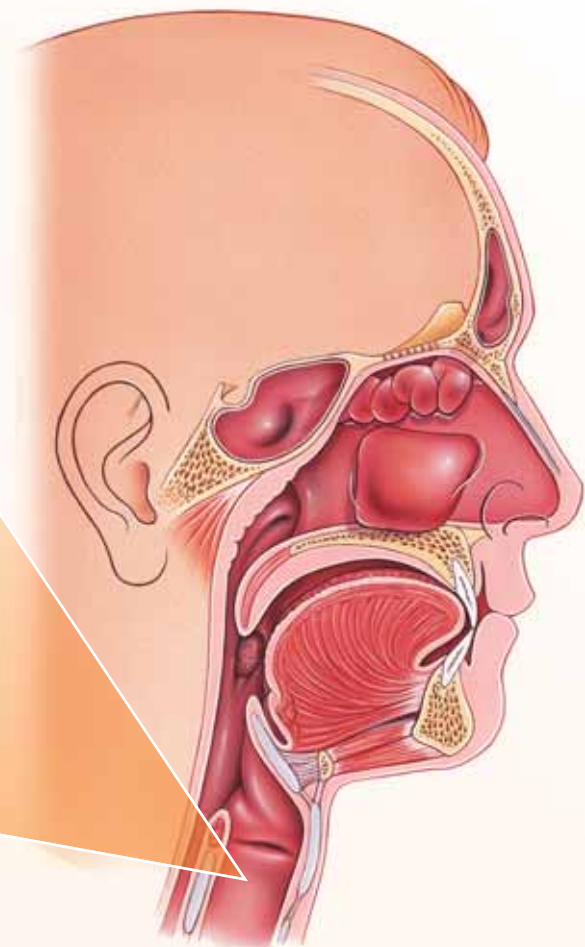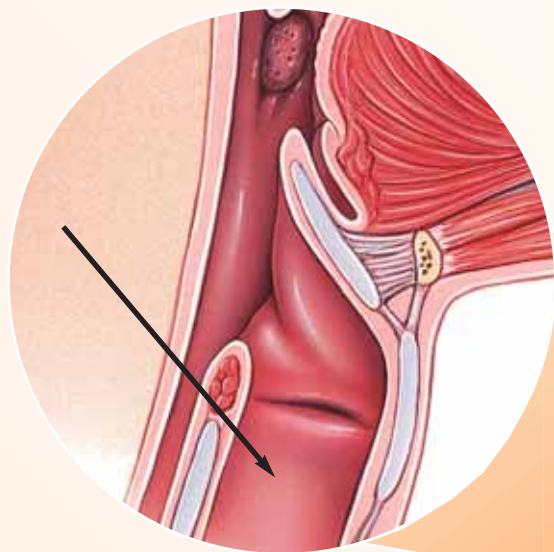
ᐱᑦᐱᑦᐱᑦᐱᑦᐱᑦ

Aqiaruq

Aqiaruq

Estomac

# Throat, Esophagus



ᐃᐅᐅᐅᐅᐅᐅ

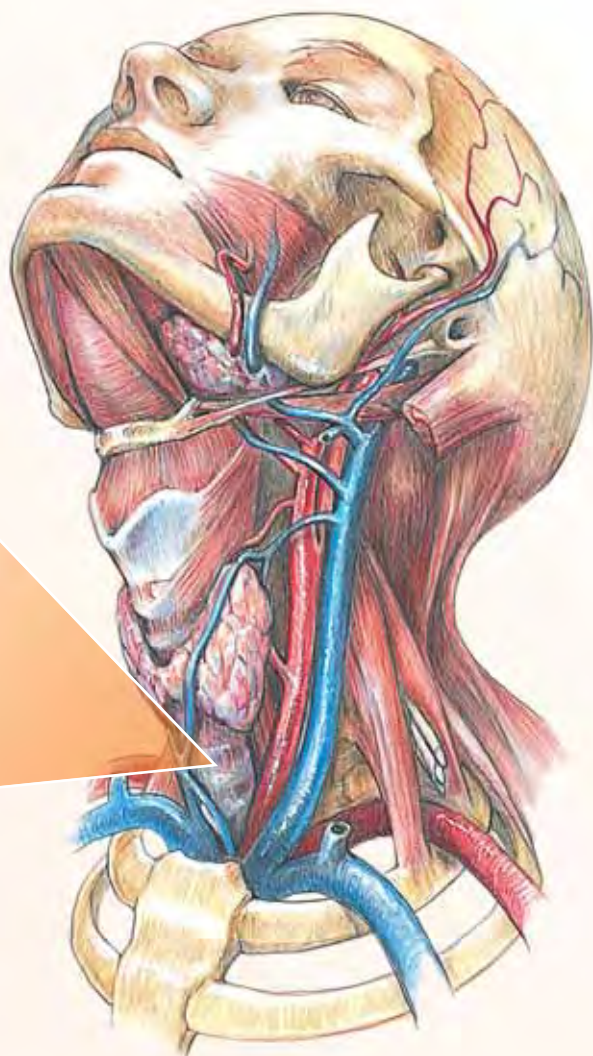
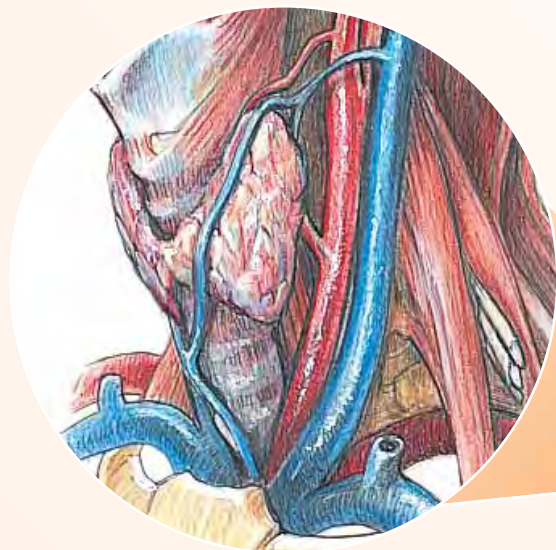Iggiaq

Tuqhuk

Gorge, œsophage



# Trachea / Windpipe



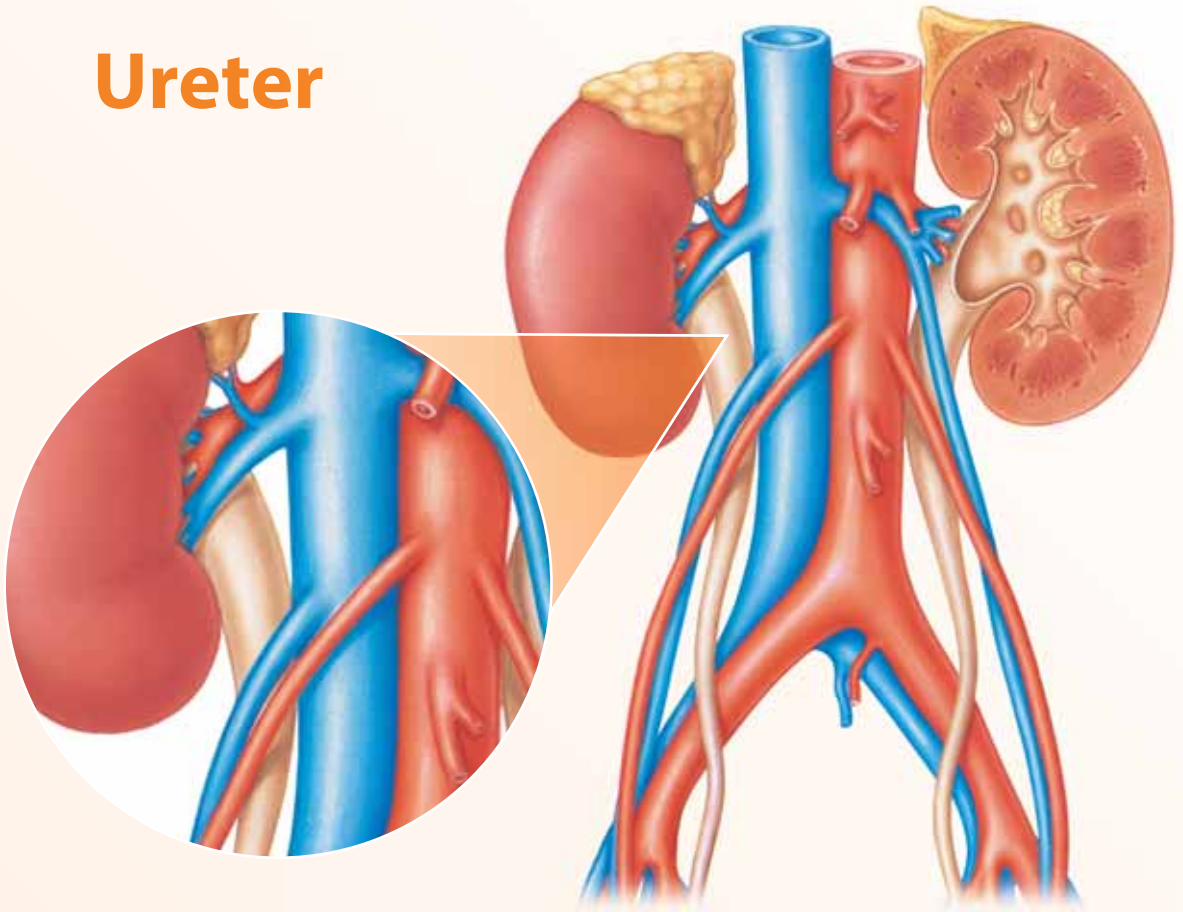
ᐅᑦᑲᑦᑲᑦ

Tuqłuk

Iggiapquq

Trachée

# Ureter



ᐸᐃᐸᐅᐃᐅ

Qurivik

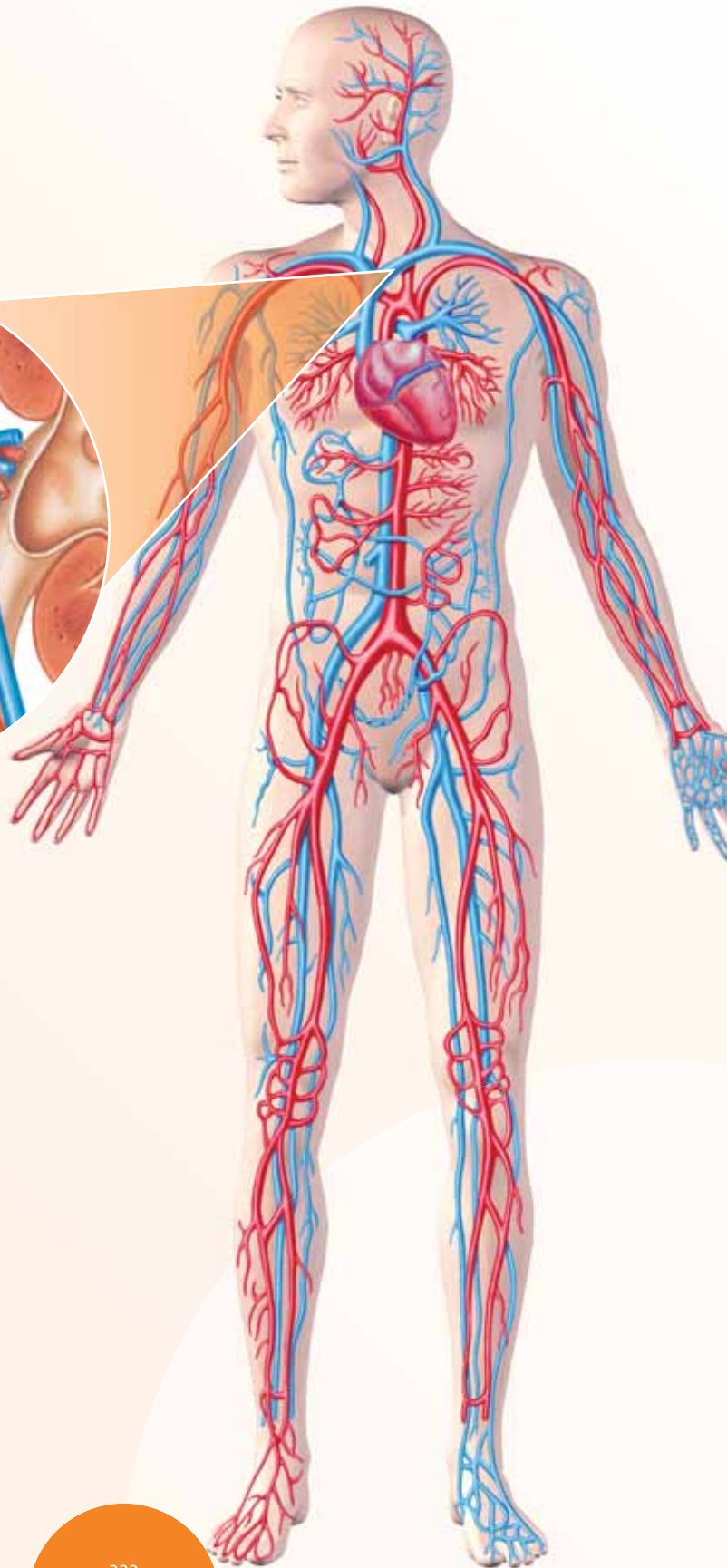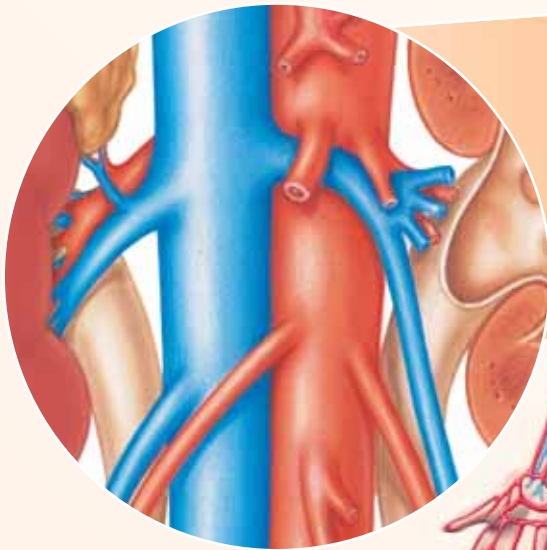
Taqtuup Tuqhuagik

Nakahungmut

Uretère



# Vein



Сʻб<sup>б</sup>

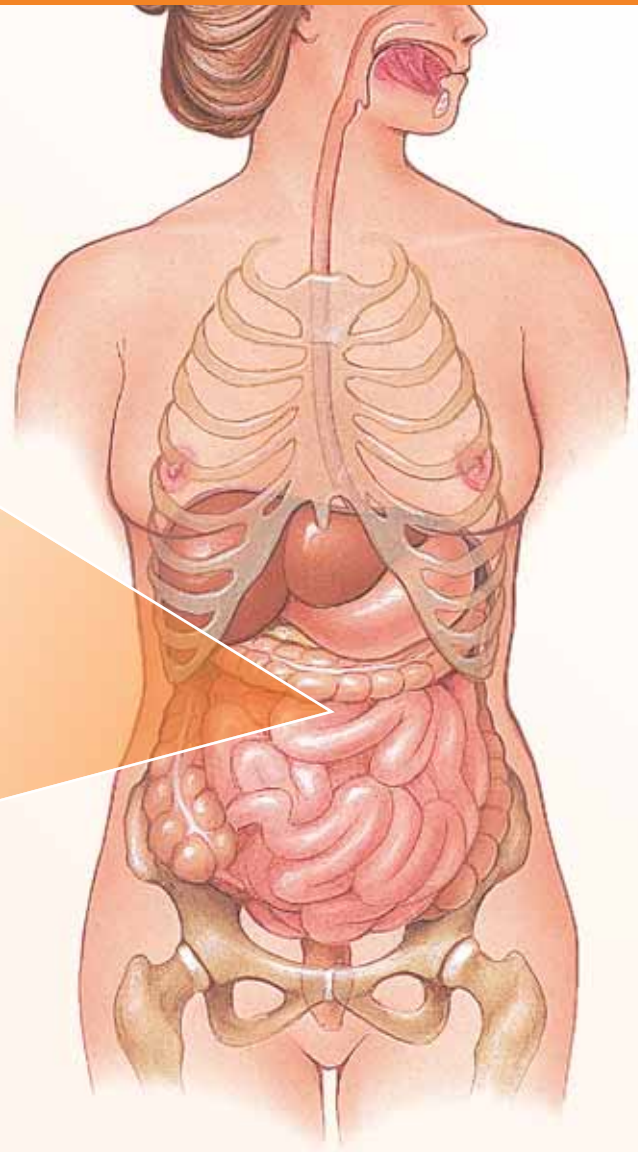
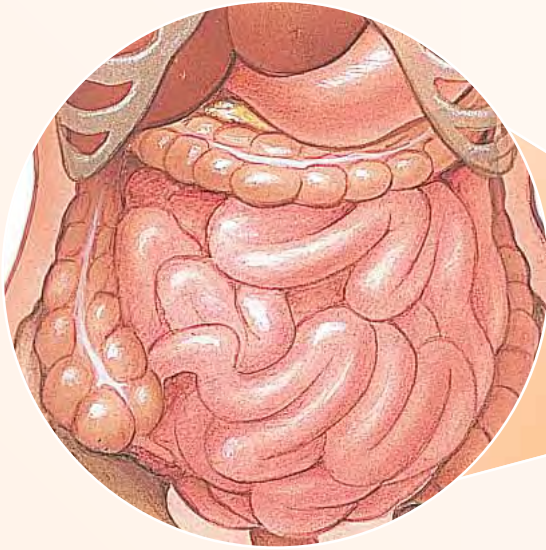
Taqak

Taqak

Veine



# Viscera



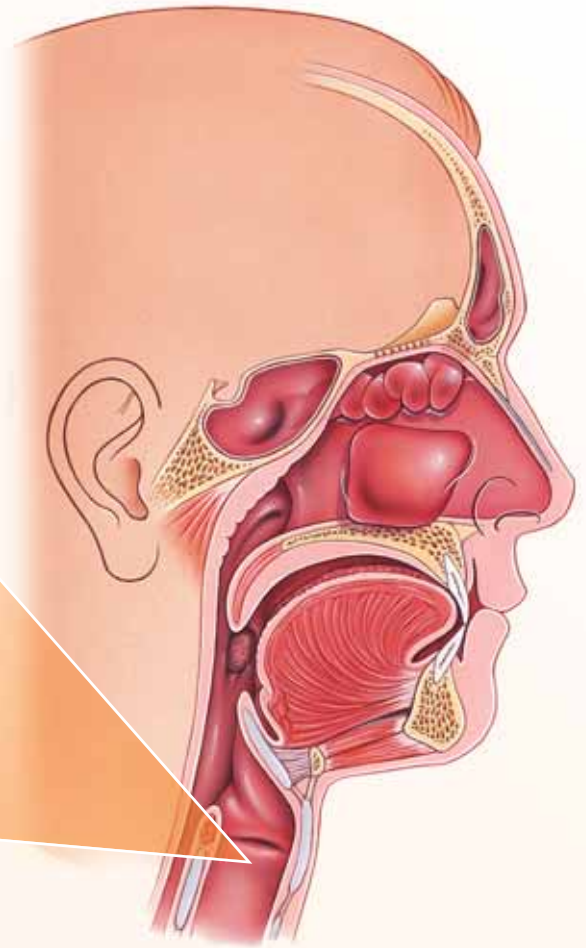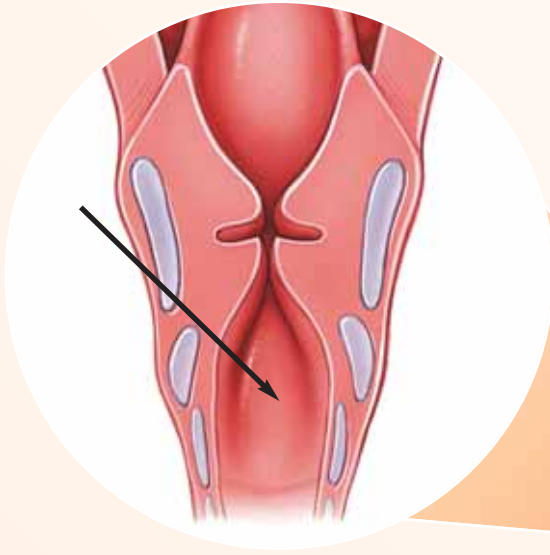
ᐃᑦᑦᐃᑦ

Irraviit

Ilraviqarvik

Viscères

# Vocal Cords



σΛ⁹b▷ᶜ

Nipiqaut

Nipiqarvik

Cordes vocales





# Skeletal System

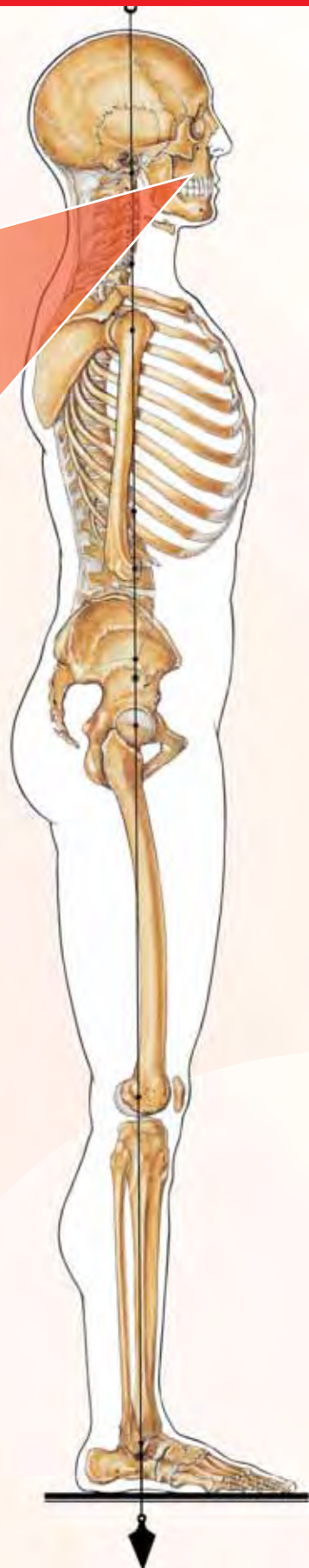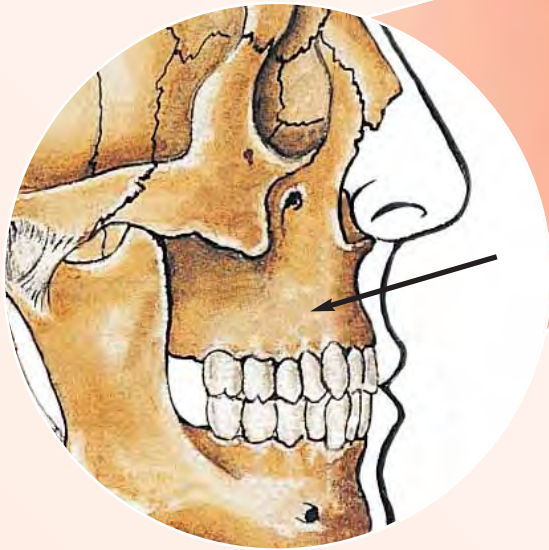
ህጋዕር

Sauniit

Timip Hauniit

Squelette

# Alveolar Bone



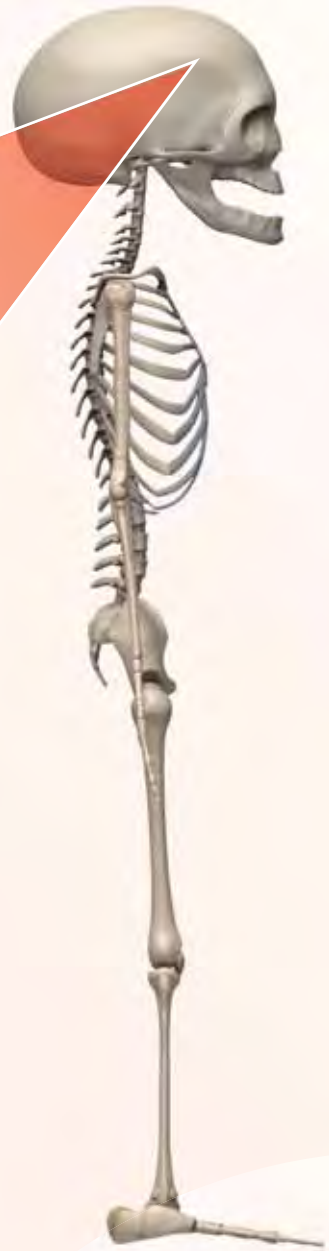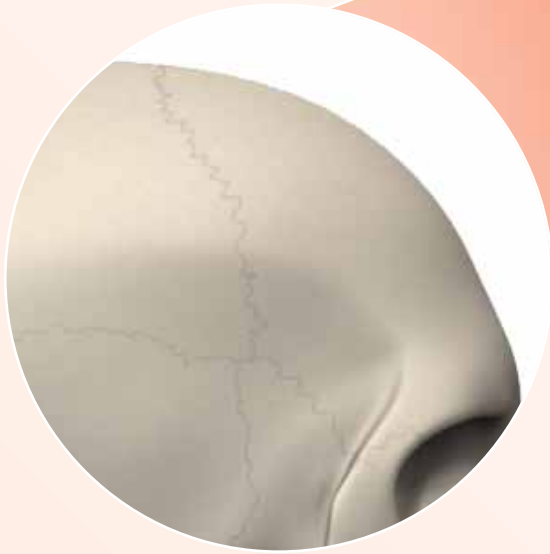ᐱᑭᑭᑦᑲᑦ

Kigusirvik

Kigutiqarviik

Os alvéolaire,  
arcade dentaire

# Anterior Fontanelle



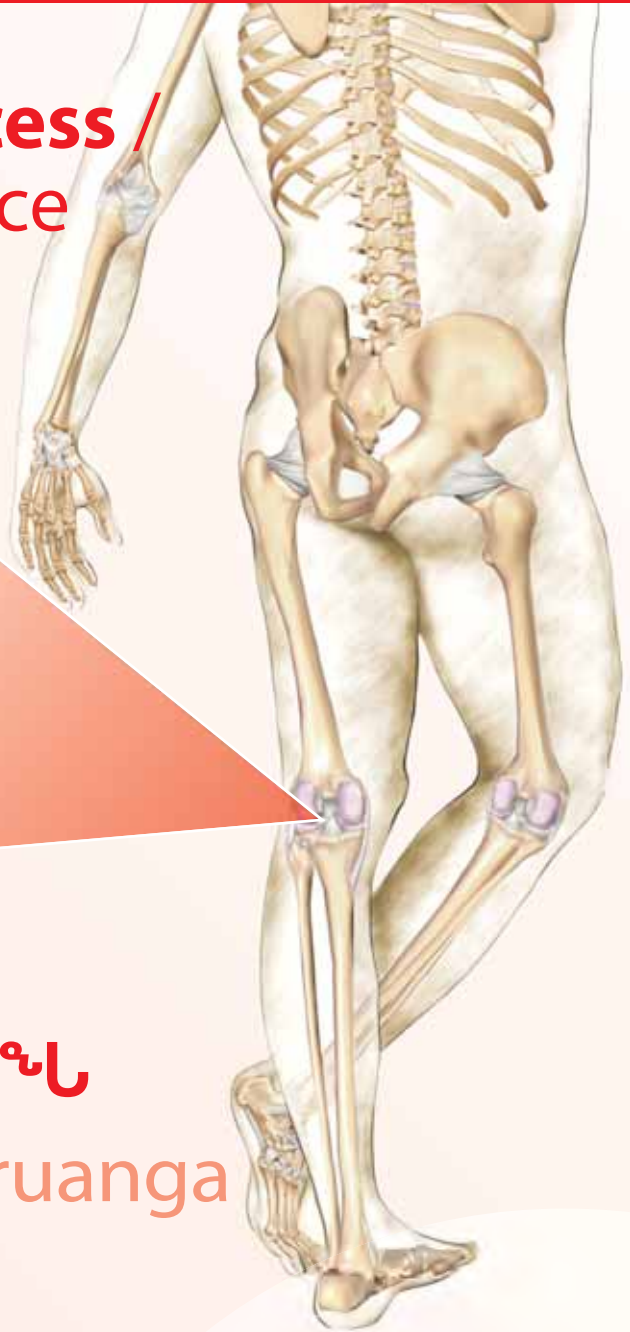
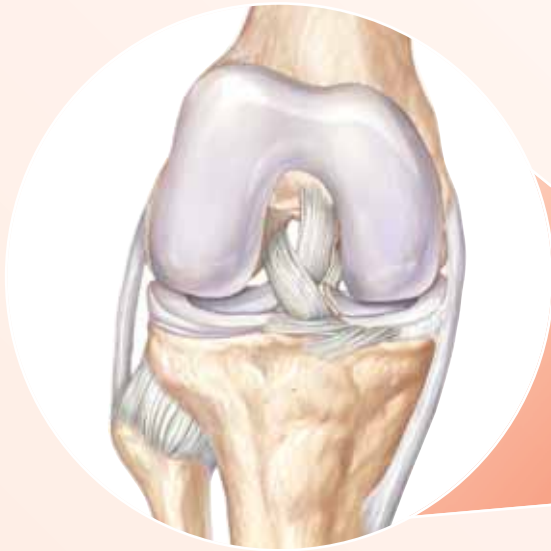Δῆβἄἔ ἄἔσῆ

Iqsaup Sauninga

Tiglingniq

Fontanelle  
antérieure

# Articular Process / Articular Surface



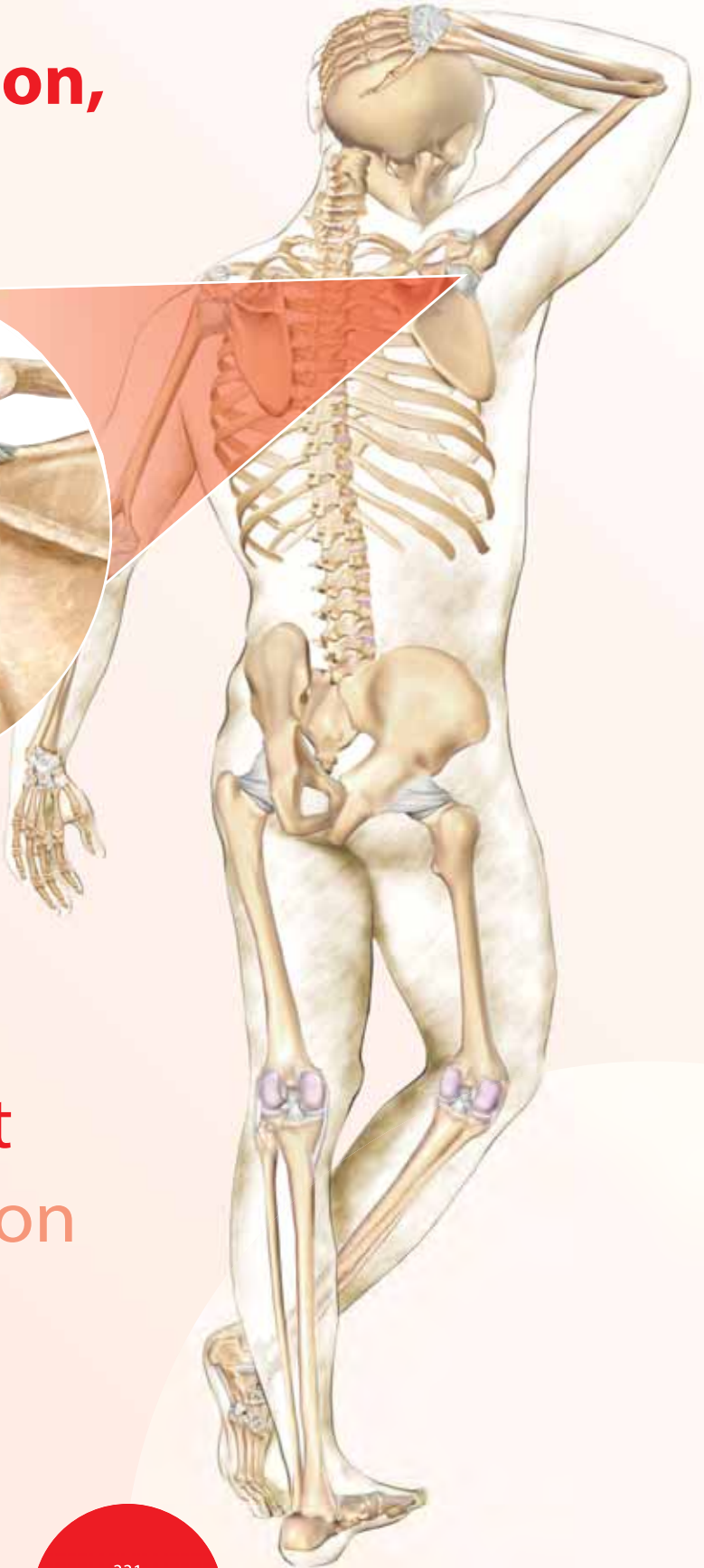
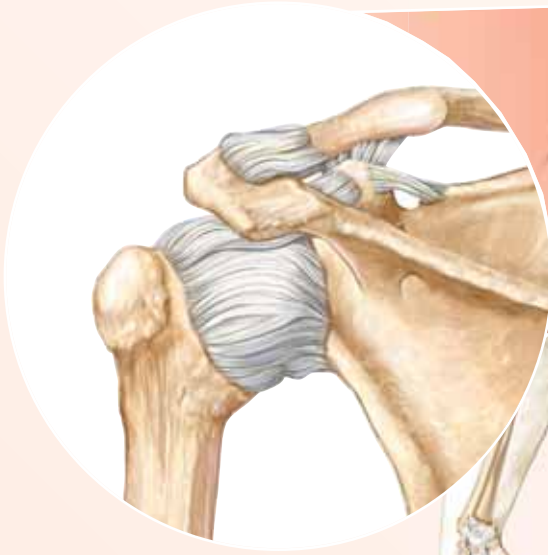
ᐃᓄᓂᓄᓂ ᐃᓄᓂᓄᓂ

Nagguap Imaruanga

Ipiringniq

Processus  
articulaire, surface  
articulaire

# Articulation, Joints



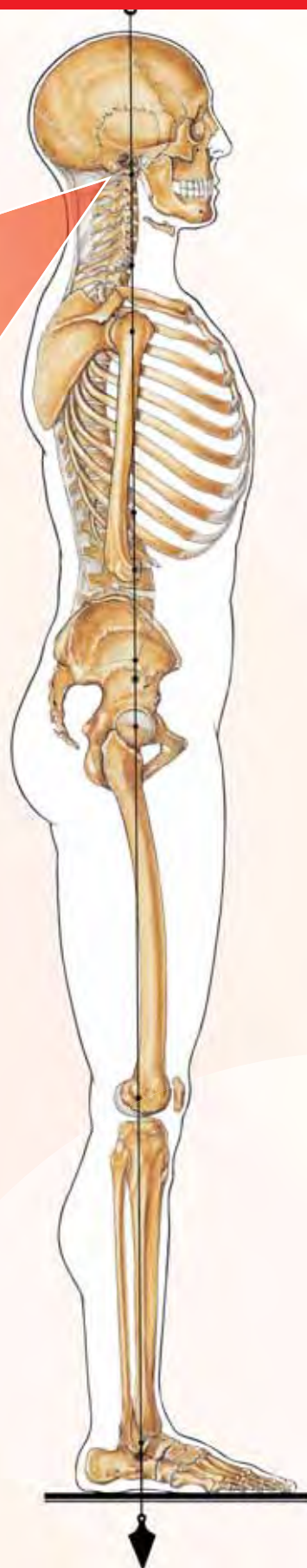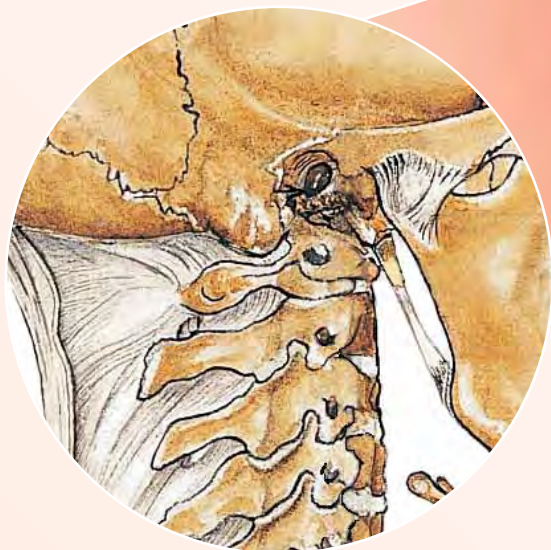ᐅᓴᓂᐱᑦ

Nagguat

Ipiringniit

Articulation

# Atlas / 1st Cervical Vertebra



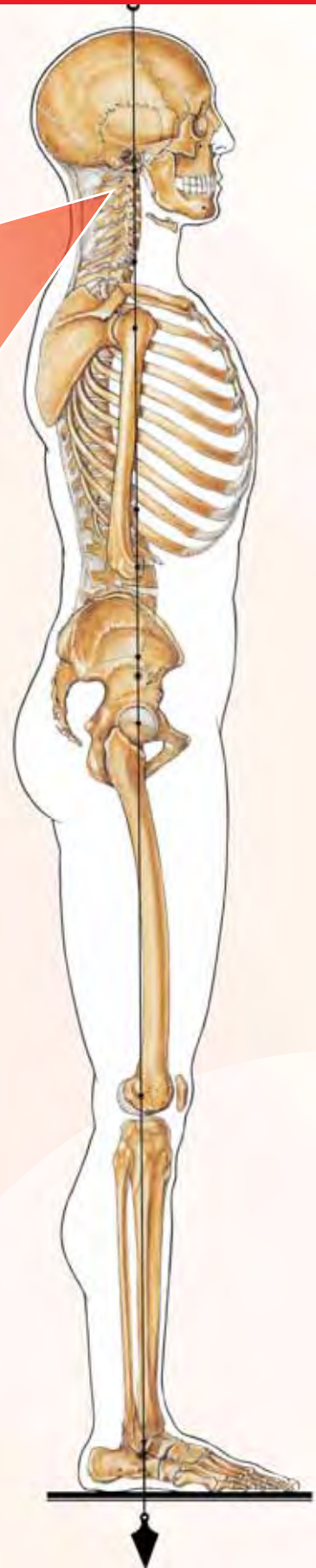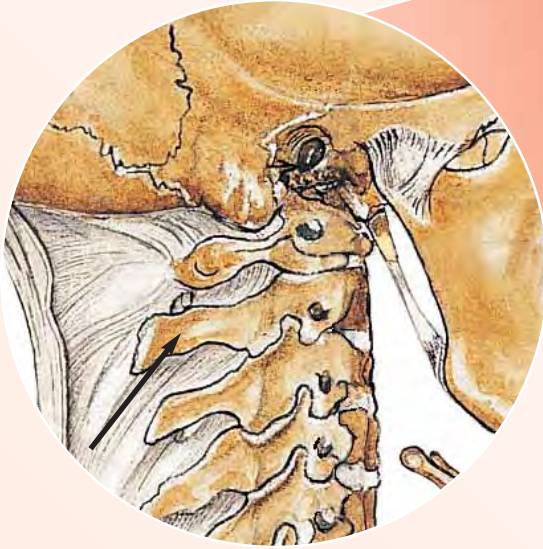σ▷C<sup>1b</sup>

Niuliq

Niuliq

Atlas (1<sup>re</sup> vertèbre  
cervicale)

# Axis



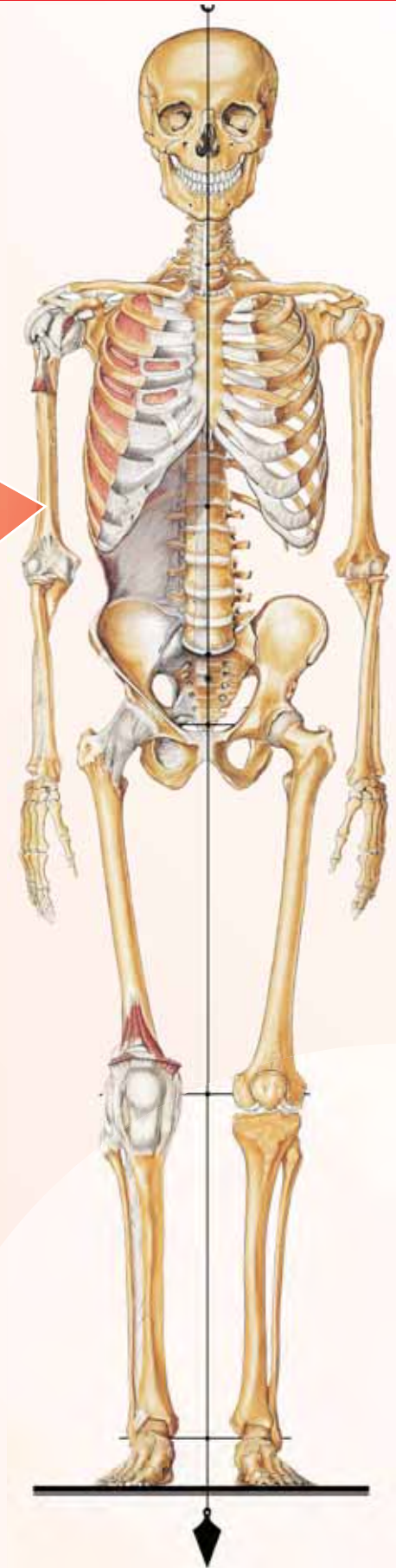
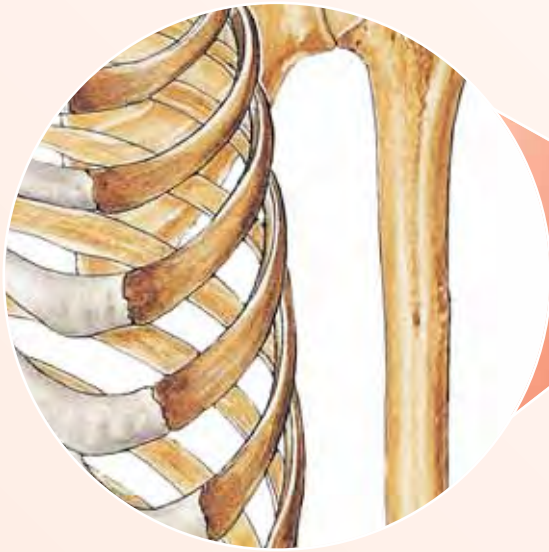
ᠲᠦᠨᠭᠠᠰᠢᠴᠢ

Qungasiq

Niuliq

Axis

# Bone



ᄎᄎᄎᄎᄎᄎ

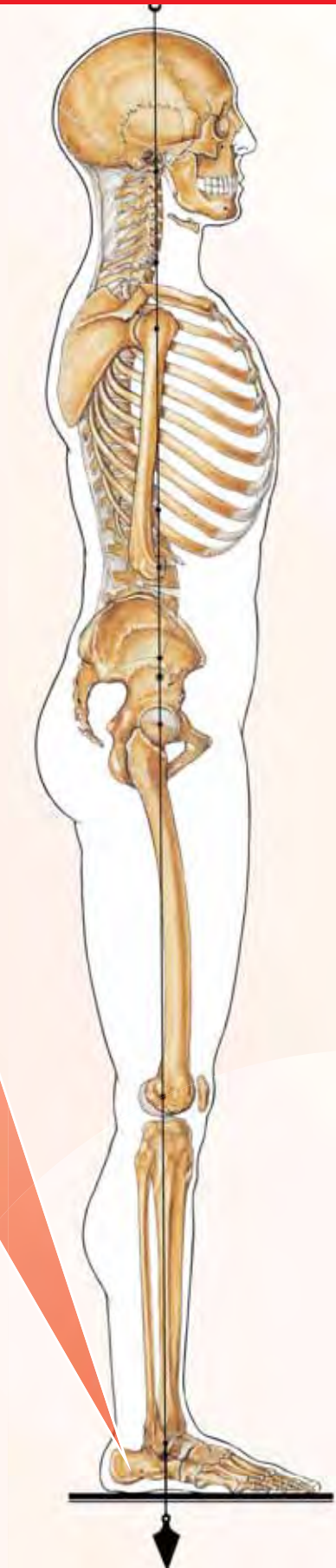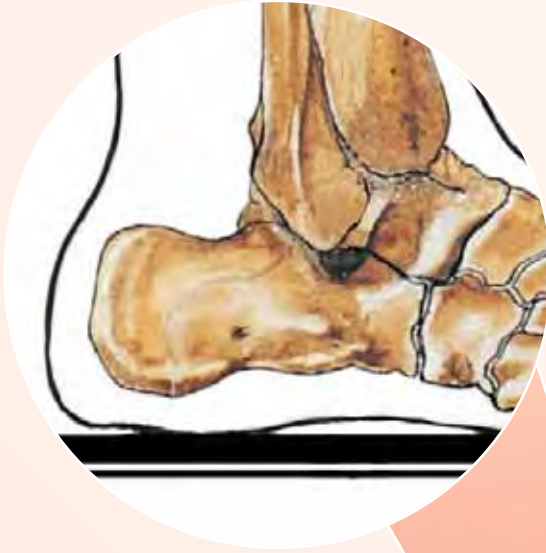Sauniq

Hauniq

Os



# Calcaneus



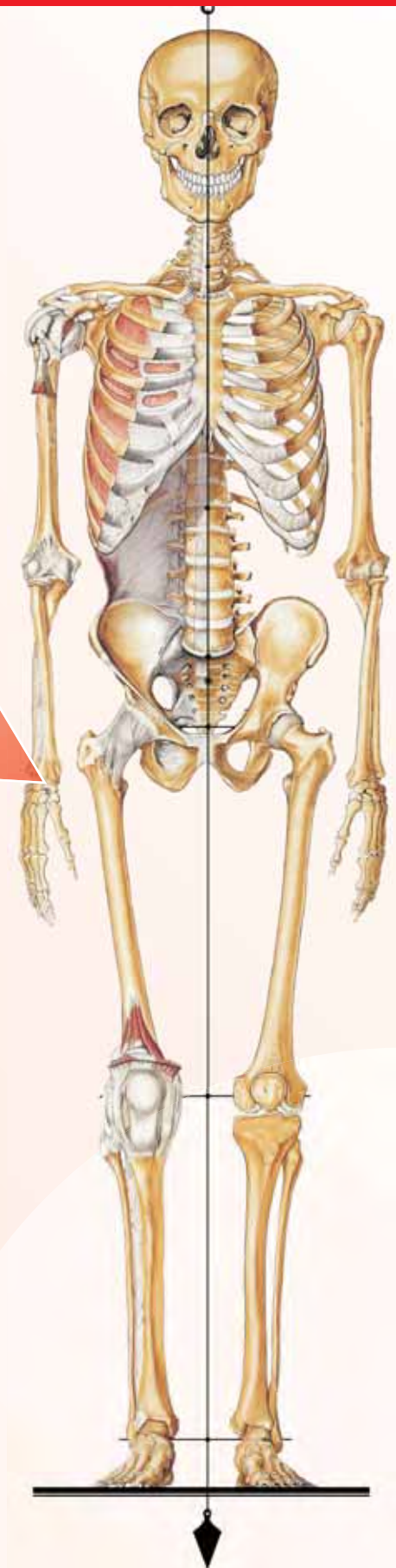
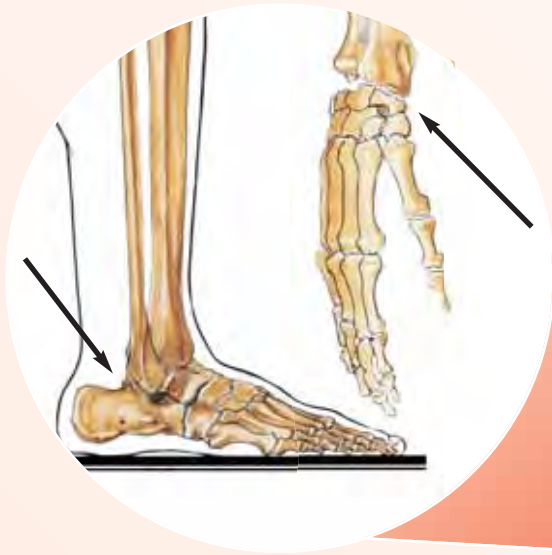ԲՆԴՆ

Kingmik

Kingmitquq

Calcaneus

# Carpus / Tarsus



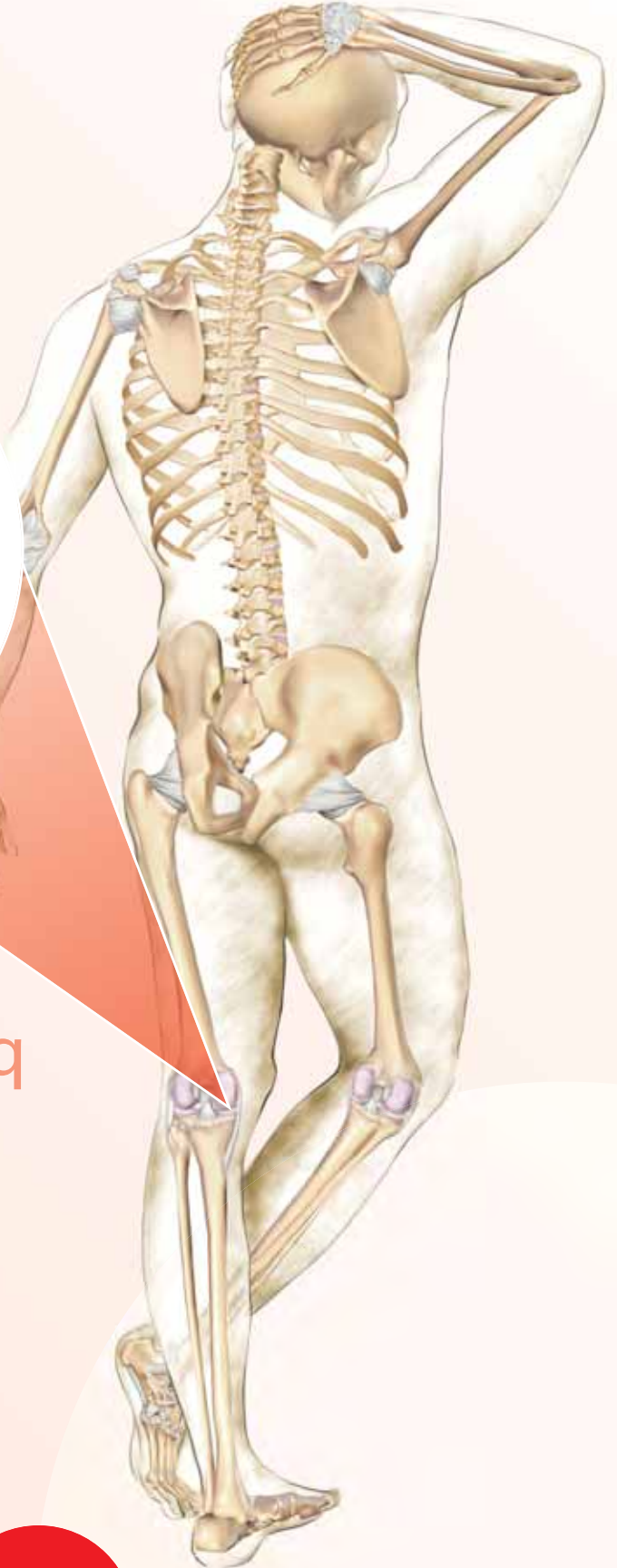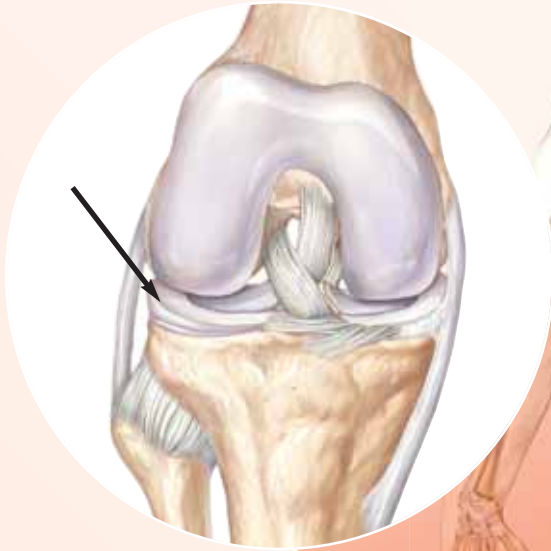
< 6 b

Pagvik

Palviit / Ihugluk

Carpe / tarse

# Cartilage



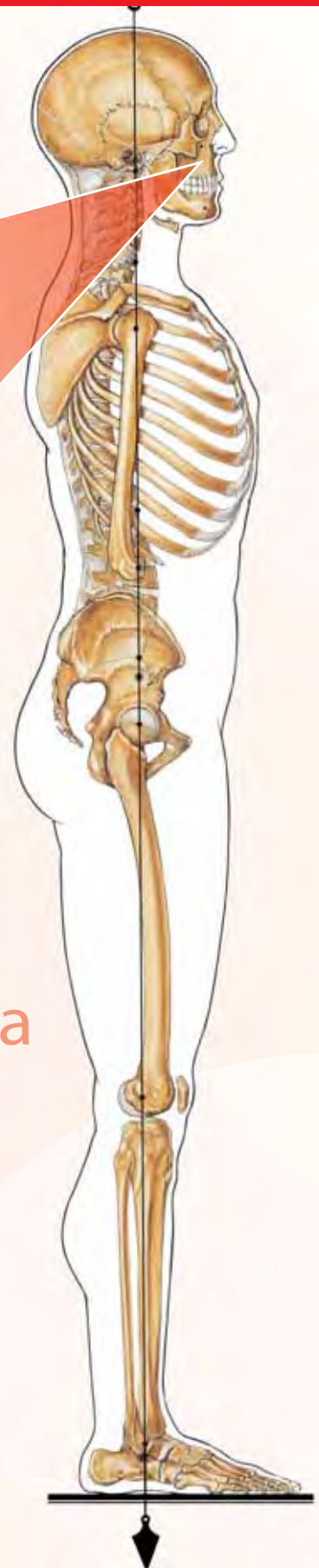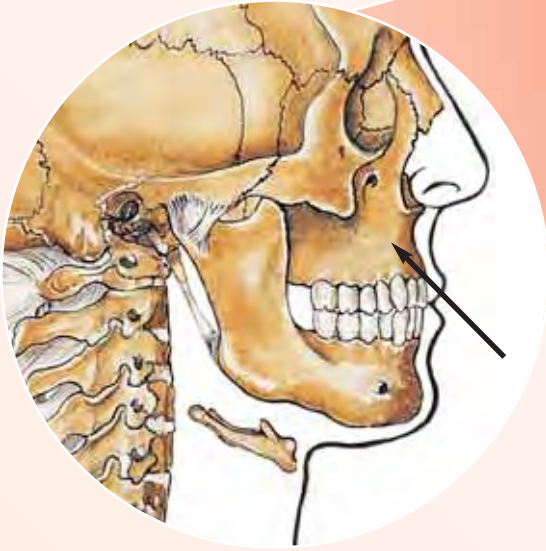ᐅᑕᖃᑦᑦᑕᖃ

Nataqqulaaq

Qaqqulaaq

Cartilage

# Centre of Upper Jaw



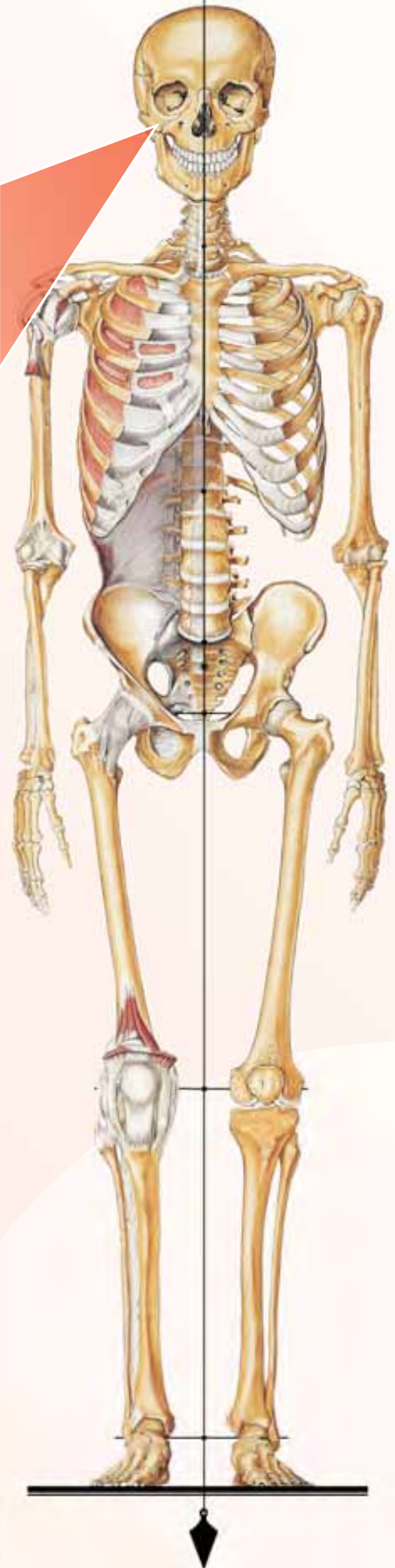
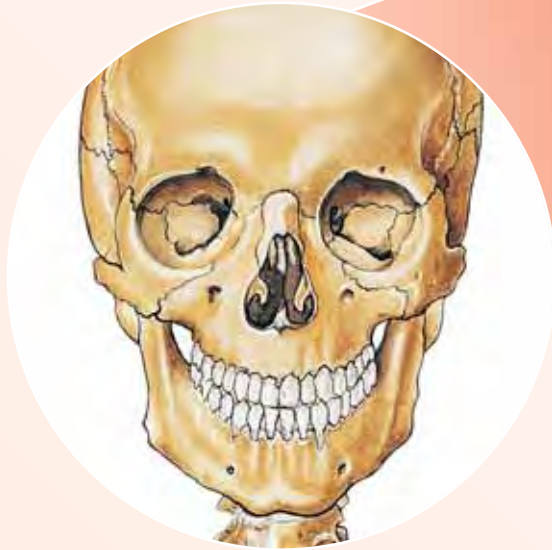ᑭᑭᑭᑭᑭᑭ ᑭᑭᑭᑭᑭᑭ

Kakkiviap Sauninga

Umiitik / Umiutik

Maxillaire  
(ou mâchoire  
supérieure)

# Cheekbone



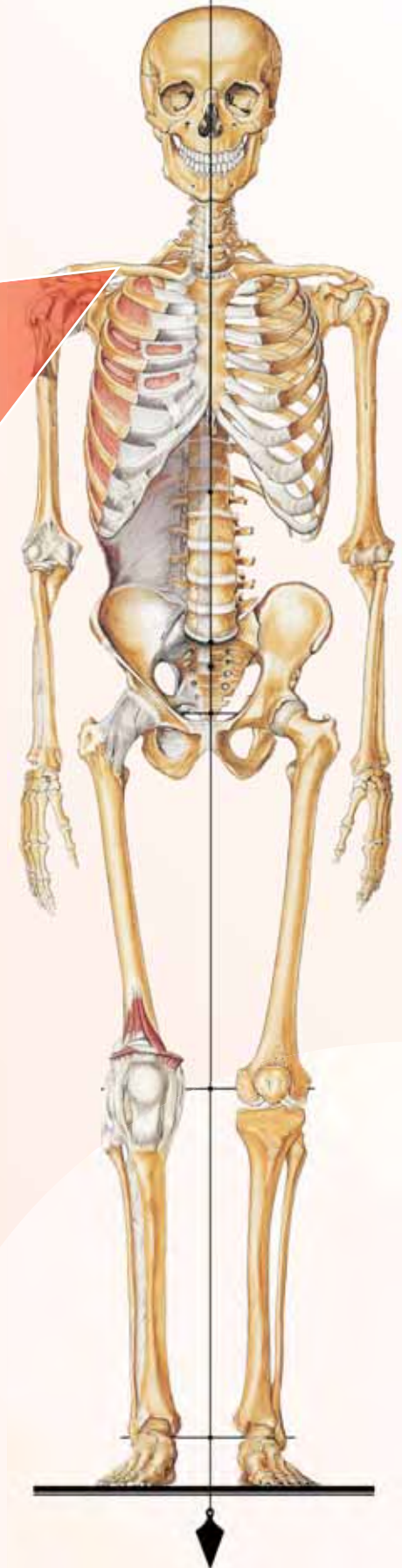
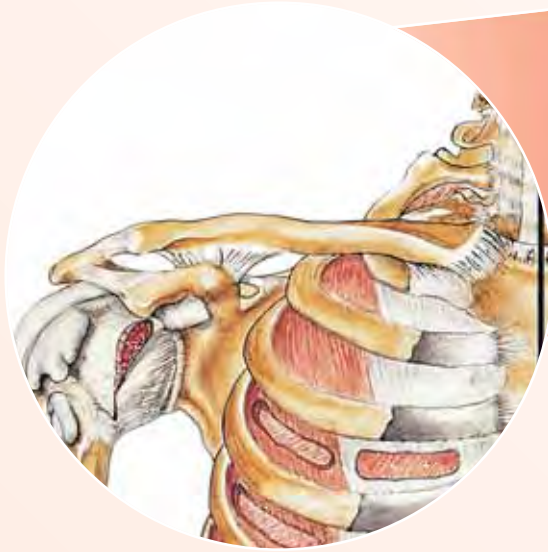
ՃՆՎ՛ ԿՃՏ՞Ն

Uluap Sauninga

Uluangnaq

Pommette

# Clavicle / Collarbone



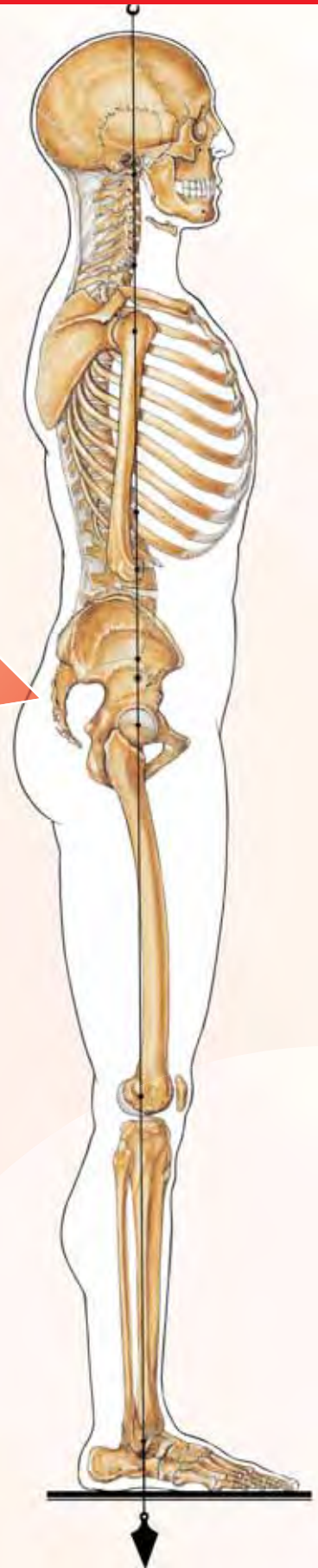
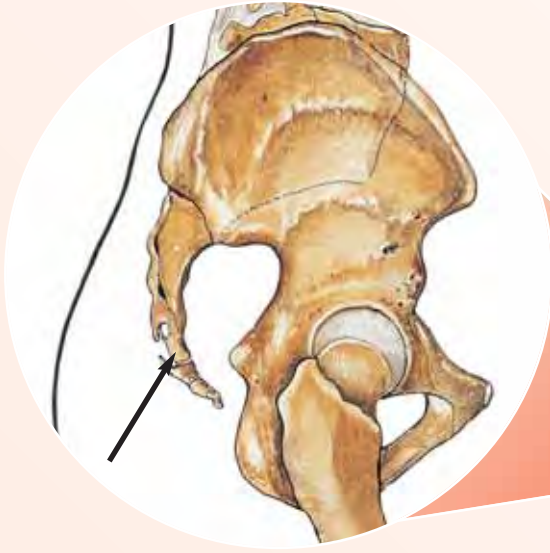
كلاوية

Qutu

Qutuk

Clavicule

# Coccyx / Sacrum



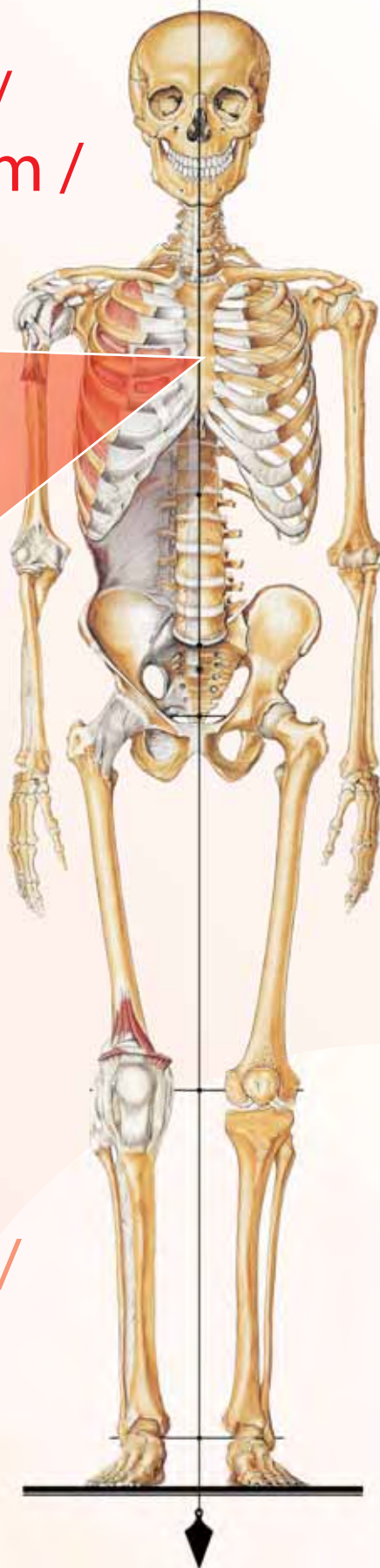
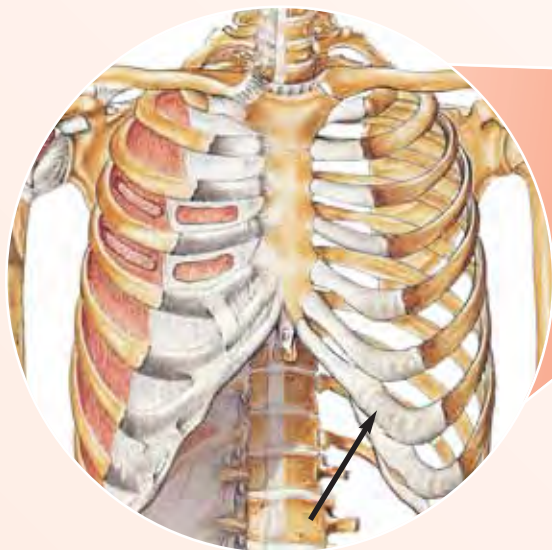
<Г>ᑭᑭ

Pamiuq

Pamialluk

Haut de la raie  
des fesses

# Costal Cartilage / Rib Cage / Sternum / Breast Bone



ᐱᐱᐱᐱ

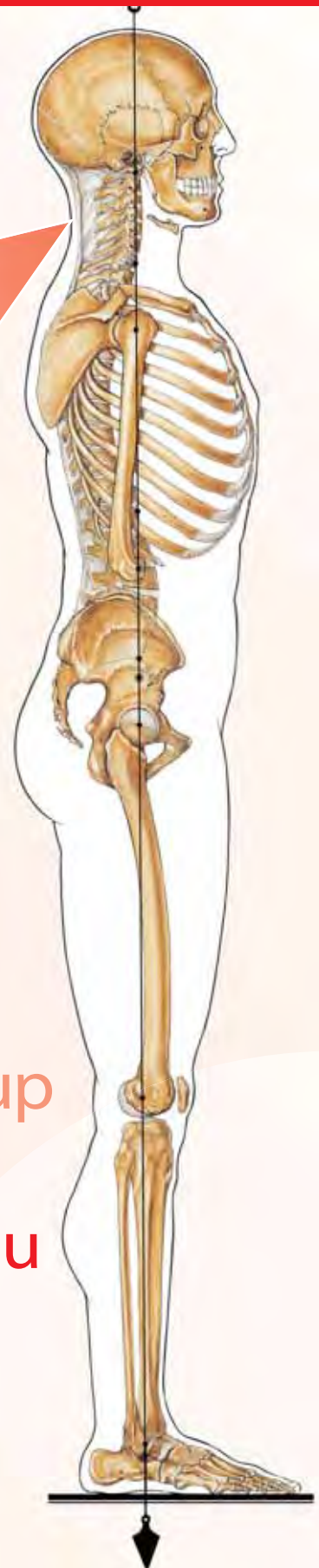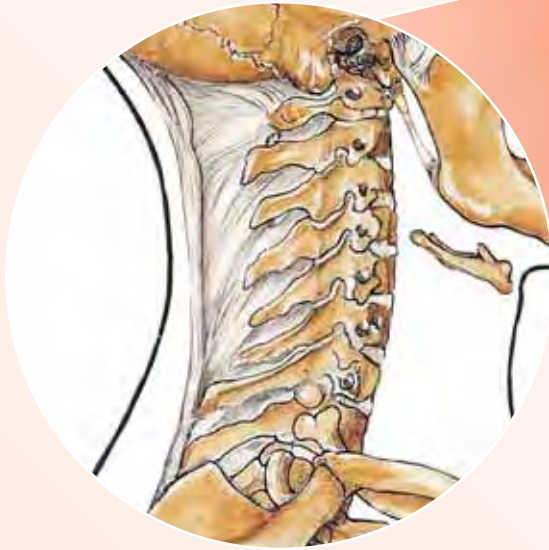Sagvik

Ilaun'nguyaq

Cartilage costal /  
cage thoracique /  
sternum



# Craniovertebral Articulation



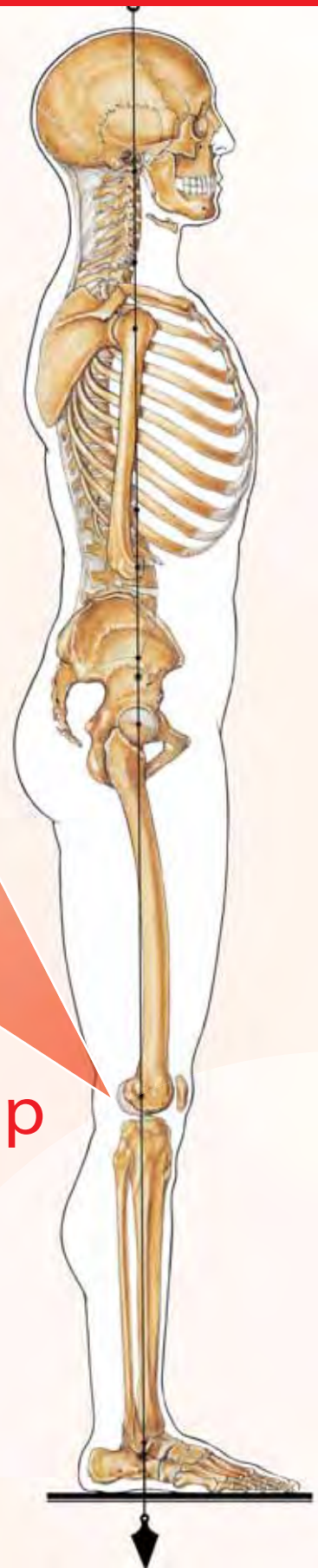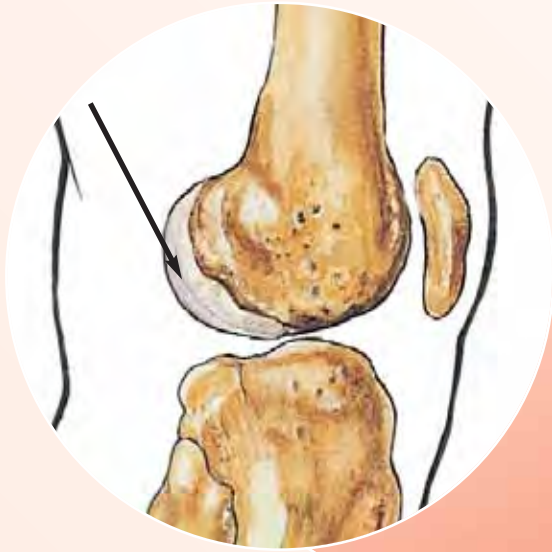ᓂᐱᑦᓂᐱᑦᑦᑦ ᑦᓂᓃᓂᑦᑦᑦ  
ᓂᓂᑦᑦᑦᑦ

Niaqurmit Qungasiup  
Nagguangit

Niaqqup Qimirluublu  
Ingutaarnia

Articulation crânio-  
vertébrale

# Distal Epiphysis



ᕐᕈᕐᕐᕐᕐᕐᕐ ᕐᕈᕐᕐᕐᕐᕐᕐᕐ

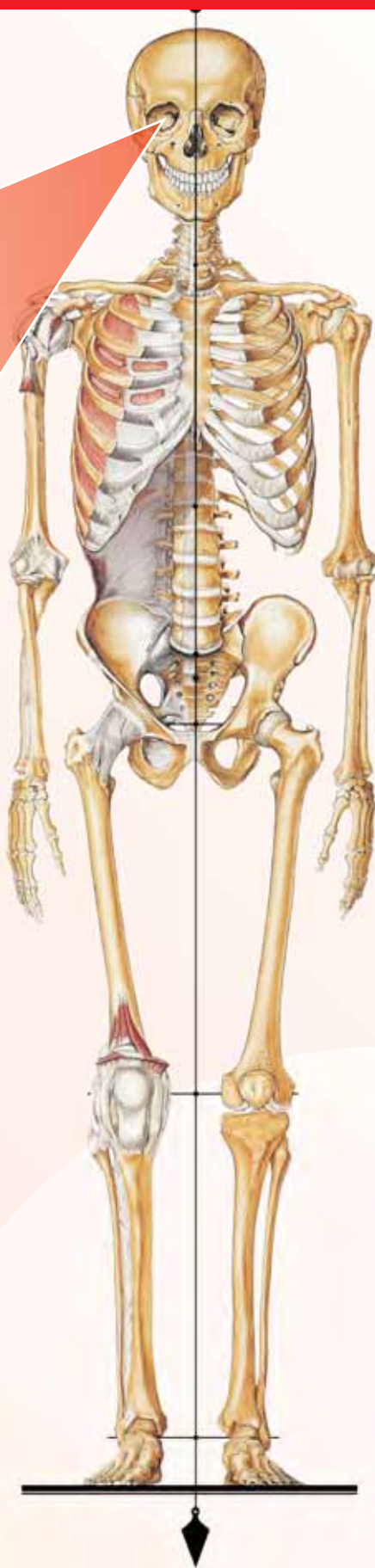
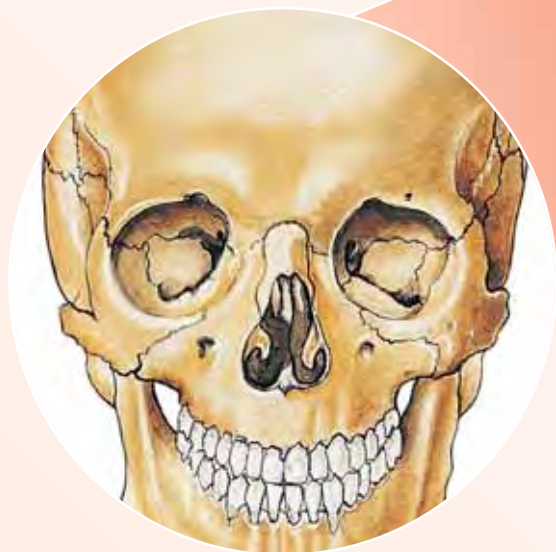Sauniup Isua

Ihugluit/Ipiringniup

Qaqqulaanga

Épiphyse distale

# Eye Socket or Orbit



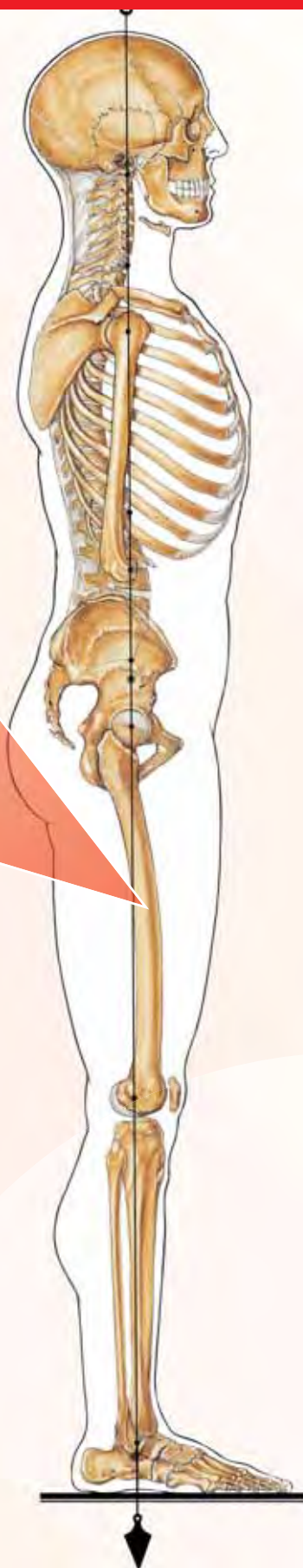
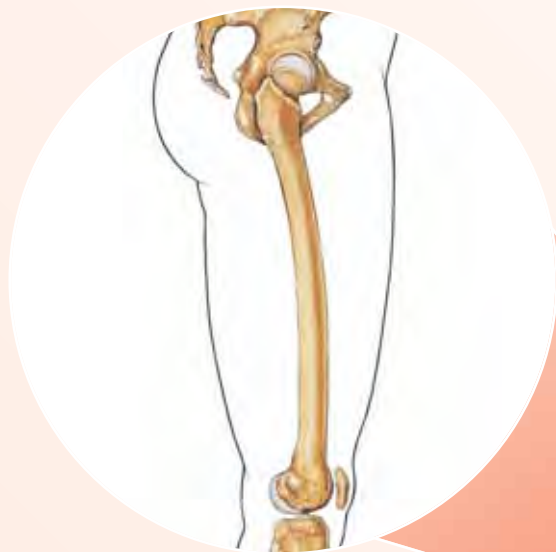
Δῖϛϛᵃᵇ

Ijilirvik

Iyiqarvik

Orbite

# Femur, Thighbone



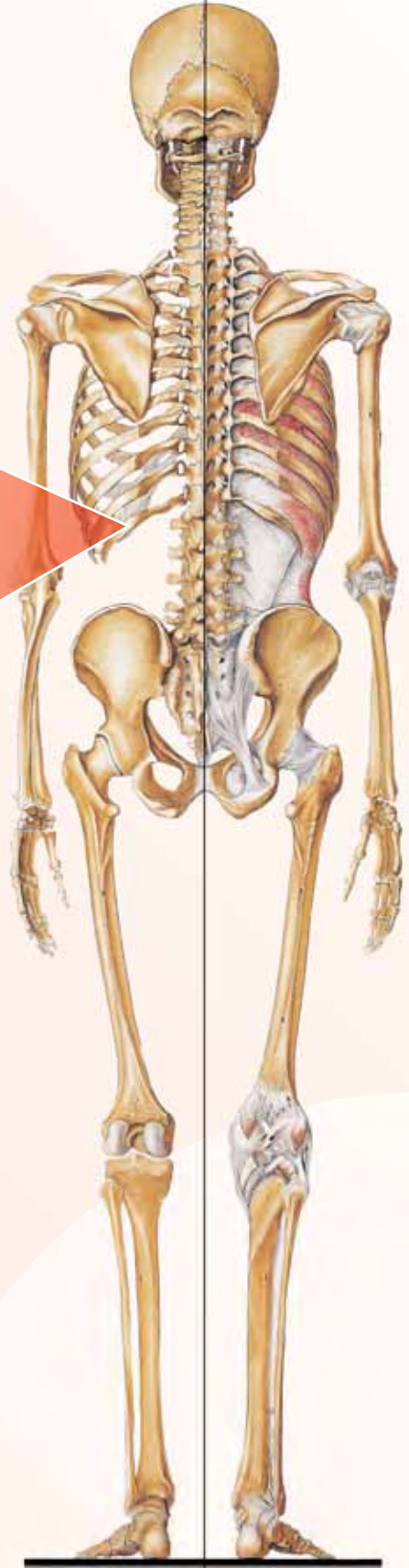
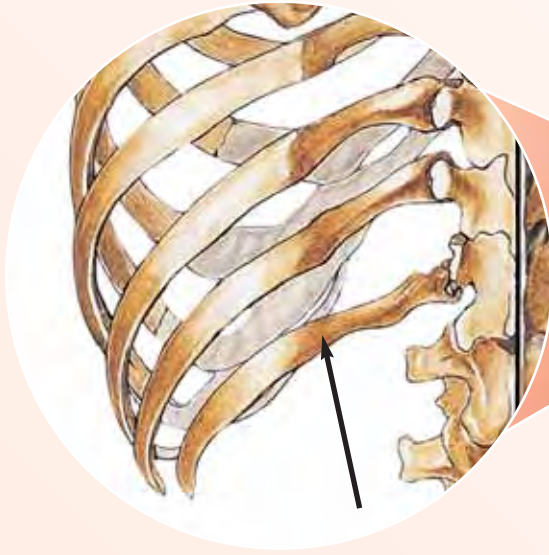
ᠵᠠᠮᠤᠰᠤ

Qukturaq

Qukturaq

Cuisse (face  
antérieure), femur

# Floating Rib, Last Rib



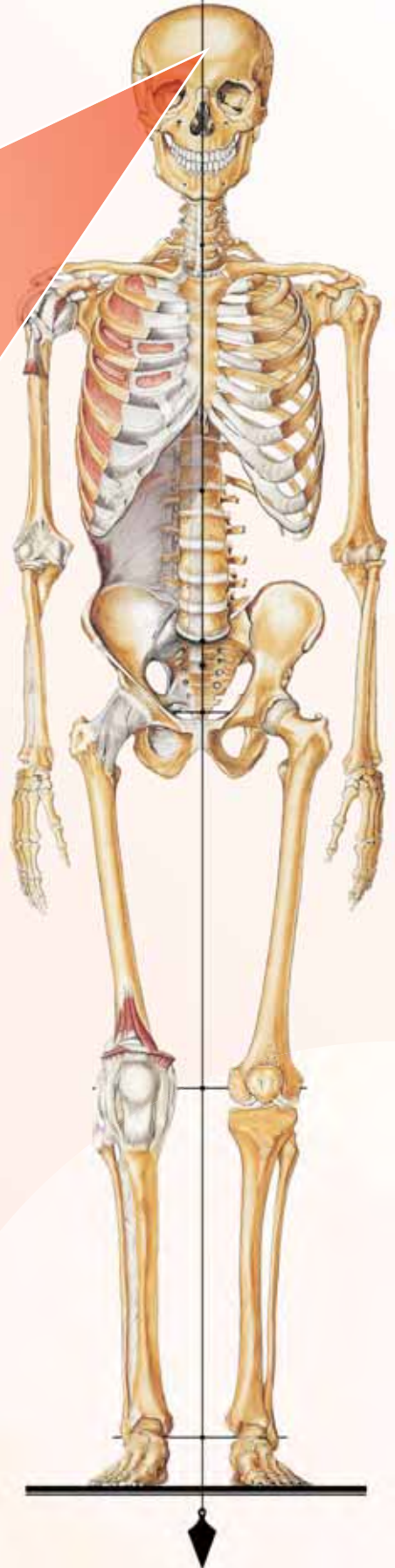
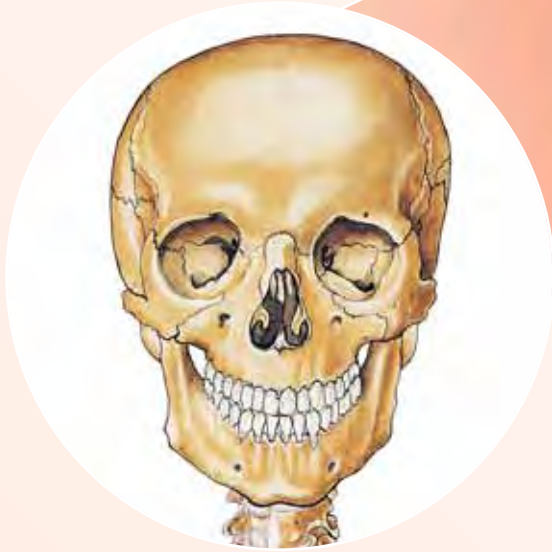ᄀᄁᄂᄃᄄᄅ

Nuvuliksaq

Ihukhiq

Côte flottante,  
dernière côte

# Frontal Bone



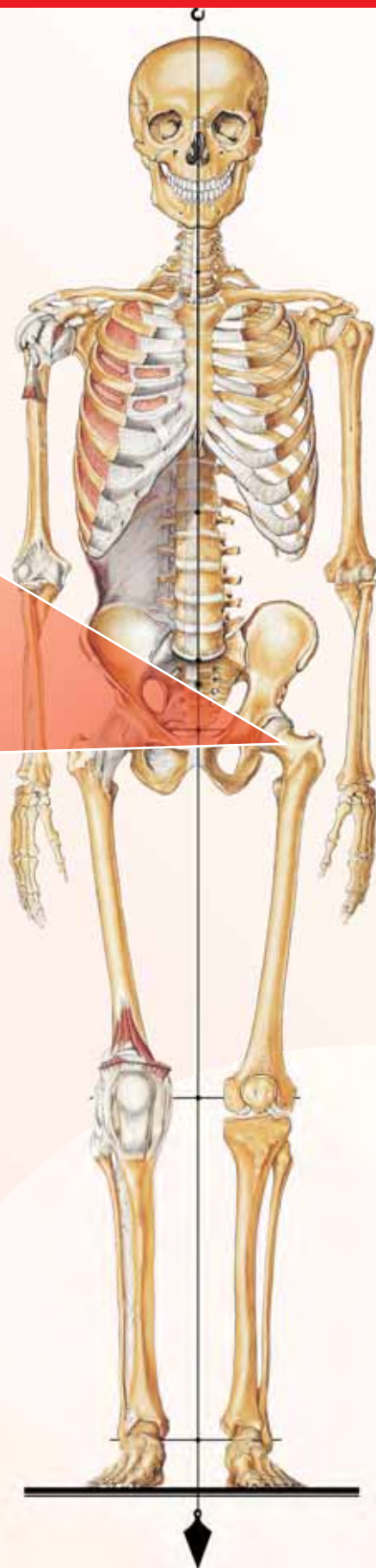
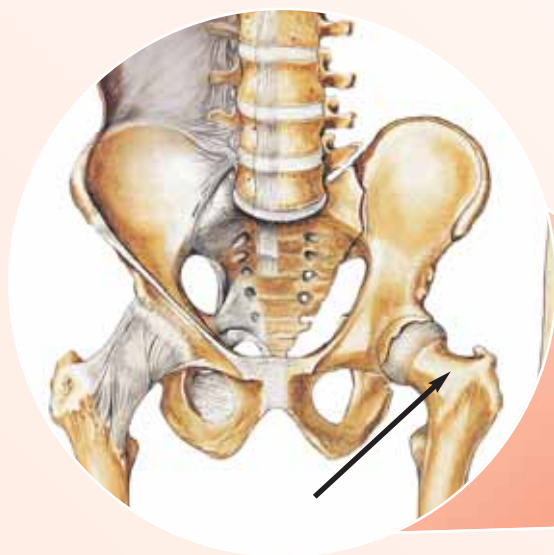
ᠶᠪᠳᠶᠪ

Qauq

Qaup Haunia

Os frontal

# Greater Trochanter



ԼՐԴԳԾ

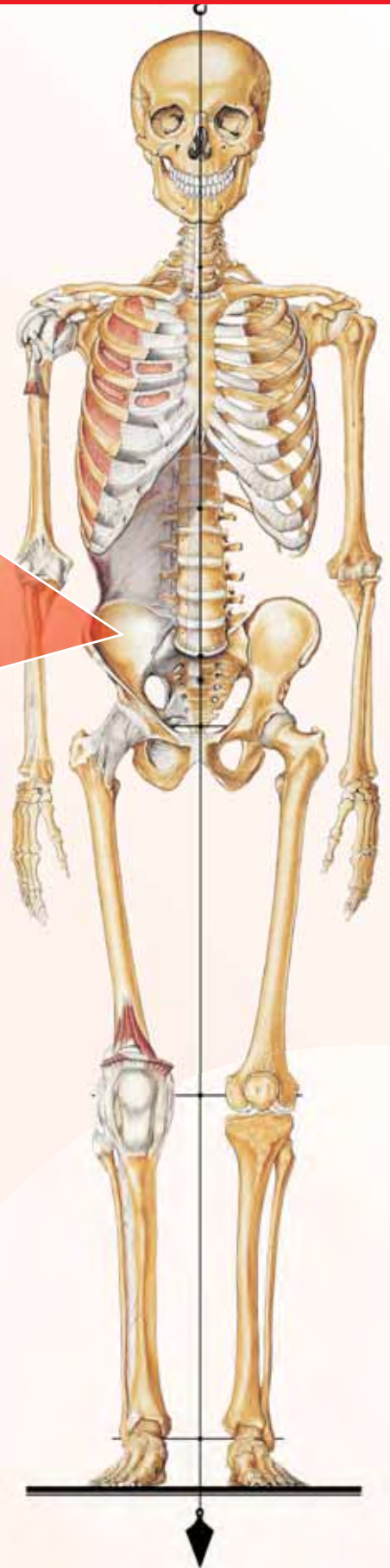
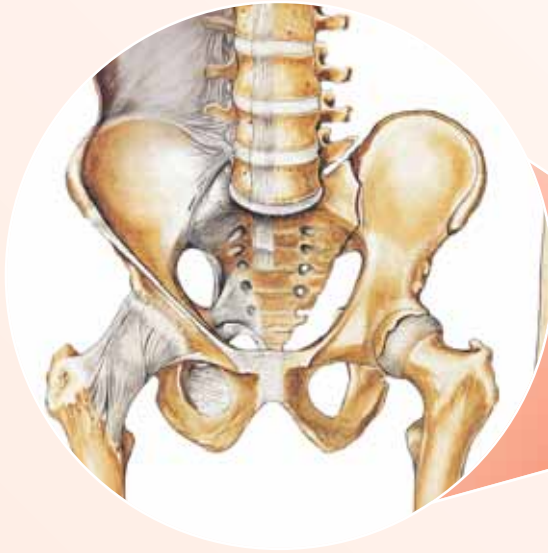
Makisiq

Makitiq

Hanche

(région de la)

# Hip



ძეგობ

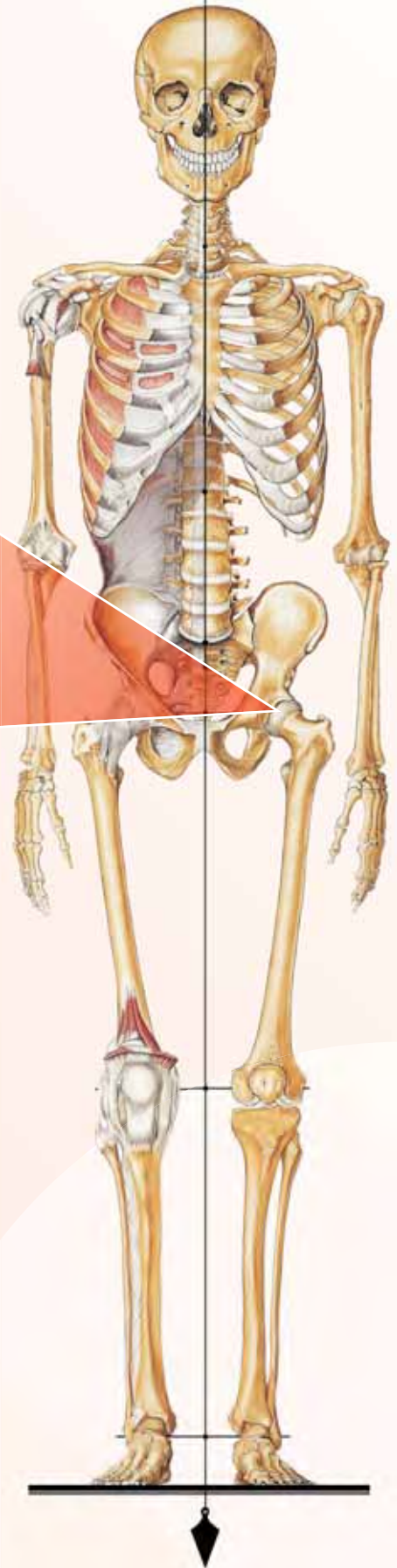
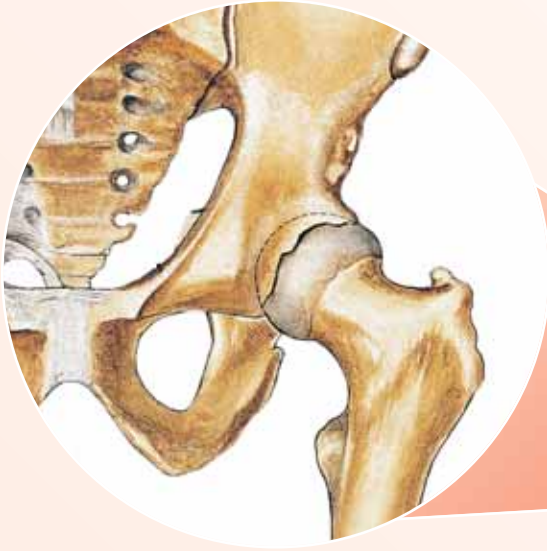
Kuuttiq

Hilviaq

Hanche



# Hip Joint



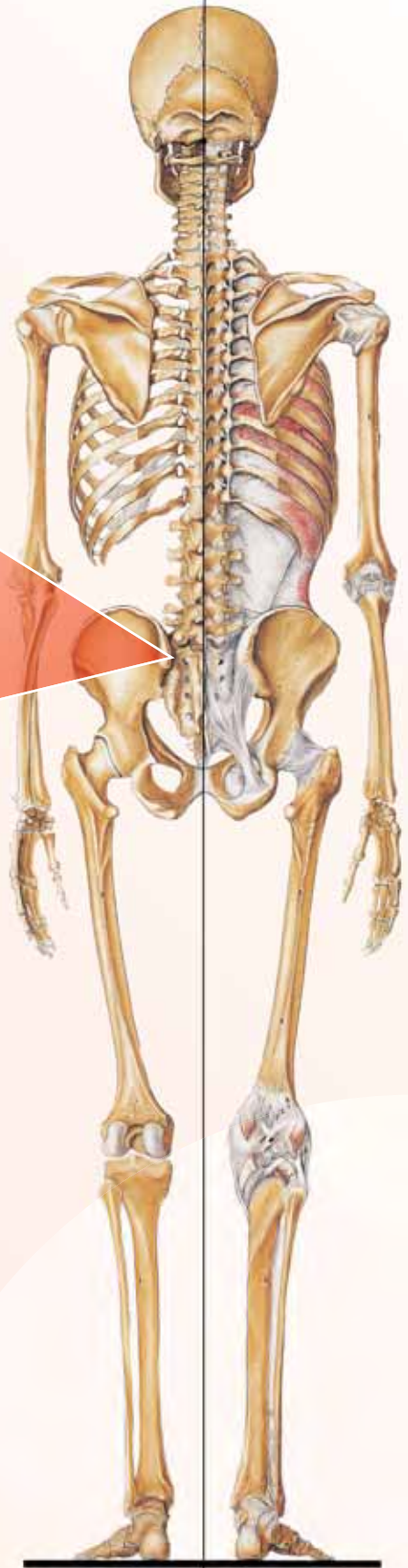
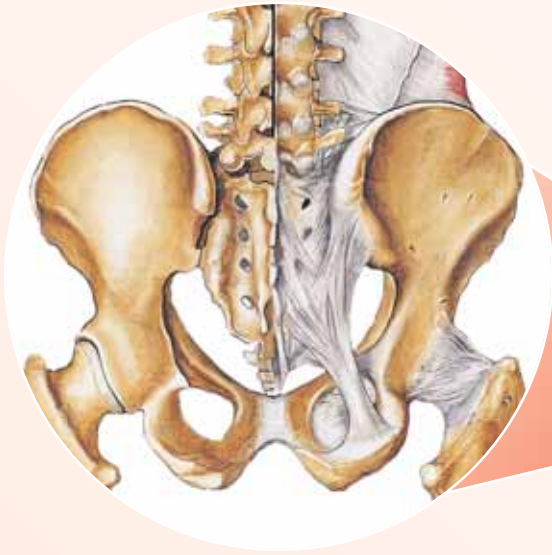
ᐱᑦᐃᐱᐱᐱᐱᐱᐱ

Sivviaq

Kuuttiq

Os iliaque,  
os de la hanche

# Hip, Iliac Bone / Hip Area



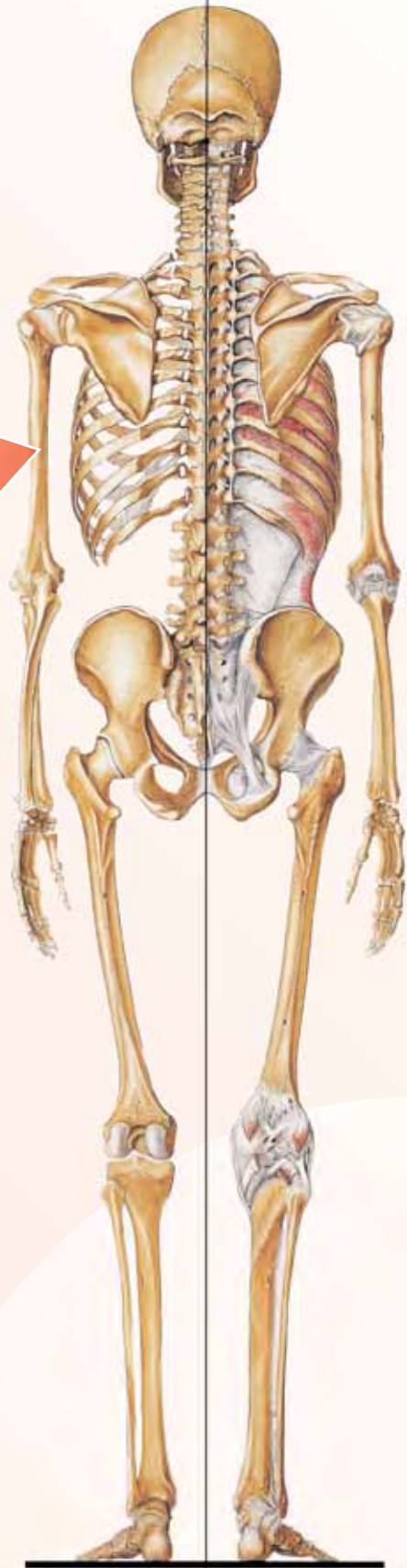
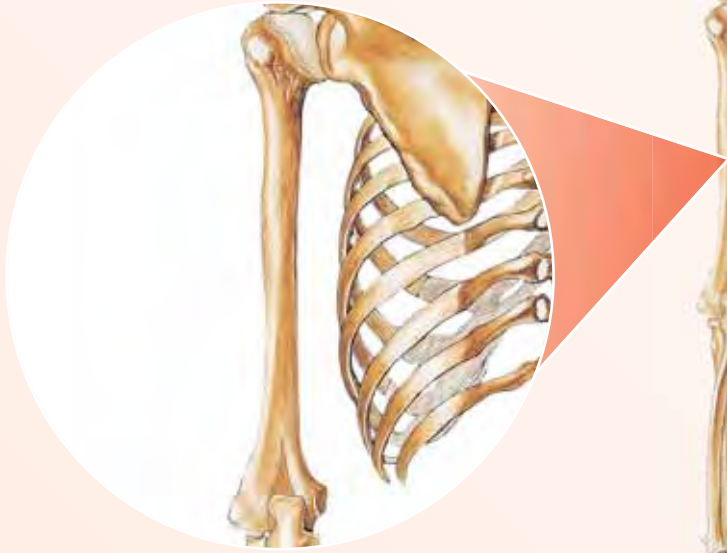ᐅᓐᓂᓐᓂᓐᓂᓐᓂᓐᓂᓐ

Sivviaqarvik

Hilviaq

Hanche,  
os iliaque

# Humerus



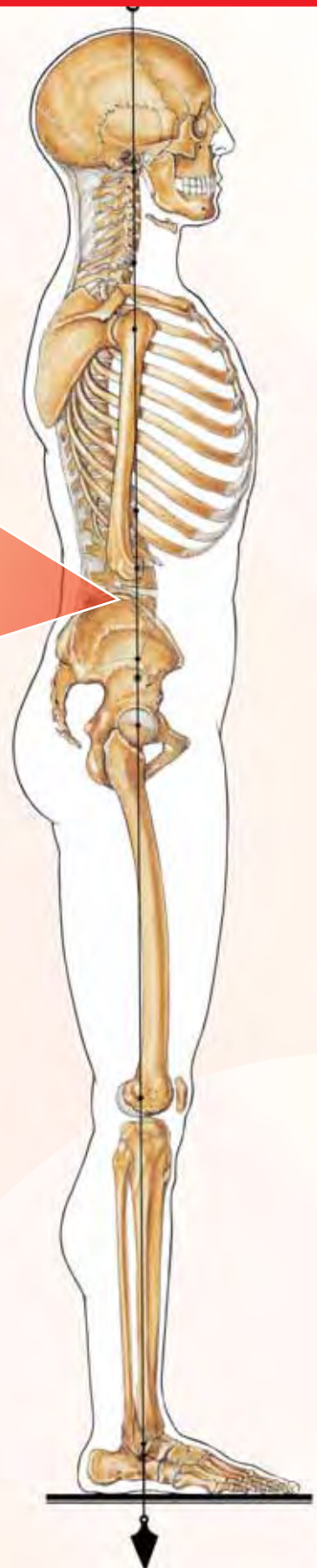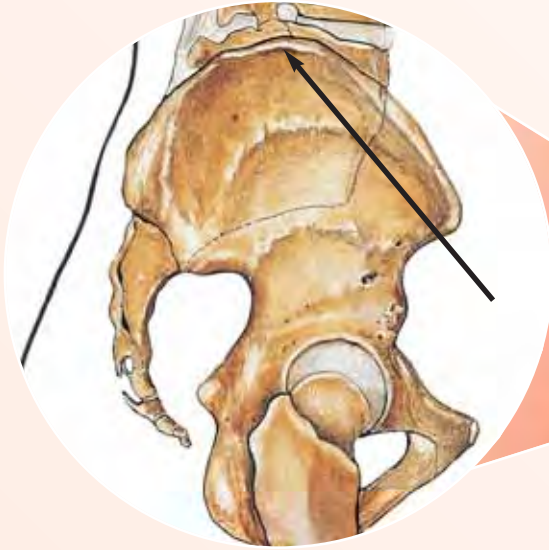
ᐱᓴᓂᕈᕐᕈᕐᕈᕐᕈᕐ

Aksaqquq

Akhatquq

Humérus

# Iliac Crest



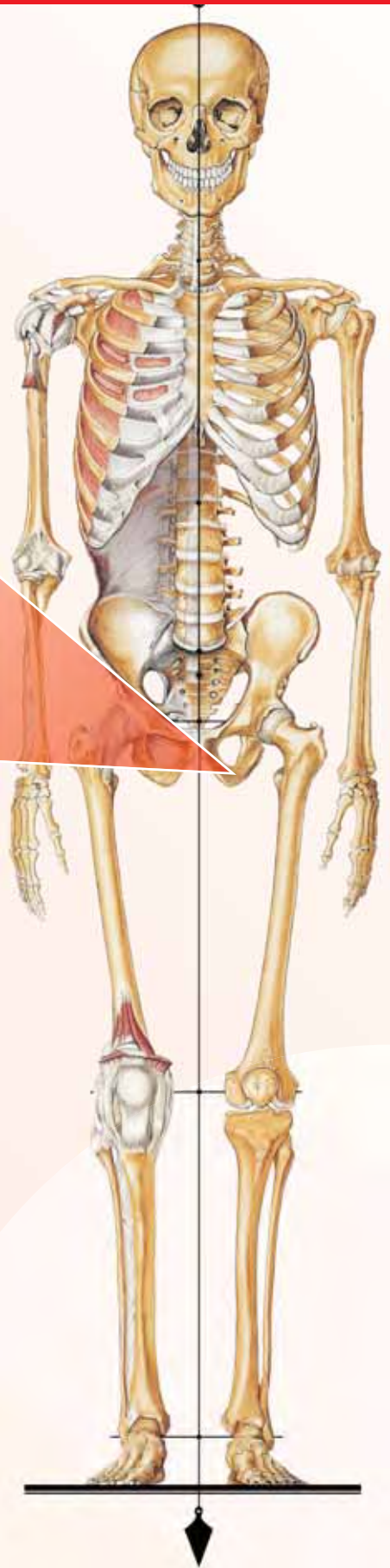
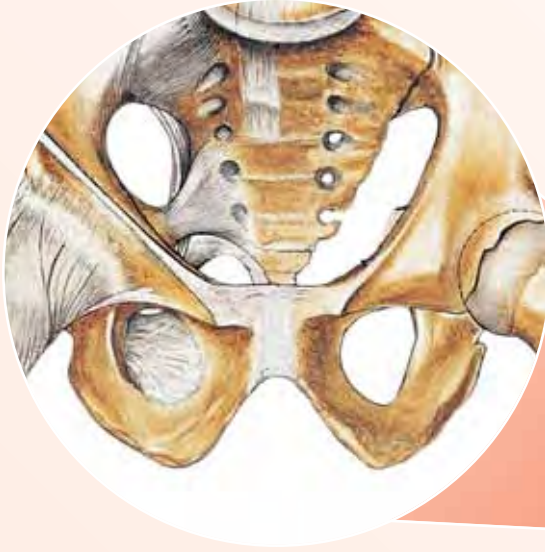
ᐱᕈᕈᕐᕐ

Makisiq

Kuuttiniq

Crête iliaque

# Ischium



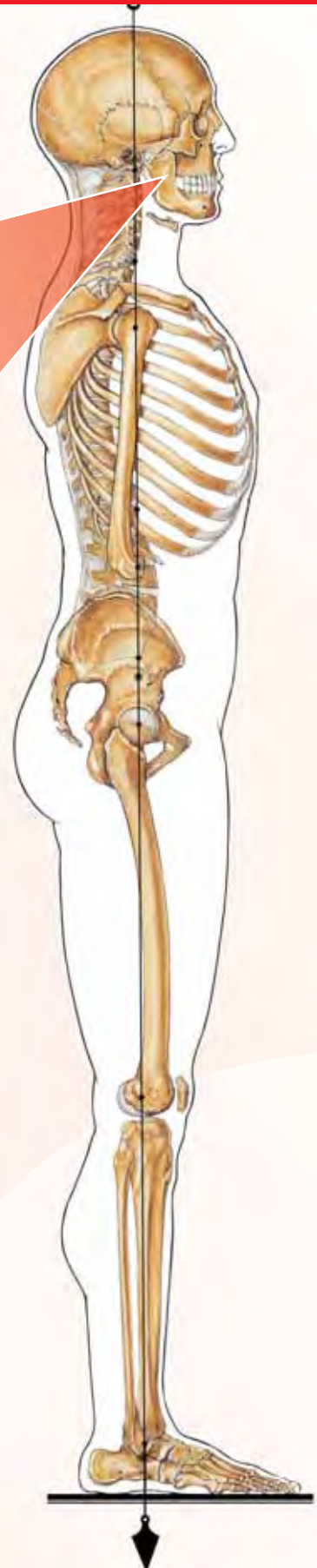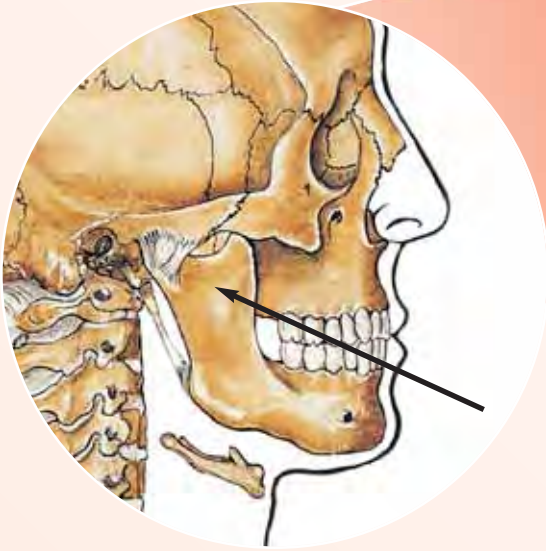نُلُوق

Nuluq

Kuuttiup Kangia

Ischion

# Jaw Bone



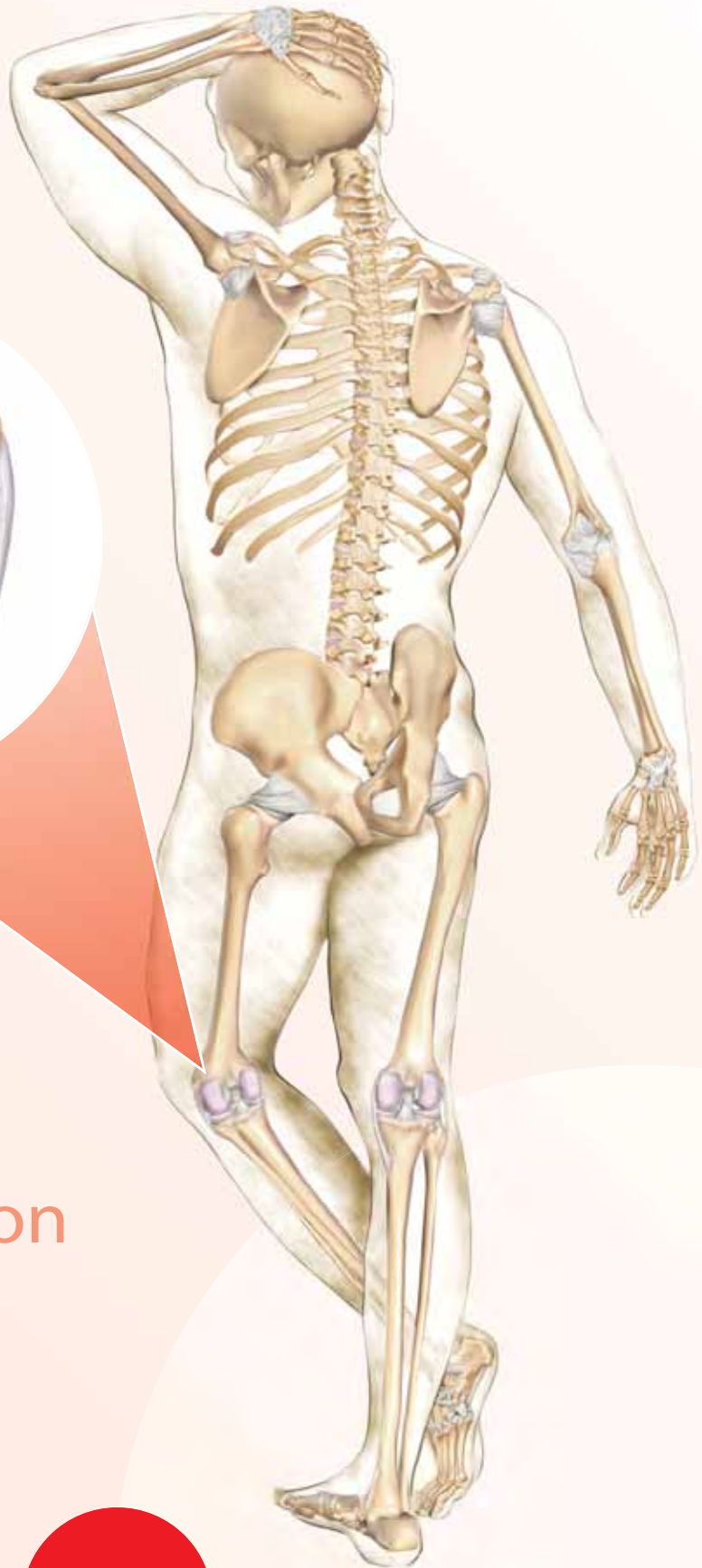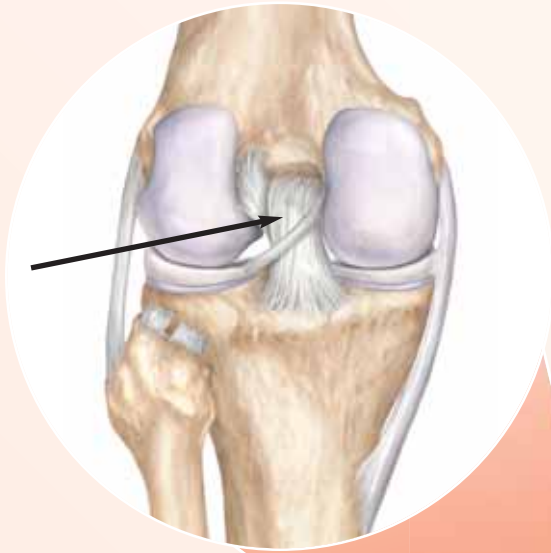
ᐃᓗᓗᐅ ᐱᓗᓗᐅ ᐱᓗᓗᐅ  
ᐱᓗᓗᐅ ᐱᓗᓗᐅ ᐱᓗᓗᐅ ᐱᓗᓗᐅ

Uluap Sauninga  
Ataaniinniiqsaq

Uluap Haunia

Os malaire ou  
zygomatique

# Knee Joint



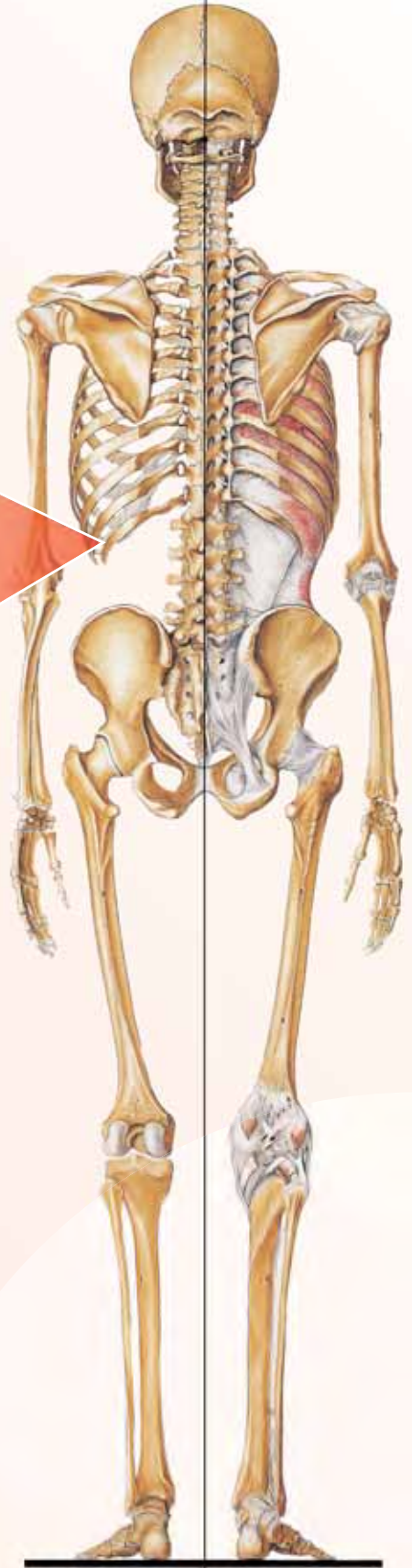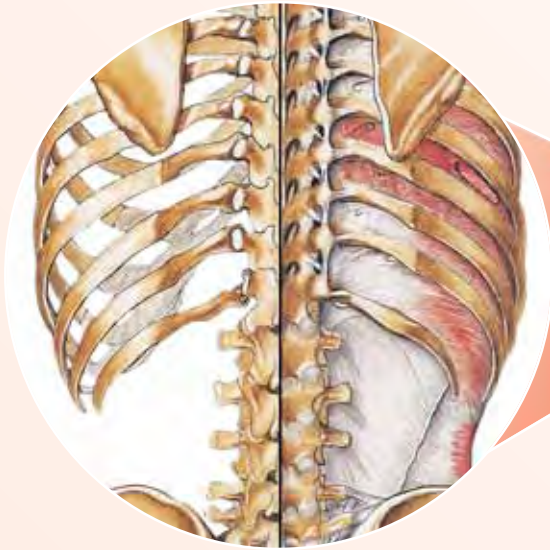
ᐱᐅᐅᐅᐅᐅᐅ

Siiqquaq

Nabluk

Articulation  
du genou

# Lower End of the Ribs



ᄆᄇᄀᄁᄂᄃ

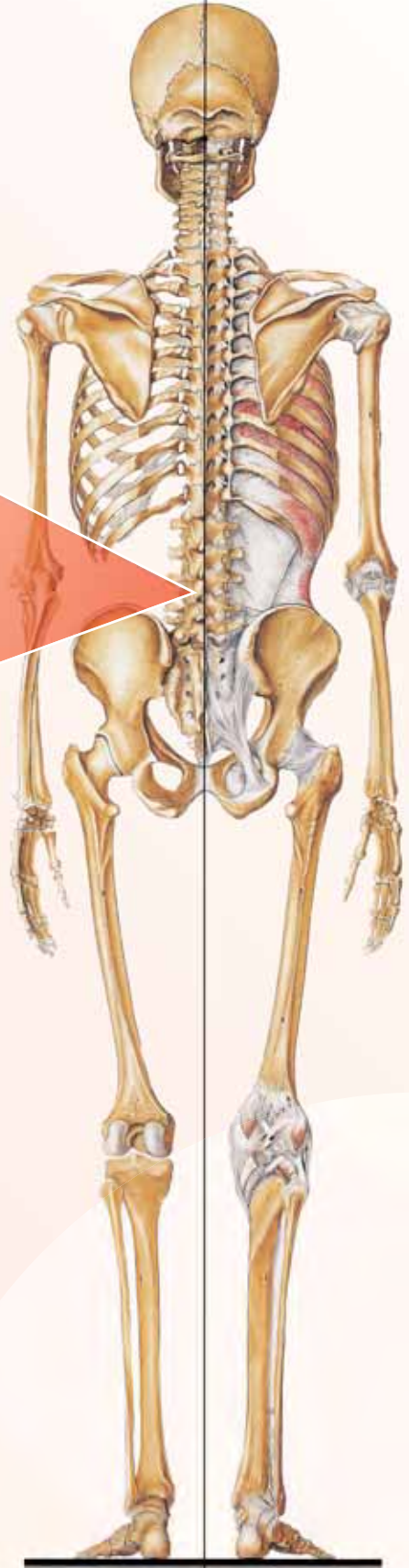
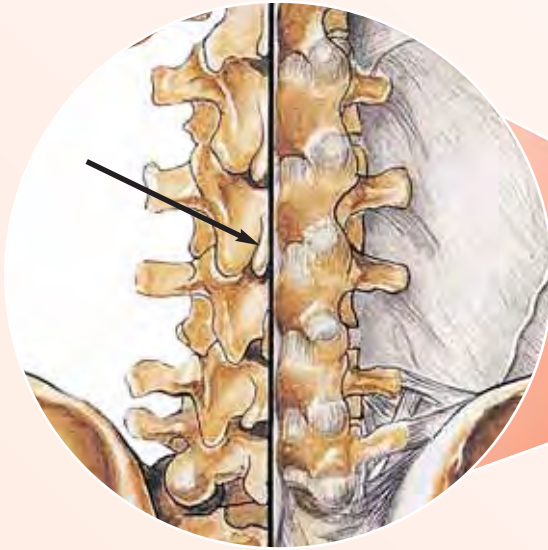
Nuvulixsat

Ihukhiq

Bas des côtes



# Lumbar Vertebrae / Sacrum



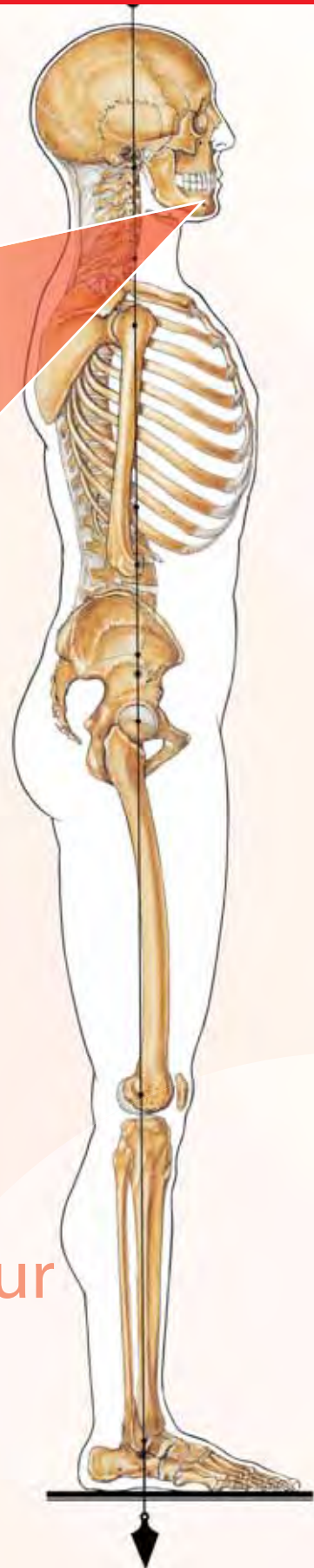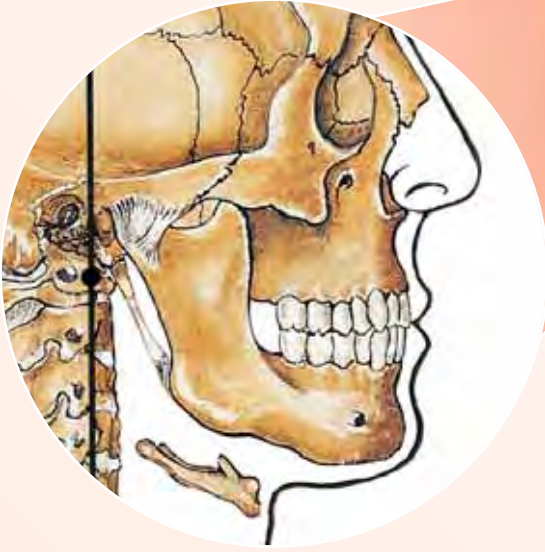
ᐃᑦᑎᓂᑦᑲ

Kuttiniq

Kuuttiniq

Vertèbres  
lombaires /  
sacrum

# Mandible / Lower Jaw Bone



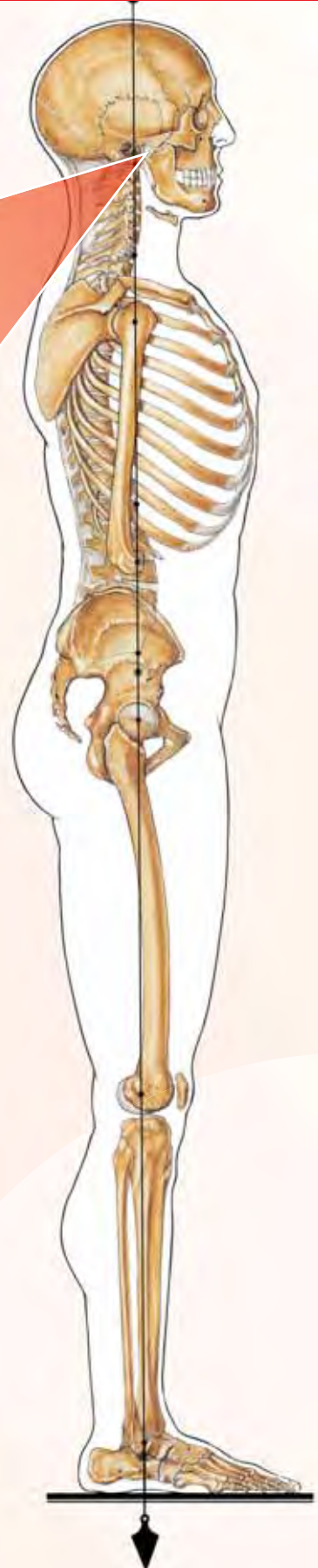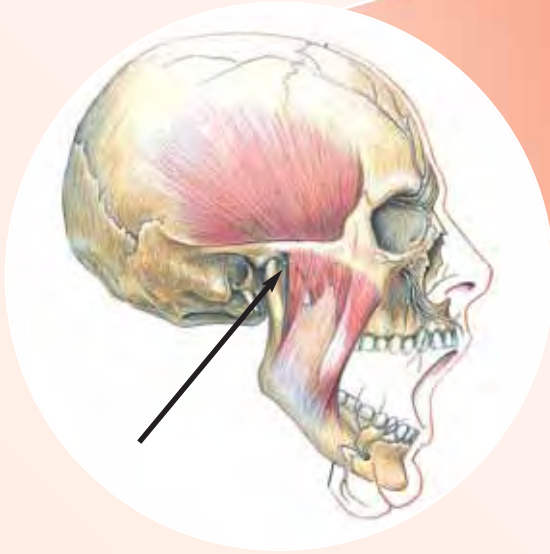
ᐱᓂᓂᓂᓂᓂᓂ

Agliuruq

Agliuruq

Mandibule  
(maxillaire inférieur  
ou mâchoire  
inférieure)

# Mandibular Condyle



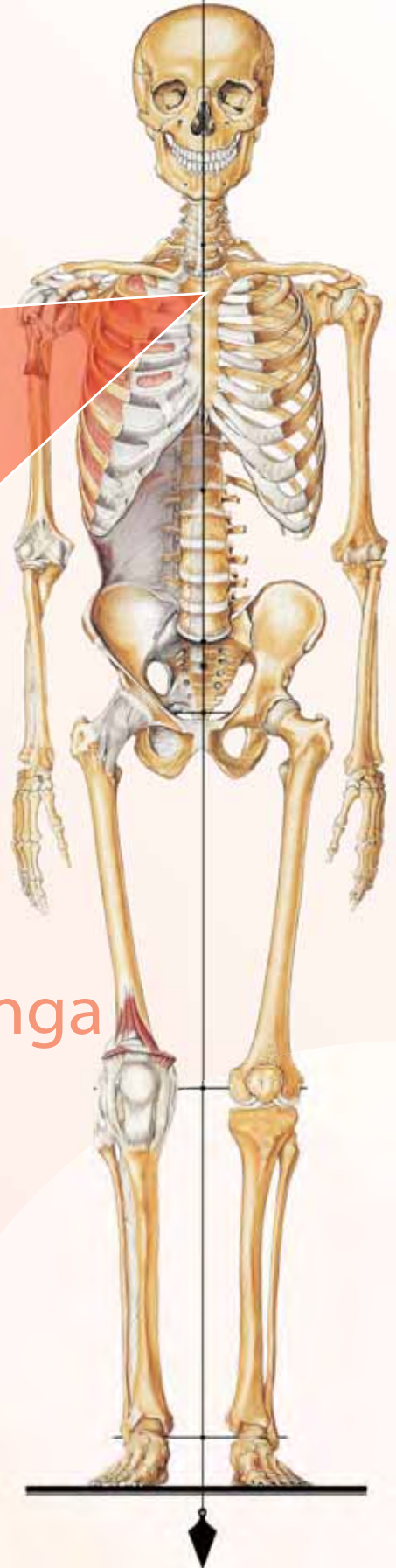
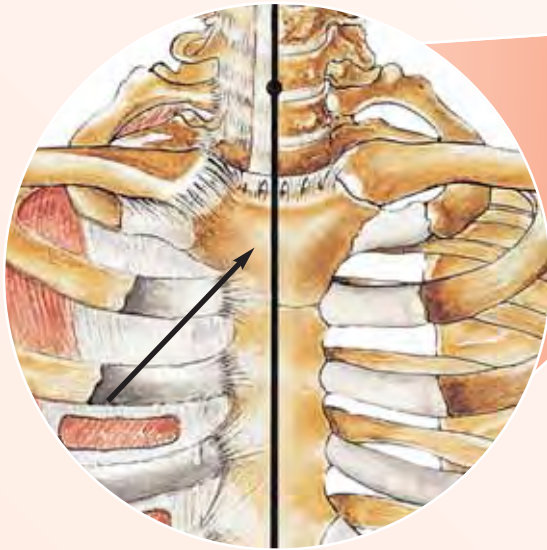
ᐱᓕᓱᓪᓴ ᓂᓄᓂᓄᓂ

Agliruup  
Tunganinga

Tuttak

Condyle de la  
mandibule

# Manubrium



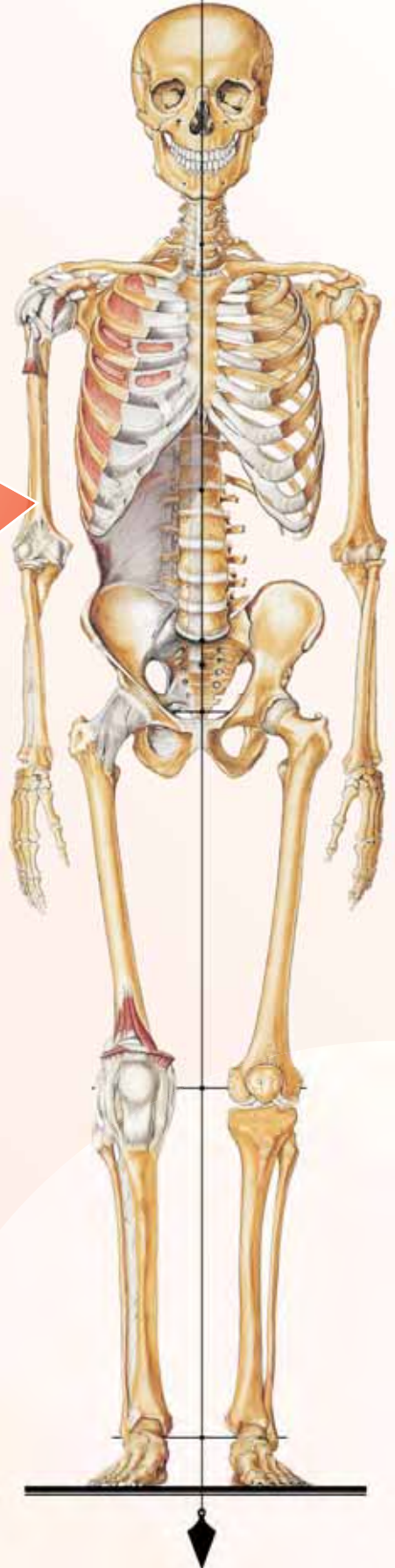
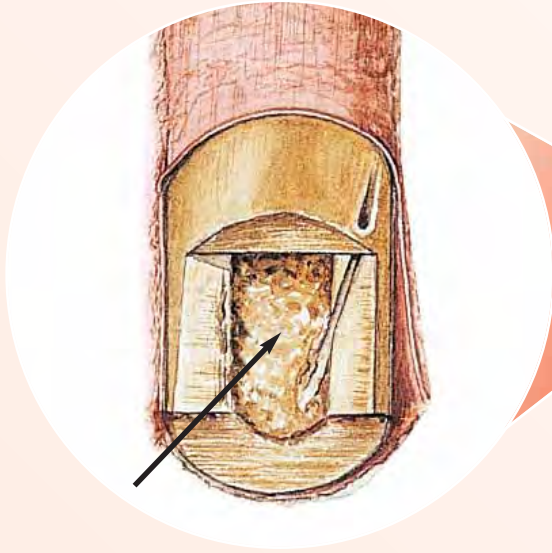
ԿՐՎԷ ԳԾԸՊՆՆՆ

Sakiap Qulingaanga

Hakiap Haunia

Manubrium

# Marrow



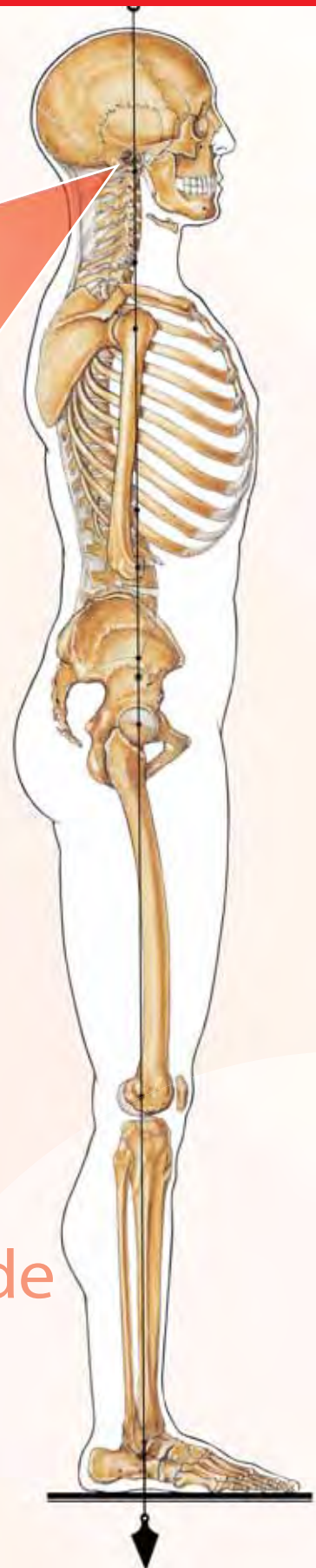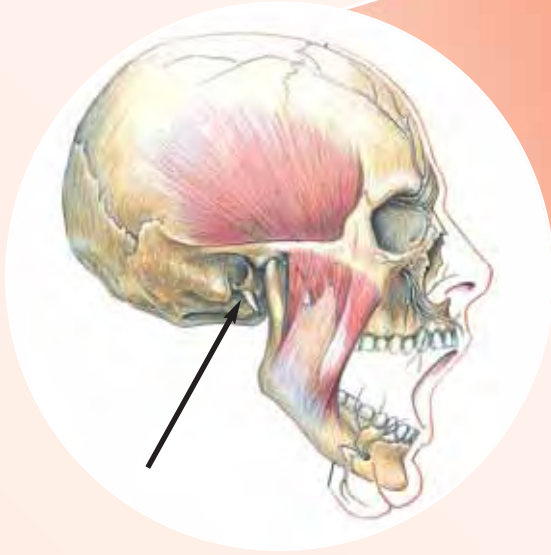
كعق

Patiq

Patiq

Moelle osseuse

# Mastoid Process



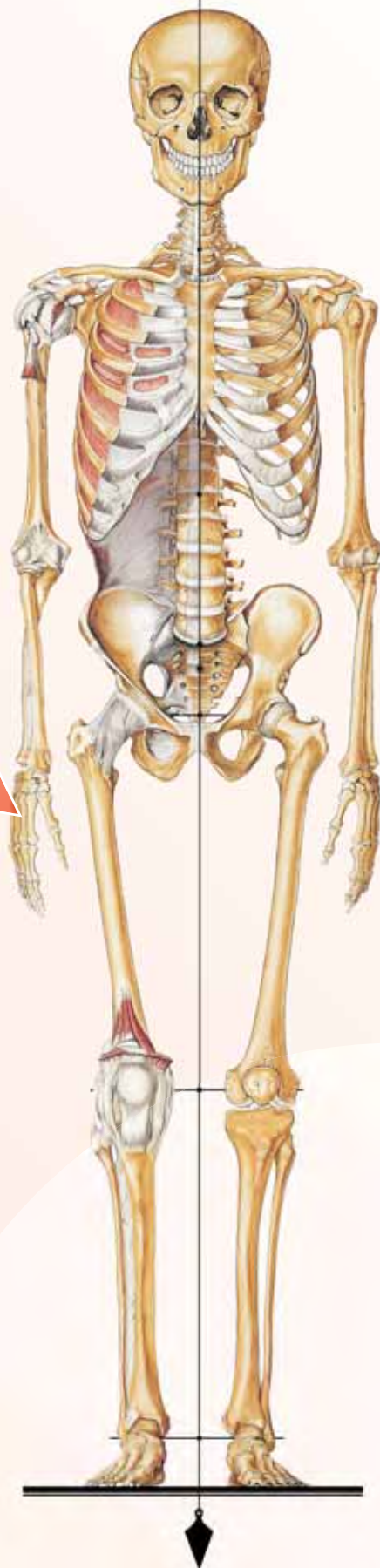
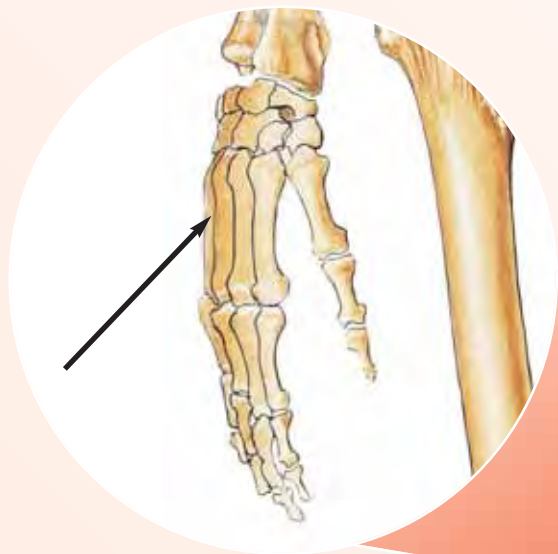
σ▷C<sup>sb</sup>

Niuliq

Niuliq

Processus (ou  
apophyse) mastoide

# Metacarpus



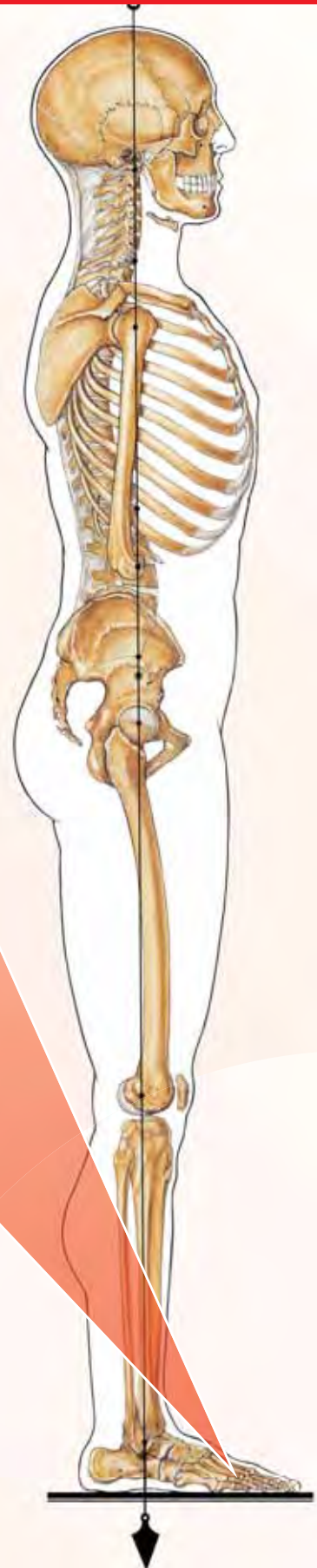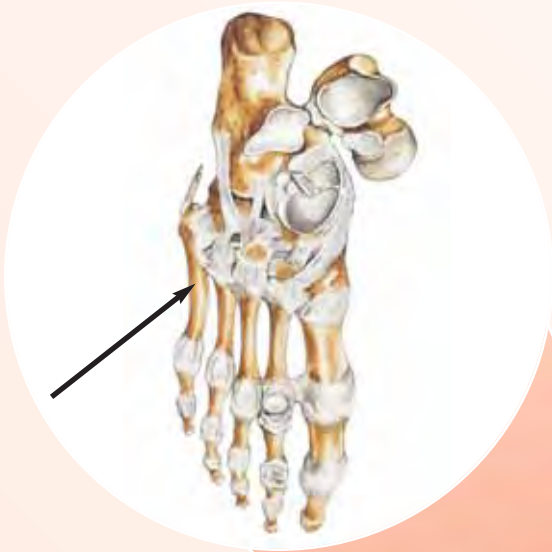< 6 b

Pagvik

Algaup Hauniit

Métacarpe

# Metatarsus

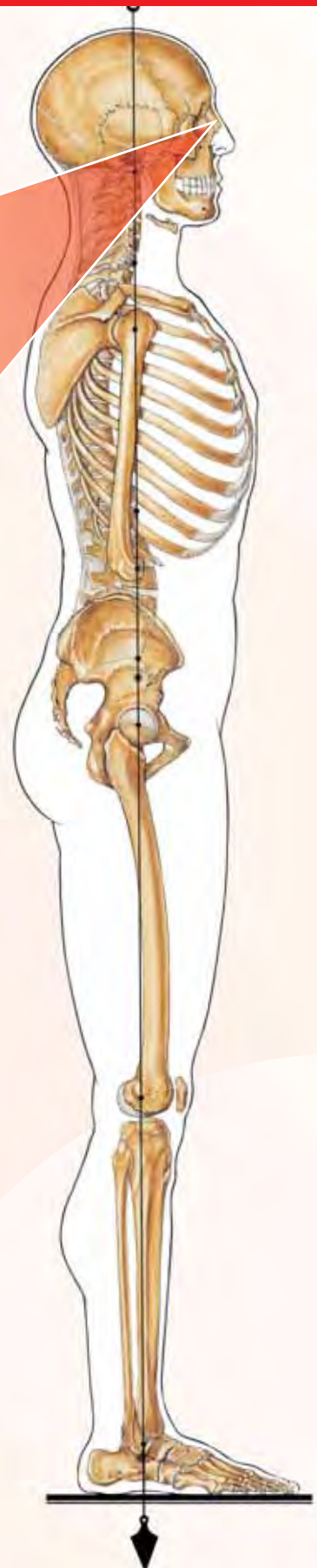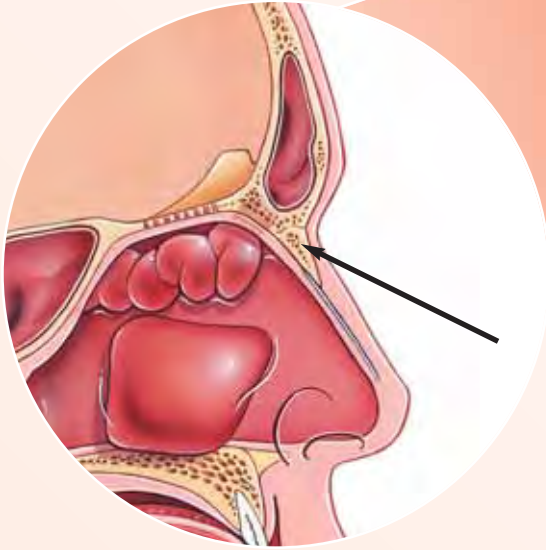


ΔΡΛΔ<  
<Λ&°Γ<

Isigaup  
Pagvingit  
Itikkap Hauniit  
Métatarse



# Nasal Bone



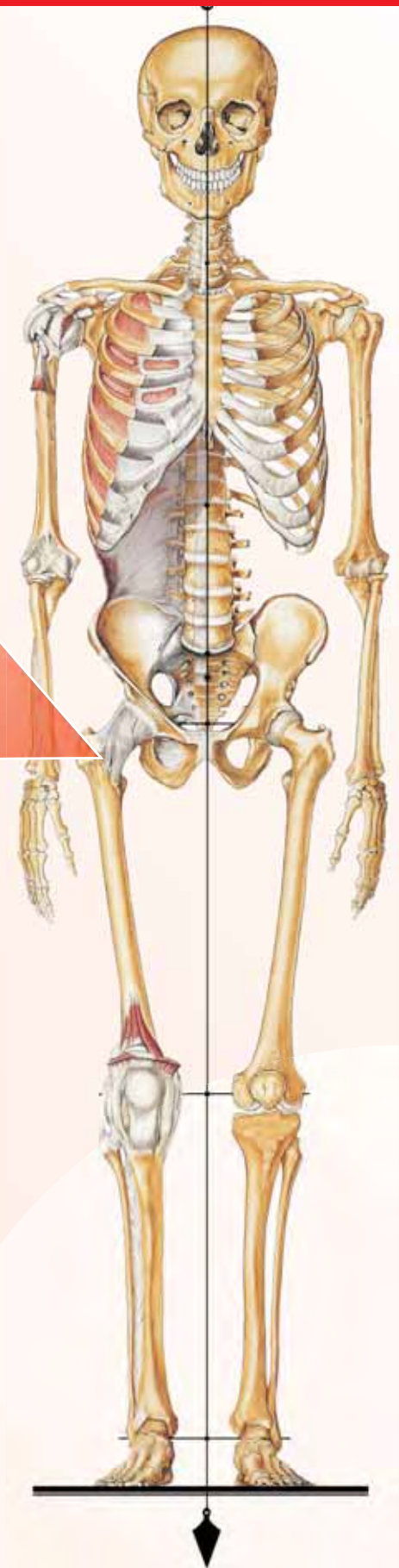
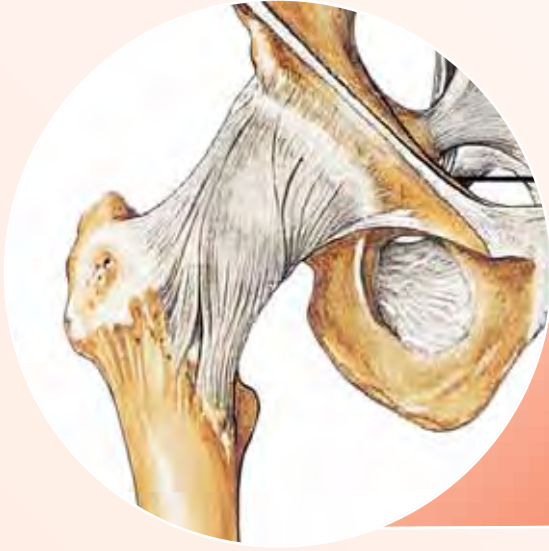
ԳՐՆԱԾՎ ԿԾՏՆ

Qingaup  
Sauninga

Qingaukhuq

Os du nez

# Neck of the Thighbone, Hip Articulation



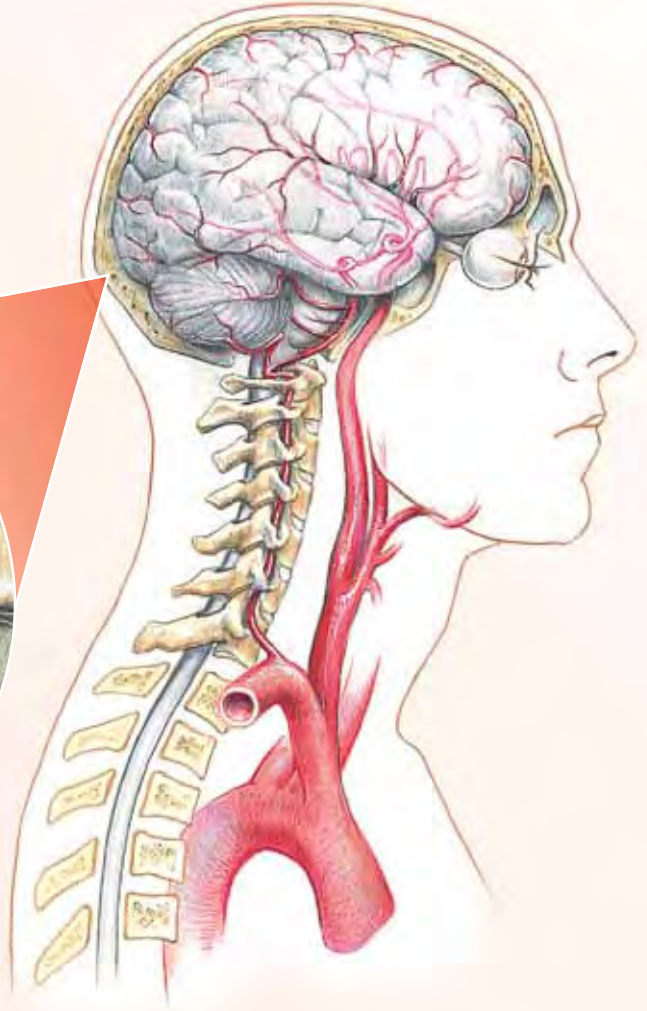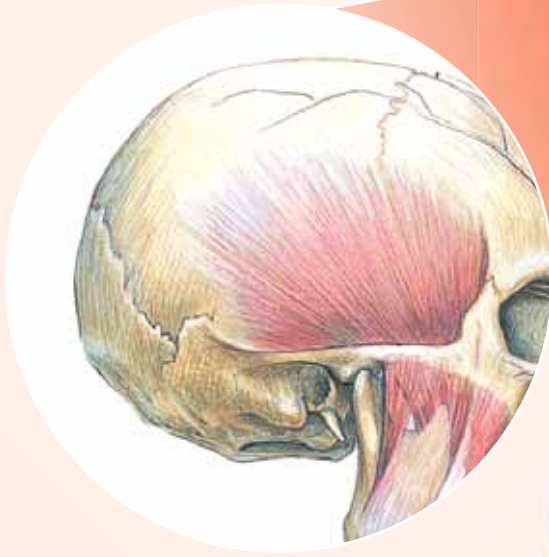
ᐱᑦᐱᐱᐱᐱᐱᐱᐱ

Sivviaq

Hilviaq

Col du fémur,  
articulation de  
la hanche

# Occiput



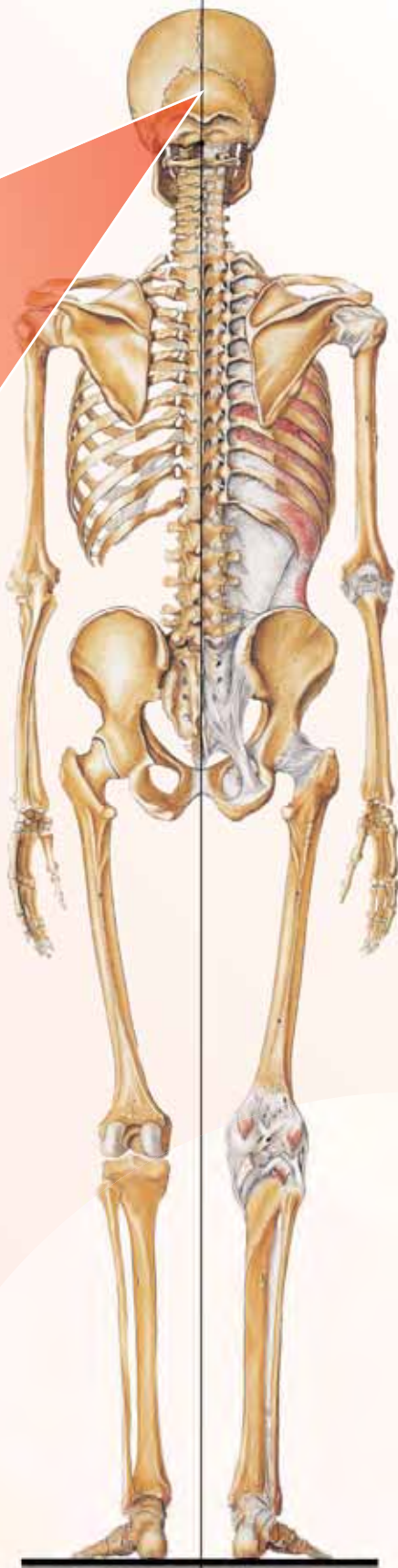
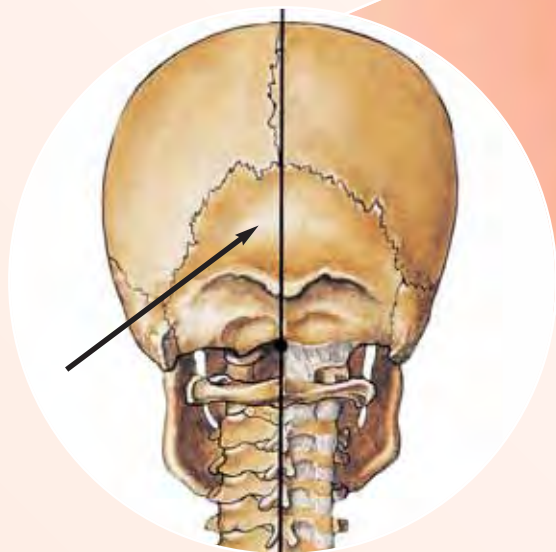
بَرْمَك

Tunusuk

Tunuhuk

Occiput

# Occipital Bone



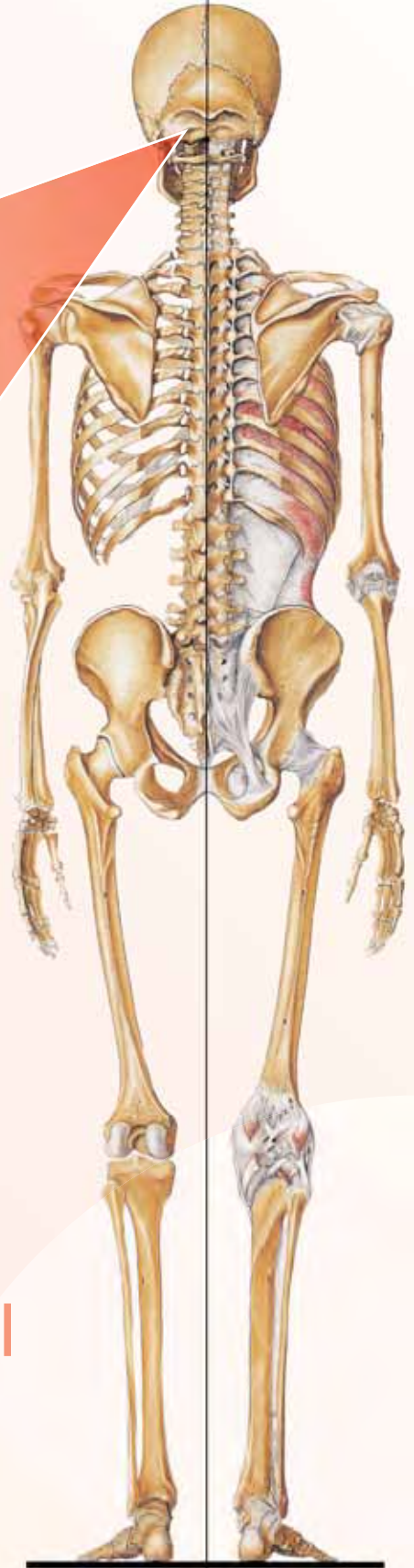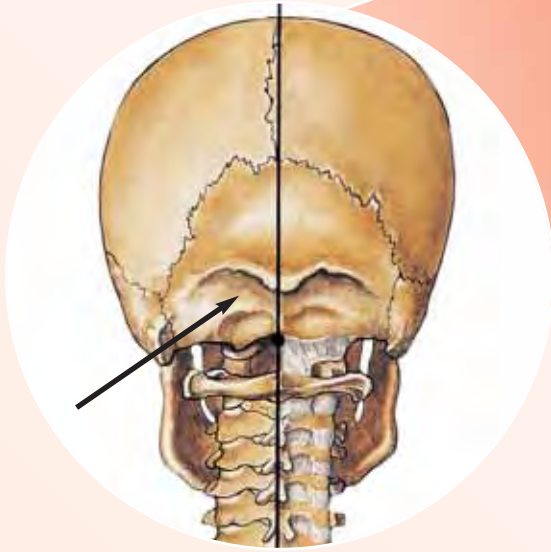
ᠲᠦᠨᠤᠰᠤᠤᠫᠤ ᠯᠢᠰᠢᠨᠠᠭᠤᠰᠤᠨ

Tunusuup  
Pirninga

Tunuhuk

Os occipital

# Occipital Condyle



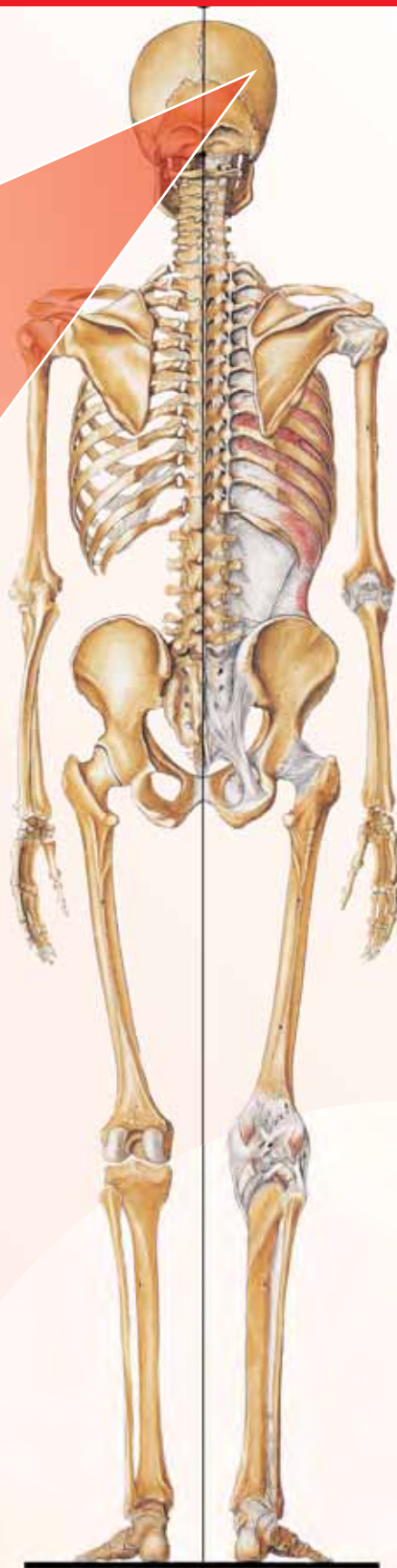
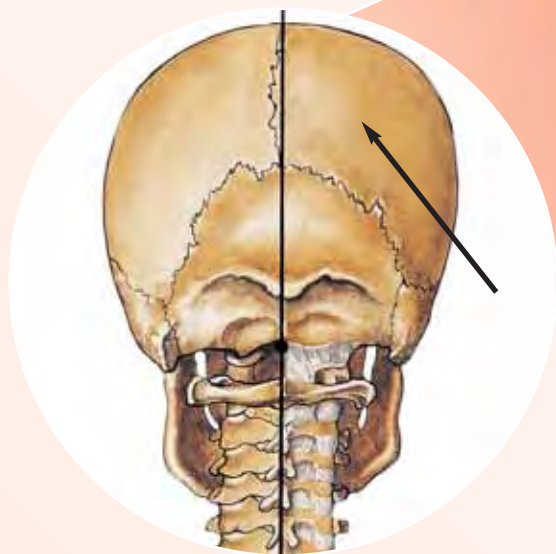
ᐅᐃᐃᐃ ᐅᐃᐃᐃ

Tunusuup  
Niulinga

Niuliq

Condyle occipital

# Parietal Bone



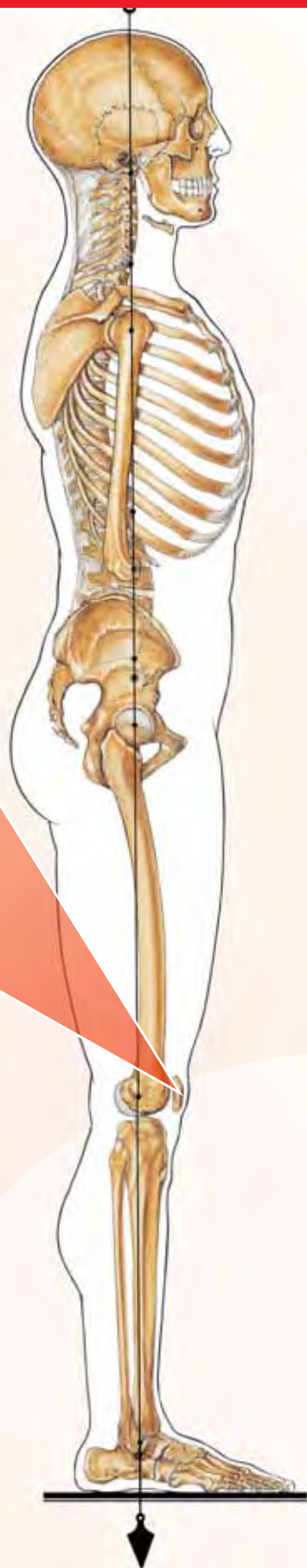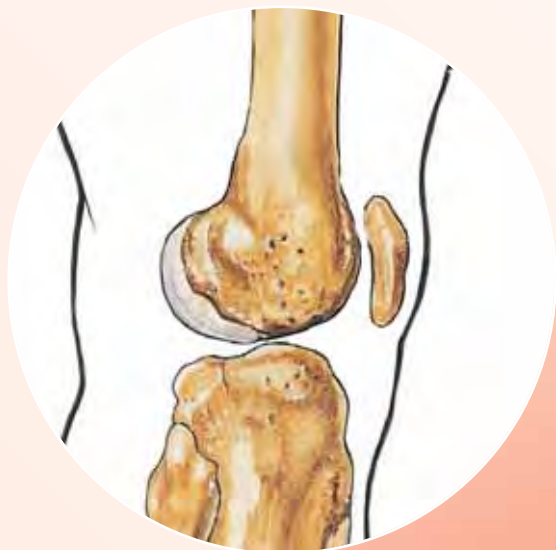Լ՛ԵԵԳԵ

Makkaq

Kaavyiup Haunia

Os pariétal

# Patella / Kneecap



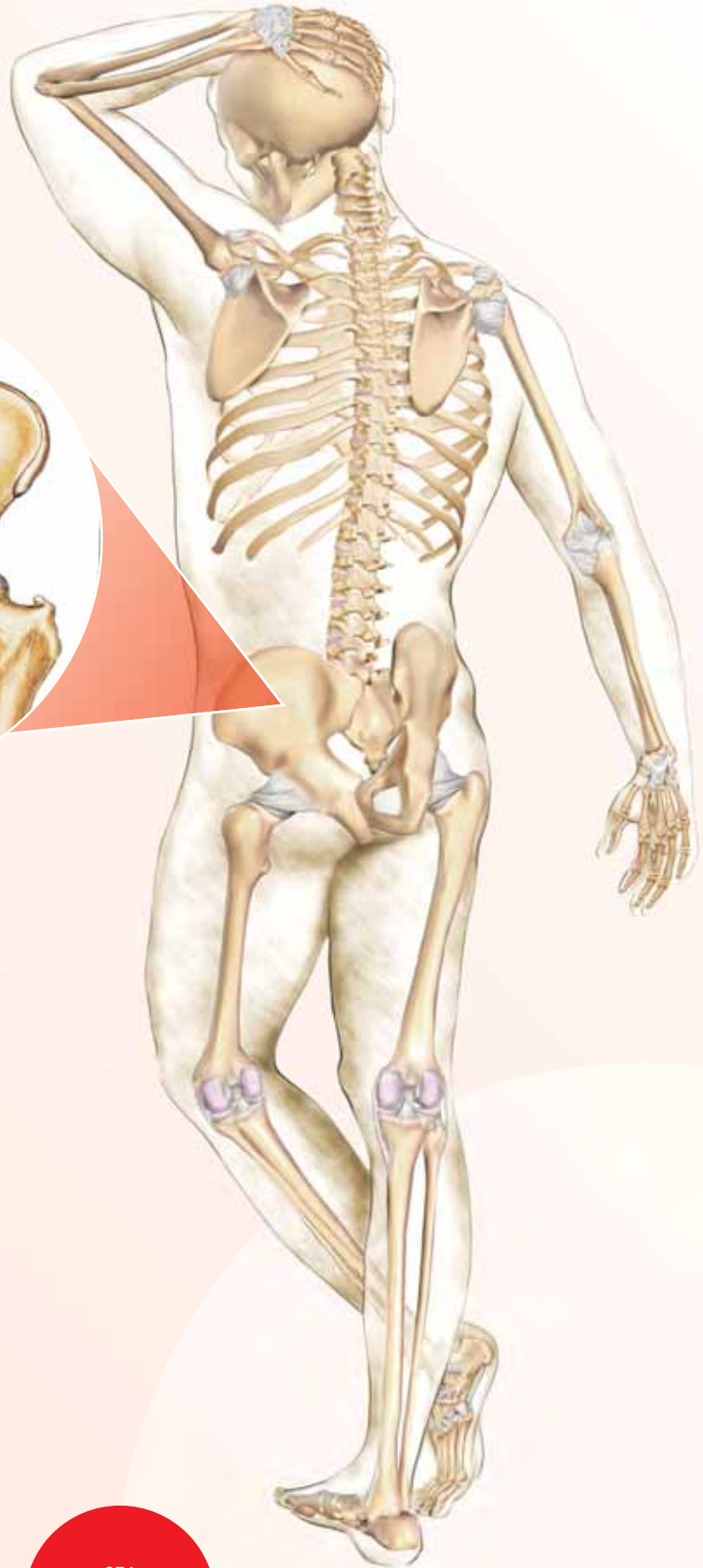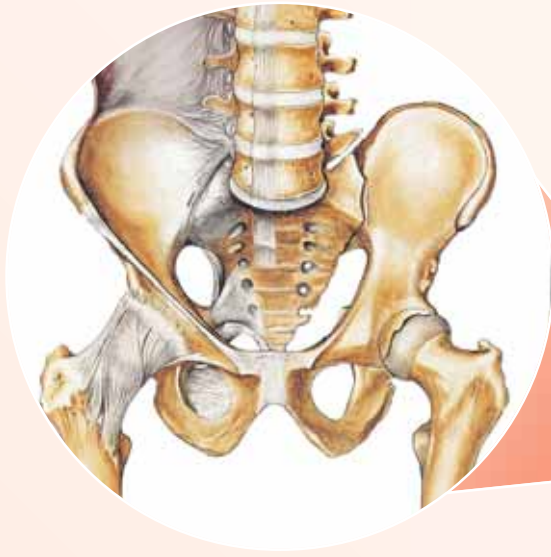
ᐃᑦᐃᑦᐃᑦ

Siiqquaq

Hiitquaq

Rotule

# Pelvis



ԺԿՈԳԵ

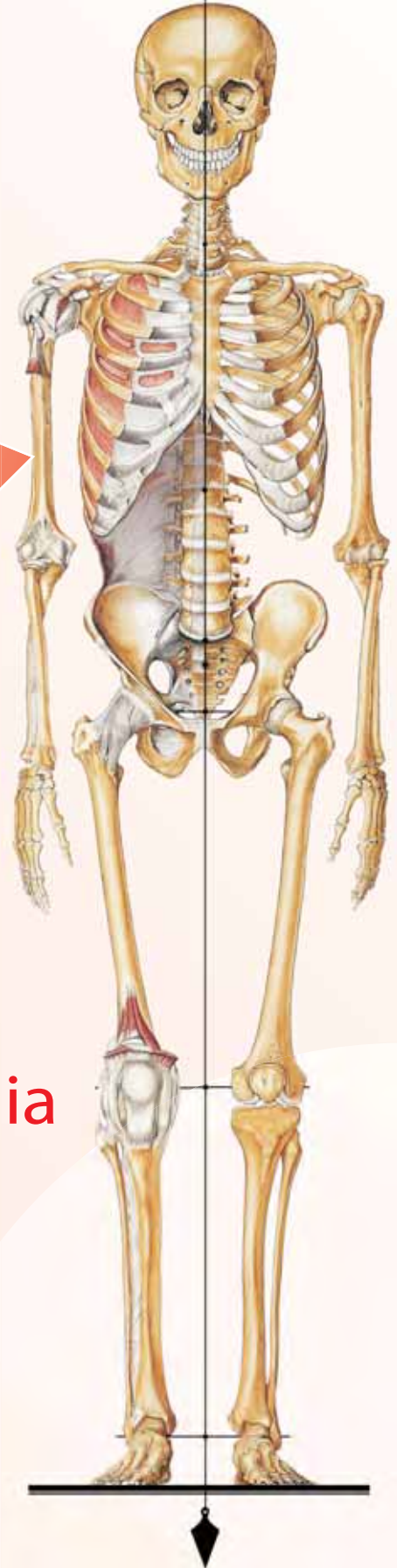
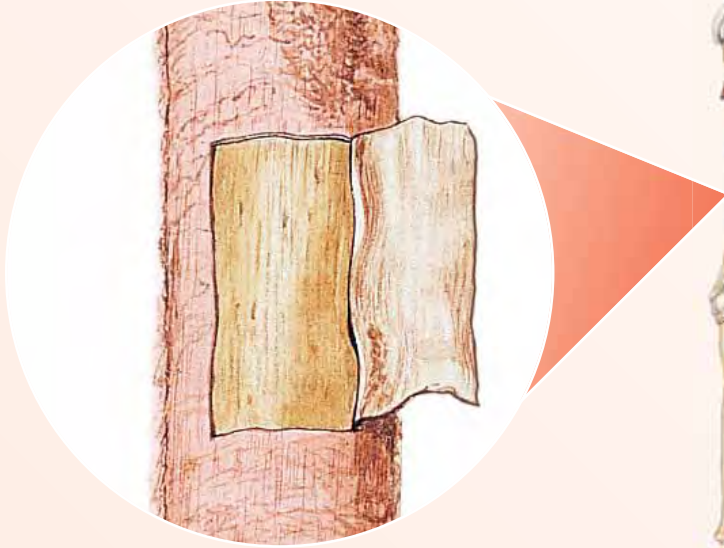
Kuuttiq

Kuuttiq

Bassin



# Periosteum



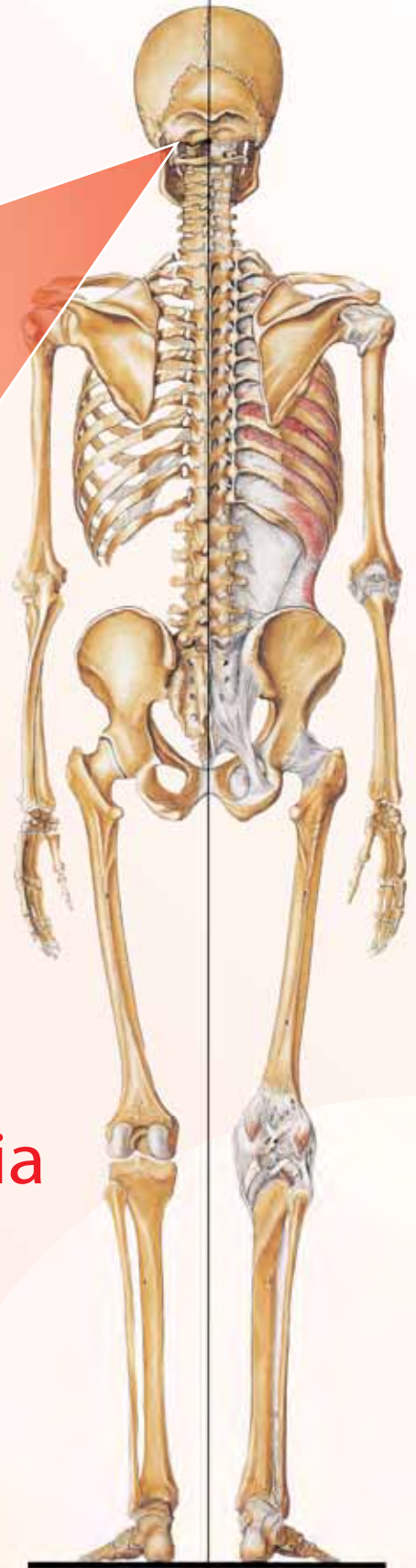
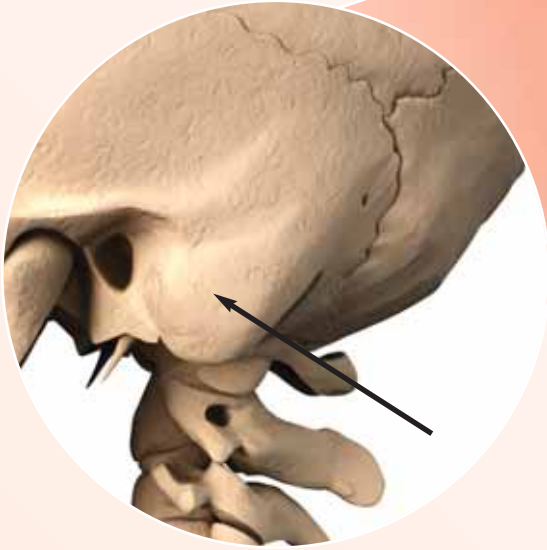ΔΛσ<sup>9b</sup>

Ipiniq

Haun'ngup Mamia

Périoste

# Petrous of Temporal Bone



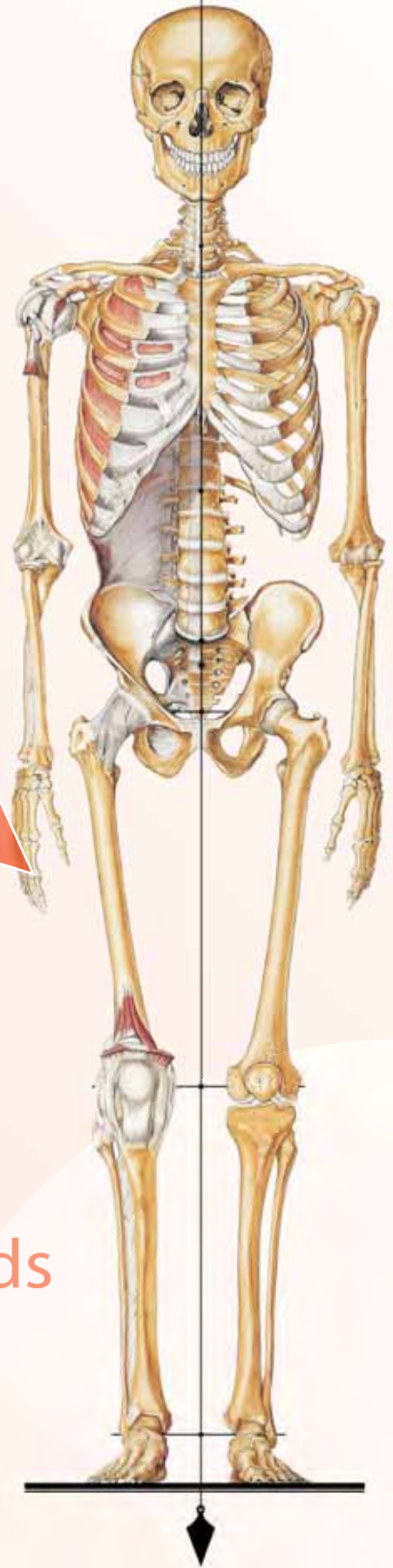
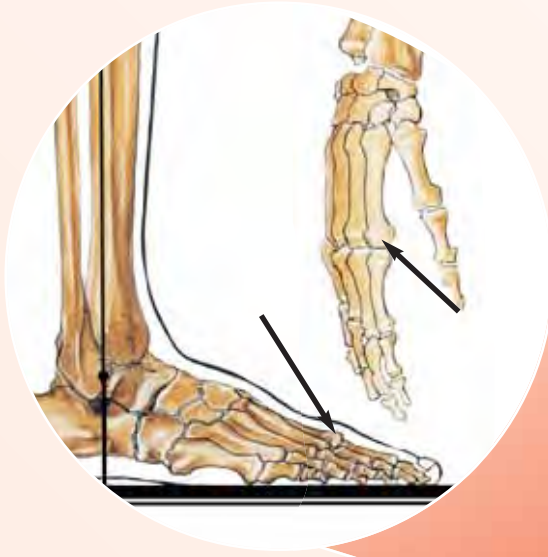ᐱᐅᐅᐅᐅᐅᐅ

Siunnaq

Tuuttiniup Haunia

Rocher de l'os  
temporal

# Phalanges of the Hands and of the Feet



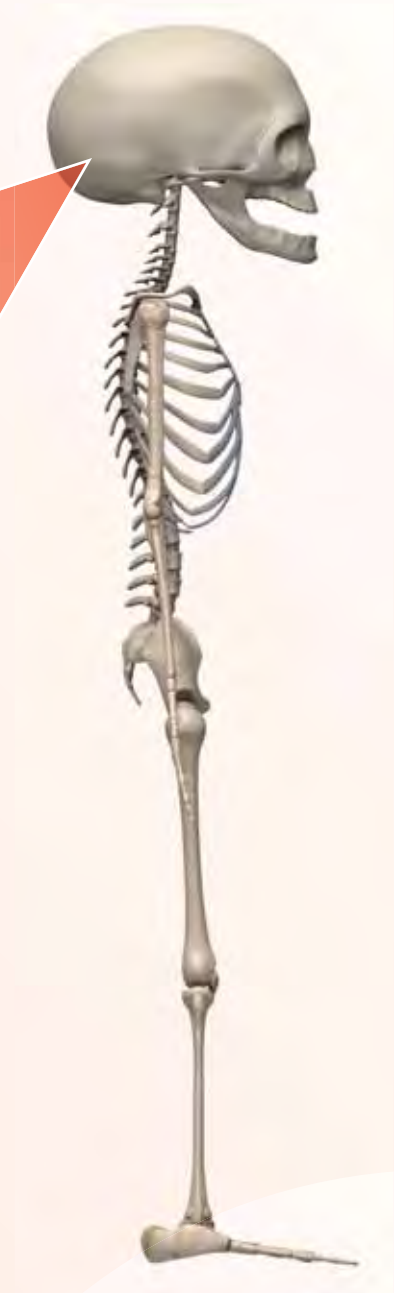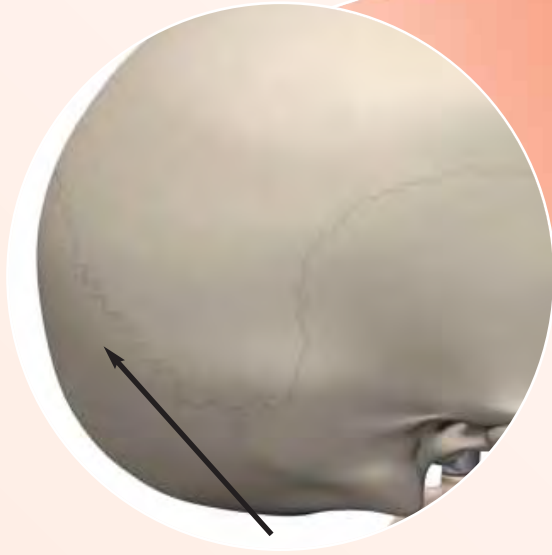Δ\_♁\_Ⓜ\_Ⓜ\_♁\_♁\_♁

Inugannguat

Inugait

Phalanges des  
mains et des pieds

# Posterior Fontanelle

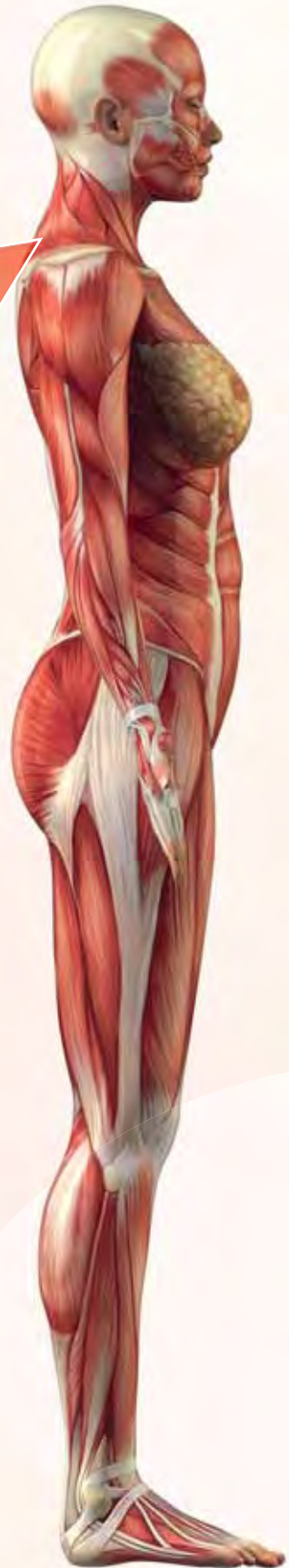
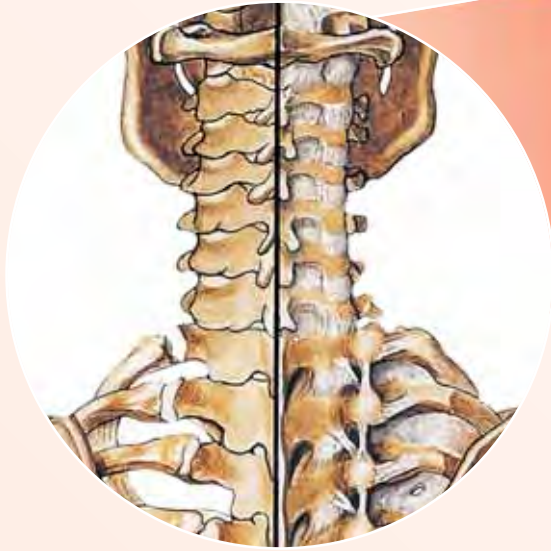
Avaag

Tunuhuk

Fontanelle postérieure

# Protuberance of the First Dorsal Vertebra, Bump



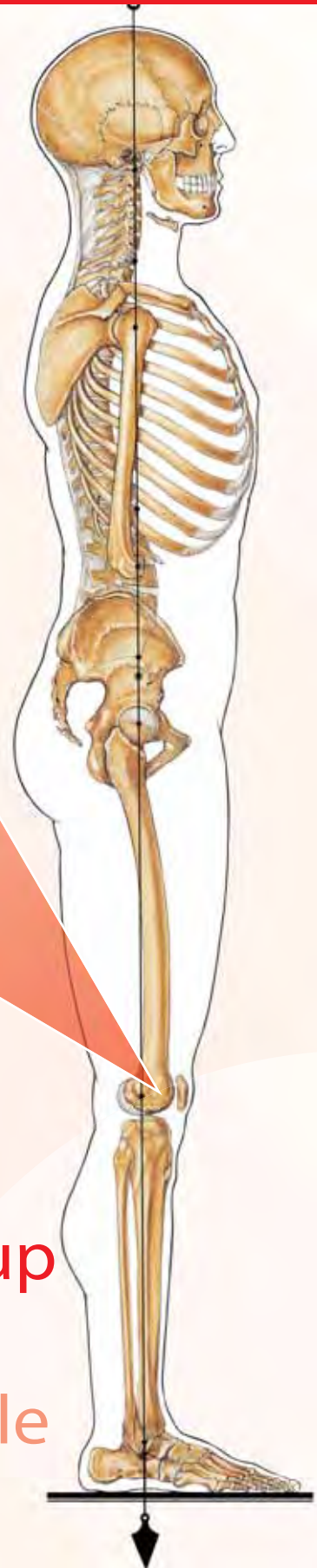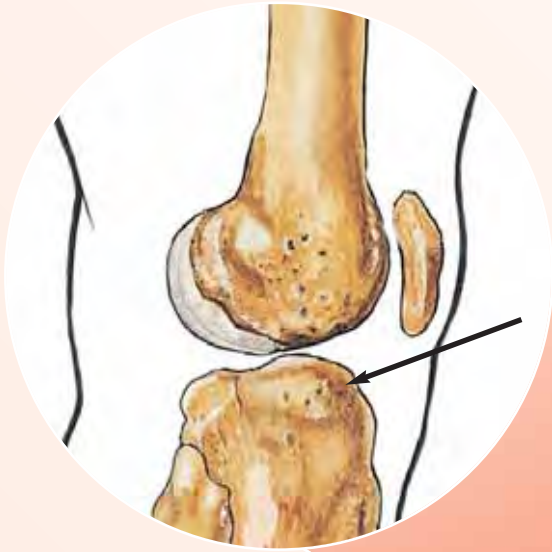
**Ad<sup>b</sup>**

Pikuk

Pikuk

Vertèbre  
proéminente  
dorsale

# Proximal Epiphysis



ᕿᐅᓂᐅᕐ

ᐅᓂᓂᓂᓂᓂ

Sauniup

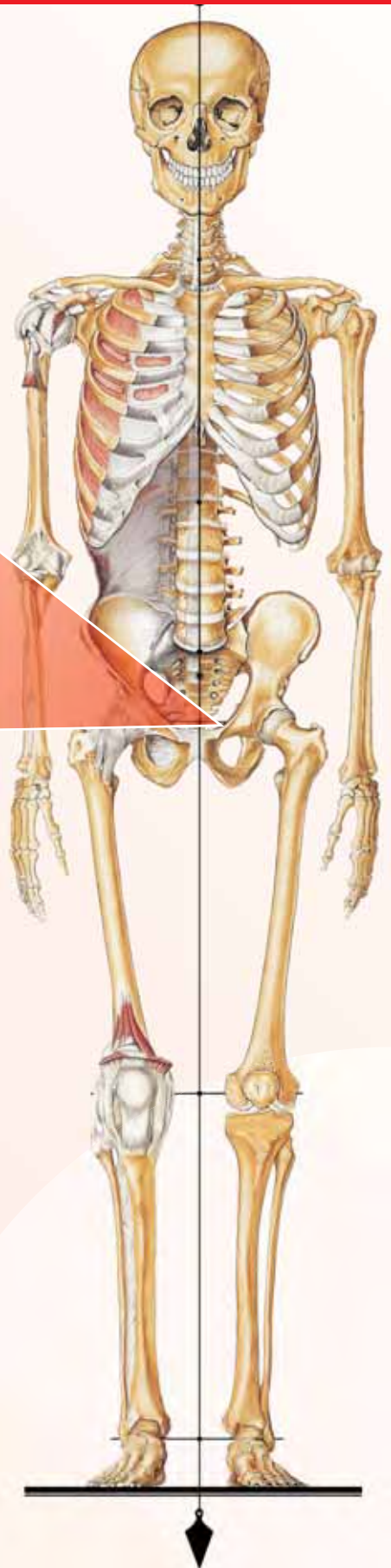
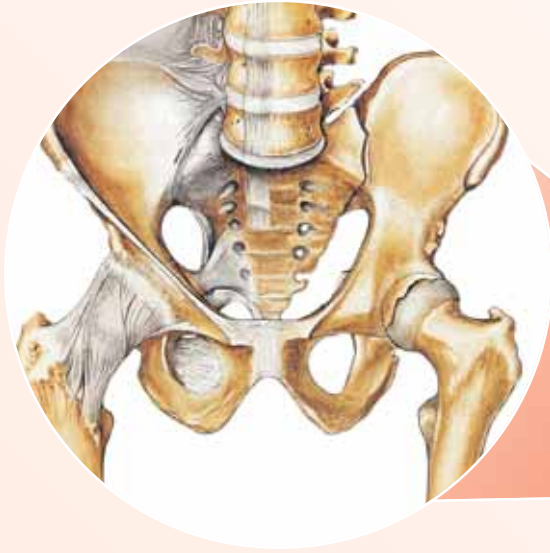
Tunnganinga

Ihugluit/Ipiringniup

Qaqqulaanga

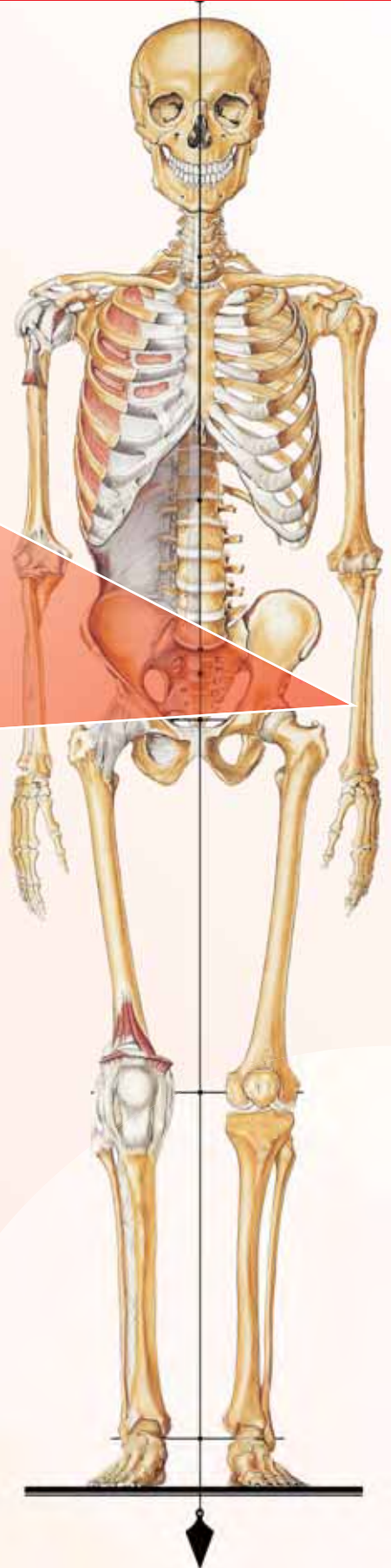
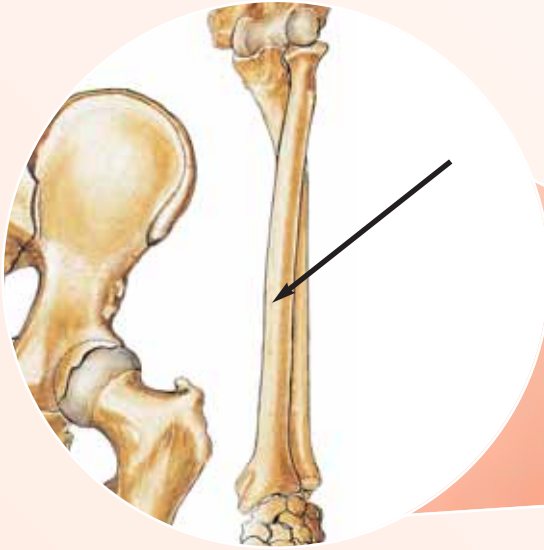
Épiphyse proximale

# Pubic Bone



ᐃᓴᓴ  
Ingi  
Ingik  
Pubis

# Radius

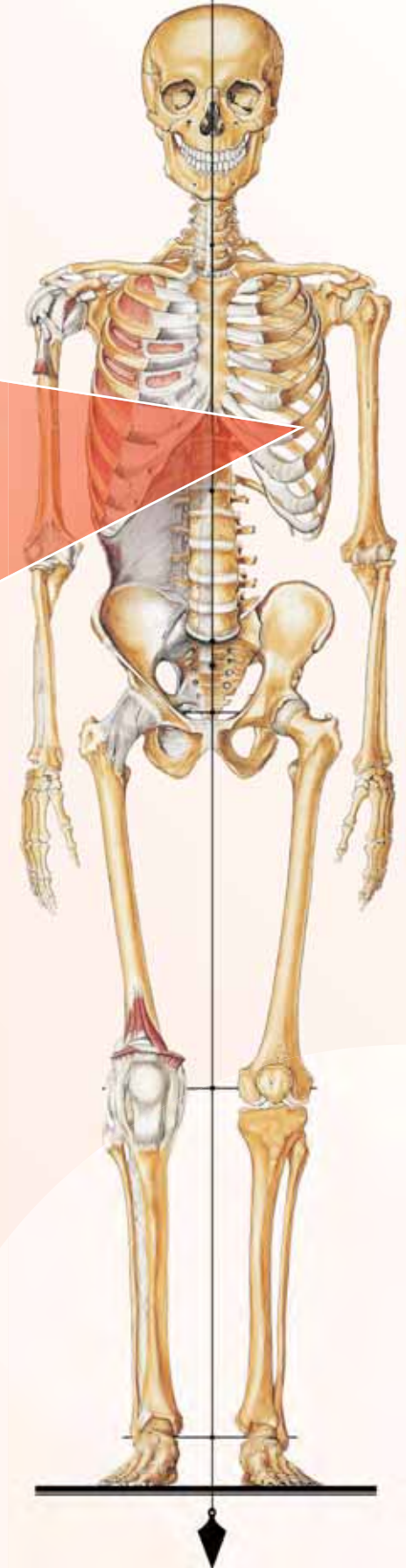
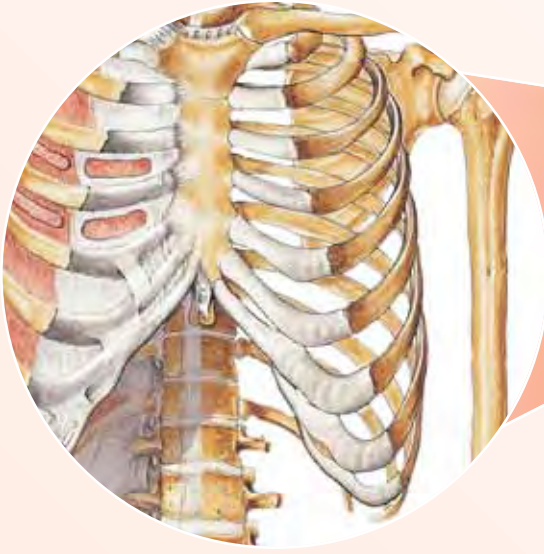


ᐱᕐᕐᕐᕐᕐᕐᕐᕐᕐᕐ  
ᕐᕐᕐᕐᕐᕐᕐᕐᕐᕐᕐ

Aggautiup  
Sauninga  
Pikilhaut  
Radius



# Rib



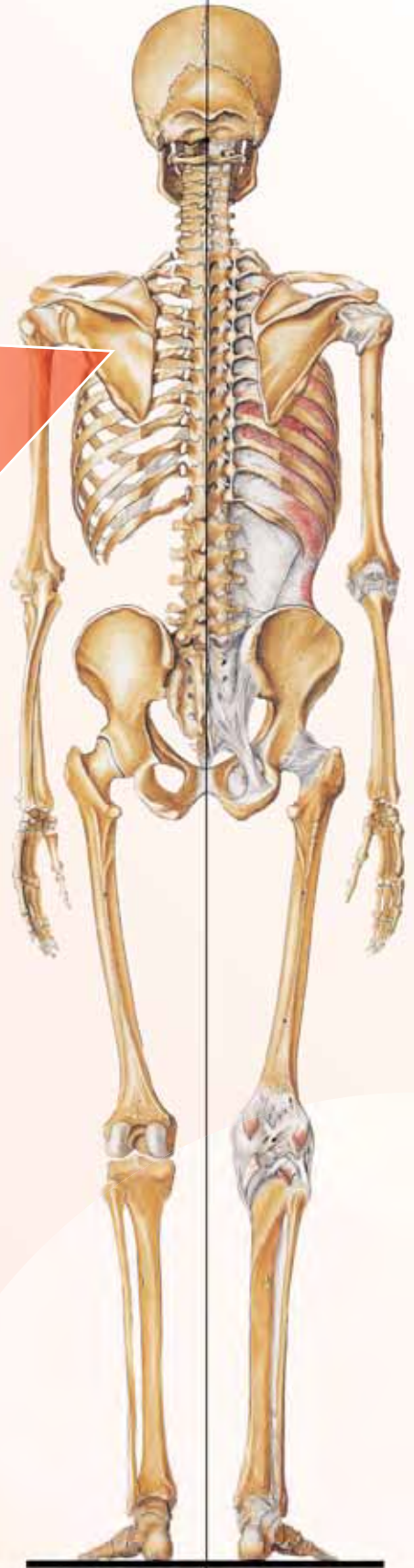
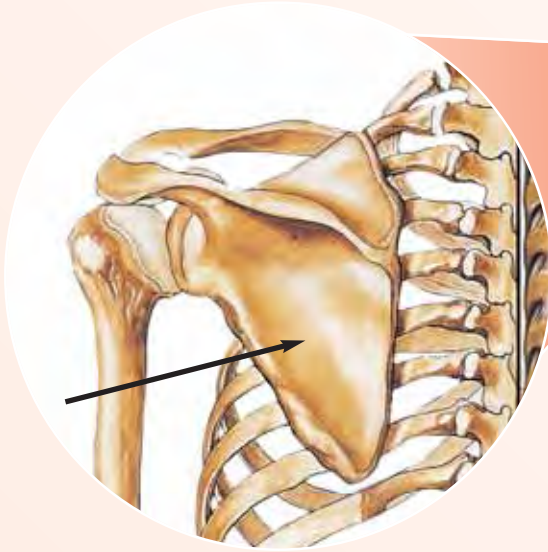
ᐅᐅᐅᐅᐅ

Tulimaaq

Tulimaaq

Côte

# Scapula / Shoulder Blade



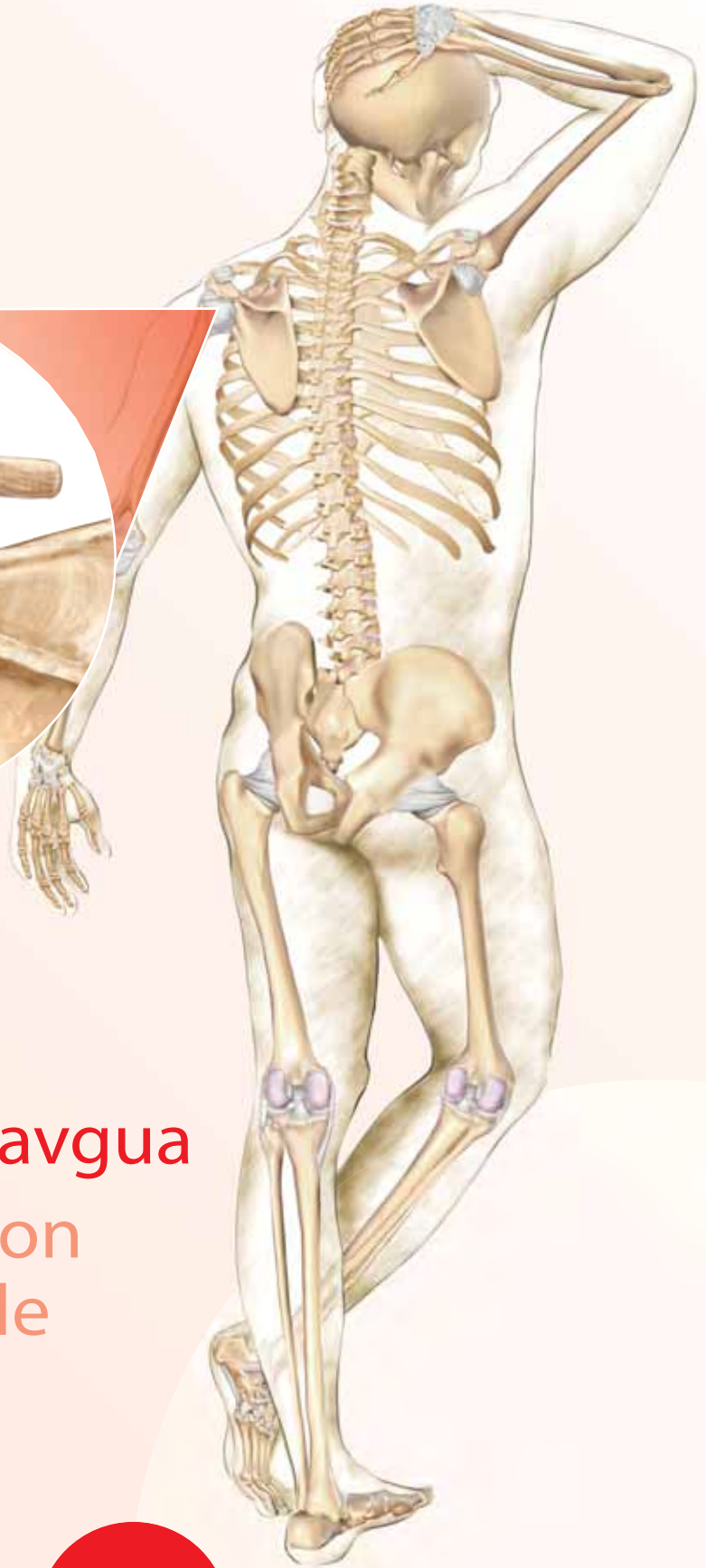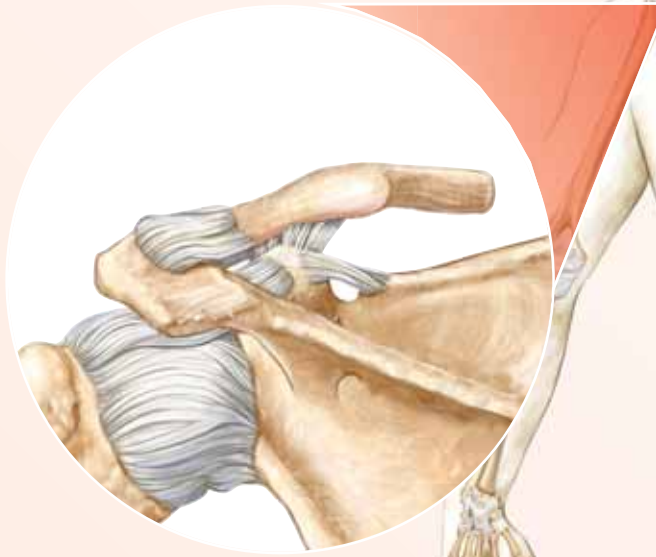
ᐃᐱᐃᐅ

Kiasik

Kiahik

Omoplate ou  
scapula

# Shoulder Joint



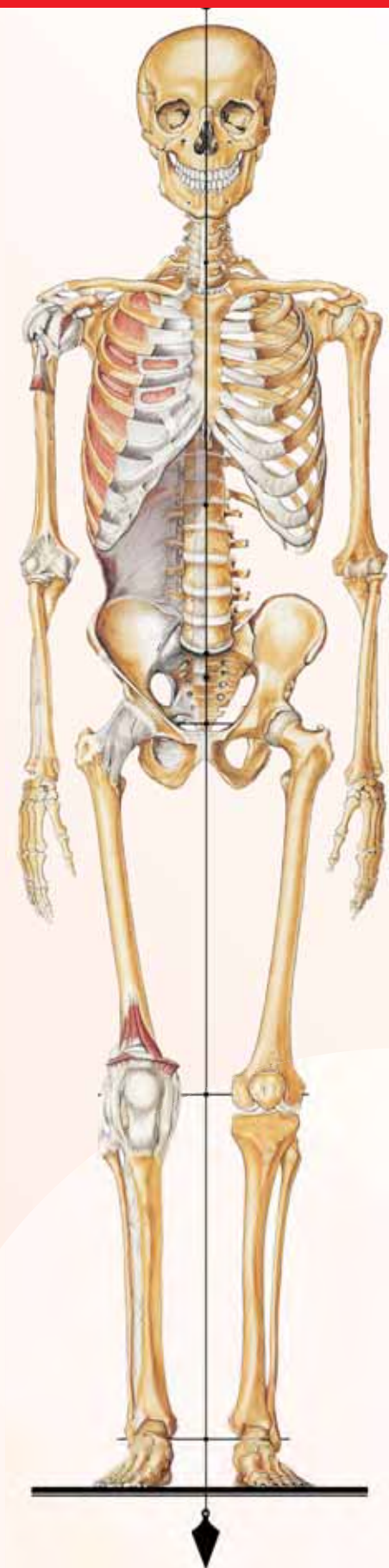
σςϳϳ

Nigalluq

Tuigup Navgua

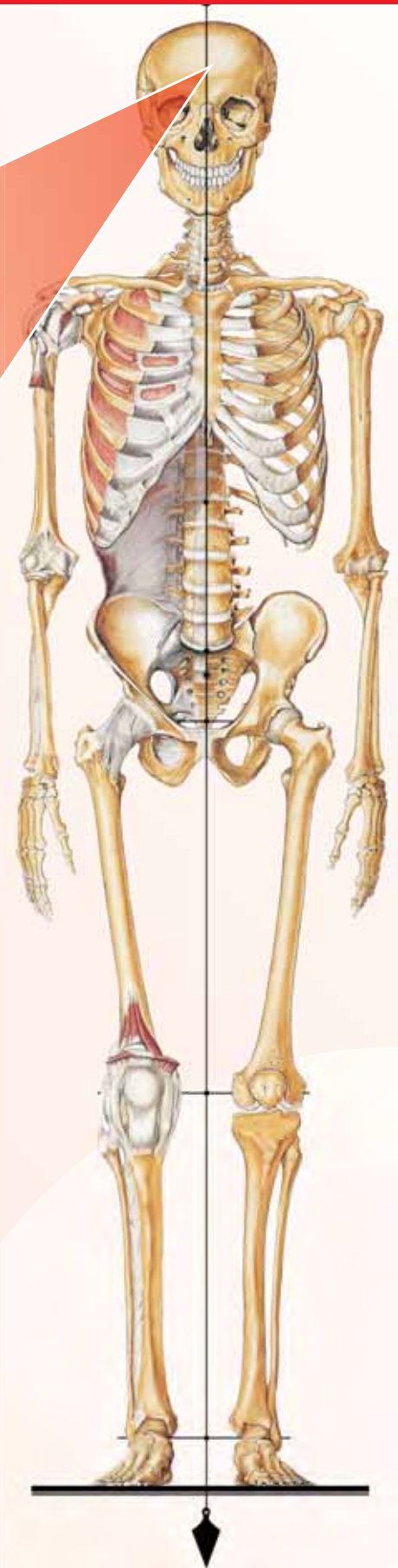
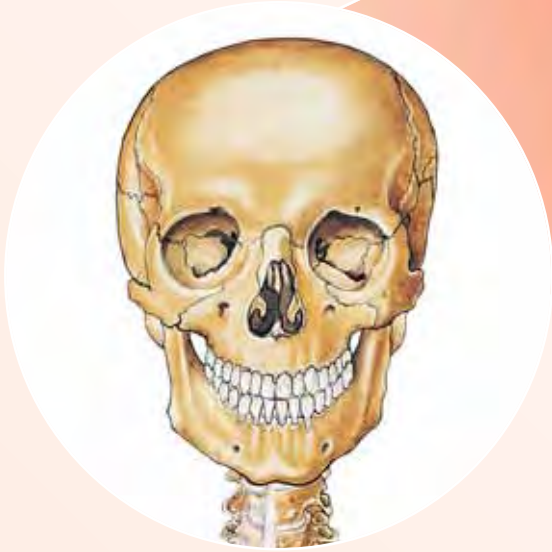Articulation  
de l'épaule

# Skeleton



ᕐᕈᕐᕐᕐᕐᕐᕐ  
Sauniinnaq  
Haun'ngit  
Squelette

# Skull



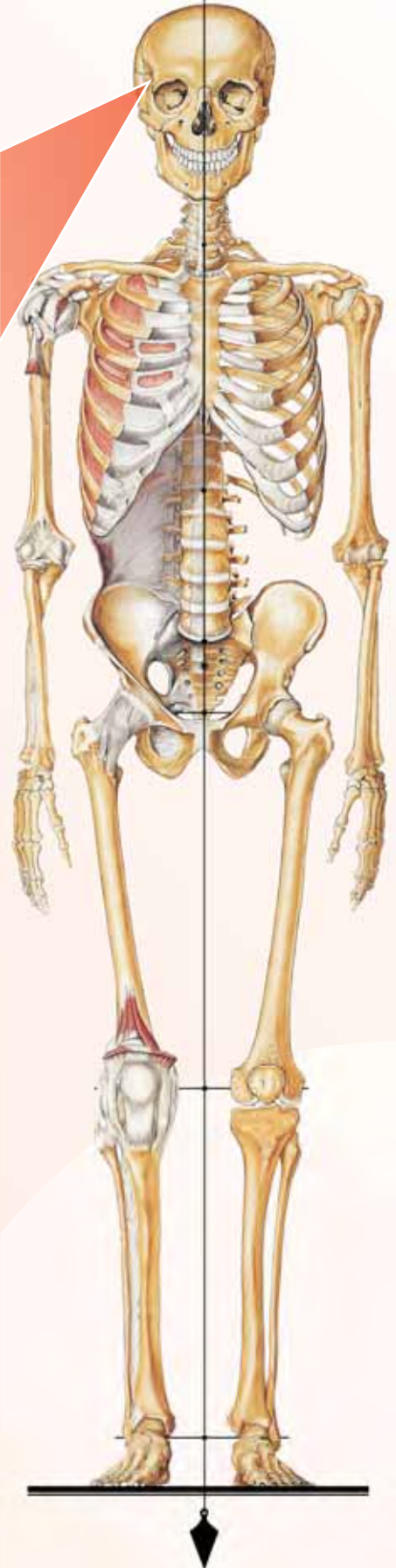
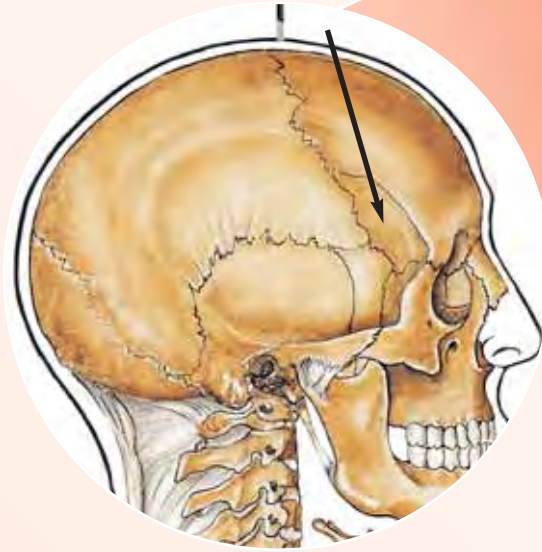
ᓄᐱᐱᐱᐱᐱ

Niaquq

Niaqqup Haunia

Crâne

# Sphenoid Bone



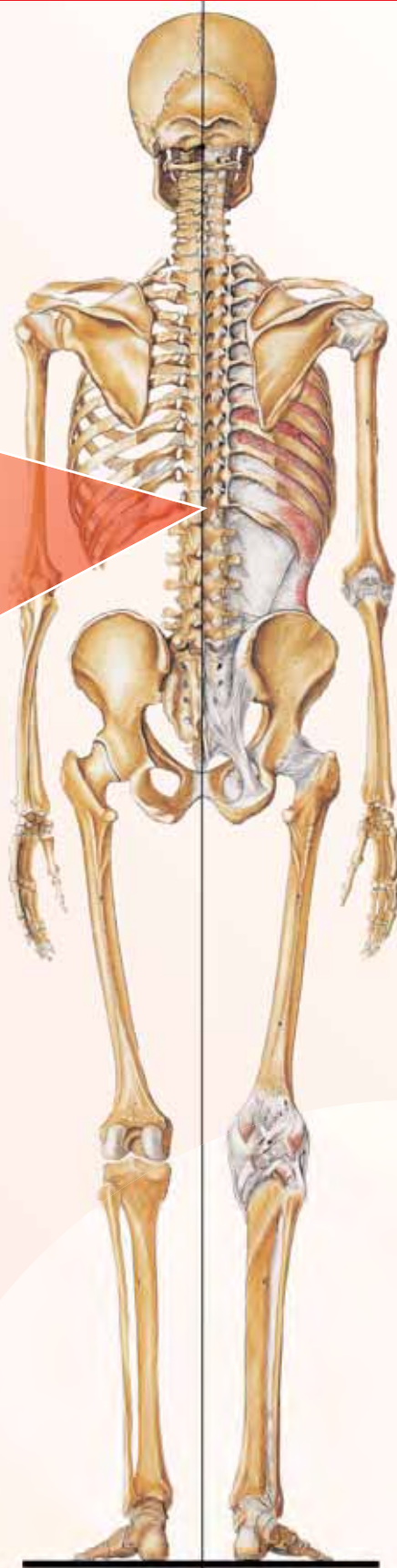
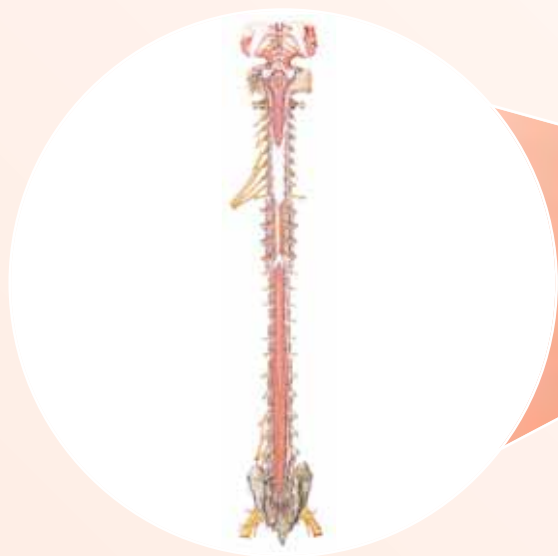Δ ၄၆၂ ၄၆

Iqsaq

Hiutiqarvik

Os sphénoide

# Spinal Cord



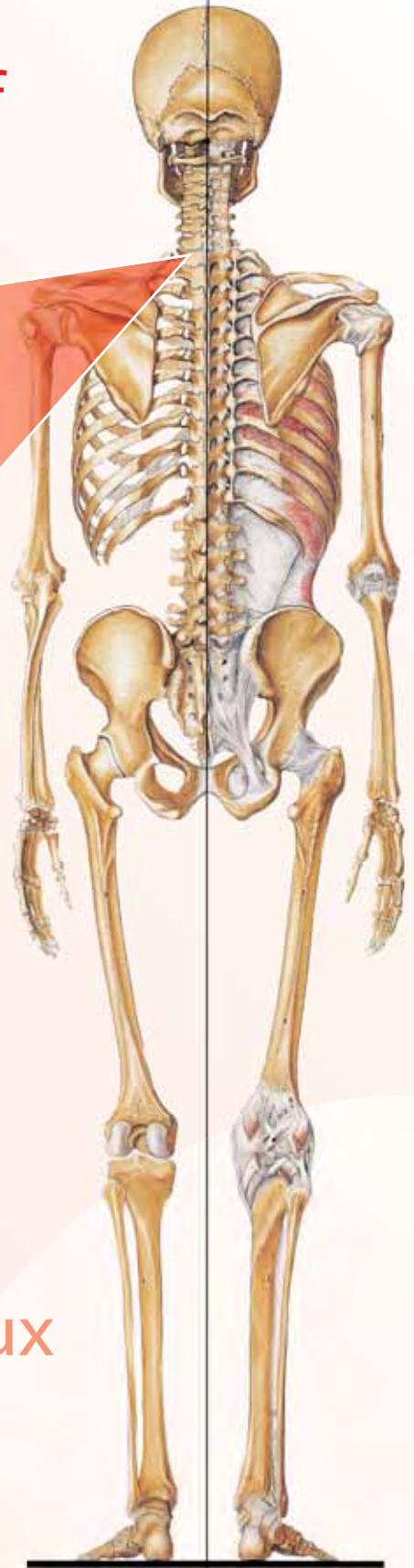
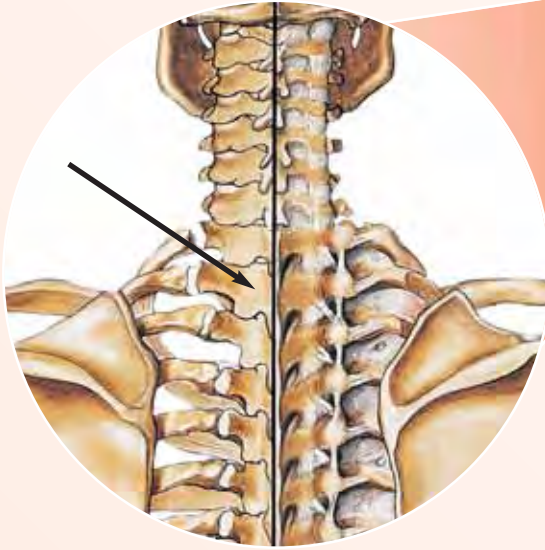
ᄎᄎᄎᄎ

Qitiraq

Qitiraq

Moelle épinière

# Spinal Process of the First Thoracic Vertebrae



Ad

Piku

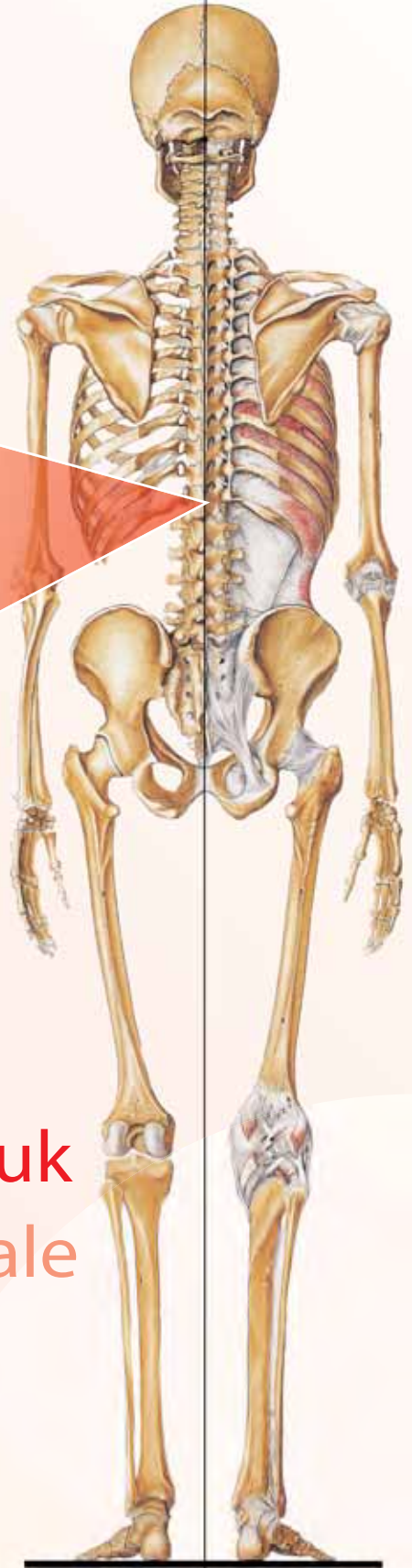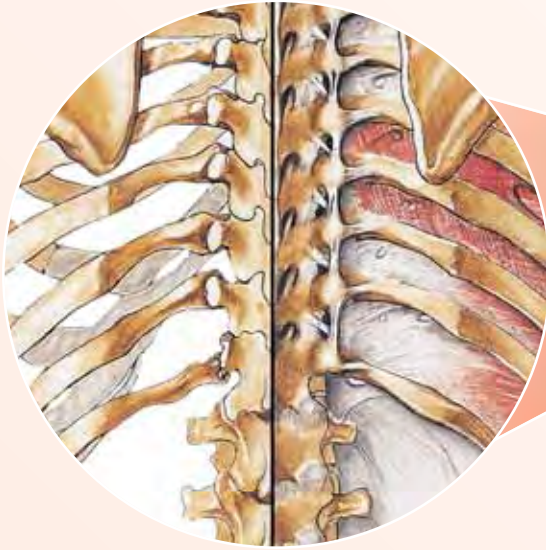
Kuapigaup

Nungummaa

Processus épineux



# Spine



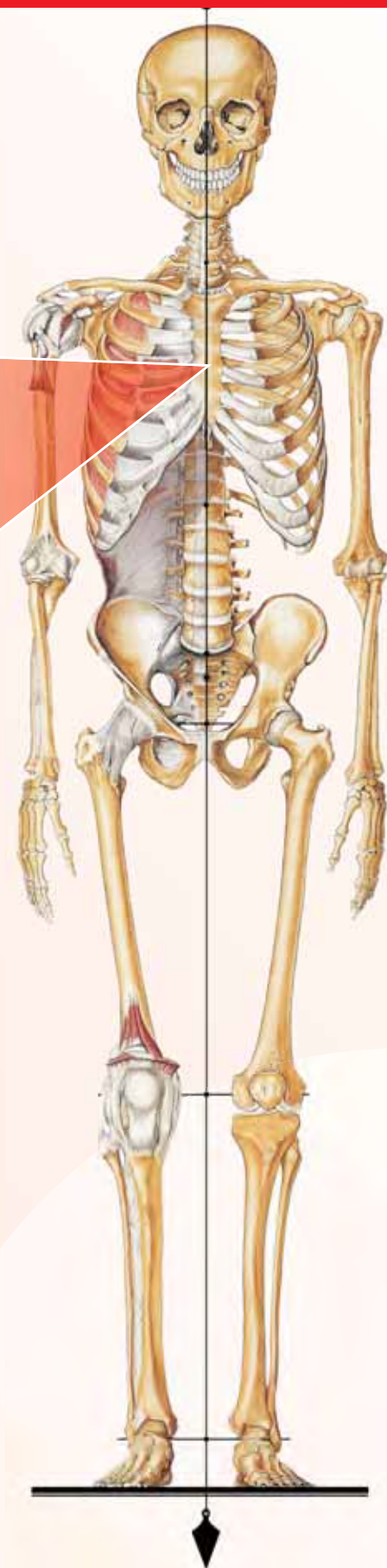
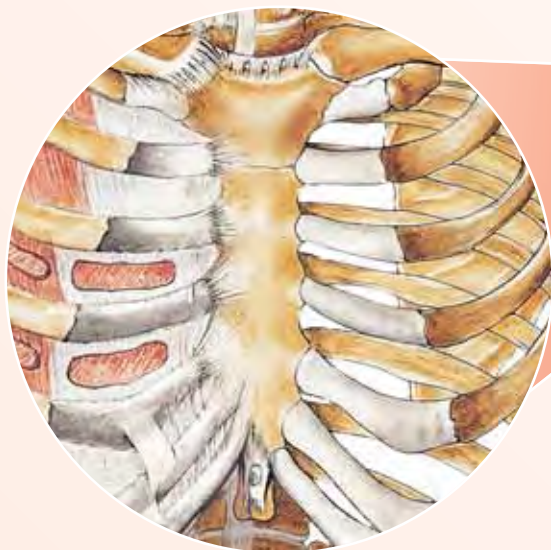
ᄎᄎᄎᄎᄎᄎ

Qimirluk

Kuapigaq/Qimirluk

Colonne vertébrale

# Sternum / Breastbone



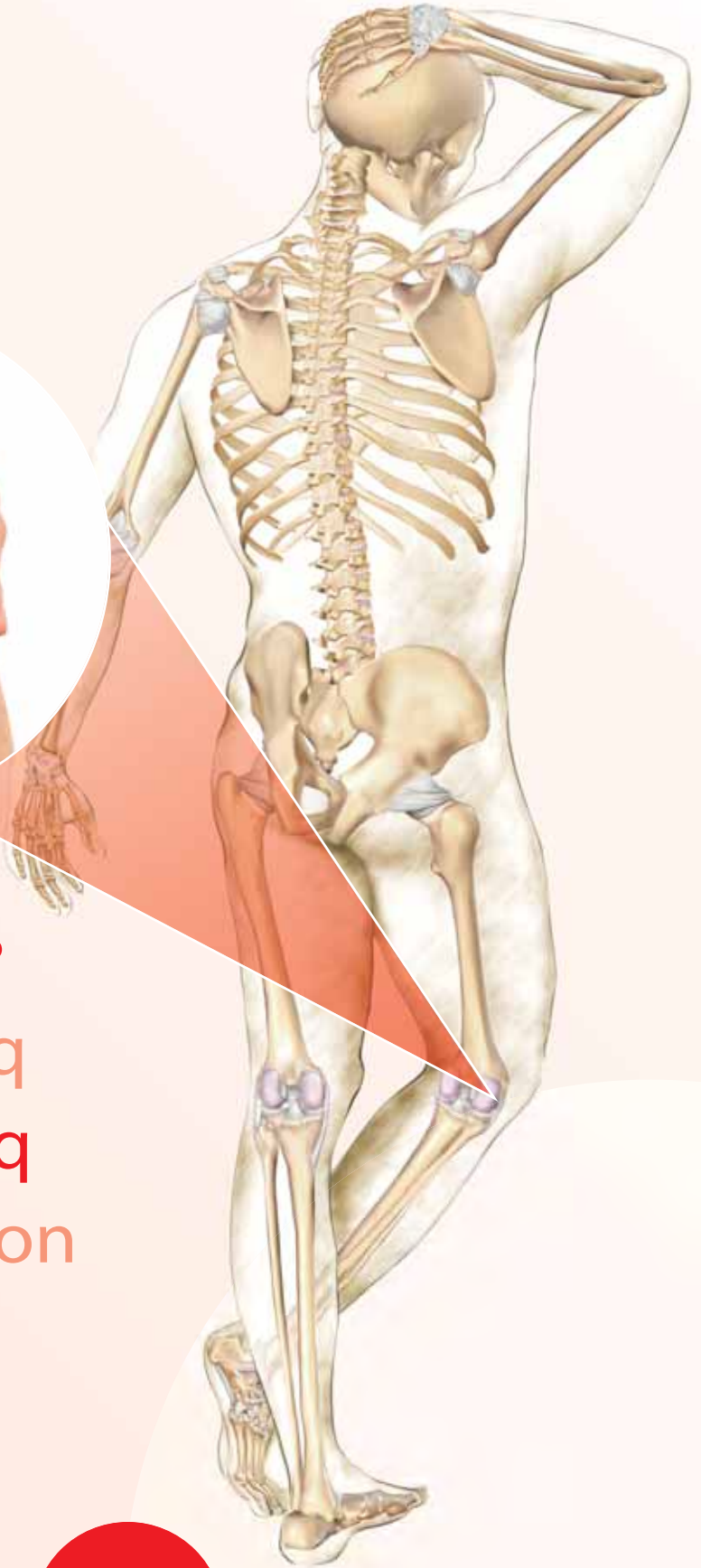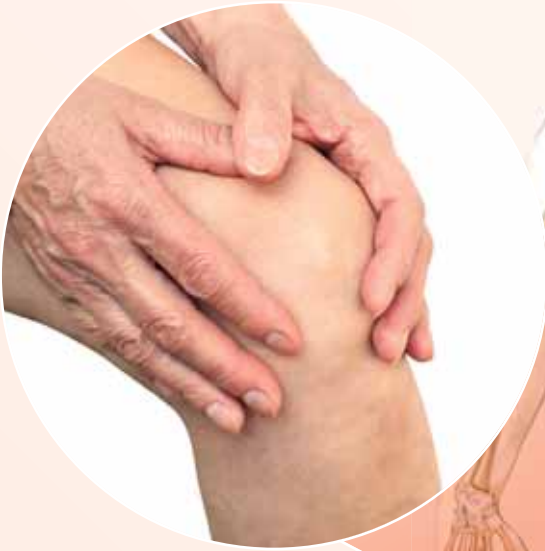ᐱᐳᐱᐳ

Sagvik

Hakiak

Sternum

# Stiffen Joint



ᐃᑦᑲᑦᑲᑦᑲᑦ

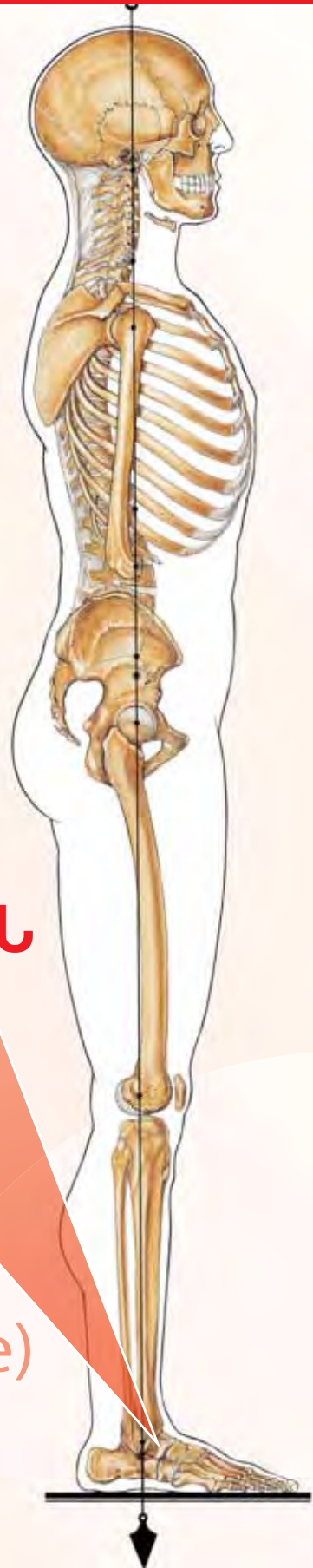
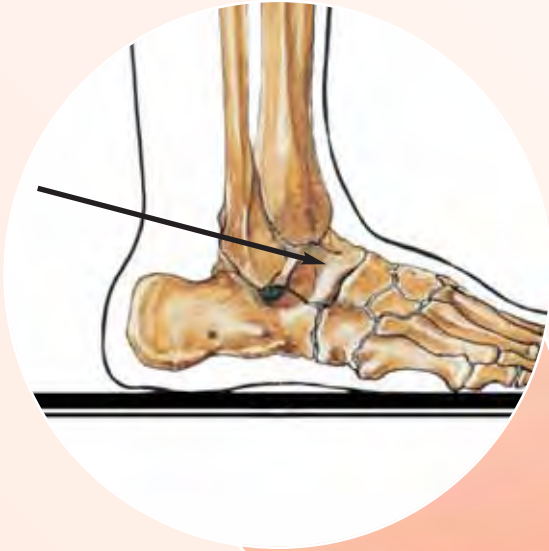Nuqaqtuq

Tumaqtuq

Articulation

raidie

# Talus / Astragalus



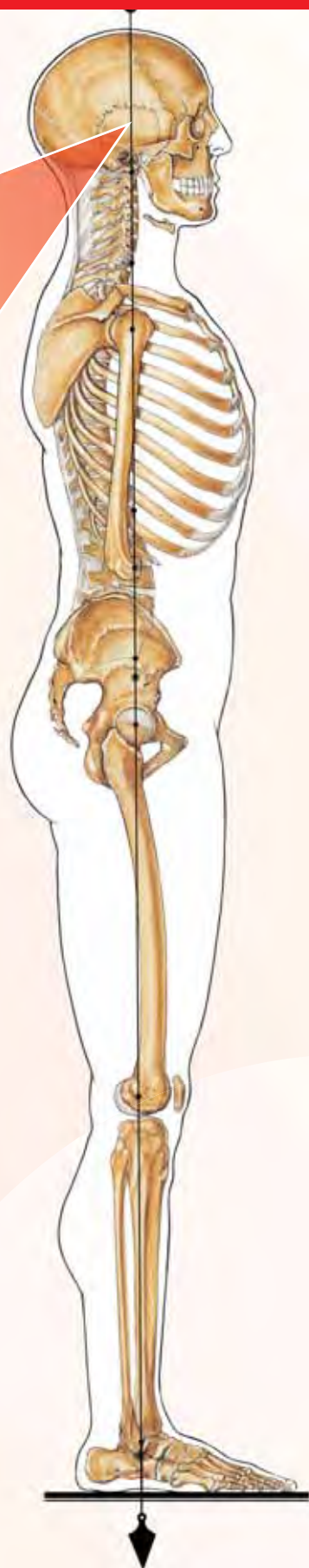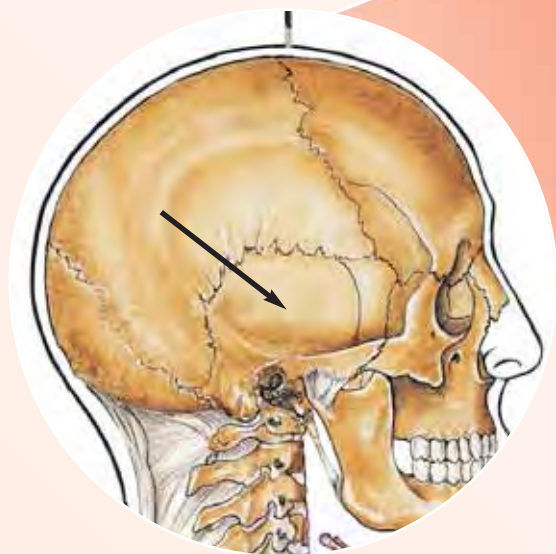
ᲠᲚᲛᲗᲚᲛ ᲠᲚᲛᲗᲚᲛ

Singirniup  
Nagguanga

Itigaup  
Nabluangit

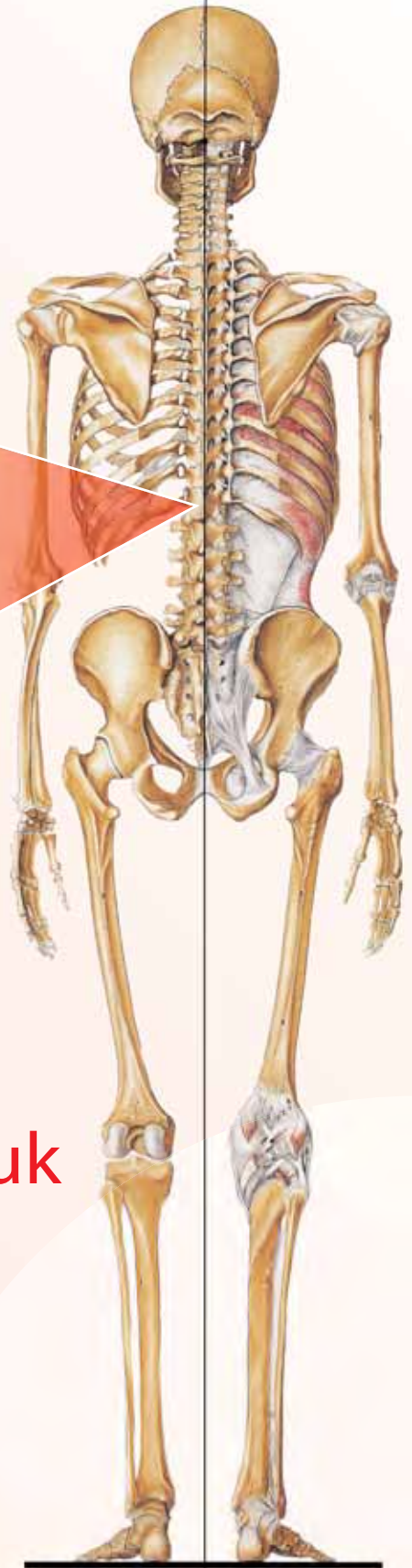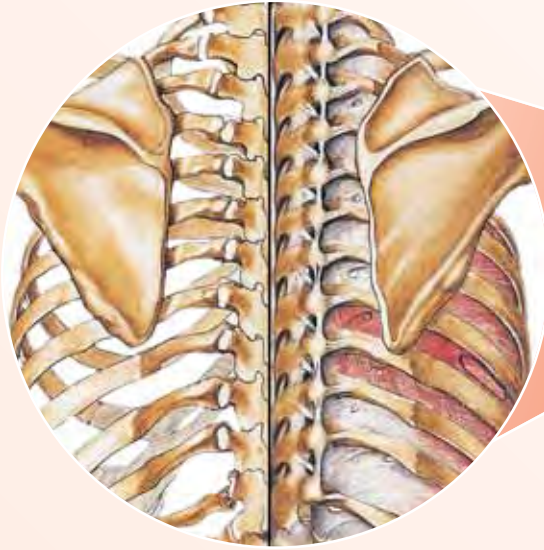
Talus (ou astragale)

# Temporal Bone



Δ<sup>96</sup>Λ▷◁ Λ▷σ<sup>96</sup>Σ  
Iqsaup Sauninga  
Tuuttiniup Haunia  
Os temporal

# The 12 Dorsal Vertebrae



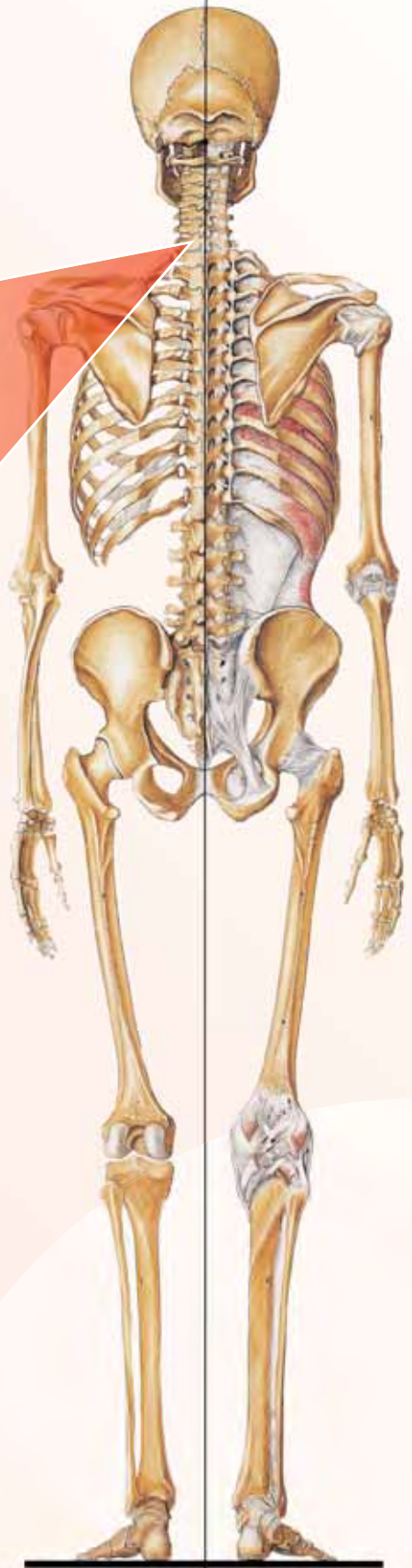
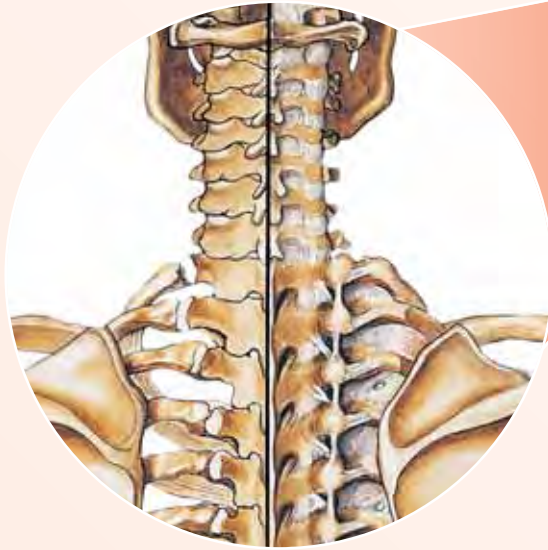
᠙ᠮᠢᠷᠯᠤᠬ

Qimirluk

Kuapigaq Qimirluk

Les 12 vertèbres dorsales

# The 7 Cervical Vertebrae



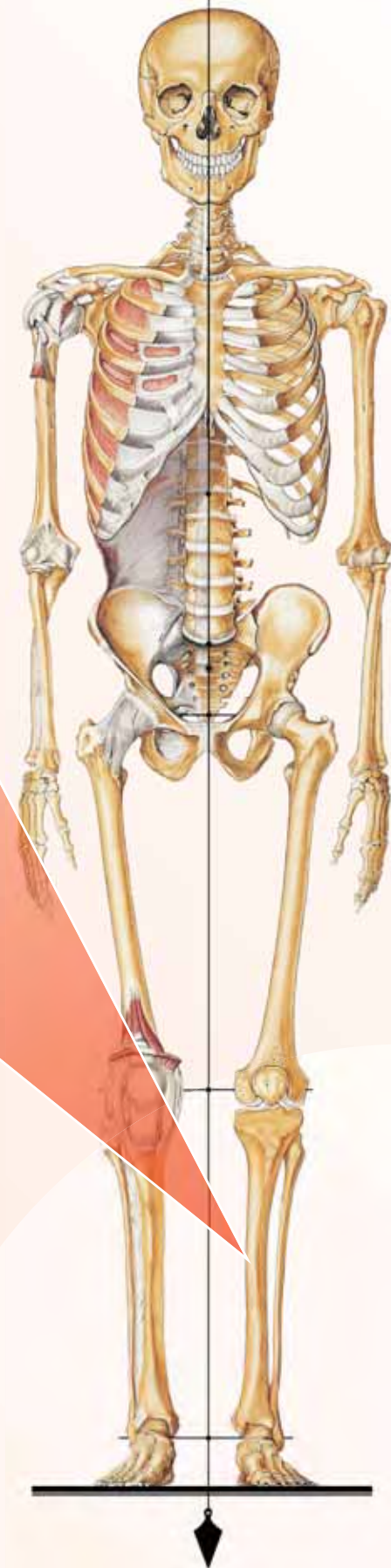
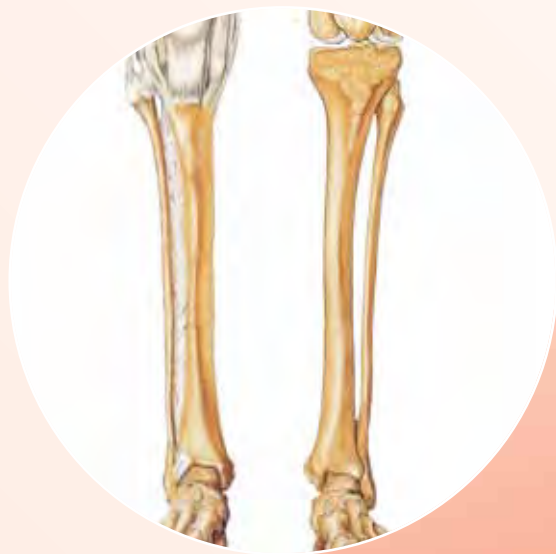ᐅᐅᐅᐅᐅᐅᐅ

Qungasiq

Niuliq

Les 7 vertèbres  
cervicales

# Tibia / Shinbone



հրճյճԵ

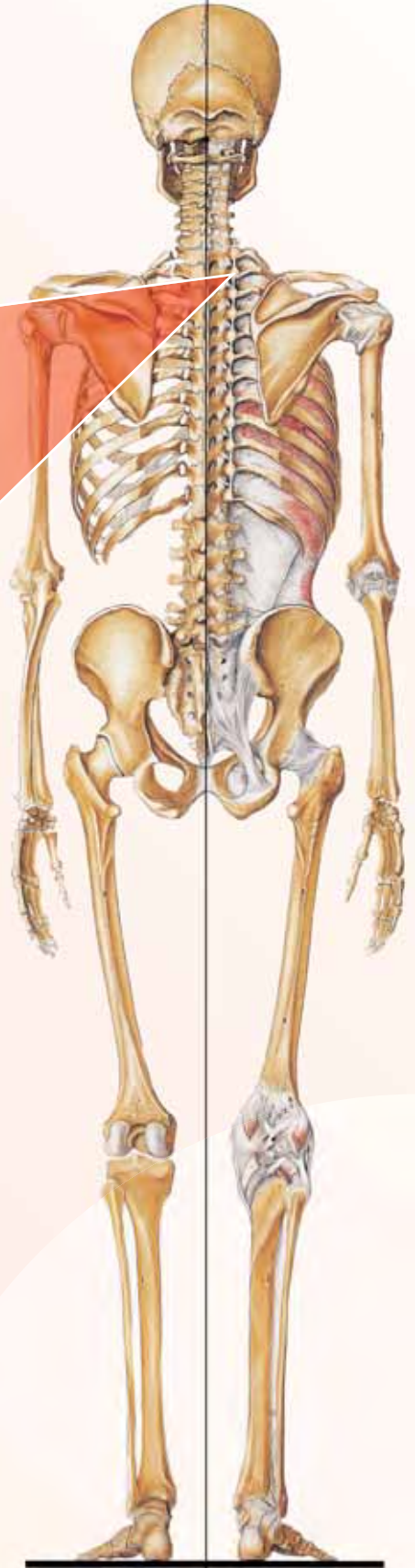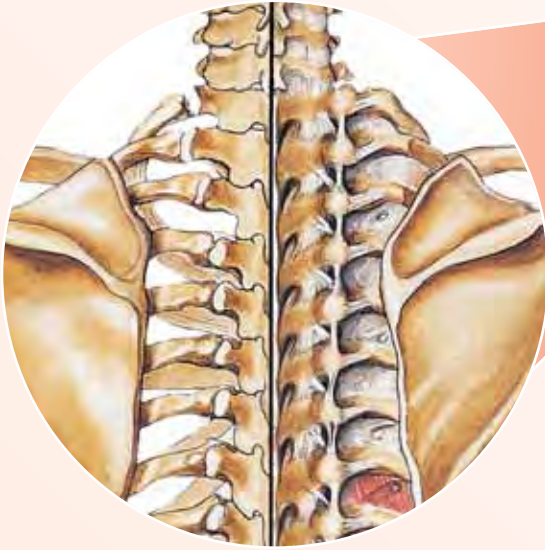
Qingaaq

Qingaaq

Tibia



# Transverse Process



Δ50°

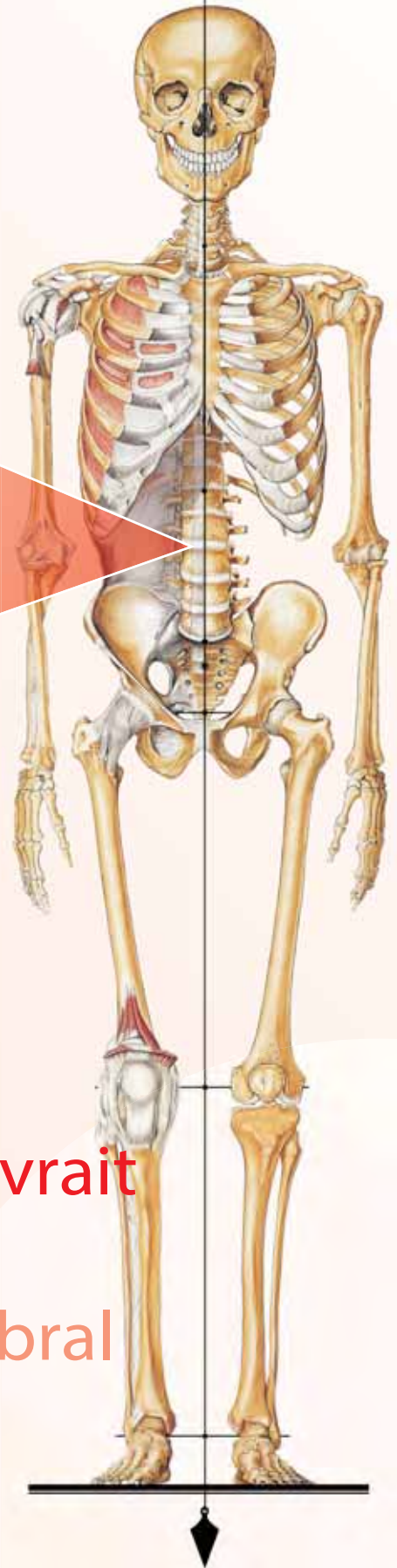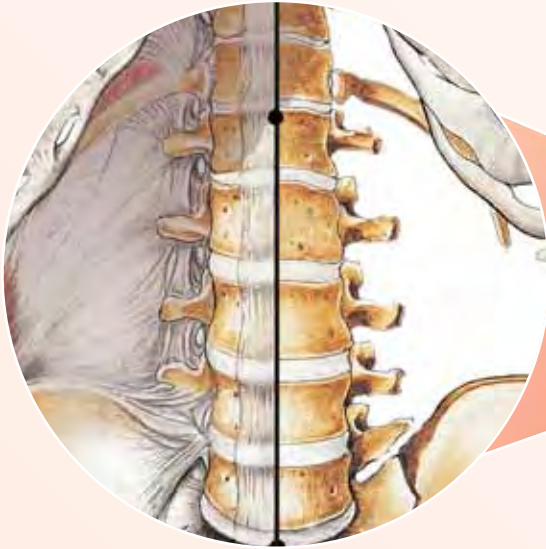
Isatit

Kanivautiqarvik

Processus  
transverse



# Vertebral Body Inter-Vertebral Disc



Δῖλσᶜᵇ

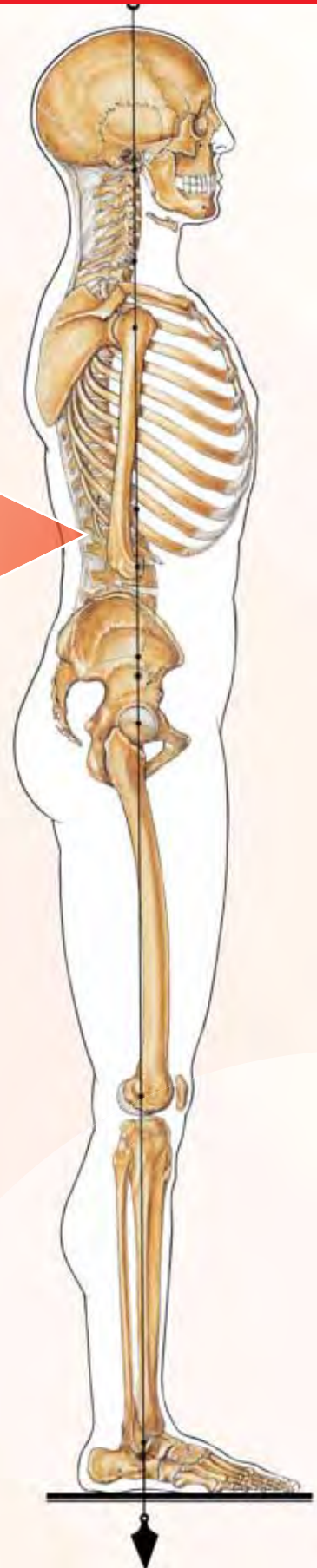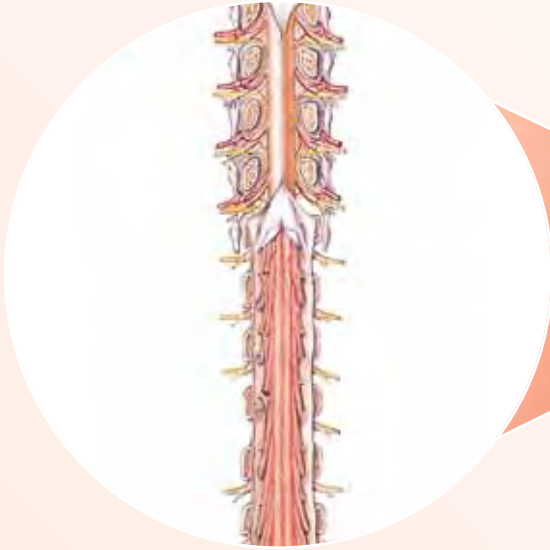
Isiriniq

Qimirluup

qaqqulaangit/ikuvrait

Corps vertébral,  
disque intervertébral

# Vertebral Canal



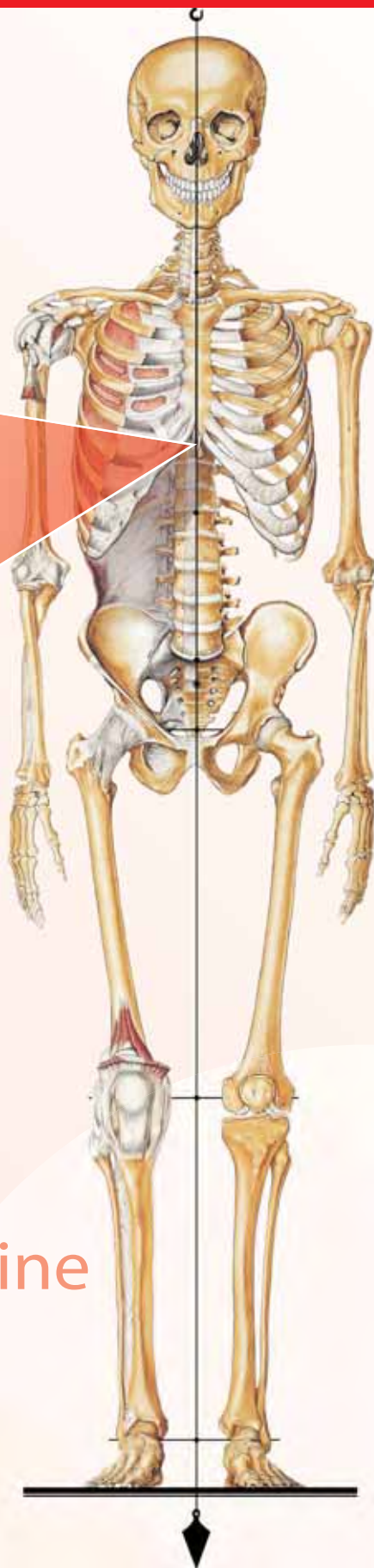
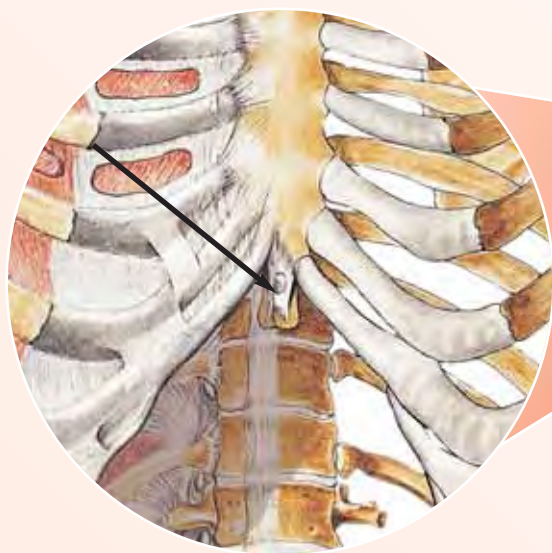
ԳՐՈԿԳԵՎԻՆ

Qitiraqarvik

Pattaq

Canal vertébral

# Xiphoid



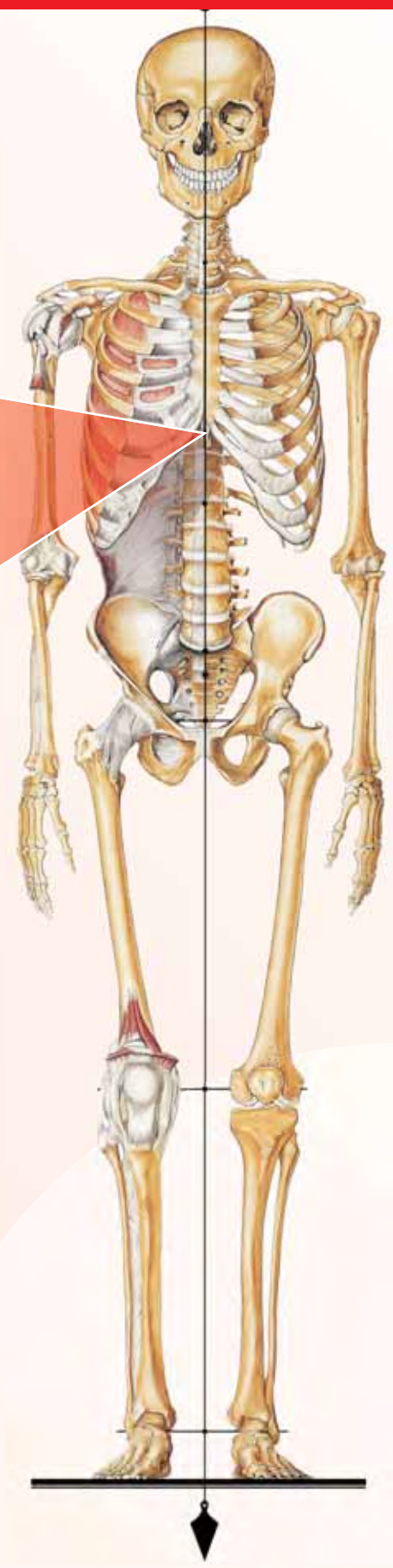
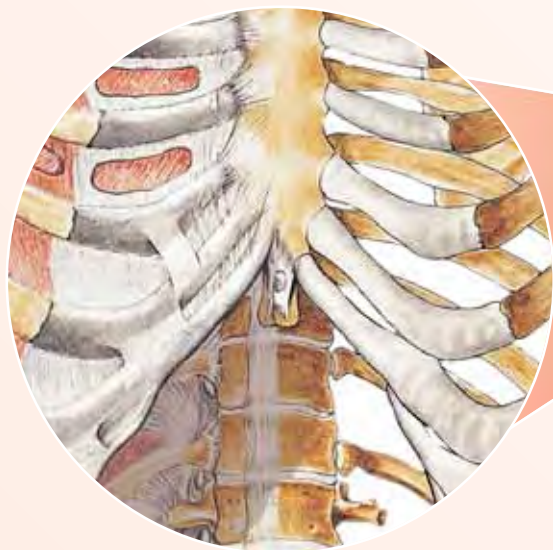
ᐱᓐᓂᓂᓐ

Saqqaaq

Ilaun'nguaq

Creux à la base  
du sternum, poitrine

# Xiphoid Process



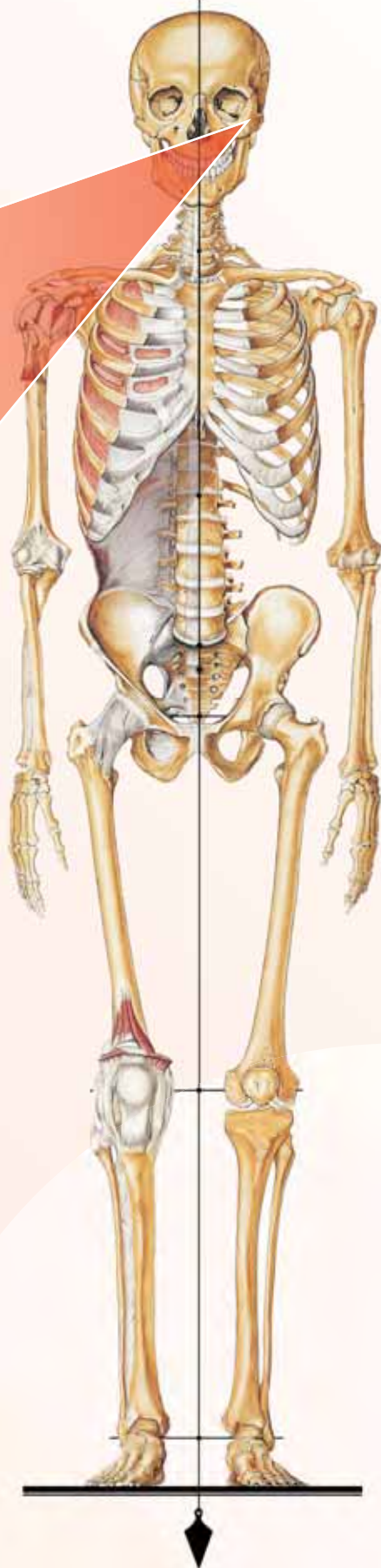
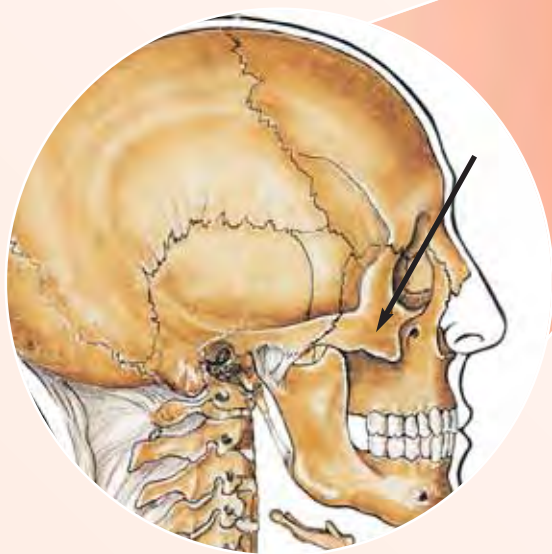ᐱᐅᐅᐅᐅ

Saqqaaq

Ilaun'nguyaaq

Appendice  
xyphoïde

# Zygomatic Arch



ᐅᐱᐱᐱ ᐱᐅᐱᐱ

Uluap Sauninga

Agliqqup Kangia

Arcade

zygomatique





IBC Blank



ᐃᑦᑲᑦᑲᑦᑲᑦᑲᑦᑲᑦ  
Pitquhiliqiyikkut  
Culture and Heritage  
Culture et Patrimoine